

# Expression of PGE2 on defenses of the gingival epithelium injected LPS Porphyromonas gingivalis with the administration of curcumin

*by Eka Fitria Augustina*

---

**Submission date:** 04-Apr-2023 09:47AM (UTC+0800)

**Submission ID:** 2055171289

**File name:** Expression\_of\_PGE2\_on\_defenses\_of\_the\_gingival\_epi\_1.pdf (793.82K)

**Word count:** 3441

**Character count:** 19181

# Expression of PGE2 on defenses of the gingival epithelium injected LPS Porphyromonas gingivalis with the administration of curcumin

Augustina EF, Periodontics Department, Universitas Airlangga, Mayjen Prof Moestopo 47, Surabaya, East Java-Indonesia, 60132.

email : [ekafitria32@yahoo.com](mailto:ekafitria32@yahoo.com)

## ABSTRACT

**Background and Objective(s) :** Epithelial cells in the gingiva epithelium are among the first host cells encountered by periodontal pathogens such as Porphyromonas gingivalis. The lipopolysaccharide (LPS) of P. gingivalis is a crucial virulence factor critically involved in the regulation of immune inflammatory responses. Early prevention is necessary for the onset of periodontitis, especially in tissues that have been exposed to gingivitis by maintaining the primary defenses of the gingival epithelium. One of the effective and efficient efforts by utilizing the plant nutritious plant extracts curcumin. Curcumin is a medicinal plant material that has anti-inflammatory properties, as a factor inhibiting transcription factor NF- $\kappa$ B. Barriers to NF- $\kappa$ B are expected to decrease the expression of pro-inflammatory mediators that play a role in defective gingival epithelial defenses in cases of gingivitis. It is therefore suspected that inflammatory mediators associated with periodontitis, PGE2 also play an important role in the mechanism of damage to the gingival epithelial defect which may result in the breakdown of deeper periodontal tissue. The aim of the study is to determine the role of PGE2 in the defense of the gingival epithelium in intervention by LPS Porphyromonas gingivalis by administering curcumin.

**Materials and methods:** 40 wistar rats, aged 2-3 months divided into control and treatment group. which got 5 heads for each group. Animal production of gingivitis, performed by induction of LPS P.gingivalis is injected into the gingival sulcus of the mandibular incisor proximal portion and since 48 hours from injection of LPS P gingivalis done giving kurkumin. Days 1, 7, and 14, wistar is sacrificed according to the group and gingival epithelial tissue is taken for immunohistochemical examination procedure to determine expressions of PGE2.

**Results :** The results from immunohistochemical examination showed decreased PGE2 expression after administration of curcumin, compared with group without administration of curcumin.

**Conclusion :** Administration of curcumin in wistar rats after induction with LPS P.gingivalis decreased PGE2 expression. Decreased expression of inflammatory mediators can maintain the gingival epithelial defenses.

**Keywords :** gingiva epithelium, LPS, Porphyromonas gingivalis, PGE2

Email : [ekafitria32@yahoo.com](mailto:ekafitria32@yahoo.com)

## Introduction :

Inflammatory disease in periodontal tissue (periodontitis) is still a problem in many developing countries including in Indonesia due to its very high prevalence.

Periodontitis is irreversible, so if treatment not optimal, most patients have the potential for lifelong disruption.<sup>1</sup> Periodontitis begins with the onset of gingivitis,

which is clinically visible features of inflammation of the gingiva, redness, the presence of gingival enlargement and bleeding (bleeding on probing) and does not cause attachment loss.<sup>2</sup> Proper treatment of gingivitis, can prevent the occurrence of periodontitis. Therefore, an effective prevention of the progression of periodontitis is more important than treating it because of the irreversible nature of periodontitis and has a broad impact of exudate and reversible when etiologic factors are removed.<sup>3</sup> Periodontal tissues that have been damaged, difficult to regenerate, even tend to be irreversible. It is therefore necessary early prevention of the onset of periodontitis, especially in tissues that have been exposed to gingivitis by maintaining the primary defenses of the gingival epithelium

Various efforts have been made in the treatment of periodontitis, among others by the use of local or systemic antibiotics, periodontal surgery, but the results are still less satisfactory. One of the effective and efficient efforts by utilizing the plant nutritious plant extracts. One of the plant extract is efficacious as a drug that is turmeric (*Curcuma longa*). The main active ingredient of turmeric is curcuminoid. The main content of curcuminoid from turmeric is curcumin, which is the most active ingredient.<sup>4</sup> Various studies have shown that curcumin has antioxidant, anti-inflammatory, and anti-cancer properties.<sup>5,6</sup> The role of 1% curcumin as subgingival irrigation can lead to a decrease in gingival inflammation with bleeding on probing indicators.<sup>7</sup>

The fact that prevalence periodontitis in remains high, the ideal strategy for reducing its prevalence is with prevention. In theory, the defect of gingival epithelial occurs due to invasion of bacteria, causing inflammation, so one of the prevention efforts by giving anti-inflammation, one of the alternatives is the plant nutritious plant extract. Curcumin is a medicinal plant material that has anti-inflammatory properties,

as a factor inhibiting transcription factor for NF- $\kappa$ B.<sup>4</sup> Barriers to NF- $\kappa$ B are expected to decrease the expression of pro-inflammatory mediators that contribute to damage to the gingival epithelial defenses in cases of gingivitis. With efforts to prevent the occurrence of periodontitis in cases of gingivitis, it is expected cases of periodontitis decreased more, and cases of gingivitis can become a reversible healthy. This thought arises because the defective process of gingival epithelial defenses occurs in the inflammatory process. It is therefore suspected that inflammatory mediators associated with periodontitis, PGE<sub>2</sub> may also play an important role in the mechanism of damage to the gingival epithelial defect which may result in the breakdown of deeper periodontal tissues.

#### **Materials and methods**

This study was an experimental study in vivo using a 20-week-old white rats (*Rattus norvegicus*) male, weighing 325-350 grams, was obtained from the Biochemistry Laboratory of the Faculty of Medicine, Airlangga University, Surabaya. The research design used is randomized control design. This study received ethical approval from The Ethical Committee of Dental Research Airlangga University 2017. Animals were divided into 4 groups: group K (n = 5) control group without treatment, sacrificed on the first day. Animal model gingivitis without treatment group K1 (n = 5) was sacrificed on the first day, group K2 (n = 5) was sacrificed on day 7, group K3 (n = 5) was sacrificed on day 14 and group K4 (n = 5) with the provision of corn oil as a curcumin carrier sacrificed on day 14. Animal model gingivitis with treatment of curcumin, group P1 (n = 5) sacrificed on the first day, group P2 (n = 5) sacrificed on day 7, group P3 (n = 5) was sacrificed on the 14th day. Curcumin is obtained from Tokyo Chemical Industry, purity is 95%. Preparation of 1% curcumin solution using curcumin in powder form which has been standardized and certified, using solvent

corn oil as a carrier, curcumin powder weight 1 gram then dissolved in corn oil until 100 ml. Gingival epithelial tissue was taken for immunohistochemical procedures to determine the expression of PGE2.

Animal production of gingivitis, performed by induction of LPS *P.gingivalis*, injected into the gingival sulcus of the mandibular incisor proximal portion. Each experimental animal injected by LPS *P.gingivalis* with volume 10  $\mu$ l and concentration 1 mg/ml with syringe tuberculin 1 cc/ml (terumo) and needle 30 G (BD).<sup>8,9</sup> Consecutive days and since 48 hours of injection of LPS *P.gingivalis*, curcumin is given.<sup>10</sup> Curcumin active ingredients derived from turmeric rhizome (*Curcuma longa*) in the form of certified powder, from Tokyo Chemical Industry. Curcumin is made in concentrations of 1% in corn oil, administered 0.03 ml (30  $\mu$ l), twice daily for 2 weeks, topically on the gingival sulcus of the mandibular incisor proximal portion.

Immunohistochemical staining used in this study was for the examination of PGE2 expression from gingival tissues of the mandibular incisor. The primary antibodies PGE2 were purchased from Biossantibodies (bs-2639R-HRP). Histologic samples of the gingival epithelium performed immunohistochemical tests for PGE2. Statistical analyses were performed using SPSS software version 21. All data were expressed as mean  $\pm$  standard deviation (SD). Differences between experimental groups were analyzed with ANOVA. A *p* value <0.05 was considered statistically significant.

## RESULTS

PGE2 expression in response to LPS *P. gingivalis* stimulation and with the curcumin administration, determination by immunohistochemical examination

procedured in gingival epithelial. Based on immunohistochemical examination, increased expression of PGE2 after treatment of LPS P. gingivalis.

Immunohistochemical measurement of PGE2 showed the following results:

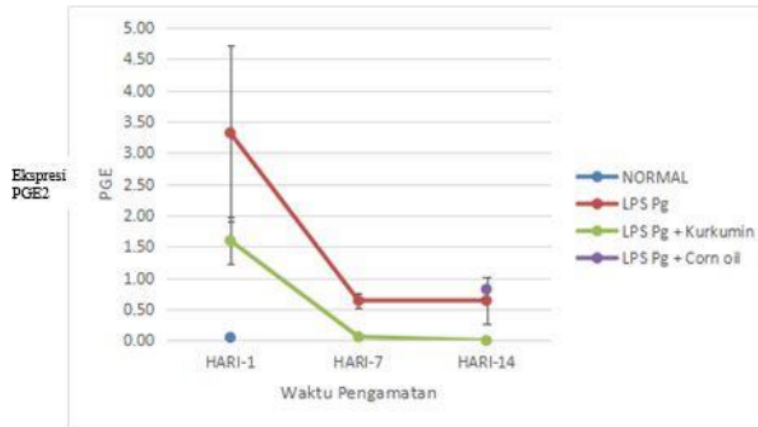


Figure 1. Increased PGE2 expression in LPS Pg treatment group on day 1 and day 7 then decreased at day 14 (red line). Compared with the gray line showing decreased PGE2 expression in the LPS Pg + curcumin treatment group on days 1, 7 and 14. Blue dots showed PGE2 expression in the control group.

Furthermore, the results of ANAVA test comparing between group, PGE2 expressions demonstrated  $p < 0.05$  indicating that significant difference.

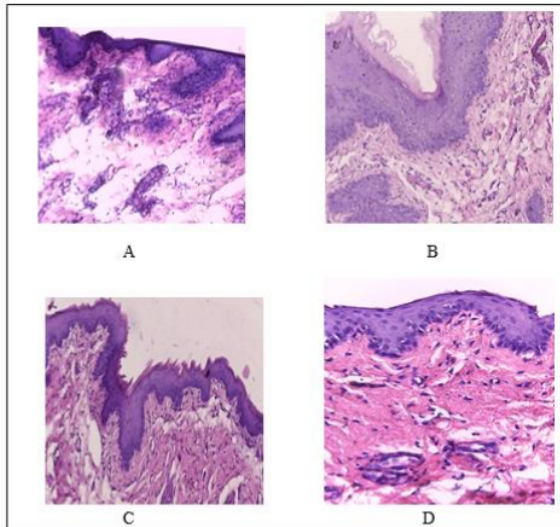


Figure 2. Histological compared to **a**: normal appearance in the control group (Original magnification,  $\times 400$ ), epithelial cells and few inflammatory cells **b**: Moderate inflammation histological appearance in the LPS Pg group. **c**: Severe inflammation histological appearance in the LPS Pg group. **d**: Mild inflammation histological appearance in the LPS Pg group administered curcumin

**Immunohistochemical staining PGE<sub>2</sub> in the gingiva epithelial after injection LPS P gingivalis administered curcumin.**

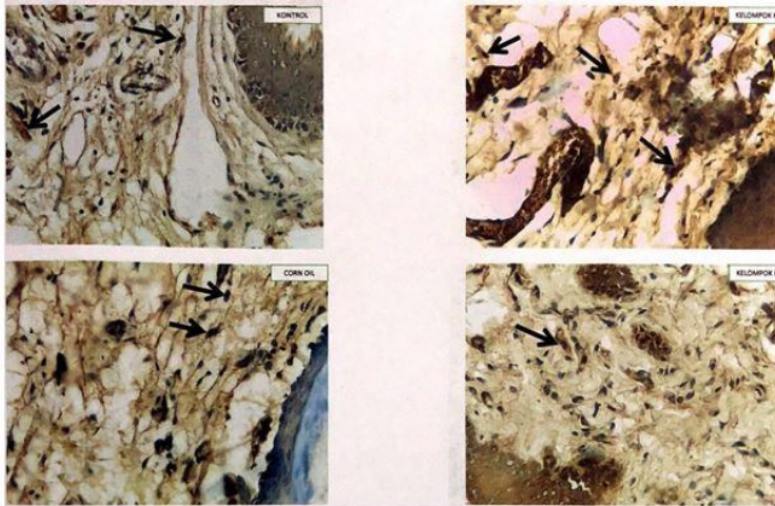


Figure 3. Immunohistochemical staining PGE<sub>2</sub> in the gingiva epithelial after injection LPS Pg administered curcumin. PGE<sub>2</sub> expression in control group (A), in LPS Pg group (B), in LPS Pg and administered curcumin (C), and in corn oil LPS Pg group (D)

## DISCUSSION

In the present study, we analysed NF- $\kappa$ B and MMP-7 expression in the gingiva epithelial of the anterior lower incisor after injection LPS P gingivalis. Porphyromonas gingivalis is an anaerobic gram-negative bacteria that is involved in the pathogenesis of periodontitis. Lipopolysaccharide from Porphyromonas gingivalis is the key leading cause of periodontitis.<sup>11</sup> LPS is a bioactive component and can induce IL-1 and mononuclear cell immunoregulation in multiple doses of pg / ml.<sup>12</sup>

All of the animals in the positive (LPS Pg) group showed macroscopic signs of inflammation, which was confirmed by histological examination. These findings are

consistent with those of the study by Dumitrescu *et al*, 2004.<sup>13</sup> Several studies have used LPS to induce periodontal inflammation in rats.<sup>14</sup> Topical application of LPS results in typical inflammatory changes such as junctional epithelial disruption, infiltration of leukocytes and oedema of the subepithelial connective tissue. We found that the expression of NF- $\kappa$ B and MMP-7 in the positive (LPS Pg) group were higher than those in the negative group. We also found NF- $\kappa$ B and MMP-7 levels in the LPS Pg group were higher than the treatment group of LPS Pg given curcumin. Similarly, Araghizadeh *et al*, found that the levels of IL-1 $\beta$  and TNF- $\alpha$  in the positive control group were higher than those in the negative control group. Enrico G, *et al* reported increases in LTB<sub>4</sub>, PGE<sub>2</sub>, PGF<sub>2</sub> $\alpha$  and PAF after LPS injection.<sup>15</sup>

LPS serves to integrate bacterial structures and protect bacteria from the system host immune defenses consisting of lipids A, O antigens and oligosaccharides bonded together is the main structure of gram negative bacteria cell wall. Lipid A can trigger an inflammatory response. LPS is endotoxin because LPS binds to the CD14 receptor which is the cell surface receptor on macrophages or monocytes. LPS is able to activate the innate immune system to stimulate Toll-Like Receptor-4 (TLR4) which is a protein on surface cells that can recognize bacterial products.<sup>16</sup>

In periodontal disease the most important pathways include the mitogen activated protein kinase (MAPK) and janus tyrosine kinase-signal transducer and activator of transcription (JAK/STAT).<sup>17</sup> NF- $\kappa$ B was first identified as a transcription factor that binds to a 10 base pairs (bp) DNA element in kappa immunoglobulin light chain enhancer in B cells. The NF- $\kappa$ B family of transcription factors has been shown to be involved in many different pathways and has a central role in regulating the expression of a wide variety of genes that control both innate and adaptive immune responses. NF- $\kappa$ B under normal circumstances is found in inactive form in the



cytoplasm as a p50/p65 heterodimer that binds to the I $\kappa$ B $\alpha$  inhibitor unit. Signals from pathogens will activate complex I $\kappa$ B $\alpha$  kinase so that I $\kappa$ B $\alpha$  is phosphorylated which subsequently undergoes ubiquitination and degrades sub unit by proteasome. This results in increased transcription activity, so that NF- $\kappa$ B expression also increases in the LPS *P.gingivalis* group. Activation of the NF- $\kappa$ B pathway occurs in the presence of many pro inflammatory mediators present in large quantities in tissues with periodontal diseases such as bacterial LPS, TNF- $\alpha$ , IL-1, MMPs, COX-2 and inducible nitric oxide synthase (iNOS).<sup>18</sup> In this study, MMP-7 expression also showed increased in LPS group. This suggests that there is a role of MMP-7 in the gingival epithelium that is inflamed by invading pathogenic bacteria. MMP-7 plays a role in the mucosal immune response and its expression increases rapidly in the attacked epithelium.<sup>19</sup> This increase in MMP-7 expression can be caused by exposure to LPS *P.gingivalis* thus stimulating and activating NF- $\kappa$ B. The activated NF- $\kappa$ B then express MMP-7. The expression of NF- $\kappa$ B and MMP-7 on gingival wistar rats exposed to LPS of *Pg* bacteria in group K without treatment was significantly different from LPS *P.gingivalis* group ;K1, K2, K3, K4, and LPS *P.gingivalis* group administered curcumin ;P1, P2 and P3. When viewed from the average in figure 1 and 2, control group has average NF- $\kappa$ B and MMP-7 expression lowered than LPS *P.gingivalis*. In the LPS *P.gingivalis* group showed higher NF- $\kappa$ B and MMP-7 expression than LPS *P.gingivalis* group with curcumin administration.

Curcumin has anti-inflammatory, anti-microbial, antiviral, anti-fungal, antioxidant and wound healing.<sup>20</sup> 1% curcumin as irrigant showed good results to reduce signs of gingival inflammation (BOP and redness) and improve healing by reducing the depth of residual pockets.<sup>21</sup> Curcumin affects expression of NF- $\kappa$ B and MMP-7 because curcumin inhibits the activation of NF- $\kappa$ B induced by LPS

*P.gingivalis*. Curcumin mainly gives its therapeutic effect by inhibiting the I $\kappa$ B $\alpha$  degradation and subsequently inactivate NF- $\kappa$ B, thus initiating the cascade in inflammation and immunogenic.<sup>22</sup> Curcumin inhibits the phosphorylation of inhibitor factor of I $\kappa$ B kinase so that the NF- $\kappa$ B translocation into the nucleus of the cell is inhibited, which further causes NF- $\kappa$ B activity to decrease and the expression of proinflammatory cytokine also decreased.<sup>23</sup> Barriers to phosphorylation of inhibitor factor I $\kappa$ B kinase in this cytoplasm may occur because curcumin is lipophilic in order to penetrate the cell membrane and reside in the cytoplasm and nucleus.<sup>24</sup> NF- $\kappa$ B activation also determines the activity of MMP-7, it means that when NF- $\kappa$ B activation decreases due to the administration of curcumin, the transcription activity performed by NF- $\kappa$ B to express the MMP-7 gene may also be delayed. In this study, administration of curcumin in wistar rat gingival epithel treated with LPS *P.gingivalis* decreased NF- $\kappa$ B and MMP-7 expression. When NF- $\kappa$ B expression as a transcription factor mediator of inflammation decreases feeding of MMP-7 expression as inflammatory mediator also decreases.

### **Conclusion**

The present investigation showed that expression of MMP-7 and NF- $\kappa$ B on the wistar rat gingival epithelium increased at induction with LPS *P.gingivalis*. This suggests that MMP-7 and NF- $\kappa$ B play an important role in the inflammatory response of inflammatory processes in the gingiva due to invasion of pathogenic bacteria. Administration of curcumin decreased the expression of MMP-7 and NF- $\kappa$ B in the wistar gingival epithelium.

### **Declaration of Interest**

The authors report no conflict of interest and the article is not funded or supported by any research grant.

## References

1. Joshi D, Garg T, Goyal AK & Rath G. Advanced drug delivery approaches against periodontitis. *Drug Delivery*. 2016;23(2):363-77.
2. Yeturu SK, Acharya S, Urala AS, Pentapati KC. Effect of Aloe vera, chlorine dioxide, and chlorhexidine mouth rinses on plaque and gingivitis : A randomized controlled trial. *J Oral Biol Craniofac Res*. 2015;182:1-5.
3. Chapple ILC, Van der Weijden F, Doerfer C. Primary prevention of periodontitis: managing gingivitis. *J Clin Periodontol*. 2015;42 (Suppl.16):S71–S76.
4. Akram M, Uddin S, Ahmed A, Usmanghani K, Hannan A, Mohiuddin E, Asif M. *Curcuma longa* and curcumin: A review article. *J. biol. – plant biol*. 2010;55(2):65–70.
5. Gottumukkala S, Koneru S, Mannem S, and Mandalapu N. Effectiveness of sub gingival irrigation of an indigenous 1% curcumin solution on clinical and microbiological parameters in chronic periodontitis patients: A pilot randomized clinical trial. *Contemp Clin Dent*. 2013;4(2):186–91.
6. Guimarães MR, Coimbra LS, Garcia de Aquino S, Spolidorio LC, Kirkwood KL, Rossa Junior C. Potent anti-inflammatory effects of systemically-administered curcumin modulates periodontal disease in vivo. *Periodontal Res*. 2011;46(2):269–79.
7. Suhag A, Dixit J, Dhan P. Role of Curcumin as a subgingival irrigant : a pilot study. *Quintessence Journals*. 2007;4(2):115-21.
8. Taguchi H, Aono Y, Kawato T, Asano M, Shimizu N and Saigusa T. Intragingival injection of Porphyromonas gingivalis-derived lipopolysaccharide induces a transient increase in gingival tumour necrosis factor- $\alpha$ , but not interleukin-6, in anaesthetised rats. *International Journal of Oral Science*. 2015;7:155–60.
9. Araghizadeh N, Paknejad M, Alaeddini M, Minaii B, Abdollahi M, Khorasanie R. The efficacy and prophylactic characteristics of omega-3 fatty acids in experimental gingivitis in rats. *Iran J Basic Med Sci*. 2014;17:87-92.
10. Chen Y, Wu ZF , and Yang LJ. Influence of Baicalin on Alveolar Bone Resorption in rat Experimental Periodontitis. *Sci Pharm*. 2008;76:689–98.
11. Olsen I, Taubman MA, Singhrao SK. Porphyromonas gingivalis suppresses adaptive immunity in periodontitis, atherosclerosis, and Alzheimer’s disease. *Journal of Oral Microbiology*. 2016;8:1.33029.DOI:10.3402/jom.v8.33029.
12. Dixon DR and Darveau RP. Lipopolysaccharide heterogeneity: innate host responses to bacterial modification of lipid A structure. *J Dent Res*. 2005;84(7):584-95.
13. Dumitrescu AL, El-Aleem A. A model of periodontitis in the rat : effect of lipopolysaccharide on bone resorption, osteoclast activity, and local peptidergic innervation. *J Clin Periodontol*. 2004;31:596–603.
14. Song, B, Zhang Y, Chen L, Zhou T, Huang W, Zhou X, Shao L. The role of Toll-like receptors in periodontitis. *Oral Diseases*. 2016;23(2):168–80.doi:10.1111/odi.12468.

15. Enrico G, Roberta F, Ramona D, Angela M, Giacomo O, Wallace John L, Rosanna D, Salvatore C. Anti-inflammatory effect of ATB-352, a H2S releasing ketoprofen derivative, on lipopolysaccharide-induced periodontitis in rats. *Pharmacological Research*. 2017; <https://doi.org/10.1016/j.phrs.2017.12.022>.
16. KØllgaard T, Enevold C, Bendtzen K, Hansen PR, Givskov M, Holmstrup P, et al. Cholesterol Crystals Enhance TLR2- And TLR4-mediated pro-inflammatory Cytokine responses of monocytes To the proatherogenic oral bacterium *Porphyromonas Gingivalis*. *PLoS ONE*. 2017;12(2):e0172773.doi:10.1371/journal.pone.0172773.
17. Mao C-y, WangY-g , Zhang X, Zheng X-y, Tang T-t, and Lu E-y. Double-edged-sword effect of IL-1B on the osteogenesis of periodontal ligament stem cells via crosstalk between the NF- $\kappa$ B, MAPK and BMP/Smad signaling pathways. *Cell Death and Disease*. 2016;7:e2296; doi:10.1038/cddis.2016.204.
18. Serasanambati M, Chilakapati SR. Function of Nuclear Factor kappa B(NF- $\kappa$ B) in human diseases-A Review. *South Indian Journal Of Biological Sciences*. 2016;2(4); 368-87.
19. Gharib SA, Altemeir WA. Matrix Metalloproteinase-7 Coordinates Airway Epithelial Injury Response and Differentiation of Ciliated Cells. *Am J Respir Cell Mol Biol*. 2013; (48):Iss.3:390-396.
20. Kunnumakkara AB, Bordoloi D, Padmavathi G, Monisha J, Roy NK, Prasad N, Bharat B. Aggarwal. Curcumin, The Golden Nutraceutical: Multitargeting for Multiple Chronic Diseases. *Anti-Inflammation Research Institute, San Diego, California, USA*. 2016; doi:10.1111/bph.13621.
21. Sharma A, Ahlawat B, Sharma S. Turmeric Its Applications in Dentistry. *J.Adv Res Med*. 2016; 3(1):27-30
22. Jagetia GC, Aggarwal BB, "Spicing up" of the immune system by curcumin. *J Clin Immunol*. 2007;(27):1:30.
23. Xie YL, Chu JG, Jian X\_M, Dong JZ, Wang LP, Li GX, Yang NB. Curcumin Attenuates lipopolysaccharide/ D -galactosamine-induced Acute Liver Injury By Activating Nrf2 Nuclear Translocation And Inhibiting NF- $\kappa$ B activation. *Biomedicine and Pharmacotherapy*. 2017;91(7):70-7.
24. Minear S, O'Donnell AF, Ballew A, Giaever G, Nishow C. Curcumin inhibits growth of *saccharomyces cerevisiae* through iron chelation. *Eukaryoticcell*. 2011;11:1574-81.

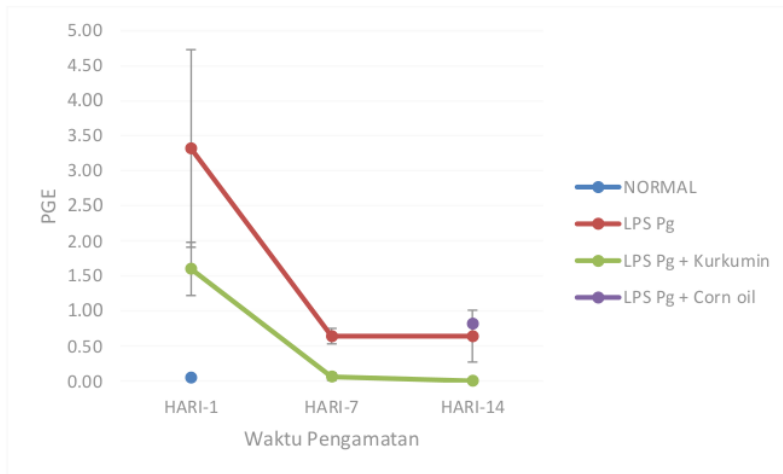


Figure 1. Increased PGE2 expression in LPS Pg treatment group on day 1 and day 7 then decreased at day 14 (red line). Compared with the gray line showing decreased PGE2 expression in the LPS Pg + curcumin treatment group on days 1, 7 and 14. Blue dots showed PGE2 expression in the control group.

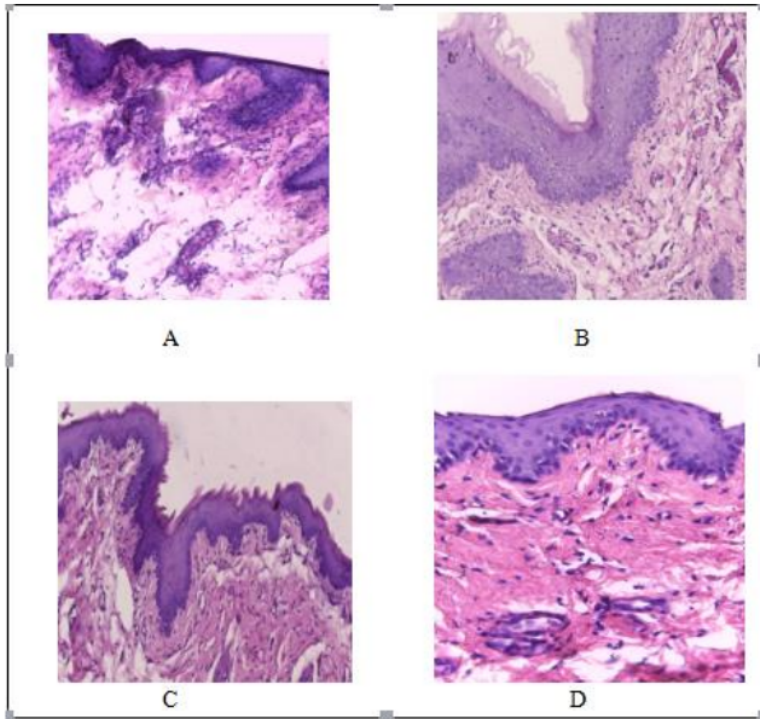


Figure 2. Histological compared to **a**: normal appearance in the control group (Original magnification,  $\times 400$ ), epithelial cells and few inflammatory cells **b**: Moderate inflammation histological appearance in the LPS Pg group. **c**: Severe inflammation histological appearance in the LPS Pg group. **d**: Mild inflammation histological appearance in the LPS Pg group administered curcumin

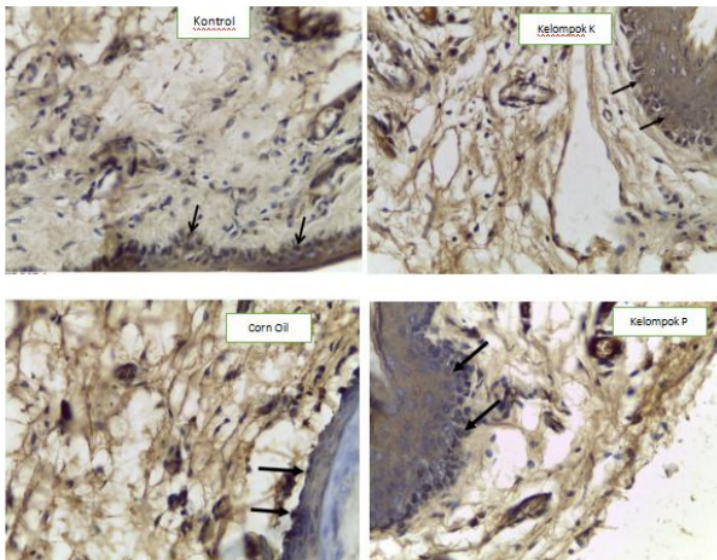


Figure 3. Immunohistochemical staining PGE2 in the gingiva epithelial after injection LPS Pg administered curcumin. PGE2 expression in control group (A), in LPS Pg group (B), in LPS Pg and administered curcumin (C), and in corn oil LPS Pg group (D)

# Expression of PGE2 on defenses of the gingival epithelium injected LPS Porphyromonas gingivalis with the administration of curcumin

## ORIGINALITY REPORT

97%

SIMILARITY INDEX

97%

INTERNET SOURCES

17%

PUBLICATIONS

2%

STUDENT PAPERS

## PRIMARY SOURCES

1

[www.jidmr.com](http://www.jidmr.com)

Internet Source

96%

2

. Justiawan, Dian Agustin Wahjuningrum, Ratna Puspita Hadi, Adienda Pajar Nurhayati, Kevin Prayogo, Riyanto Sigit, Zainal Arief. "

<1%

Comparative Analysis of Color Matching System for Teeth Recognition Using Color Moment

", Medical Devices: Evidence and Research, 2019

Publication

Exclude quotes Off

Exclude matches Off

Exclude bibliography On



# Expression of PGE2 on defenses of the gingival epithelium injected LPS Porphyromonas gingivalis with the administration of curcumin

---

GRADEMARK REPORT

---

FINAL GRADE

**/0**

GENERAL COMMENTS

**Instructor**

---

PAGE 1

---

PAGE 2

---

PAGE 3

---

PAGE 4

---

PAGE 5

---

PAGE 6

---

PAGE 7

---

PAGE 8

---

PAGE 9

---

PAGE 10

---

PAGE 11

---

PAGE 12

---

PAGE 13

---

PAGE 14

---