

# Effect of Lipopolysaccharide- Induced Apica

*by Widya Saraswati*

---

**Submission date:** 06-Apr-2023 04:47PM (UTC+0800)

**Submission ID:** 2057414330

**File name:** ontitis\_in\_Diabetes\_Mellitus\_Rats\_on\_Periapical\_Inflammation.pdf (1.33M)

**Word count:** 5162

**Character count:** 28907



# Effect of Lipopolysaccharide-Induced Apical Periodontitis in Diabetes Mellitus Rats on Periapical Inflammation

Eric Priyo Prasetyo<sup>1</sup> Galih Sampoerno<sup>1</sup> Devi Eka Juniarti<sup>1</sup> Febriastuti Cahyani<sup>1</sup> Widya Saraswati<sup>1</sup>  
Mefina Kuntjoro<sup>2</sup> Evelyn Tjendronegoro<sup>3</sup>

<sup>1</sup> Department of Conservative Dentistry, Faculty of Dental Medicine, Universitas Airlangga, Surabaya, Indonesia

<sup>2</sup> Department of Prosthodontics, Faculty of Dental Medicine, Universitas Airlangga, Surabaya, Indonesia

<sup>3</sup> Healthcare and Research, Irvine Medical Center, University of California, Irvine, California, United States

<sup>8</sup> Address for correspondence Eric Priyo Prasetyo, Department of Conservative Dentistry, Faculty of Dental Medicine, Universitas Airlangga, Jalan Mayjen Prof. Dr. Moestopo 47, Surabaya, Indonesia. ☎ +62 31 5030255 (e-mail: eric-p-p@fkg.unair.ac.id).

Eur J Dent

## Abstract

**Objectives** To evaluate periapical inflammation through immunohistochemical analysis of interleukin 6 (IL-6) and tumor necrosis factor  $\alpha$  (TNF- $\alpha$ ) expression resulting from lipopolysaccharide (LPS)-induced apical periodontitis in diabetes mellitus rats, observed at 14, 28, and 42 days.

**Materials and Methods** Diabetes model on rats was induced by streptozotocin (STZ). Fifteen rats were injected with low-dose STZ for 5 days and waited for 5 days until the blood glucose level was stable and measured above 300 mg/dL confirmed by a digital glucometer. LPS was used to induce apical periodontitis. After performing access cavity, pulpal and root canal extirpation was done on the right mandibular first molar's root canal space of rats, under anesthesia. LPS of 1 mg/mL dose was induced in the pulpal and root canal space. Apical periodontitis was expected 14 days afterward and then, the rats were randomly allocated to three groups. The first group was terminated 14 days after induction and used as control. The second group was observed 28 days after induction, and the third group was observed 42 days after induction. IL-6 and TNF- $\alpha$  expression was analyzed by immunohistochemistry on macrophages in the periapical area.

**Statistical Analysis** Data were analyzed using one-way ANOVA and continued with the post hoc Tukey HSD test. Significance was considered if  $p < 0.05$ .

**Results** LPS induced apical periodontitis in diabetes mellitus rats at control (14 days), 28 and 42 days observation showed a significant increase in the expression of IL-6 and TNF- $\alpha$ . There were significant differences between the control and observed groups ( $p < 0.05$ ). The expression of IL-6 in the apical area was not significant at 14 and 28 days ( $p > 0.05$ ) but increased significantly at 42 days ( $p < 0.05$ ). The expression of TNF- $\alpha$  in the apical area was significantly increased after 14 days ( $p < 0.05$ ) and remained stable at 28 and 42 days ( $p > 0.05$ ).

## Keywords

- ▶ diabetes mellitus
- ▶ lipopolysaccharide
- ▶ apical periodontitis
- ▶ inflammation
- ▶ interleukin-6
- ▶ tumor necrosis factor- $\alpha$

DOI <https://doi.org/10.1055/s-0042-1758790>.  
ISSN 1305-7456.

© 2023. The Author(s).

This is an open access article published by Thieme under the terms of the Creative Commons Attribution License, permitting unrestricted use, distribution, and reproduction so long as the original work is properly cited. (<https://creativecommons.org/licenses/by/4.0/>)  
Thieme Medical and Scientific Publishers Pvt. Ltd., A-12, 2nd Floor, Sector 2, Noida-201301 UP, India

1 **Conclusions** The periapical inflammation of LPS-induced apical periodontitis in diabetes mellitus rats increased macrophages' expression of IL-6 at 42 days and TNF- $\alpha$  at 28 days.

## Introduction

Diabetes mellitus is a worldwide issue<sup>23</sup> affecting the young, adolescents, adults, and elderly. It is a chronic metabolic disease characterized by hyperglycemia caused by lack of insulin<sup>57</sup> production, responsiveness, or both and the number of people suffering from this degenerative disease is expected to increase to more than 600 million world population by 2040.<sup>1</sup> Persistent and untreated hyperglycemia may lead to diabetic vascular complications involving macro and micro vasculatures through many structural and metabolic changes including in the oral tissues.<sup>2</sup> Poor metabolic control in hyperglycemia will increase the risk of dental complications in the oral cavity such as tooth decay, tooth loss, periodontal problems, pulp necrosis, and apical periodontitis.<sup>3,4</sup>

Apical periodontitis is an inflammatory condition in the periapical area, causing tissue inflammation, destruction, and resorption.<sup>5</sup> This condition damages the tissues in the periapical area and involves systemic host factors including the production of inflammatory mediators.<sup>6</sup> Inflammatory mediators are closely related to involved microorganisms. One of many microorganisms responsible for periodontitis, periapical lesions, and endodontic treatment failures is *Porphyromonas gingivalis*.<sup>7,8</sup> *Porphyromonas gingivalis* is a gram-negative bacterium that has lipopolysaccharide (LPS) in its outer membrane. LPS is an endotoxin with a rigorous effect on periodontal tissue destruction and inflammation, including the induction of pro-inflammatory mediators.<sup>9,10</sup>

Systemic inflammatory mediators focused on in this study are tumor necrosis factor- $\alpha$  (TNF- $\alpha$ ) and interleukin-6 (IL-6). IL-6 and TNF- $\alpha$  are important targets for an effective treatment strategy for their potency in periodontal destruction and erosion.<sup>11</sup> These mediators in hyperglycemic conditions are responsible for heightened levels of chronic inflammation, delayed apical tissue healing and increased bone destruction.<sup>12</sup> IL-6 and TNF- $\alpha$  as pro-inflammatory cytokines can directly stimulate osteoclastogenesis, stimulate RANKL production, and act synergistically with RANKL to cause bone resorption.<sup>13</sup> In diabetes mellitus, the elevated amount of circulating IL-6 and TNF- $\alpha$  may impair glycemic control in association with endodontic inflammatory reaction.<sup>14</sup>

Diabetes mellitus increases the severity and risk of inflammatory periodontal disease<sup>4</sup> and both diseases have a bidirectional relationship.<sup>15</sup> Local infections in the oral cavity are also related to systemic conditions, target macrophages and neutrophils, and activate TNF- $\alpha$ , IL-6, other interleukins,  $\alpha$ -interferon, prostaglandins, and the complement system.<sup>16</sup> In the process of apical periodontitis and bone loss in diabetic subjects, polymorphonuclear neutrophils and macrophages are prominent cells in the regulation of inflammation and bone destruction, including the secre-

tion of pro-inflammatory cytokines leading to bone resorption.<sup>17</sup> Inflammatory profile of apical periodontitis is still not completely understood as the process is dynamic involving different inflammatory cells and their by-products which are interrelated.<sup>18</sup>

Many studies use open-pulp methods to allow many bacteria to produce apical periodontitis, but this would lead to the vast destruction of rat teeth as teeth in subjects with diabetes mellitus are prone to decay. Previous studies have conducted various time range for observation from days to weeks. In this study, we investigated whether *P. gingivalis* LPS induction may produce apical periodontitis and evaluated the changes in IL-6 and TNF- $\alpha$  expression on macrophages after 14, 28, and 42 days in a diabetes mellitus rat model.

## Materials and Methods

### Animals

All experimental procedures were approved by the Health Ethics Commissions for Animal Studies, Faculty of Dental Medicine, Universitas Airlangga (approval number 040/2022). Fifteen healthy adult (10–12 weeks) male rats (*Rattus norvegicus*, Wistar strain) weighing 250 to 300 g were used in this study. The animals were randomly divided into three groups with five rats each, with three experimental groups. The rats were cared for in diurnal lighting conditions (12 hours light/dark cycle) with a constant temperature of 25°C, and relative humidity of 45 to 55%. Rats have free access to food and water ad libitum.

### Diabetes Mellitus Model by Streptozotocin Induction

Accu-Chek Digital blood glucometer (Roche, Germany) was used to measure rats' blood glucose levels before, during, and 5 days after the last STZ injections. Streptozotocin (STZ) was purchased from Bio-World (USA). Diabetes mellitus induction by multiple low-dose STZ was according to a previously published method with modification on the dose of STZ and glucose solution.<sup>19</sup>

Rats were fasted for 6 hours before daily STZ low-dose injection intraperitoneally (20 mg/kg body weight) for 5 days consecutively. After every STZ injection, a 5% glucose solution (Otsuka, Indonesia) was given to the rats for 24 hours. Confirmation of successful diabetes model was done 1 week after STZ injection by measuring fasting blood glucose level of > 300 mg/dL. The blood glucose level of each rat was recorded.

### Apical Periodontitis Model by Lipopolysaccharide Induction

After diabetes mellitus induction on the rats was confirmed successful (blood glucose level > 300 mg/dL), LPS induction for the apical periodontitis model was performed in the

following week. Ultrapure LPS from *P. gingivalis* was purchased (Invitrogen, USA) and mixing was done as per the manufacturer's instruction to obtain a concentration of 1 mg/mL.

Adult rats weighing 250 to 300 g were subjected to anesthesia with ketamine 40 mg/kg (Kepro B.V., The Netherlands) and xylazine 5 mg/kg (Xyla Interchemie, The Netherlands) by intraperitoneal injection. The involved right mandibular teeth and gingival areas were swabbed with Consepis (Ultradent, USA). The <sup>56</sup>mandibular right first molar was prepared using a dental <sup>56</sup>handpiece (NSK, Japan) with <sup>56</sup>round diamond bur no. 1/4 (Intensiv SA, Switzerland), access cavity, and pulpectomy were done using a barbed brooch (Dentsply, USA). Root canal preparation was done with K-file numbers 6, 8, 10, and 15 (Dentsply, USA). An electronic apical locator was used (Dentsply, USA) to assist with the preparation. Sterile saline (Otsuka, East Java, Indonesia) irrigation was done following <sup>44</sup>root canal preparation using Navi-tips (Ultradent, USA). <sup>44</sup>Root canals were dried with sterile paper point number 15 (Dentsply, USA). Prepared 1 mg/mL LPS was injected into the root canal space 25 microliters using a Hamilton microliter syringe (Hamilton, USA). The coronal was sealed with Cention glass ionomer (Ivoclar-Vivadent, Liechtenstein) to prevent contamination into the root canals.

The rats were terminated after 14 days, 28, and <sup>22</sup>42 days after induction of LPS by anesthetic overdose with <sup>22</sup>ketamine 300 mg/kg and <sup>22</sup>xylazine 30 mg/kg intraperitoneal injection according to the AVMA-recommended <sup>22</sup>guidelines on euthanasia. The mandibles were dissected and immersed in 10% paraformaldehyde solution.

### Histopathological and Immunohistochemical Analyses

All samples were decalcified with a 5.0% <sup>35</sup>aqueous solution of <sup>35</sup>ethylene diamine tetra acetic acid (EDTA) for 90 days, embedded in paraffin blocks, and sliced by microtome at 5 µm thickness following standard histological protocol. Hematoxylin and eosin (HE) staining was used for histopathological examination. Sections containing treated teeth with apical periodontitis were focused on for consideration.

Immunohistochemical (IHC) staining was performed using monoclonal primary antibody anti-IL-6 (ABIN6002527, anti-

bodies-online, Germany) and anti-TNF-α (ABIN3023860, antibodies-online, Germany) to assess macrophage expression. Macrophages were counted in the periapical region. Histopathological and immunohistochemical specimens were analyzed microscopically using a light microscope Nikon Eclipse Ci-E (Nikon Corp, Japan) focusing in the periapical area of apical periodontitis. <sup>3</sup>Expression of IL-6 and TNF-α of macrophages was counted from IHC-stained specimens at 400× magnification.

### Data Analysis

All data were computed and are expressed as mean ± standard <sup>52</sup>deviation. Statistical analysis was processed for normality using the Shapiro-Wilk test and homogeneity using the <sup>6</sup>Levene test. Data were evaluated using a one-way <sup>21</sup>analysis of variance (ANOVA) test followed by a Tukey honest significant difference (HSD) test between the groups. A <sup>21</sup>p-value of less than 0.05 was considered statistically significant.

### Results

#### Blood Glucose Level

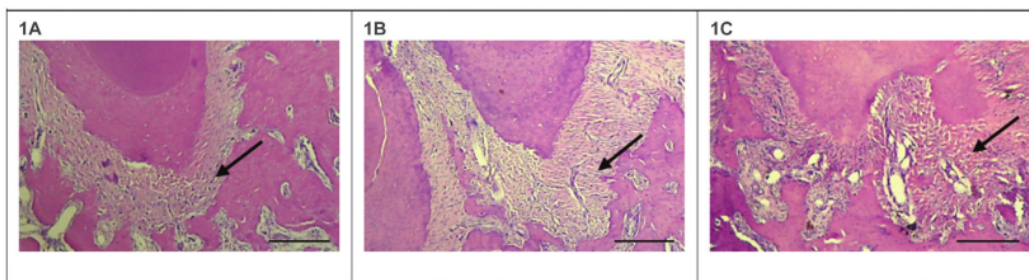
Before STZ treatment, the <sup>60</sup>blood glucose level of each rat was measured as normal (70–130 mg/dL). During STZ treatment, the blood glucose level rises variably (140–310 mg/dL), and after the completion of 5 days of injections, the blood glucose level was stable at 300 to 490 mg/dL. The level remains stable after 5 days from the last injection. All 15 animals survived multiple low doses of given STZ induction.

#### Apical Periodontitis Induction

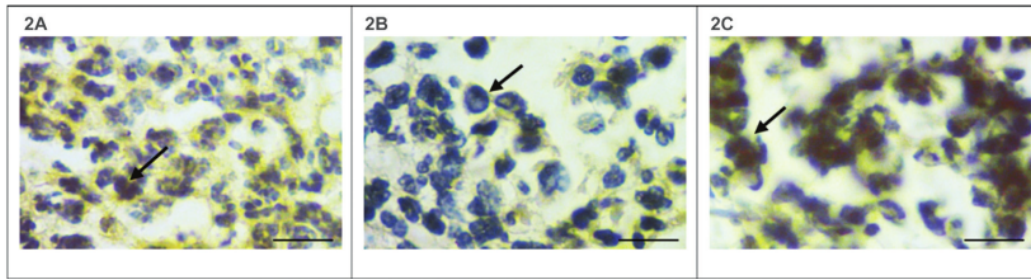
Ultrapure *P. gingivalis* LPS induction resulted in the formation of apical periodontitis in the periapical area. The histopathological examination of induced apical periodontitis can be seen in <sup>7</sup>Fig. 1. The images were obtained from a light microscope (Nikon Eclipse Ci-E, Japan) with 40× magnification.

#### Inflammation in the Apical Area

Expression of IL-6 and TNF-α on macrophages in the <sup>7</sup>periapical area was analyzed by immunohistochemical staining



**Fig. 1** Histopathological examination in the apical area (indicated by black arrows) of LPS-induced AP in DM rats. Scale bar: 200 µm. 1A showing apical periodontitis at control, 1B showing apical periodontitis at 28 days of observation, and 1C showing apical periodontitis at 42 days of observation. Compared with the control group, apical periodontitis at 28 days and 42 days were larger in size. The structure of apical periodontal tissues at 42 days showed the most irregularity.



**Fig. 2** Immunohistochemistry examination of IL-6 expression on macrophages (indicated by black arrows) in the apical area of LPS-induced AP in DM rats. 2A showing the expression of IL-6 at control, 2B showing the expression of IL-6 at 28 days of observation, and 2C showing the expression of IL-6 at 42 days of observation.

(~Figs. 2 and 3). The images were obtained from a light microscope (Nikon Eclipse Ci-E, Japan) with 400× magnification. Inflammatory cells were found around the periapical area. The comparison of IL-6 and TNF- $\alpha$  expression between groups can be seen in Tables 1 and 2. Significances were found in both groups of IL-6 and TNF- $\alpha$ . IL-6 expression was significantly increased at 42 days, while TNF- $\alpha$  expression was significantly increased at 28 days and remained stable at 42 days compared with the control group.

## Discussion

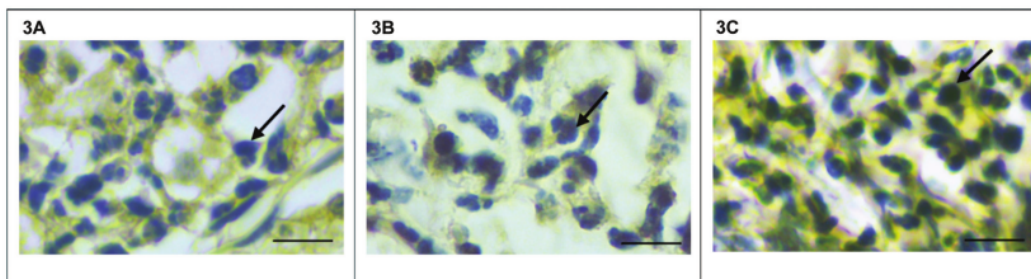
The model to evaluate diabetes mellitus and apical periodontitis in rats is well established.<sup>19</sup> STZ is the agent of choice for reproducible diabetes mellitus induction in an animal model, and the metabolism resulting in rats is very similar to the metabolism in humans.<sup>20</sup> Previous studies have shown that the process of periapical tissue is similar to that observed in humans. Root development is complete in 16 weeks old rat molars, and the similarity of histological features in rat teeth benefits the use of rats in our study. Several studies have experimented the induced apical periodontitis by pulp exposure to infection from oral microorganisms.<sup>21</sup>

Our study provided a detailed model of using LPS to induce apical periodontitis in diabetes mellitus rats. LPS, an endotoxin of *P. gingivalis*, gram-negative bacteria, when in contact with host cells induces an immune-inflammatory reaction, at a certain concentration would develop tissue

damage.<sup>22</sup> In this study, access opening and closed induction of LPS was chosen to preserve tooth structure, as the open method will result in faster tooth decay and deteriorate tooth structure, especially in the diabetes mellitus model in which the tooth structure is prone to decay and have high caries risk.<sup>1</sup>

LPS as endotoxin binds to Toll-like receptors 4 (TLR-4) in the host's innate immune system and activates nuclear factor kappa B (NF $\kappa$ B) to trigger the release of pro-inflammatory cytokines.<sup>16</sup> Inflammatory conditions in periapical region can be determined by the expression of IL-6 and TNF- $\alpha$ . As dominant inflammatory cells in chronic periodontitis, macrophages (M1) express and secrete a range of pro-inflammatory mediators such as IL-6 and TNF- $\alpha$ , which reduce insulin signaling and contribute to insulin resistance and affect the balance between M1 and M2 macrophages to determine the inflammatory effect.<sup>23</sup> Previous studies have demonstrated that macrophages abundantly play a crucial role in apical periodontitis development involving their activation and migration.<sup>24</sup>

Diabetes condition increases inflammation, this is accordance with our study, which showed an increase in the expression of IL-6 and TNF- $\alpha$  in inflammatory cells. This inflammation is suggested to be triggered by oxidative stress, including the increased levels of advanced glycation end-products (AGEs) as a result of prolonged hyperglycemia, and eventually further activate pro-inflammatory pathways and may cause epigenetic changes of persistent expression of



**Fig. 3** Immunohistochemistry examination of TNF- $\alpha$  expression on macrophages (indicated by black arrows) in the apical area of LPS-induced AP in DM rats. 3A showing the expression of TNF- $\alpha$  at control, 3B showing the expression of TNF- $\alpha$  at 28 days of observation, 3C showing the expression of TNF- $\alpha$  at 42 days of observation.

55 Table 1 Mean and standard deviation of IL-6 and TNF-α expressions among groups

Groups	n	IL-6 expression (mean ± SD)		TNF-α expression (mean ± SD)	
Control	5	5.800 ± 1.114	p = 0.034*	6.160 ± 1.161	p = 0.001*
28 days	5	6.920 ± 0.610		8.880 ± 0.867	
42 days	5	7.960 ± 1.493		9.320 ± 0.996	

\*Significant difference.

3 Table 2 Significance of IL-6 and TNF-α expression among groups

Comparisons	IL-6 expression (p-value)	TNF-α expression (p-value)
Control to 28 days	p = 0.297	p = 0.003*
Control to 42 days	p = 0.027*	p = 0.001*
28 days to 42 days	p = 0.346	p = 0.776

\*Significant difference.

proinflammatory genes even after the hyperglycemia is controlled.<sup>23</sup> In this case, epigenetic involvement is related to the persistence of apical periodontitis.

IL-6 is synthesized at low levels in healthy periapical tissues but might be drastically upregulated during periapical inflammation.<sup>25</sup> High expression of IL-6 in apical periodontitis is correlated with active symptomatic lesions, but the relation to systemic inflammatory condition showed conflicting results.<sup>18</sup> IL-6 is a key cytokine expressed and released by several inflammatory cells, including macrophages, associated with bone resorption and host defenses.<sup>26</sup> Higher IL-6 level is positively associated with the size of the lesion, while higher TNF-α level is associated with exudation.<sup>27</sup>

In our study, IL-6 expression is gradually increased and statistically significant between control and day 42, indicating greater macrophage presence in the periapical area over a longer time, but the increase is not significant between control to 28 days and 28 to 42 days. This showed the diabetes mellitus condition delayed the healing process of apical periodontitis resulting from closed induction of LPS. IL-6 is important in immune responses, expressed during inflammation, after TNF-α to play a protective role in immune reactions and bone resorption.<sup>28</sup> IL-6 is induced by TNF-α and IL-1 during the early stages of inflammation, promoting inflammatory cell recruitment, moving from acute to chronic stage, inducing the expression of matrix metalloproteinase, and stimulating osteoclast differentiation and bone resorption.<sup>25</sup> Other possible factors to consider about the increase of IL-6 at 42 days and TNF-α at 28 days are the interaction or homeostasis of cytokines and chemokines during periodontitis state,<sup>29</sup> such as IL-1a, IL-1b, IL-1ra, IL-4, IL-10, IL-12, and IL-17, and this process could be imbalanced or disturbed in diabetes mellitus condition. In humans, higher levels of IL-6 were significantly found in symptomatic apical periodontitis compared with asymptomatic apical

periodontitis, representing an active process immunologically.<sup>13</sup>

TNF-α is strongly correlated to the incidence and exacerbation of periodontitis in diabetes mellitus.<sup>30</sup> TNF-α is a major cytokine released by activated macrophages, monocytes, and T lymphocytes which affect growth regulation, immune response, survival, differentiation, and physiological functions of different cells together with the production of other enzymes, mediators, and cytokines. TNF-α production to increase disease progression is triggered by endotoxins.<sup>31</sup> The role of TNF-α expression on bone resorption and exacerbation is established in apical periodontitis.<sup>21</sup> TNF-α is a potent inducer of bone resorption among other cytokines in apical periodontitis.<sup>32</sup> TNF-α interferes with autophagy and modulates pro-inflammatory responses, cell differentiation, proliferation, and death.<sup>31</sup> TNF-α expression is correlated with the amount of macrophages in the surrounding tissues, indicating the production of this cytokine and inflammation status.<sup>18</sup>

TNF-α is expressed from day 7 after pulpal exposure and 13 in days 28 onward, while a positive correlation is found between TNF-α levels and destruction size in rats.<sup>21</sup> Complete healing in the peri-radicular tissue was not resolved in this study. Diabetes mellitus condition remaining in the systemic milieu enables apical periodontitis to persist. This study did not include root canal treatment to study the condition of periapical destruction. The present study showed the presence of periodontal destruction and lower bone density in the periapical region. The constant number of inflammatory cells was related to diabetes mellitus where continuous hyperglycemic condition plays a crucial part in the tissue healing modulation process.

Patients with diabetes and inflammatory stimulation of LPS showed higher levels of IL-6 and TNF-α, and IL-6 levels are strongly correlated with the severity of disease progression.<sup>16</sup> In line with our study results, clinical studies reported significantly higher expression of IL-6 and TNF-α synergistically in periapical lesion progression and stability to stimulate bone resorption and osteoclast differentiation via RANK/RANKL/OPG mechanisms.<sup>33,34</sup> The pattern of tissue destruction in the periapical area of rats over control, 28, and 42 days observation showed diabetes mellitus with hyperglycemia as a stimulus for healing difficulties, increased risk of infection, and reduced recovery is in agreement with our result. Histological observation showed necrotic periapical areas with irregular apical periodontal tissue structure.

Periapical tissue repair is a coordinated process involving highly related events, including cell proliferation and

migration, growth factors, and cytokine release. In the mechanism of apical periodontitis, cytokines are involved, including IL-6 and TNF- $\alpha$  for bone resorption, osteoclast activity, and proinflammatory cytokines. Immune and systemic systems interact with one another, sharing fundamental interactions that are involved in the pathophysiology of periodontal tissue including apical periodontitis. Previous studies presented that the same bacterial stimulus-induced greater inflammation in diabetic animals compared with normal control, and diabetes significantly increase the severity and susceptibility of periodontal disease.<sup>35</sup> Other factors such as stress oxidative parameters are partly responsible for the higher and more aggressive apical periodontitis in diabetes mellitus.<sup>36,37</sup> Further studies should be done to investigate the effects on other inflammatory mechanisms and therapeutic effects. Understanding inflammation is expected to set a basis for further study on endodontic regeneration and treatments in the apical area for subjects with diabetes mellitus.

## Conclusion

Our study demonstrated that LPS from *P. gingivalis* can produce apical periodontitis in diabetes mellitus rats in an *in vivo* model, and affect the expression of IL-6 and TNF- $\alpha$ . Observation times of 28 and 42 days influence the inflammatory status of apical periodontitis, especially in diabetes mellitus condition. The periapical inflammation of LPS-induced apical periodontitis in diabetes mellitus rats increased macrophage expression of IL-6 at 42 days and TNF- $\alpha$  at 28 days. Further studies are important to understand the mechanism of time, diabetes mellitus, apical periodontitis, and other contributing factors, for endodontic treatment and regeneration in the apical area, especially in subjects with diabetes mellitus.

### Authors' Contributions

EPP and ET did the study conception, design, drafting of manuscript and critical revision. FC and WS contributed to the reagents and materials. GS, DEJ and MK acquired data, analyzed and interpreted it. All authors approved the final version of manuscript.

### Conflicts of Interests

None declared.

## References

- Saghiri MA, Aminsobhani M, Gutmann JL, Kawai T, Nath D, Hirschberg C. Effect of diabetes on rotary instrumentation of dentin. *J Endod* 2021;47(08):1301–1307. Doi: 10.1016/j.joen.2021.03.019
- Lima SMF, Grisi DC, Kogawa EM, et al. Diabetes mellitus and inflammatory pulpal and periapical disease: a review. *Int Endod J* 2013;46(08):700–709. Doi: 10.1111/iej.12072
- Yeh CK, Harris SE, Mohan S, et al. Hyperglycemia and xerostomia are key determinants of tooth decay in type 1 diabetic mice. *Lab Invest* 2012;92(06):868–882. Doi: 10.1038/labinvest.2012.60
- Kuntjoro M, Agustono B, Prasetyo EP, Salim S, Rantam FA, Hendrijantini N. The effect of advanced glycation end products (AGEs) on human umbilical cord mesenchymal stem cells (hUCMSCs) with regard to osteogenesis and calcification. *Res J Pharm Tech* 2021;14(08):4019–4. Doi: 10.52711/0974-360X.2021.00696
- Zhang CC, Liu YJ, Yang WD, et al. Morphological changes of the root apex in anterior teeth with periapical periodontitis: an *in vivo* study. *BMC Oral Health* 2022;22(01):31. Doi: 10.1186/s12903-022-02062-z
- Tsai HC, Chen CH, Mochly-Rosen D, Li YE, Chen MH. The role of alcohol, LPS toxicity, and ALDH2 in dental bony defects. *Biomolecules* 2021;11(05):651. Doi: 10.3390/biom11050651
- Prada I, Micó-Muñoz P, Giner-Lluesma T, Micó-Martínez P, Colado-Castellano N, Manzano-Saiz A. Influence of microbiology on endodontic failure. Literature review. *Med Oral Patol Oral Cir Bucal* 2019;24(03):e364–e372. Doi: 10.4317/medoral.22907
- Prasetyo EP, Juniarti DE, Sampoerno G, et al. The antibacterial efficacy of calcium hydroxide-iodophors and calcium hydroxide-barium sulfate root canal dressings on *Enterococcus faecalis* and *Porphyromonas gingivalis* *in vitro*. *Dent J (Maj Ked gigi)* 2022;55(02):62–66. Doi: 10.20473/j.djmg.v55.i2.p62-66
- Nelwan SC, Nugraha RA, Endaryanto A, Retno I. Modulating toll-like receptor-mediated inflammatory responses following exposure of whole cell and lipopolysaccharide component from *Porphyromonas gingivalis* in wistar rat models. *Eur J Dent* 2017;11(04):422–426. Doi: 10.4103/ejd.ejd\_147\_17
- Kuntjoro M, Prasetyo EP, Cahyani F, et al. Lipopolysaccharide's cytotoxicity on human umbilical cord mesenchymal stem cells. *Pesqui Bras Odontopediatria Clin Integr* 2020;20:e0048. Doi: 10.1590/pboci.2020.153
- Ren B, Lu J, Li M, et al. Anti-inflammatory effect of IL-1ra-loaded dextran/PLGA microspheres on *Porphyromonas gingivalis* lipopolysaccharide-stimulated macrophages *in vitro* and *in vivo* in a rat model of periodontitis. *Biomed Pharmacother* 2021;134:111171. Doi: 10.1016/j.biopha.2020.111171
- García-Hernández A, Arzate H, Gil-Chavarría I, Rojo R, Moreno-Fierros L. High glucose concentrations alter the biomineralization process in human osteoblastic cells. *Bone* 2012;50(01):276–288. Doi: 10.1016/j.bone.2011.10.032
- Jakovljevic A, Knezevic A, Karalic D, et al. Pro-inflammatory cytokine levels in human apical periodontitis: Correlation with clinical and histological findings. *Aust Endod J* 2015;41(02):72–77. Doi: 10.1111/aej.12072
- Aminoshariae A, Kulild JC, Mickel A, Fouad AF. Association between systemic diseases and endodontic outcome: a systematic review. *J Endod* 2017;43(04):514–519. Doi: 10.1016/j.joen.2016.11.008
- Anil K, Vadakkekuttal RJ, Radhakrishnan C, Parambath FC. Correlation of periodontal inflamed surface area with glycemic status in controlled and uncontrolled type 2 diabetes mellitus. *World J Clin Cases* 2021;9(36):11300–11310. Doi: 10.12998/wjcc.v9.i36.11300
- Marcano R, Rojo MA, Cordoba-Diaz D, Garrosa M. Pathological and therapeutic approach to endotoxin-secreting bacteria involved in periodontal disease. *Toxins (Basel)* 2021;13(08):533. Doi: 10.3390/toxins.13080533
- Segura-Egea JJ, Castellanos-Cosano L, Machuca G, et al. Diabetes mellitus, periapical inflammation and endodontic treatment outcome. *Med Oral Patol Oral Cir Bucal* 2012;17(02):e356–e361
- Braz-Silva PH, Bergamini ML, Mardegan AP, De Rosa CS, Hasseus B, Jonasson P. Inflammatory profile of chronic apical periodontitis: a literature review. *Acta Odontol Scand* 2019;77(03):173–180. Doi: 10.1080/00016357.2018.1521005
- Furman BL. Streptozotocin-induced diabetic models in mice and rats. *Curr Protoc* 2021;1(04):e78. Doi: 10.1002/cpz1.78
- Cintra LTA, Samuel RO, Azuma MM, et al. Apical periodontitis and periodontal disease increase serum IL-17 levels in normoglycemic and diabetic rats. *Clin Oral Invest* 2014;18(09):2123–2128. Doi: 10.1007/s00784-014-1192-7
- do Nascimento IV, Rodrigues MIQ, Isaias PHC, et al. Chronic systemic corticosteroid therapy influences the development of

- pulp necrosis and experimental apical periodontitis, exacerbating the inflammatory process and bone resorption in rats. *Int Endod J* 2022;55(06):646–659. Doi: 10.1111/iej.13724
- 22 Keong JY, Low LW, Chong JM, et al. Effect of lipopolysaccharide on cell proliferation and vascular endothelial growth factor secretion of periodontal ligament stem cells. *Saudi Dent J* 2020;32(03):148–154. Doi: 10.1016/j.sdentj.2019.08.001
  - 23 Ndip A, Jude EB, Boulton AJM. Inflammation in type 2 diabetes. *Front Inflamm* 2016;1:164–179
  - 24 Hasegawa T, Venkata Suresh V, Yahata Y, et al. Inhibition of the CXCL9-CXCR3 axis suppresses the progression of experimental apical periodontitis by blocking macrophage migration and activation. *Sci Rep* 2021;11(01):2613. Doi: 10.1038/s41598-021-82167-7
  - 25 Garrido M, Dezerega A, Bordagaray MJ, et al. C-reactive protein expression is up-regulated in apical lesions of endodontic origin in association with interleukin-6. *J Endod* 2015;41(04):464–469. Doi: 10.1016/j.joen.2014.12.021
  - 26 Bracks IV, Armada L, Gonçalves LS, Pires FR. Distribution of mast cells and macrophages and expression of interleukin-6 in periapical cysts. *J Endod* 2014;40(01):63–68. Doi: 10.1016/j.joen.2013.09.037
  - 27 Cotti E, Schirru E, Acquas E, Usai P. An overview on biologic medications and their possible role in apical periodontitis. *J Endod* 2014;40(12):1902–1911. Doi: 10.1016/j.joen.2014.08.013
  - 28 Azuma MM, Samuel RO, Gomes-Filho JE, Dezan-Junior E, Cintra LTA. The role of IL-6 on apical periodontitis: a systematic review. *Int Endod J* 2014;47(07):615–621. Doi: 10.1111/iej.12196
  - 29 Ramadan DE, Hariyani N, Indrawati R, Ridwan RD, Diyatri I. Cytokines and Chemokines in periodontitis. *Eur J Dent* 2020;14(03):483–495. Doi: 10.1055/s-0040-1712718
  - 30 Berniyanti T, Wening GRS, Palupi R, Setyowati D, Putri CR. Low levels of tumor necrosis factor- $\alpha$  will prevent periodontitis exacerbation in type 2 diabetes mellitus. *Eur J Dent* 2022;16(02):443–448. Doi: 10.1055/s-0041-1739442
  - 31 Ge Y, Huang M, Yao YM. Autophagy and proinflammatory cytokines: Interactions and clinical implications. *Cytokine Growth Factor Rev* 2018;43:38–46. Doi: 10.1016/j.cytogfr.2018.07.001
  - 32 Márton IJ, Kiss C. Overlapping protective and destructive regulatory pathways in apical periodontitis. *J Endod* 2014;40(02):155–163. Doi: 10.1016/j.joen.2013.10.036
  - 33 Salinas-Muñoz M, Garrido-Flores M, Baeza M, et al. Bone resorptive activity in symptomatic and asymptomatic apical lesions of endodontic origin. *Clin Oral Investig* 2017;21(08):2613–2618. Doi: 10.1007/s00784-017-2062-x
  - 34 Cavalla F, Letra A, Silva RM, Garlet GP. Determinants of periodontal/periapical lesion stability and progression. *J Dent Res* 2021;100(01):29–36. Doi: 10.1177/0022034520952341
  - 35 Xiao E, Mattos M, Vieira GHA, et al. Diabetes enhances IL-17 expression and alters the oral microbiome to increase its pathogenicity. *Cell Host Microbe* 2017;22(01):120–128.e4. Doi: 10.1016/j.chom.2017.06.014
  - 36 Vincent RR, Appukuttan D, Victor DJ, Balasundaram A. Oxidative stress in chronic periodontitis patients with type II diabetes mellitus. *Eur J Dent* 2018;12(02):225–231. Doi: 10.4103/ejd.ejd\_244\_17
  - 37 Prieto AKC, Gomes-Filho JE, Azuma MM, et al. Influence of apical periodontitis on stress oxidative parameters in diabetic rats. *J Endod* 2017;43(10):1651–1656. Doi: 10.1016/j.joen.2017.05.014



# Effect of Lipopolysaccharide-Induced Apica

## ORIGINALITY REPORT

25%

SIMILARITY INDEX

18%

INTERNET SOURCES

19%

PUBLICATIONS

2%

STUDENT PAPERS

## PRIMARY SOURCES

1	<a href="http://www.unboundmedicine.com">www.unboundmedicine.com</a> Internet Source	4%
2	Yessy Ariesanti, Putri Graesya Melani Octavianus, Annisa Tri Handayani, Basril Abbas. "Characterization of Polyvinyl Alcohol–Collagen–Hydroxyapatite Composite Membrane from Lates calcarifer Scales for Guided Tissue and Bone Regeneration", <i>European Journal of Dentistry</i> , 2023 Publication	2%
3	<a href="http://pubmed.ncbi.nlm.nih.gov">pubmed.ncbi.nlm.nih.gov</a> Internet Source	1%
4	Rosalia Marcano, M. Ángeles Rojo, Damián Cordoba-Diaz, Manuel Garrosa. "Pathological and Therapeutic Approach to Endotoxin-Secreting Bacteria Involved in Periodontal Disease", <i>Toxins</i> , 2021 Publication	1%
5	<a href="http://e-journal.unair.ac.id">e-journal.unair.ac.id</a> Internet Source	1%

6	<a href="http://www.nature.com">www.nature.com</a> Internet Source	1 %
7	Guan-Sheng Shang, Lunxu Liu, Yi-Wei Qin. "IL-6 and TNF- $\alpha$ promote metastasis of lung cancer by inducing epithelial-mesenchymal transition", <i>Oncology Letters</i> , 2017 Publication	1 %
8	<a href="http://www.dovepress.com">www.dovepress.com</a> Internet Source	1 %
9	<a href="http://escholarship.org">escholarship.org</a> Internet Source	1 %
10	Irmaleny Irmaleny, Opik Taofik Hidayat, Yolanda Yolanda, Elisabeth Lumban Tobing. "Comparative Evaluation of the Increase in Enamel Hardness Post-External Bleaching after Using Casein Phosphopeptide Amorphous Calcium Phosphate Fluoride (CPP-ACPF) and 5% Sodium Fluoride (NaF) Remineralizing Agents", <i>European Journal of Dentistry</i> , 2023 Publication	1 %
11	<a href="http://jneuroinflammation.biomedcentral.com">jneuroinflammation.biomedcentral.com</a> Internet Source	<1 %
12	E Xiao, Marcelo Mattos, Gustavo Henrique Apolinário Vieira, Shanshan Chen et al. "Diabetes Enhances IL-17 Expression and	<1 %

## Alters the Oral Microbiome to Increase Its Pathogenicity", Cell Host & Microbe, 2017

Publication

---

13

Isabelly Vidal Nascimento, Maria Imaculada de Queiroz Rodrigues, Pedro Henrique Chaves Isaias, Paulo Goberlânio Barros - Silva et al. "Chronic systemic corticosteroid therapy influences the development of pulp necrosis and experimental apical periodontitis, exacerbating the inflammatory process and bone resorption in rats", International Endodontic Journal, 2022

Publication

---

<1 %

14

L. L. Ferreira, J. E. Gomes-Filho, F. Benetti, M. Carminatti, E. Ervolino, A. L. F. Briso, L. T. A. Cintra. "The effect of dental bleaching on pulpal tissue response in a diabetic animal model: a study of immunoregulatory cytokines", International Endodontic Journal, 2018

Publication

---

<1 %

15

Md. Meraj Ansari, Anas Ahmad, Rakesh Kumar Mishra, Syed Shadab Raza, Rehan Khan. "Zinc Gluconate-Loaded Chitosan Nanoparticles Reduce Severity of Collagen-Induced Arthritis in Wistar Rats", ACS Biomaterials Science & Engineering, 2019

Publication

---

<1 %

16

Steven C. Gribar, Chhinder P. Sodhi, Ward M. Richardson, Rahul J. Anand et al. "Reciprocal Expression and Signaling of TLR4 and TLR9 in the Pathogenesis and Treatment of Necrotizing Enterocolitis", *The Journal of Immunology*, 2009

Publication

---

<1 %

17

Aleksandra Kimak, Małgorzata Strycharz-Dudziak, Teresa Bachanek, Elżbieta Kimak. "Lipids and lipoproteins and inflammatory markers in patients with chronic apical periodontitis", *Lipids in Health and Disease*, 2015

Publication

---

<1 %

18

Luciano Tavares Angelo Cintra, Renata Oliveira Samuel, Mariane Maffei Azuma, Clícia Pereira Ribeiro et al. "Apical periodontitis and periodontal disease increase serum IL-17 levels in normoglycemic and diabetic rats", *Clinical Oral Investigations*, 2014

Publication

---

<1 %

19

Armelia Sari Widyarman, Louise Anastasya Halim, Jesslyn, Heidi Amanda Irma, Mario Richi, Muhammad Ihsan Rizal. "The potential of reuterin derived from Indonesian strain of *Lactobacillus reuteri* against endodontic pathogen biofilms in vitro and ex vivo", *The Saudi Dental Journal*, 2023

<1 %

---

20	<a href="https://www.mdpi.com">mdpi.com</a> Internet Source	<1 %
21	<a href="https://journals.plos.org">journals.plos.org</a> Internet Source	<1 %
22	<a href="https://rsdjournal.org">rsdjournal.org</a> Internet Source	<1 %
23	<a href="http://www.spandidos-publications.com">www.spandidos-publications.com</a> Internet Source	<1 %
24	<a href="http://pubs.asahq.org">pubs.asahq.org</a> Internet Source	<1 %
25	<a href="http://www.oalib.com">www.oalib.com</a> Internet Source	<1 %
26	Mefina KUNTJORO, Nike HENDRIJANTINI, Eric Priyo PRASETYO, Djoko LEGOWO et al. "Human umbilical cord mesenchymal stem cells accelerate and increase implant osseointegration in diabetic rats", Journal of Applied Oral Science, 2023 Publication	<1 %
27	Tatsuya Hasegawa, V. Venkata Suresh, Yoshio Yahata, Masato Nakano et al. "Inhibition of the CXCL9-CXCR3 axis suppresses the progression of experimental apical periodontitis by blocking macrophage	<1 %

---

migration and activation", Scientific Reports, 2021

Publication

28

[core.ac.uk](https://www.core.ac.uk)

Internet Source

<1 %

29

A. P. Torres-Monjarás, R. Sánchez-Gutiérrez, B. Hernández-Castro, L. González-Baranda et al. "Bacteria associated with apical periodontitis promotes in vitro the differentiation of macrophages to osteoclasts", Clinical Oral Investigations, 2023

Publication

<1 %

30

Francisco Wanderley Garcia Paula-Silva, Maya Fernanda Manfrin Arnez, Igor Bassi Ferreira Petean, Luciano Aparecido Almeida-Junior et al. "Effects of 5-lipoxygenase gene disruption on inflammation, osteoclastogenesis and bone resorption in polymicrobial apical periodontitis", Archives of Oral Biology, 2020

Publication

<1 %

31

[www.tandfonline.com](https://www.tandfonline.com)

Internet Source

<1 %

32

"Common Complications in Endodontics", Springer Nature, 2018

Publication

<1 %

33

M. Salinas-Muñoz, M. Garrido-Flores, M. Baeza, P. Huamán-Chipana, J. García-Sesnich,

<1 %

R. Bologna, R. Vernal, M. Hernández. "Bone resorptive activity in symptomatic and asymptomatic apical lesions of endodontic origin", Clinical Oral Investigations, 2017  
Publication

---

34

[jnanobiotechnology.biomedcentral.com](http://jnanobiotechnology.biomedcentral.com)

Internet Source

<1 %

---

35

[www.freepatentsonline.com](http://www.freepatentsonline.com)

Internet Source

<1 %

---

36

[www.oncotarget.com](http://www.oncotarget.com)

Internet Source

<1 %

---

37

[www.wjgnet.com](http://www.wjgnet.com)

Internet Source

<1 %

---

38

Andreas Pratama Nugraha, David B. Kamadjaja, Ni Putu Mira Sumarta, Andra Rizqiawan et al. "Osteoinductive and Osteogenic Capacity of Freeze-Dried Bovine Bone Compared to Deproteinized Bovine Bone Mineral Scaffold in Human Umbilical Cord Mesenchymal Stem Cell Culture: An In Vitro Study", European Journal of Dentistry, 2023

Publication

<1 %

---

39

Tanguy Déméautis, Alexandra Bouyssi, Annelise Chapalain, Johann Guillemot et al. "Chronic Exposure to Secondary Organic

<1 %

# Aerosols Causes Lung Tissue Damage", Environmental Science & Technology, 2023

Publication

---

40

Submitted to Universitas Airlangga

Student Paper

<1 %

---

41

advbiores.net

Internet Source

<1 %

---

42

worldwidescience.org

Internet Source

<1 %

---

43

"Endodontic Prognosis", Springer Science and  
Business Media LLC, 2017

Publication

<1 %

---

44

Abdulaziz Bakhsh, David Moyes, Gordon  
Proctor, Francesco Mannocci, Sadia Ambreen  
Niazi. "The impact of apical periodontitis,  
non - surgical root canal retreatment and  
periapical surgery on serum inflammatory  
biomarkers", International Endodontic Journal,  
2022

Publication

<1 %

---

45

Elisabetta Cotti, Kenneth Abramovitch, James  
Jensen, Elia Schirru, Dwight D. Rice,  
Udochukwu Oyoyo, Mahmoud Torabinejad.  
"The Influence of Adalimumab on the Healing  
of Apical Periodontitis in Ferrets", Journal of  
Endodontics, 2017

Publication

<1 %

---



46

Gena D Tribble, Jennifer E Kerr, Bing-Yan Wang. " Genetic diversity in the oral pathogen : molecular mechanisms and biological consequences ", Future Microbiology, 2013

Publication

---

<1 %

47

Jenny Sunariani, Christian Khoswanto, Wahyuning Ratih Irmalia. "Difference of brain-derived neurotrophic factor expression and pyramid cell count during mastication of food with varying hardness", Journal of Applied Oral Science, 2019

Publication

---

<1 %

48

Ketut Suardita, Ira Arundina, Udijanto Tedjosasongko, Anita Yuliati et al. "Concanavalin A Enhanced Proliferation and Osteogenic Differentiation of Dental Pulp Stem Cells", European Journal of Dentistry, 2020

Publication

---

<1 %

49

Mauricio Garrido, Andrea Dezerega, María José Bordagaray, Montserrat Reyes et al. "C-Reactive Protein Expression Is Up-regulated in Apical Lesions of Endodontic Origin in Association with Interleukin-6", Journal of Endodontics, 2015

Publication

---

<1 %

50

Nadja Nikolic, Aleksandar Jakovljevic, Jelena Carkic, Katarina Beljic-Ivanovic et al. "Notch

<1 %

# Signaling Pathway in Apical Periodontitis: Correlation with Bone Resorption Regulators and Proinflammatory Cytokines", Journal of Endodontics, 2018

Publication

---

51	<a href="#">dokumen.pub</a> Internet Source	<1 %
52	<a href="#">jofs.in</a> Internet Source	<1 %
53	<a href="#">link.springer.com</a> Internet Source	<1 %
54	<a href="#">mdpi-res.com</a> Internet Source	<1 %
55	<a href="#">revista.uepb.edu.br</a> Internet Source	<1 %
56	<a href="#">saudiendodj.com</a> Internet Source	<1 %
57	<a href="#">www.mdpi.com</a> Internet Source	<1 %
58	<a href="#">www.omicsonline.org</a> Internet Source	<1 %
59	<a href="#">www.remedypublications.com</a> Internet Source	<1 %
60	"Abstracts", Diabetologia, 1997 Publication	<1 %

---

61

Hebatullah Hussein, Anil Kishen. "Local immunomodulatory effects of intracanal medications in apical periodontitis", *Journal of Endodontics*, 2022

Publication

---

<1 %

62

Nilton Dessaune Neto, Mariana Teixeira Maneschy Porpino, Henrique dos Santos Antunes, Renata Costa Val Rodrigues et al. "Pro-inflammatory and anti-inflammatory cytokine expression in post-treatment apical periodontitis", *Journal of Applied Oral Science*, 2018

Publication

---

<1 %

63

Paulo Henrique Braz-Silva, Mariana Lobo Bergamini, Andressa Pinto Mardegan, Catharina Simioni De Rosa et al. "Inflammatory profile of chronic apical periodontitis: a literature review", *Acta Odontologica Scandinavica*, 2018

Publication

---

<1 %

64

Yingzhi Gu, Xiaozhe Han. "Toll-Like Receptor Signaling and Immune Regulatory Lymphocytes in Periodontal Disease", *International Journal of Molecular Sciences*, 2020

Publication

---

<1 %

---

Exclude quotes      On

Exclude matches      Off

Exclude bibliography      On