

CaCO₃ from Anadara granosa shell as reparative dentin inducer in odontoblast pulp cells: In-vivo study

by Widya Saraswati

Submission date: 08-Apr-2023 05:38PM (UTC+0800)

Submission ID: 2058949366

File name: JOBCR_Anadara_Granosa_2023.pdf (3.68M)

Word count: 3678

Character count: 19924



Contents lists available at ScienceDirect

Journal of Oral Biology and Craniofacial Research

journal homepage: www.elsevier.com/locate/jobcr



CaCO₃ from *Anadara granosa* shell as reparative dentin inducer in odontoblast pulp cells: In-vivo study

Widya Saraswati^{a,*}, Adioro Soetojo^a, Nina Dhaniar^b, Hermawan Adi Praja^b,
Ratih Mahanani Santoso^b, Nadiah Salsabila Nosla^b, Ganiezha Cindananti^b,
Rossabella Vennowusky Rafli^b, Nabiela Rahardia^b

^a Department of Conservative Dentistry, Faculty of Dental Medicine, Universitas Airlangga, Indonesia

^b Faculty of Dental Medicine, Universitas Airlangga, Indonesia

ARTICLE INFO

Keywords:

CaCO₃
Anadara granosa
Reparative dentin
NF-kB
TGF-β1
VEGF-A

ABSTRACT

Introduction: *Anadara granosa* (blood clam) shell contained 98.7% of calcium carbonate (CaCO₃). This material has bio-properties that able to induced the dentin regeneration. This study is expected to reveal the nuclear factor kappa beta (NF-kB), transforming growth factor beta (TGF-β1), and vascular endothelial growth factor A (VEGF-A) expression in dental pulp after application of CaCO₃ from *Anadara granosa* shell

Material and methods: The thirty *Rattus norvegicus* strain Wistar used as model. The maxillary first molar was preparation using 0.84 mm low-speed diamond bur to made cavity. The cavity then applied glass ionomer cement (as control group) and other group applied CaCO₃ from *Anadara granosa* shell. The teeth in each group were extracted after 1st, 3rd and 7th days of application for immunohistochemistry analysis for NF-kB, TGF-β1, and VEGF-A expression.

Result: The NF-kB expression in the group with CaCO₃ from *Anadara granosa* shell lower than control after 1st, 3rd and 7th days (p < 0.05). In other hand, the TGF-β1 and VEGF-A expression in the group with CaCO₃ from *Anadara granosa* shell higher than control after 1st, 3rd and 7th days (p < 0.05).

Conclusion: CaCO₃ from *Anadara granosa* shell able to stimulate the TGF-β1 and VEGF-A and suppress the NF-kB expression in the dental pulp. This material able to develop as dentin-pulp material restoration.

1. Introduction

Pulpitis reversible diagnosis within large caries tooth require dentin-pulp material restoration with anti-inflammatory properties. Pulp capping is one of dentin-pulp material restoration for pulpitis reversible, to maintain the pulp vitality.¹ Calcium hydroxide [Ca(OH)₂] is the gold standard for pulp capping materials or dentin-pulp material restoration. Ca(OH)₂ has mechanism to form a hard tissue in tooth with stimulate the tertiary dentine.² Ca(OH)₂ release the OH⁻ ion which possessed as anti-bacterial.³ The disadvantages of Ca(OH)₂ is easily dissolve and produce a tunnel defect. This process will decrease the tooth vitality and sensitivity of the pulp.⁴

Mechanically injured dentin, will increase the nuclear factor kappa B (NF-kB) and stimulate the production of pro-inflammatory cytokines such as interleukin 1β (IL-1β). If not treated, this condition can cause persistent inflammation in the dental pulp.⁵ Acute inflammation is a

necessary part of the healing process, but if it isn't managed appropriately, it can turn into chronic inflammation. The marker of inflammation was activation of NF-kB, it will express after injury and maintenance until three days.^{6,7}

The NF-kB play crucial role in the inflammatory process, and affecting the cell to expressed TNF-α and IL-1β.⁸ This process also possessed by the dentine. The dentin secretion, which mean, odontoblast metabolic activity can be controlled in response to damage.⁹ Dentin contains a small number of bioactive molecules, including cytokines and growth factors during the demineralization process from the tissue accompanied by the release of molecules such as many growth factors, especially those of the transforming growth factor β1 (TGF-β1) family.¹⁰ These growth factors are extremely potent and have a variety of cell signaling capabilities, allowing them to act at extremely low doses. Once released, these factors traverse the tubule to the pulp and induce a variety of cellular responses, including odontoblast activation. TGF-β1 is a

20

* Corresponding author. Jl. Prof. Dr. Moestopo No 47, Surabaya, 60132, Indonesia.
E-mail address: widya-s@fkg.unair.ac.id (W. Saraswati).

<https://doi.org/10.1016/j.jobcr.2023.01.003>

Received 7 March 2022; Received in revised form 6 June 2022; Accepted 5 January 2023

Available online 6 January 2023

2212-4268/© 2023 The Authors. Published by Elsevier B.V. on behalf of Craniofacial Research Foundation. This is an open access article under the CC BY-NC-ND license (<http://creativecommons.org/licenses/by-nc-nd/4.0/>).

Table 1
The combination of CaCO₃ from *Anadara Granosa* shell and aquadest.

Combination	Ratio of CaCO ₃ from <i>Anadara Granosa</i> shell and aquadest	Mixed/ Not Mixed	Consistency	Setting time
A	1:1	mixed	watery	No setting
B	2:1	mixed	watery	No setting
C	3:1	mixed	Soluble (mixed well)	26 s
D	3:2	mixed	Soluble (mixed well)	17 min
E	4:1	not mixed	not mixed	No setting

Table 2
Animal distribution.

Treatment	Teeth extraction
Glass ionomer cement CaCO ₃ from <i>Anadara Granosa</i> shell and glass ionomer cement	1st day after application
Glass ionomer cement CaCO ₃ from <i>Anadara Granosa</i> shell and glass ionomer cement	3rd day after application
Glass ionomer cement CaCO ₃ from <i>Anadara Granosa</i> shell and glass ionomer cement	7th day after application

growth factor, with various biological activities such as modulating cell growth, differentiation, chemotaxis, and apoptosis which can affect many types of cells, such as monocytes, epithelial, mesenchymal, and neuronal cells.¹¹ TGF-β1 is activated shortly after trauma occurred, increases on the first day, the highest peak is expressed on the third day, and continues to increase on the seventh day.¹²

Dental pulps with good vascularity express vascular endothelial growth factor A (VEGF-A). VEGF-A is the main regulator of angiogenesis in dental pulp tissue whose changes may have a significant impact on the maintenance and regulation of pulp tissue and tooth integrity.¹³ VEGF-A

is a protein specifically secreted by the endothelium, which plays an important role in angiogenesis. The most potent angiogenic and vasculogenic agent involved in tertiary dentin production is VEGF-A. Human vascular endothelial growth factor (hVEGF) has a positive effect on proliferation, differentiation, mineralization, neovascularization and formation of reparative dentin from dental pulp tissue in vitro and in vivo. For the treatment of pulp disease, hVEGF offers clinical therapeutic potential. VEGF-A began to be expressed on third day and was maximally expressed on seventh day.¹⁴

Anadara granosa (blood clam) is accessible and an economic resource in Indonesia. *Anadara granosa* contained calcium carbonate (CaCO₃) (98.7%), magnesium (0.05%), and sodium (0.9%). The CaCO₃ in the *Anadara granosa* shells showed a biocompatibility, insoluble in water, non-toxic and able to use as bone material.¹⁵

Therefore, the *Anadara granosa* shells are expected to be dentin-pulp material restoration by stimulating the formation of reactionary dentin. This process created because this material has anti-inflammatory properties and stable. In the previous studies, *Anadara granosa* shells was shown no toxicity properties,¹⁶ accelerating the healing process of alveolar bones,¹⁷ but there is no research yet on the role of CaCO₃ from *Anadara granosa* shells in the process of pulp inflammation. Thus, this study is expected to reveal the NF-kB, TGF-β1, and VEGF-A expression in

Table 3
NF-kB expression.

Group	NF-kB expression (X±SD)	p
1st days Glass ionomer cement CaCO ₃ from <i>Anadara Granosa</i> shell and glass ionomer cement	7.60 ± 2.61 3.00 ± 1.22	0.013 ^a
3rd days Glass ionomer cement CaCO ₃ from <i>Anadara Granosa</i> shell and glass ionomer cement	12.60 ± 2.70 5.20 ± 1.64	0.001 ^a
7th days Glass ionomer cement CaCO ₃ from <i>Anadara Granosa</i> shell and glass ionomer cement	14.40 ± 1.82 5.60 ± 1.52	0.000 ^a

^a Significant difference using independent t-test with p < 0.05.

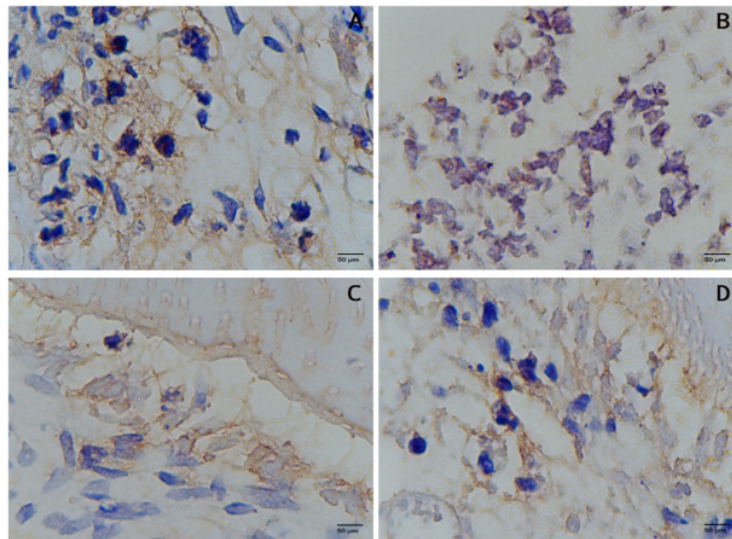


Fig. 1. The NF-kB expression at 1000 × magnification. Control group (A), CaCO₃ from *Anadara Granosa* shell after 1st day (B), CaCO₃ from *Anadara Granosa* shell after 3rd day (C) and CaCO₃ from *Anadara Granosa* shell after 7th day (D).

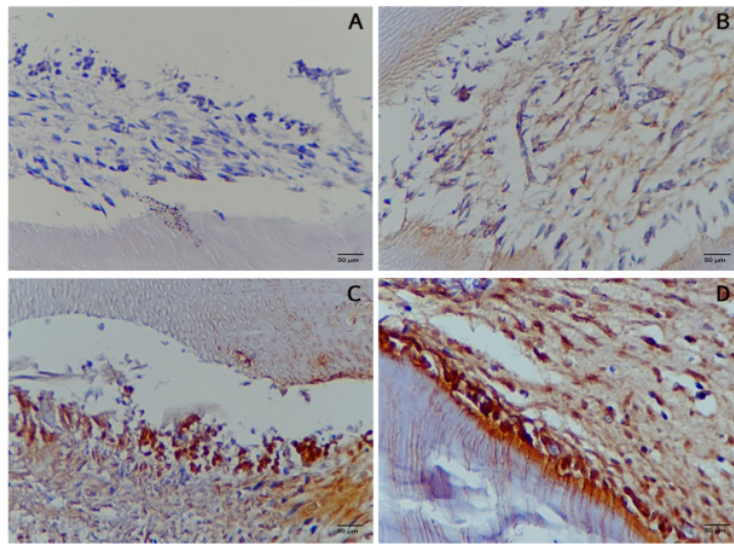


Fig. 2. The TGF-β expression at 1000× magnification. Control group (A), CaCO₃ from *Anadara Granosa* shell after 1st day (B), CaCO₃ from *Anadara Granosa* shell after 3rd day (C) and CaCO₃ from *Anadara Granosa* shell after 7th day (D).

Table 4
TGF-β expression.

	Group	NF-kB expression (X±SD)	p
1st days	Glass ionomer cement	4.20 ± 1.30	0.009 ^a
	CaCO ₃ from <i>Anadara Granosa</i> shell and glass ionomer cement	8.40 ± 1.82	
3rd days	Glass ionomer cement	6.60 ± 1.34	0.000 ^a
	CaCO ₃ from <i>Anadara Granosa</i> shell and glass ionomer cement	11.80 ± 1.48	
7th days	Glass ionomer cement	8.40 ± 2.19	0.031 ^a
	CaCO ₃ from <i>Anadara Granosa</i> shell and glass ionomer cement	12.20 ± 2.39	

^a Significant difference using independent t-test with p < 0.05.

dental pulp after applied with CaCO₃ from *Anadara granosa* shell for one, three and seven days.

2. Material and methods

2.1. CaCO₃ from *Anadara granosa* shell

The CaCO₃ from *Anadara granosa* shell used in this study was mixed using sterile water to obtain a paste form. The combination of CaCO₃ from *Anadara granosa* shell and sterile water was obtained based on preliminary research that had been carried out using 5 different combinations (Table 1).

The selected combination has a fastest setting time which is considered ideal as a pulp capping material. Combination D has the fastest setting time as 26 s, so it was chosen as the ideal combination of CaCO₃ from *Anadara granosa* shell and sterile water with ratio 3:2.

2.2. Animals

The thirty *Rattus norvegicus* strain Wistar, male, healthy and weight 300–350 g used as animal model. Each group consist of five rats. The protocol of this study design was approved by Health Experiment

Committee, Faculty of Dental Medicine, Universitas Airlangga, Indonesia with registration number 254/HRECC.FODM/V/2019.

Tooth cavity created in the occlusal of the first maxillary molar. Diamond bur with diameter 0.84 mm was used with low-speed turbine. The tooth cavity has depth dimension as 1 mm. Before the procedure, the animals were given 0.2 cc/kg body weight combined anesthesia of ketamine hydrochloride and diazepam with weight ratio 10:1.

The cavity then applied glass ionomer cement (*Cention N, Ivoclar Vivadent, Liechtenstein*) (as control group). The other group, applied CaCO₃ from *Anadara granosa* shell then glass ionomer cement. The CaCO₃ from *Anadara granosa* shell was smeared into the cavity using a fine micro brush. The teeth in each group were extracted after 1st, 3rd and 7th days accordingly (Table 2).

2.3. NF-kB, TGF-β and VEGF-A expression

Histological assessment was done by doing immunohistochemistry staining for NF-kB, TGF-β and VEGF-A expression, using a microscope with 1000× magnification by a single operator in 5 filed of views. The primary antibody was used NF-kB (*mouse monoclonal, Santa cruz biotechnology*), TGF-β (*mouse monoclonal, Santa cruz biotechnology*) and VEGF-A (*mouse monoclonal, Santa cruz biotechnology*). The secondary antibody was used DAB system (*Universal HRP Excell Stain, Biogear, Life Science*). The counterstain was used hematoxylin 560 (*Leica Biosystem*).

2.4. Statistical analysis

The data of NF-kB, TGF-β and VEGF-A expression were analyzed for data distribution (One-Sample Kolmogorov Smirnov Test) and homogeneity (Levene test). The differences of NF-kB, TGF-β and VEGF-A expression was analyzed with independent t-test was with p < 0.05 consider as significance differences.

3. Results

3.1. NF-kB expression

The NF-kB expression presented in Fig. 1. The group given CaCO₃

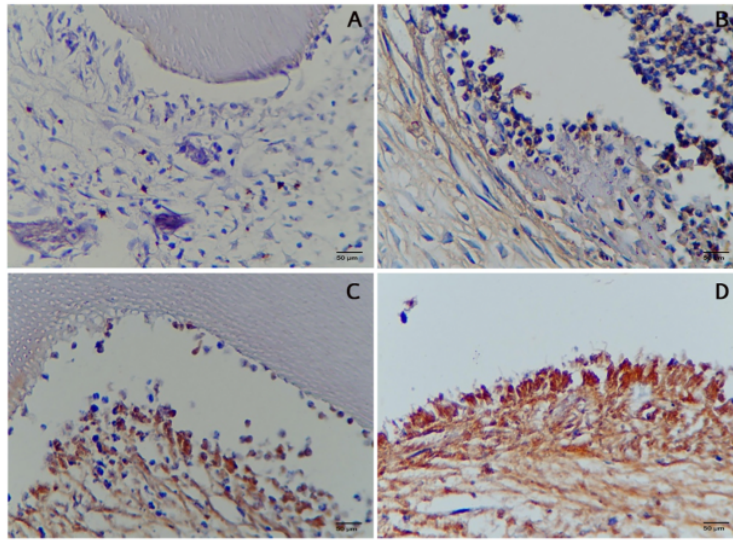


Fig. 3. The VEGF-A expression at 1000× magnification. Control group (A), CaCO₃ from *Anadara Granosa* shell after 1st day (B), CaCO₃ from *Anadara Granosa* shell after 3rd day (C) and CaCO₃ from *Anadara Granosa* shell after 7th day (D).

Table 5
VEGF-A expression.

Group	VEGF-A expression (X±SD)	p	
1st days	Glass ionomer cement CaCO ₃ from <i>Anadara Granosa</i> shell and glass ionomer cement	3.80 ± 1.30 10.00 ± 1.00	0.000 ^a
3rd days	Glass ionomer cement CaCO ₃ from <i>Anadara Granosa</i> shell and glass ionomer cement	5.60 ± 1.52 12.20 ± 1.92	0.000 ^a
7th days	Glass ionomer cement CaCO ₃ from <i>Anadara Granosa</i> shell and glass ionomer cement	9.00 ± 1.58 12.80 ± 2.17	0.015 ^a

^a Significant difference using independent t-test with $p < 0.05$.

from *Anadara granosa* shell showed lower NF-kB expression in pulp tissue compared to controls group on 1st, 3rd and 7th days ($p = 0.013$; $p = 0.001$; $p = 0.000$, respectively) (Table 3).

3.2. TGF-β expression

The TGF-β expression presented in Fig. 2. The group given CaCO₃ from *Anadara granosa* shell showed higher TGF-β expression in pulp tissue compared to controls group on 1st, 3rd and 7th days ($p = 0.009$; $p = 0.000$; $p = 0.031$, respectively) (Table 4).

3.3. VEGF-A expression

The VEGF-A expression presented in Fig. 3. The group given CaCO₃ from *Anadara granosa* shell showed higher VEGF-A expression in pulp tissue compared to controls group on 1st, 3rd and 7th days ($p = 0.000$; $p = 0.000$; $p = 0.015$, respectively) (Table 5).

4. Discussion

The control group was express higher NF-kB expression, because the direct injury process due to the resin in glass ionomer cement. During

the tooth preparation, the odontoblast cell in the dental pulp and dentine, rule out the inflammatory response. The first inflammatory reaction was reactive oxygen species (ROS) producing by leukocytes and macrophages. The ROS, leading the activation of inflammatory transcription factors by separating the NF-kB and inhibitor kappa beta (IκB) bonds. NF-kB is a transcription factor that regulates and produce pro-inflammatory cytokines and growth factors.⁵ NF-kB expression and the presence of pro-inflammatory cytokines used as pulp inflammatory marker and it able enhance the odontoblastic differentiation and collagen matrix formation.^{8,18}

In this study, confirmed that the TGF-β1 expression is higher after CaCO₃ was applied from *Anadara granosa* shell. The higher of TGF-β1 expression is due to the suppression of NF-kB expression. The TGF-β1 expressed in odontoblast cell. This cell appear in the trauma area 1st day after the injury, increasing after 3rd and 7th day.¹⁹ One of the anti-inflammatory cytokines that is activated by NF-kB is interleukin 10 (IL-10). IL-10 is an immunosuppressive interleukin that activates TGF-β1 by carrying a signal into the cells via type I and II receptors (TGF-βRI and TGF-βRII). The TGF-β1 is highly potent and have various cell signaling properties that allow them to act at very low concentrations. Once released, this growth factors transverse the tubule to the pulp and induce a variety of cellular responses, including odontoblast activation. These molecules can be responsible for the stimulation of odontoblast activity. The organic components secreted in response to injury give rise to a dentine matrix called 'reactionary', corresponding to the increased secretion of the matrix by stimulated odontoblasts.^{20,21}

In the term of VEGF, based on the result, the expression of VEGF-A increase after application of CaCO₃ from *Anadara granosa* shell. This result has the similarity with the Zhang et al., 2016 which reports VEGF began to be expressed on 3rd day and was maximally expressed on 7th day.¹⁴ These conditions occurred because normal human pulp represents a tissue with relatively high vascular activity and the ability to remodeling. All VEGF types (VEGF-A, VEGF-B, VEGF-C, and VEGF-D) are expressed in the pulp and can exert both autocrine and paracrine effects in vascular and immune cells supplemented with VEGFR-2 and VEGFR-3.²² VEGF-A has been considered a strong mitogenic factor for vascular endothelial cells, which are involved in the physiological modulation of angiogenesis, vascular permeability as well as the

development of tissue inflammation. VEGF has also been recognized as a positive regulator of bone development, bone growth, and fracture repair, as well as stimulant of the proliferation and differentiation of bone-derived osteoblasts.^{20,21} The VEGF-A, one of the growth factors expressed in dental pulp, release in local blood vessels and by immune cells.^{14,22} On the other hand, there was a more significant increase in the treatment with CaCO₃ from *Anadara granosa* shell because the more activity of the anti-inflammatory cytokines which activate the TGF-β1, thus increase the expression of VEGF-A.

The significant ability of CaCO₃ to increase more VEGF-A that turns out the conclusion that there was more reparative dentin formed in the dentin. And has the correlation with the ability of reactionary dentin to response the early injury to the tooth. The higher VEGF-A release the higher ability of dentine to activate reactionary dentin as the early stage of the pulpo-dentinal complex defense. A previous study by Zhang et al., 2016 also reported that VEGF-A could increase the mineralization and differentiation of human dental pulp cell (hDPC) and significantly increase the expression of Runx2, alkaline phosphatase (ALP), Col-1α, osterix (Ox), Dentin matrix acidic phosphoprotein 1 (DMP1), Dentin sialophospho protein (DSPP), bone morphogenetic protein (BMP2), bone sialoprotein (BSP) and osteocalcin (OCN) genes in pulp cell culture in vitro.¹⁴ Hence, VEGF-A is able to enhance osteoblast and odontogenic differentiation and mineralization of hDPC in vitro. Many studies have reported that the expression of Runx-2 and ALP genes plays an important role in the early and middle stages of the differentiation process during bone formation, and the expression of osteopontin (OPN), BSP and OCN plays an important role in the late stages of osteoblast differentiation. Future research needs to be carried out for analysis of Runx2, ALP, Col-1α, Oxsm DMP1, DSPP, BMP2, BSP) and OCN expression for determine the overall mechanism

5. Conclusion

CaCO₃ from *Anadara granosa* shell able to stimulate the TGF-β1 and VEGF-A and suppress the NF-κB expression in the dental pulp tissue. This material able to develop as dentin-pulp material restoration.

Declaration of competing interest

All author declares no conflict of interest

Acknowledgement

This research is funded by Ministry of Higher Education, Republic of Indonesia 2020 in the schema Penelitian Dasar Unggul Terapan (PDUPT) number 633/UN3.14/PT/2020.

References

- Garg N, Garg A. Textbook of operative dentistry. In: 3ed Editio. *Textbook of Operative Dentistry*. New Delhi: Jaypee Brothers Medical Publishers (P) Ltd; 2013.
- Laslami K, Dhoum S, Karami M, M J. Direct pulp capping with bioactive material: bioceramics. *Econicon Dental Science*. 2017;13(2):75–83.
- Arandi NZ. Calcium hydroxide liners: a literature review. *Clin Cosmet Invest Dent*. 2017;9:67–72.
- Noort R Van. *Introduction to Dental Materials*. fourth ed. Edinburgh: Mosby Elsevier; 2013:108–129.
- Nirwana I, Agustantina TH, Soekartono RH. NF-κB expressions on rat dental pulp mechanically exposed after pomegranate fruit extract administration. *J Int Dental Med Res*. 2017;10(1):123–127.
- Surboyo MDC, Arundina I, Rahayu RP, Mansur D, Bramantoro T. Potential of distilled liquid smoke derived from Coconut (Cocos nucifera L.) shell for traumatic ulcer healing in diabetic rats. *Eur J Dermatol*. 2019 May 5;13:271–279. 02 <http://www.thieme-connect.de/DOI/DOI?10.1055/s-0039-1693527>. Available from.
- Surboyo MDC, Mahdani FY, Ernawati DS, Sarasati A, Rezki F. The macrophage responses during diabetic oral ulcer healing by liquid coconut shell smoke: an immunohistochemical analysis. *Eur J Dermatol*. 2020 Jul 24;14:41–414, 03 <http://www.thieme-connect.de/DOI/DOI?10.1055/s-0040-1712776>. Available from.
- Lin TH, Pajarinen J, Lu L, et al. NF-κB as a therapeutic target in inflammatory-associated bone diseases. In: *Advances in Protein Chemistry and Structural Biology*. 2017;1:17–154.
- Shah D, Lynd T, Ho D, et al. Pulp-dentin tissue healing response: a discussion of current biomedical approaches. *J Clin Med*. 2020 Feb 5;9(2):434.
- Nie X, Tian W, Zhang Y, CHEN X, DONG R, JIANG M, et al. Induction of transforming growth factor-beta 1 on dentine pulp cells in different culture patterns. *Cell Biol Int*. 2006 Apr;30(4):295–300.
- Xu X, Zheng L, Yuan Q, Zhen G, Crane JL, Zhou X, et al. Transforming growth factor-β in stem cells and tissue homeostasis. *Bone Research*. 2018 Dec 31;6(1):2.
- Wang L, Qin W, Zhou Y, Chen B, Zhao X, Zhao H, et al. Transforming growth factor β plays an important role in enhancing wound healing by topical application of Povidone-iodine. *Sci Rep*. 2017;7(1):1–8.
- Saghiri MA, Asatourian A, Sorenson CM, Sheibani N. Role of angiogenesis in endodontics: contributions of stem cells and proangiogenic and antiangiogenic factors to dental pulp regeneration. *J Endod*. 2015 Jun;41(6):797–803.
- Zhang J, Liu X, Yu W, ZHANG Y, SHI C, NI S, et al. Effects of human vascular endothelial growth factor on reparative dentin formation. *Mol Med Rep*. 2016 Jan;13(1):705–712. Available from: <https://www.spandidos-publications.com/10.3892/mmr.2015.4608>.
- Al Omari MMH, Rashid IS, Qinna NA, Jaber AM, Badwan AA. Calcium carbonate. In: *Profiles of Drug Substances, Excipients and Related Methodology*. 2016:31–132.
- Nastiti AD, Lailah FM. Bioviabilitas Hidroksiapatit Ekstrak Cangkang Kerang Darah (*Anadara granosa*) terhadap Sel punca mesenkimal Sebagai Bahan graft tulang alveolar (Bioviabilitas Hidroksiapatite *Anadara granosa* shell extract against mesenchyme stem cell as bone graft. *Material. Denta*. 2015;9(2):122, 031.
- Sari RP. *Mekanisme Kerja Bone Graft dari Cangkang Kerang Darah (Anadara Granosa) dan Teripang Emas (Stichopus Hermannii) pada Penyembuhan Tulang Alveolar Pasca Pencabutan Gigi*. Universitas Airlangga; 2018.
- Hozhabri NST, Benson MD, Vu MD, Patel RH, Martinez RM, Nakhaie FN, et al. Decreasing NF-κB expression enhances odontoblastic differentiation and collagen expression in dental pulp stem cells exposed to inflammatory cytokines. *Liu X. PLoS One*. 2015 Jan 28;10(1), e0113334.
- Khoswanto C. Optimum concentration anredera cordifolia (Ten.) steenis gel in increasing the expression BMP-2 and the number of osteoblasts post tooth extraction in wistar rats. *J Int Dental Med Res*. 2019.
- Zavan B, Ferroni L, Gardin C, Sivoletta S, Piattelli A, Mijiritsky E. Release of VEGF from dental implant improves osteogenic process: preliminary in vitro tests. *Materials*. 2017 Sep 8;10(9):1052.
- Gardin C, Bressan E, Ferroni L, Nalesso E, Vindigni V, Stellini E, et al. Vitro concurrent endothelial and osteogenic commitment of adipose-derived stem cells and their genomic analyses through comparative genomic Hybridization array: novel strategies to increase the successful engraftment of tissue-engineered bone grafts. *Stem Cell Dev*. 2012 Mar 20;21(5):767–777.
- Virtelj A, Løes S, Iden O, Blets A, Berggreen E. Vascular endothelial growth factors signalling in normal human dental pulp: a study of gene and protein expression. *Eur J Oral Sci*. 2013 Apr;121(2):92–100.

CaCO₃ from Anadara granosa shell as reparative dentin inducer in odontoblast pulp cells: In-vivo study

ORIGINALITY REPORT

19%

SIMILARITY INDEX

15%

INTERNET SOURCES

17%

PUBLICATIONS

0%

STUDENT PAPERS

PRIMARY SOURCES

- | | | |
|---|--|----|
| 1 | tessera.spandidos-publications.com
Internet Source | 3% |
| 2 | www.thieme-connect.com
Internet Source | 2% |
| 3 | Simon, Stéphane, Anthony J. Smith, Philip J. Lumley, Paul R. Cooper, and Ariane Berdal. "The Pulp Healing Process: From Generation to Regeneration*", Oral Wound Healing Larjava/Oral Wound Healing, 2013.
Publication | 2% |
| 4 | Virtej, Anca, Sigbjørn Løes, Ole Iden, Athanasia Bletsas, and Ellen Berggreen. "Vascular endothelial growth factors signalling in normal human dental pulp: a study of gene and protein expression", European Journal Of Oral Sciences, 2013.
Publication | 1% |
| 5 | www.mdpi.com
Internet Source | 1% |

6	core.ac.uk Internet Source	1 %
7	cyberleninka.org Internet Source	1 %
8	mdpi-res.com Internet Source	1 %
9	Mohammad Ali Saghiri, Armen Asatourian, Christine M. Sorenson, Nader Sheibani. "Role of Angiogenesis in Endodontics: Contributions of Stem Cells and Proangiogenic and Antiangiogenic Factors to Dental Pulp Regeneration", Journal of Endodontics, 2015 Publication	1 %
10	www.dovepress.com Internet Source	1 %
11	Meircurius Dwi Condro Surboyo, Fatma Yasmin Mahdani, Diah Savitri Ernawati, Andari Sarasati, Fianza Rezkita. "The Macrophage Responses during Diabetic Oral Ulcer Healing by Liquid Coconut Shell Smoke: An Immunohistochemical Analysis", European Journal of Dentistry, 2020 Publication	1 %
12	Dini Asrianti Bagio, Indah Julianto, Anggraini Margono, Endang Suprastiwi. "Increased VEGF-A Expression of Human Dental Pulp	1 %

Stem Cells (hDPSCs) Cultured with Advanced Platelet Rich Fibrin (A-PRF)", The Open Dentistry Journal, 2021

Publication

13

opus.bsz-bw.de

Internet Source

<1 %

14

pure.rug.nl

Internet Source

<1 %

15

Milena Giulia Gonçalves. "História natural da infecção por variantes genéticas de HPV-16 no canal anal de homens participantes do estudo internacional multicêntrico HIM (HPV Infection in Men)", Universidade de Sao Paulo, Agencia USP de Gestao da Informacao Academica (AGUIA), 2022

Publication

<1 %

16

f1000research.com

Internet Source

<1 %

17

www.rti.org

Internet Source

<1 %

18

www.karger.com

Internet Source

<1 %

19

www.koreascience.or.kr

Internet Source

<1 %

20

Maria Istiqomah Marini, Hastomo Angrosidy, Arofi Kurniawan, Mieke Sylvia Margaretha.

<1 %

"The anthropological analysis of the nasal morphology of Dayak Kenyah population in Indonesia as a basic data for forensic identification", Translational Research in Anatomy, 2020

Publication

21

dspace.pondiuni.edu.in

Internet Source

<1 %

Exclude quotes Off

Exclude matches < 10 words

Exclude bibliography On

CaCO₃ from Anadara granosa shell as reparative dentin inducer in odontoblast pulp cells: In-vivo study

GRADEMARK REPORT

FINAL GRADE

/0

GENERAL COMMENTS

Instructor

PAGE 1

PAGE 2

PAGE 3

PAGE 4

PAGE 5
