

Case Report

Direct anterior resin composite bridge – a case report

Cendranata Wibawa Ongkowijoyo¹, Sukaton² and Veronica Regina Rosselle¹

¹Resident of Conservative Dentistry Specialist Program,

²Lecturer of Department of Conservative Dentistry,

Faculty of Dental Medicine, Universitas Airlangga, Surabaya, Indonesia

ABSTRACT

Background: Dental hard tissue loss renders a tooth restorable or unrestorable. The treatment ranges from endodontic treatment to dental implant. Sometimes patients in need to restore their oral function and esthetics cannot afford those treatments due to a limited financial capability and time availability. **Purpose:** This case report presents a minimal invasive, single appointment, quick, and affordable alternative treatment to restore morphology, function, and esthetics. **Case:** A 40 years old male patient suffered enamel-dentin-pulp fracture on central incisor due to trauma. Eventhough the fracture involves pulp exposure, it remains vital. The tooth lacks sound tooth structure for ferrule effect. The patient wished to retain the tooth. Therefore, initial treatment plan comprised of reestablishing ferrule effect, root canal treatment, endodontic post, and porcelain crown. Nevertheless, due to financial and time constraint, patient refused the suggested treatment plan; thus, direct resin composite bridge was suggested. **Case Management:** Isolation is followed by calcium hydroxide capping of the exposed pulp. After application of etch and adhesive bonding to tooth 11, 21, and 22, nanohybrid resin composite was layered to fabricate the direct composite bridge, bonded to 11 and 21, with the following layering sequence: 1) palatal; 2) proximal; 3) body; 4) labial. The procedure took 1 hour to restore tooth morphology, function, and esthetics. Upon five years follow-up, the tooth remains asymptomatic. The direct resin composite bridge has been serving well. **Conclusion:** Direct resin composite bridges can be an affordable, quick, and minimal invasive treatment modality resulting in satisfactory esthetics, function, and longevity.

Keywords: composite; bridge; direct; resin

Correspondence: Sukaton, Department of Conservative Dentistry, Faculty of Dental Medicine, Universitas Airlangga. Jl. Mayjen Prof. Dr. Moestopo, No 47, Surabaya 60132, Indonesia. Email: sukaton@fkg.unair.ac.id.

INTRODUCTION

Dental hard tissue loss can be caused by either carious disease or traumatic injury.^{1,2} Following hard tissue loss, a tooth is either rendered restorable or non-restorable. A restorable tooth can be treated with fillings or root canal treatment, endodontic post, core build-up, and porcelain crown. An unrestorable tooth which needs to be extracted can be replaced in the future with removable denture, fixed partial denture, or dental implants.^{3,4} Sometimes patients in need to restore their oral function and esthetics cannot afford those treatments due to a limited financial capability.^{5,6} Moreover, due to increased mobility, work demand, and limited time availability, some patients cannot afford long chairside time and multiple dental appointments.^{1,7}

This case report presents an alternative treatment to restore the morphology, function, and esthetics of fractured or even missing tooth with the additional benefits of being minimal invasive, single appointment only, short chairside time, and affordable.

CASE

A 40th years old male patient came to the conservative dentistry department of Universitas Airlangga Oral Hospital, Surabaya, East Java, Indonesia, with a chief complaint of fractured upper front tooth due to traffic accident two weeks previously. Patient had experienced severe pain few days after the tooth fractured until suddenly subsided. There was no more pain at present; thus, his main concern was the esthetics. Patient reported no mobility and no soft tissue swelling. Moreover, his general health was not contributory.

Upon clinical examination, the patient maintains an excellent oral hygiene. All teeth were intact except the maxillary left central incisor. The maxillary left central incisor suffered complete crown oblique fracture with supragingival margin on the buccal side and subgingival margin on the palatal side, exposing the orifice (Figure 1); thus, it is classified as enamel-dentin-pulp fracture according to International Association of Dental Traumatology

(IADT).² However, the tooth remains vital. The patient wished to retain the tooth. There was no carious lesion, no pain on percussion, no mobility, no soft tissue swelling, and no crack lines.

Due to lack of remaining sound coronal tooth structure for adequate ferrule effect, surgical extrusion needed to be performed prior to root canal treatment and restoration in order to reestablish a ferrule effect.^{4,8} Therefore, surgical extrusion, root canal treatment followed with endodontic post, core build-up, and porcelain crown was proposed to restore the morphology, function, and esthetics of the fractured maxillary left central incisor. Nevertheless, due to financial and time constraint, patient refused the suggested treatment plan. Hence, an alternative treatment plan which suited the financial capability and time availability of the patient needed to be addressed. Therefore, pulp capping followed by direct resin composite bridge was proposed as the alternative treatment. Direct resin composite bridge takes only one appointment to deliver and costs only a fraction than the conventional treatment.^{5,7} The patient agreed the alternative treatment plan of direct resin composite bridge.

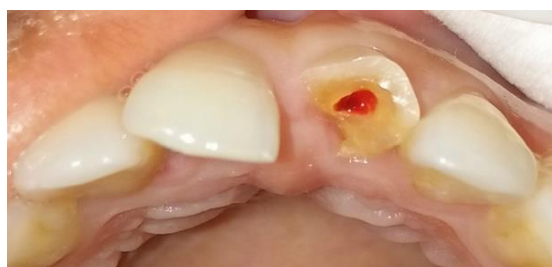

Figure 1. Pre-operative clinical picture.

CASE MANAGEMENT

Working field was isolated with rubber dam (Sanctuary, Malaysia) (Figure 2). Both maxillary left and right first premolars were clamped as the anchorage for the split dam anterior quadrant isolation technique. Maxillary right and left central incisor as well as the maxillary left lateral incisor (tooth 11, 21, and 22) were cleaned with ultrasonic scaler. Slight labial chamfer was prepared on the labial surface of tooth 21 to accommodate restorative material thickness. Then, those teeth were desinfected with 2.5% NaOCl (OneMed, Indonesia).

The exposed pulp of tooth 21 was then capped with calcium hydroxide (Prisma VLC dycal, Dentsply Sirona, USA) (Figure 2). Subsequently, the mesial surface of tooth 11, 22, and remaining structure of tooth 21 were etched with 37% phosphoric acid (Any-etch, Medclus, Korea). Tooth 11 and 22 was not prepared with diamond bur to preserve enamel tissue. After rinsing the phosphoric acid, 2% chlorhexidine (Consepsis, Ultradent, USA) was applied to the exposed dentin of tooth 21 for one minute as MMP inhibitor and to increase bond strength.⁹ 5th generation bonding (Scotchbond Universal Adhesive, 3M, USA) was applied to tooth 11, 21, and 22.

The fabrication of direct resin composite bridge started with the palatal layer (Figure 3). Index finger was used as the palatal matrix to aid in layering the palatal wall morphology. The palatal layer was splinted and extended to the adjacent teeth, paying careful attention to the incisal length and incisal embrasures. Z350XT (3M, USA) A3 enamel shade was used for the palatal layer.

The second phase was to build the proximal walls (Figure 4). The proximal walls needed to be splinted to adjacent teeth (tooth 11 and 22) and built according to proper

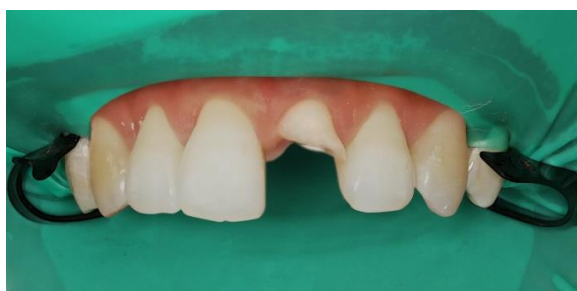

Figure 2. Isolation and direct pulp capping.

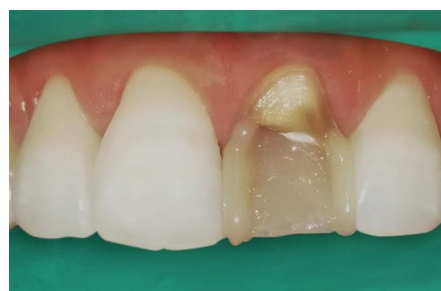

Figure 4. Proximal walls.

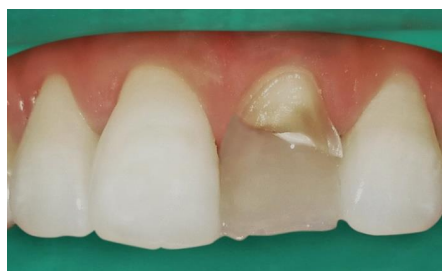

Figure 3. Palatal layer.

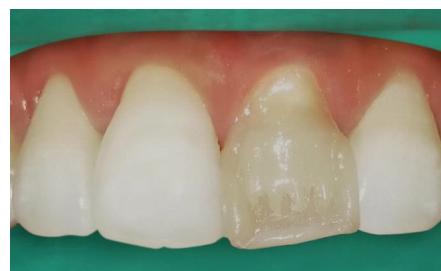

Figure 5. Dentin body, mamelons, and incisal halo.

gingival and incisal embrassures. For esthetics purpose, the proximal walls was bonded in contact with the proximal contact zone of adjacent teeth with proper mesiodistal dimension. Z350XT (3M, USA) A3 enamel shade was used for the proximal walls.

The third phase was building the dentin body, mamelons, and incisal halo (Figure 5). Those were built with Z350XT (3M, USA) A3 dentin shade. Finally, the labial layer was built with Z350XT (3M, USA) A3 enamel shade (Figure 6). Shaping the labial layer was aided with a thin flat nylon brush, paying careful attention to anatomical landmarks such as cervical bulge and mesial and distal line angles. Glycerin gel was applied to all surface of the direct resin composite bridge before 40 seconds photopolymerization from labial and palatal side to prevent the formation of oxygen inhibited layer and to increase the resin composite's surface hardness.¹⁰

Occlusion was checked and adjusted. Finishing was carried out with fine and extra fine-long thin diamond bur (Mani, Japan). Attention was given during finishing the labial layer, cervical bulk, and mesial and distal line angle. Polishing was done with medium to fine polishing discs (TOR VM, Russia) and felt disc (TDV, Brazil). In total, all procedures took 1 hour.

The patient was very satisfied with the result of the direct resin composite bridge which offered him a quick and affordable anterior morphology, function, and esthetic rehabilitation (Figure 7 a,b,c). Upon follow-ups, the tooth

remains asymptomatic. The direct resin composite bridge has been followed-up routinely and has been in function for five years (Figure 8 a,b).

DISCUSSION

The principle of the management of dental trauma involves preserving pulp vitality or otherwise performing root canal treatment, and restoring the morphology of the dentition, function for mastication, and esthetics.² Whenever sufficient sound coronal tooth structure is present to establish a ferrule effect, a fractured crown can be restored with root canal treatment, endodontic post, core build-up, and porcelain crown.⁴ If there is an insufficient tooth structure, orthodontic forced eruption, or surgical crown lengthening, or surgical extrusion must be performed to reestablish the ferrule effect prior to restoration phase of the treatment.⁸

Conventional treatment for enamel-dentin-pulp fracture leaving little sound tooth structure like in this case report comprises of reestablishing ferrule effect, endodontic

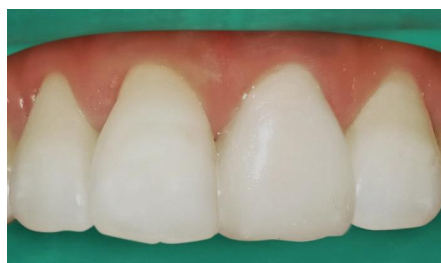

Figure 6. Labial layer.

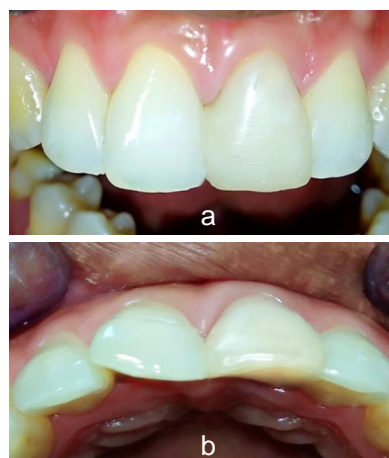

Figure 8. Direct resin composite bridge five years follow up a) Labial view; b) Incisal view.

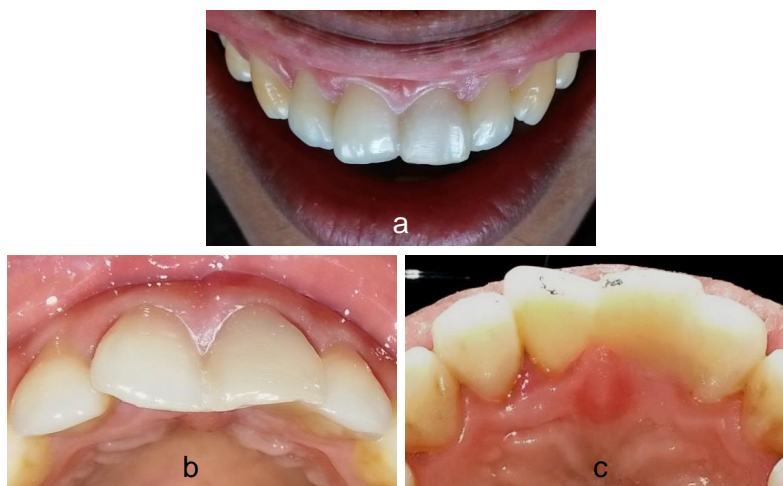


Figure 7. a) Direct resin composite bridge immediately after finishing and polishing; b) Incisal view; c) Palatal view.

treatment, and restoration which involves several dental visits, lengthy overall treatment duration, and significant cost.⁷ In reality, not every patient in need can actually afford this treatment modality. Moreover, due to increased mobility, work demand, and time constraint, some patients cannot comply to dental treatment which necessitates multiple visits.^{1,5,6} Therefore, clinicians need to consider an alternative treatment to overcome the problem with cost and time; hence, direct resin composite bridge can be considered as a viable alternative.¹

Direct resin composite bridge can also be an alternative treatment for patients who do not want removable partial denture due to issue with comfort and chewing capacity, or do not want their adjacent teeth prepared to be abutments for fixed partial denture, or do not want dental implant treatment due to anxiety, local, or general medical contraindications.^{7,11} Direct resin composite bridge offers the advantages over conventional treatments: non-invasive; fixed in nature; comfortable; finished within 1 visit; takes a short chairtime; needs neither sophisticated materials nor technique; affordable; and easy to repair.^{5,6,11,12}

The principles of the durability of direct resin composite bridge involves the enamel-rich surface area of adjacent dentition for bonding as well as the bulk of the composite itself which enable the whole structure to withstand masticatory forces.^{7,11} Nevertheless, careful case selection is paramount. For example, patients who need more than multiple anterior tooth replaced, or who have lost a considerable number of teeth, or patients with a history of bruxism might yield a poor prognosis. Furthermore, direct resin composite bridge for replacement of molars is not recommended.⁵

A clinical follow up study by Al-Wahadni and Al-Omari in 2004 found that direct resin composite bridge for lower anterior teeth has a 80% survival rate over 5 years.³ Dr John Savage in the USA and dr Terry Shaw in Canada have been performing a large number of direct resin composite bridge since more than a decade ago. According to them, direct resin composite bridges are as durable as most of them last for more than 5 years and some of them served for up to 20 years.^{5,6}

Conventional treatment for fractured anterior teeth consisting of root canal treatment, endodontic post, core build-up, and porcelain crown can sometimes be prohibitive for some patients in terms of fee and time. Direct resin composite bridge as an alternative treatment costs a fraction of conventional treatment and can be finished within one chairside appointment, which also benefits the dentist in

terms of higher productivity with lower operational cost. Moreover, it offers an additional benefit which is minimal invasive. Despite being uncommon, direct resin composite bridges has been proven as a treatment modality which results in satisfactory esthetics, function, and longevity.

REFERENCES

1. Machmud E. Teknik sederhana pembuatan gigitiruan jembatan tiga unit dari komposit A simple technique to make three-unit composite bridge. *J Dentomaxillofacial Sci.* 2011;10(1):23-5.
2. Andreasen JO, Di Angelis AJ, Ebeleseder KA, Kenny DJ, Trope M, Sigurdsson A, et al. International Association of Dental Traumatology guidelines for the management of traumatic dental injuries: 1. Fractures and luxations of permanent teeth. *Dent Traumatol.* 2012;28(1):2-12.
3. Al-Wahadni AM, Al-Omari WM. Immediate resin-bonded bridgework: results of a medium-term clinical follow-up study. *J Oral Rehabil.* 2004;31(1):90-4.
4. Juloski J, Radovic I, Goracci C, Vulicevic ZR, Ferrari M. Ferrule effect: A literature review. *J Endod.* 2012;38(1):11-9.
5. Savage J. The One-Appointment Direct Bridge. Parkell Inc. 2011;1-2.
6. Shaw T. Composite resin bridges: reflecting on 20 years of success [Internet]. *Perio-Implant Advisory.* 2011 [cited 2019 Nov 8]. Available from: <https://www.perioimplantadvisory.com/restorative-dentistry/article/16411901/composite-resin-bridges-reflecting-on-20-years-of-success>
7. Carlson R. Senior Solutions: Direct Composite Fixed Bridges. *Biomed J Sci Tech Res.* 2017;1(4):1082-5.
8. Argueta J, Orellana A, Plotino G. Surgical extrusion: A reliable technique for saving compromised teeth. A 5-years follow-up case report. *G Ital Endod.* 2018;32:25-30.
9. Zheng P, Chen H. Evaluate the effect of different mmpps inhibitors on adhesive physical properties of dental adhesives, bond strength and mmp substarte activity. *Sci Rep.* 2017;7(1):1-11.
10. Park H-H, Lee I-B. Effect of glycerin on the surface hardness of composites after curing. *J Korean Acad Conserv Dent.* 2011;36(6):483-9.
11. Lowe R. The direct composite bridge: still a unique solution for some clinical situations [Internet]. *Dentistry Today.* 2012 [cited 2019 Nov 8]. Available from: <https://www.dentistrytoday.com/restorative/7320-the-direct-composite-bridge-still-a-unique-solution-for-some-clinical-situations>
12. Carlson R. Immediate post-extraction in situ direct lamination composite bridge [Internet]. *Dentistry Today.* 2006 [cited 2019 Nov 8]. Available from: <https://www.dentistrytoday.com/restorative-134/1818--sp-1274717504>