

# A Case Report on Lateral Proboscis : A Rare Congenital Anomaly

*by* Indri Lakhsmi Putri

---

**Submission date:** 07-Apr-2023 05:14PM (UTC+0800)

**Submission ID:** 2058283689


**File name:** A\_Case\_Report\_on\_Lateral\_Proboscis\_A\_Rare\_Congenital\_Anomaly.pdf (2.93M)

**Word count:** 5189

**Character count:** 28287

# A Case Report on Lateral Proboscis: A Rare Congenital Anomaly

Indri Lakshmi Putri, MD, PhD<sup>1</sup> , Taufiqur Rakhim Aditra, MD<sup>1</sup>, Tedy Apriawan, MD<sup>2</sup>, Djoko Kuswanto<sup>3</sup> , Faizal Rezky Dhafin<sup>4</sup>, and Magda Rosalina Hutagalung, MD<sup>1</sup>

6  
The Cleft Palate-Craniofacial Journal  
1-9  
© 2021, American Cleft Palate-Craniofacial Association  
Article reuse guidelines:  
sagepub.com/journals-permissions  
DOI: 10.1177/10556656211066434  
journals.sagepub.com/home/cpc  


## Abstract

Lateral proboscis is a rare congenital condition characterized by a cylindrical protuberance on the nasofrontal region accompanied by abnormal nasal development on the affected side. We aimed to describe the management of the lateral proboscis in staged repair. A 7-year-old girl came with a tube-like projection on the left medial canthal region and nasal agenesis on the ipsilateral side. She was diagnosed with lateral proboscis, left microphthalmia, lower eye lid coloboma, and asymmetry in the orbital region. The patient has undergone 3 major surgeries at our institution. The first surgery involved the deconstruction of the tube to form the left nasal body and nostril. The second operation involved trimming of the new nose form and the excision of the bony protrusion directly beneath the base of the pedicle through bifrontal craniotomy. The remaining bone defect was closed using a pericranial flap. The orbital floor was reconstructed using titanium mesh. The third operation involved nasal reconstruction using a costal cartilage graft to create a dorsal nasal and alar framework. The patient healed with no complications, had become less reserved and her grades improved significantly after the operation. Further appointments are being scheduled to evaluate growth distortion and the resulting facial asymmetry. Surgical correction will be planned thereafter to further reconstruct the facial features. Evaluation of patient is necessary to explore possible clinical outcomes and corresponding treatment options. Multidisciplinary management is highly recommended, involving plastic surgeons, neurosurgeons, ophthalmologists, pediatricians, and pediatric psychiatrists in order to improve patient's quality of life.

## Keywords

lateral proboscis, nasal agenesis, craniofacial surgery, medical care

## Background

Lateral proboscis is an uncommon congenital disorder identified by the presence of a primitive, tube-like structure that emerges from the medial orbital roof (Ajike et al., 2018). It refers to a primitive nasal structure or appendage that is positioned away from the face's vertical midline (Chauhan and Guruprasad, 2010). It is first elucidated by Foster in 1961 in his monograph entitled "Congenital Malformation of the Human Body" (Magadam et al., 2012). He elucidated a case of an 8-month-old girl with lateral proboscis, cyclopean eye, and heminasal aplasia. Another well-described encounter is presented by Selenkoff in 1884, where he presented more comprehensive postmortem findings on a 35-year-old farmer (Martin et al., 2013).

The incidence of this condition was reported to be around 1:100,000 to 1:1,000,000 live births with a male preponderance of 3:1 (Sakamoto et al., 2010; Verma et al., 2011; Magadam et al., 2012). However, patient history revealed no known history of facial abnormalities in the family and that

karyotyping revealed no divergence from the normal 46XX or 46 XY karyotype (Martin et al., 2013). Clinically, the lateral proboscis is described as a tubular protuberance about 2 to 3 cm long and 1 cm wide. It can happen either unilaterally or bilaterally (Ajike et al., 2018). It is usually attached to the medial canthal area, but other areas of attachment have been

<sup>1</sup>Department of Plastic Reconstructive and Aesthetic Surgery, Faculty of Medicine, Airlangga University, Surabaya, Indonesia

<sup>2</sup>Department of Neurosurgery, Faculty of Medicine, Airlangga University and Airlangga University Hospital, Surabaya, Indonesia

<sup>3</sup>Department of Industrial Design, Institut Teknologi Sepuluh Nopember, Surabaya, Indonesia

<sup>4</sup>PT ReKayasa Teknologi Medis Indonesia, Surabaya, Indonesia

## Corresponding Author:

Indri Lakshmi Putri, Department of Plastic Reconstructive and Aesthetic Surgery, Faculty of Medicine, Airlangga University, Surabaya, East Java, Indonesia.

Email: indrilakshmiputri@fk.unair.ac.id

documented, including the lateral canthus, the chin, and the root of the nose (Martin et al., 2013).

There is a spectrum of clinical presentation, from the milder form of olfactory tract agenesis to the more severe malformation of cyclopia and cebocephaly (Schinzel et al., 1984). It can develop as an isolated abnormality or in association with other anomalies such as heminasal aplasia/hypoplasia, mental retardation, callosal agenesis, encephalocele, microphthalmia, holoprosencephaly, and clefts (Ajike et al., 2018). The most common associated condition is a hypoplasia of the ipsilateral nose, and the second most common is coloboma of the iris and cleft of the eyelids (Kirkpatrick, 1970). The lateral proboscis has been rarely associated with nervous system abnormalities such as cognitive and neurological deficits, and also anatomically, such as the absence of olfactory bulbs and holoprosencephaly (Martin et al., 2013).

Boo-Chai (1985) has developed a classification of this condition as follows:

- Group I: lateral proboscis with normal nose
- Group II: lateral proboscis with ipsilateral nasal abnormality
- Group III: lateral proboscis with ipsilateral abnormality of the nose, eye, or ocular adnexa
- Group IV: lateral proboscis with ipsilateral abnormality of the nose, eye, or ocular adnexa with the occurrence of cleft lip and/or palate.

Most recently, Sakamoto et al. (2012) has developed additional categories into the above classification as follows:

- Group V: lateral proboscis with encephalocele
- Group VI: lateral proboscis with holoprosencephaly

### Pathogenesis

Any facial anomaly can be attributed to 2 main developmental aberrations: (1) an abnormal fusion process of embryonic mesenchyme or (2) a deficient cell formation and migration (Antoniades and Baraister, 1989). At the 28th day (5th week) of embryological development, the nasal placode starts to form. The nasal placodes invagination forms the nasal pits that will eventually be the nasal cavities. The borders of the nasal pit are the medial and nasal processes. The 2 lateral nasal processes form the lateral nasal wall and the nasal ala. The medial nasal process at its globular process merges with the lateral process to form the lower lining of the nares and vestibule.

Speculations give rise to several theories regarding the origin of the lateral proboscis. One theory suggests that it represents the nasolacrimal duct because sometimes tears are produced from the opening and in some cases, injecting a dye reveals a connection to the lacrimal sac (Kirkpatrick, 1970). The opening at the end of the proboscis is supposed to be the olfactory pit that fails to form the nasal cavity (Bishop, 1964). Another opinion is that the proboscis arises from

aberrations of the medial and lateral nasal processes on the affected side. If this is the case, the philtrum, if present, may be the result of compensatory growth of the globular process of the normal unaffected side. This theory is further supported by the fact that on the affected side, there is atresia of the anterior nares and there is an absence of cribriform plate and olfactory bulb as shown on the results of T2-weighted images conducted on a patient with lateral proboscis (Vaid et al., 2010).

Another alternative explanation as to why the philtrum is still present is that the premaxillary component of the medial process that came from the globular process grows as an independent entity, and thus is unaffected (Bishop, 1964). It is of note that the medial nasal process undergoes further division into medial and lateral processes, the former of which forms the columella with the unaffected side (Martin et al., 2013). Other theory suggests that the lateral proboscis arises from the fusion between the maxillary process of the affected side and the globular and nasal process of the contralateral side (Abou-Elhamd, 2004). Abnormal development of the maxillary process results in abnormal alveolus, lacrimal apparatus, palate, lips, eyes, and nose. The optic furrow will fail to close in this case, causing formation of colobomas of the eyelid, retina, and iris (Martin et al., 2013).

It is possible that there might be an abnormal development of the nasal placode in the first place. As a result, the maxillary mesoderm comes into contact with the frontonasal process, isolating the medial and lateral nasal processes (Kirkpatrick, 1970). The incomplete merger of the lateral nasal process with the maxillary process results in the formation of a lateral proboscis (Abou-Elhamd, 2004). The presence of heminasal aplasia is directly attributed to the abnormality in one of these nasal placodes and the corresponding processes (Martin et al., 2013), but some are caused by the presence of supernumerary nasal placodes (Ajike et al., 2018).

As described by Ajike et al. (2018), a cleft of the lip may occur concurrently. However, there is no direct explanation on the cleft and the proboscis occurring concurrently because, at this embryonic stage, the formation of various organs of the face occurs simultaneously. Any assault may affect any of these processes. The lateral proboscis is sometimes associated with the presence of a cyclopean eye. Experts believe that the cyclopean eye is a result of monozygotic twinning, whereby incomplete separation of these twins caused duplication of organs (Meeker and Aebli, 1947). Several theories also explained the clinical manifestations that appeared in group 5 and 6 in the classification by Sakamoto et al. (2012). Group 5 manifestations are caused by disturbance of facial growth by central mass or encephalocele affecting the growth of the maxillary process, while in group 6, the characteristics arise from aplasia of medial nasal prominence (Martin et al., 2013).

### Diagnosis

Diagnosis is made by clinical examination, nasal endoscopy, and confirmation with computed tomography (CT) scanning



(Abou-Elhamd, 2004). Vaid et al. (2010) reported a 2-year-old child with proboscis lateral in the left medial canthus who was scheduled for CT. A CT scan showed left sinonasal aplasia, with agenesis of the left nasal vault, maxillary, and ethmoid sinus. The proboscis arises from an osseous opening in the superomedial side of the left orbit.

Prenatal ultrasound can help in the diagnosis of lateral proboscis. It can also point out brain abnormalities, such as the absence of the falx cerebri or complete amalgamation of the ventricles (Schinzel et al., 1984). Ultrasonographic prenatal diagnosis of lateral proboscis is also documented in reports on 4 cases of cyclopia. In all these cases, they found one median fused orbit. In 3 cases, other findings found were microcephaly, agenesis of the nose, and proboscis (Schinzel et al., 1984). Parents should be well informed about the possible malformations that can accompany this abnormality and the surgical interventions that should be done after birth (Mehta et al., 1999).

A histological examination carried on a sample of the proboscis tissue revealed similar results from previous similar reports: sebaceous glands, striated muscle fibers, cartilaginous elements, and stratified columnar epithelium mucous lining (Kirkpatrick, 1970). This is consistent with the normal structure of the nasal wall: skin, muscle, and fibrous tissue; nasal cartilage; bony trabeculae; submucosal glands; blood; and lymph vessels. The distal opening will produce a mucous discharge consistent with the product of low columnar to cuboidal respiratory epithelium which is present in the lining of the lumen (Martin et al., 2013).

### Management

The treatment is highly specific to individual needs. It is necessary to use a multidisciplinary approach that includes an otolaryngologist, a plastic surgeon, and an ophthalmologist (Martin et al., 2013). Historically, the mainstay of surgery was to excise the proboscis, but it was believed that there was invariably intracranial communication through the proboscis (Martin et al., 2013).

In deciding the most appropriate time for surgery, Biber (1949) advocated operating on the patient at maturity to prevent the normal side from outgrowing the operated side. However, this is denounced based on the fact that delayed treatment will prolong the mental grievance of the patient. Thus, the ideal age proposed will be at age 4, before the child goes to school (Kirkpatrick, 1970). Staged repair is needed, with the most important reconstructive step done at maturity (Martin et al., 2013). Total aesthetic makeover is delayed until maturation when there is completion of growth of the nasal skeleton (Magadam et al., 2012). It is also recommended to over-correct the deformity to prevent multiple subsequent adjustments (Kirkpatrick, 1970).

### Case Report

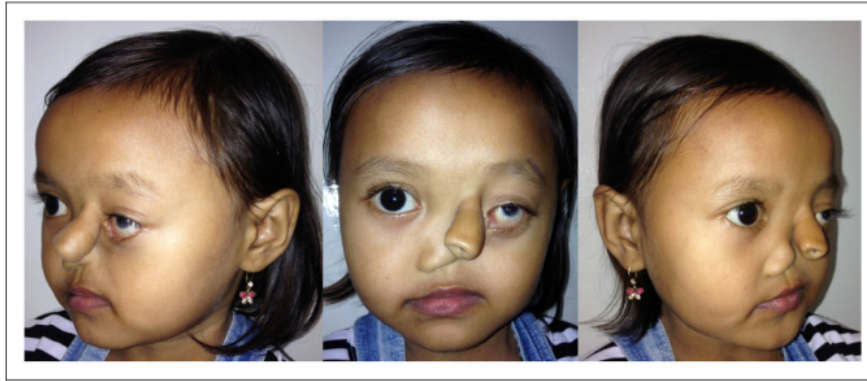We report a case of a 7-year-old girl who came with a tube-like projection on the left medial canthal region, nasal agenesis on the ipsilateral side, and severe asymmetry in the orbital region present since birth. History was taken from the father as the biological mother was deceased. The antenatal history was uneventful. There was no maternal history of alcoholism, drug abuse, or radiation. The father denied any family history of a similar condition.

Generally, the little girl appeared reserved. Physical examination revealed a tube-like proboscis with mucoid discharge arising from the medial canthal region, epiphora and lower eyelid coloboma of her left eye, heminasal agenesis, and what looks like a smaller than normal and displaced globe on the affected side, rendering the face severely asymmetric (Figure 1). The patient was unable to see with the normal eye closed. There was no abnormality in other systems.

The patient was then sent for ophthalmologic consultation and a CT scan of the head. Sonography of the globe on the affected side revealed microphthalmia. The results of the CT scan showed that there was an anatomical defect on the base of the sella turcica with herniation of the dura into the nasal cavity (Figure 2). There was atresia of the left nasal cavity and severe hypoplasia of the left maxillary sinus. The proboscis was described to be 1.6 × 1.2 cm in dimension, entrapped within a branch of the supratrochlear artery. On the left globe, there was calcification of the optic lens, and the diagnosis of microphthalmia was again confirmed.

The patient was then prepped for the first surgery which involved the deconstruction of the tube to form the left nasal body and nostril. The implantation site along with the margin of the supposed anatomical location of the nasal dorsum was de-epithelialized. The proboscis was incised along with its length at the posteromedial side to reveal a mucosal-lined lumen. The exposed lining of the proboscis was partially skin grafted, and the rest of the raw surface was approximated to the implantation site to form the newly constructed nasal body (Figure 3). The patient was discharged with no complications a few days after the operation.

The second operation, carried out 3 years afterward, was conducted in a multidisciplinary fashion, involving the neurosurgeon and ophthalmologist. We carried out a preoperative CT scan to evaluate possible intracranial communication through the proboscis (Figure 2). Intraoperatively, the neurosurgeon carried out a bifrontal craniotomy to expose the bony protrusion directly beneath the base of the proboscis (Figure 4). There was what looked like a rudimentary remnant of meningoencephalocele. The bony protrusion was leveled and the rudiment it contained was excised and sent for pathologic examination. The remaining bone defect was closed using a pericranial flap. The ophthalmologist did not find any lacrimal punctum and functional lacrimal apparatus overall on the affected side. He carried out a temporary tarsorrhaphy on the left eye. We reconstruct the proboscis at the end of the operation to match the growth of the normal side (Figure 4).



**Figure 1.** The patient presentation on her first visit to our clinic. The clinical findings revealed a tube-like projection on the left medial canthal region, nasal agenesis on the ipsilateral side, and severe asymmetry in the orbital region. The patient suffered from visual loss on the affected side.

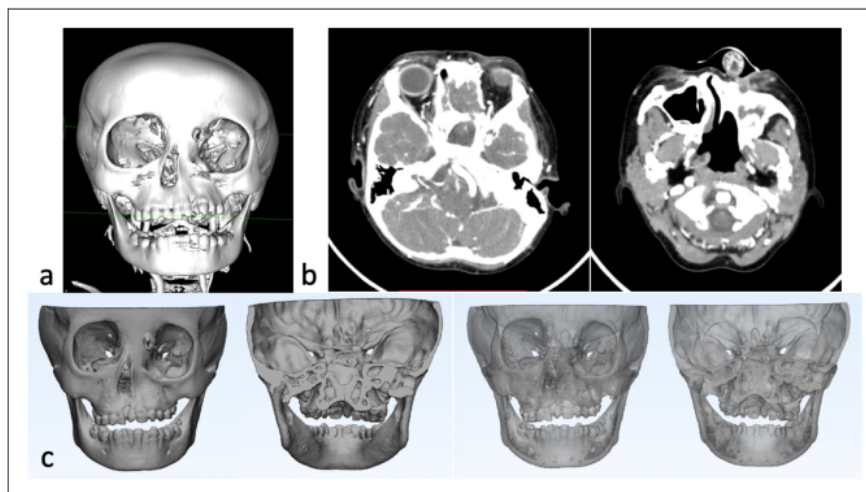
One year afterward, the patient was summoned back to our clinic to undergo the third operation. It involved nasal reconstruction using a costal cartilage graft to create a dorsal nasal and alar framework. The cartilage graft was harvested from the costae and carved from the alar and dorsal nasal support (Figure 5).

After the operation, the patient healed with no complications and was discharged 3 days postoperatively. At a later date, we established communication with her and her family to evaluate the operation results and her overall well-being. One year follow-up, the parents reported that she had become less reserved, more confident with her appearance (Figure 5) and her grades improved significantly after the operation. Video samples of her interacting showed a much more cheerful child.

The patient was scheduled for a further appointment at the clinic to be evaluated for eye evaluation, growth distortion, and the resulting facial asymmetry. Surgical correction will be planned thereafter to further reconstruct the facial features.

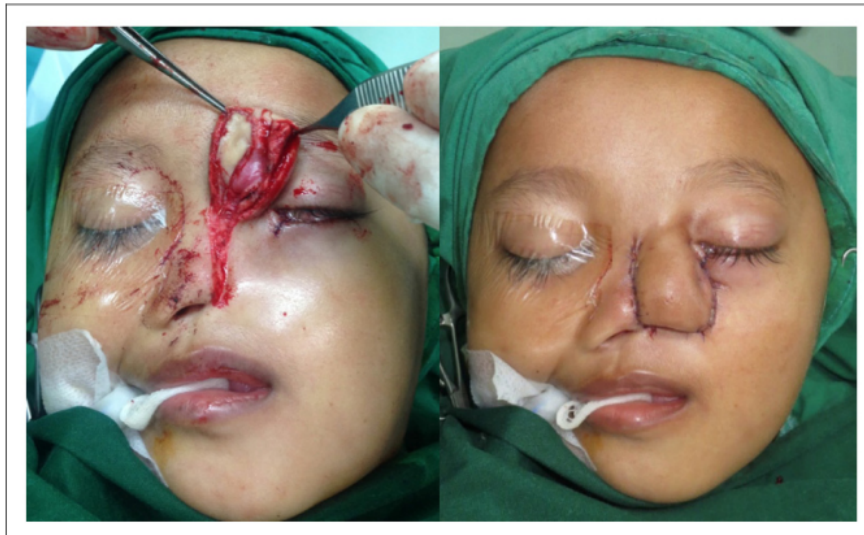### Discussion

The description of the lateral proboscis in the current literature is still limited. Among all the evidence we encountered in the literature, most case reports describe patients of American, European, African, and Middle Eastern origin. A number of cases have also been presented in India. However, up until now, there had been no evidence describing patients of East Asian origin.



**Figure 2.** (a) The 3D rendering of the computed tomography (CT) scan of the head showed absence of the left nasal aperture. (b) There was a defect in the sella turcica and herniation of the meninges and CSF. The proboscis appeared as a tubular mass on the left side with an underdeveloped maxillary sinus. (c) There was no intracranial communication through the bony projection in the medial canthal area.





**Figure 3.** The first stage surgery. (Left) The proboscis was incised on the posteromedial side. The lining was skin grafted and the implantation site was de-epithelialized. (Right) The postoperative result.

The diagnosis and management of lateral proboscis is concisely summarized in Figure 6. The diagnosis is most important clinical, although adjuvant diagnostic tests are of value in evaluating concurrent abnormalities. The mainstay treatment of lateral proboscis is surgery, although the reconstructive options vary according to the patient's needs and the clinical spectrum of the disease.

The role of the nasal placode in the development of the lateral proboscis remains at the center of our attention. The pathology that leads to aberration of the medial and lateral processes may lead to the findings of absent olfactory bulb and olfactory sulcus on the affected side (Vaid et al., 2010). Before corrective surgery, CT and magnetic resonance imaging (MRI) should be performed to examine the connection of the lesion with neighboring structures and to present the precise anatomy, as well as to identify any brain abnormalities (Belet et al., 2002). We have not yet carried out MRI scanning on our patient, but we are looking forward to elucidating this pathology using MRI in the foreseeable future.

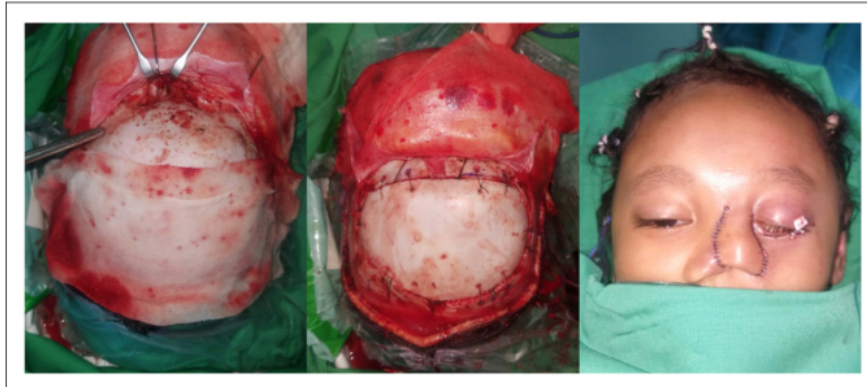
According to classification by Sakamoto et al. (2012), our patient belongs to Group V due to the presence of a possible encephalocele remnant on the base of the proboscis. We sent the excised tissue for pathologic examination. The result showed that it is consistent with nasofrontal sinus tissue without any other findings. Nevertheless, we cannot dismiss the possibility of any intracranial communication, especially when the tissue was attached to the meninges during intracranial exploration.

Surgical methods will differ based on the location of the tube, its length, and the amount of nasal hypoplasia (Bowe, 1986). The proboscis is a useful source of tissue donors for the reconstruction of the nose, it has a texture and a plentiful

blood supply (Galie et al., 2019). Some surgeons utilized the lateral proboscis without altering it to form a nostril, while others opened it up to expand its size and produce a more aesthetically attractive look (Jost et al., 1995). Popular recommendations regarding lateral proboscis reconstruction include, first, removing the proboscis, reconstructing it using local tubed flaps, and then grafting bone afterward. Second, the tunneling method described as the de-epithelialized proboscis is transmitted subcutaneously via a transverse pedicled flap in the future nasal area. The third and most common approach is to divide the proboscis in a variety of patterns over its whole length and connect the resultant convex disk to the normal side (Boo-Chai, 1985).

Some studies managed a case of lateral proboscis by incising the proboscis along with its length at its medial border and implanting it into the underdeveloped right nose (Agarwal and Latta, 2010; Magadum et al., 2012). After decortication, D'assumpção (1975) implanted the inferior edge of the proboscis into a large enough raw area formed on the edge of the nasal pyramid to accommodate the ectopic nostril. Similar to it, Galie et al. (2019) completely de-epithelialized the ventral tube except for the distal section, which served as the donor site, and the skin beneath the proboscis, which served as the receiver site. The donor flap was relocated and parallel sutured to the recipient site, opposing the 2 de-epithelialized areas.

Vyas et al. (2003) chose staged surgery, first splitting the proboscis and attaching the lower end to the side of the normal nose, then transferring and attaching the top end at the root of the nose. Seventeen years later, the patient returned with the groove and saddle deformities, with the intention of correcting the malformations. Similar to the previous

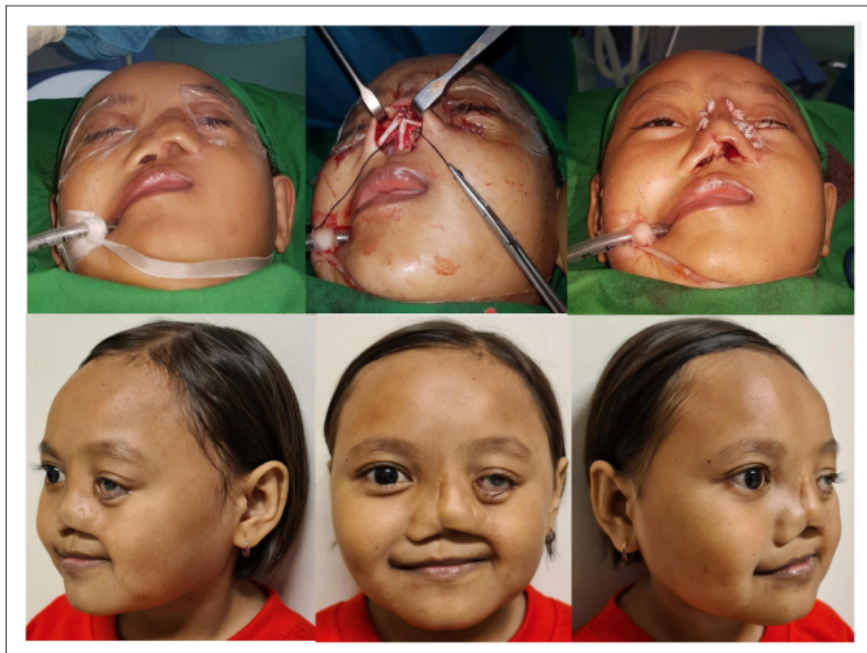

**Figure 4.** The second stage surgery. (Left) The bony protrusion and rudimentary tissue at the base of the proboscis were shown. (Center) A picture showing replacement of the craniotomy segments and the pericranial flap. (Right) Postoperative result.

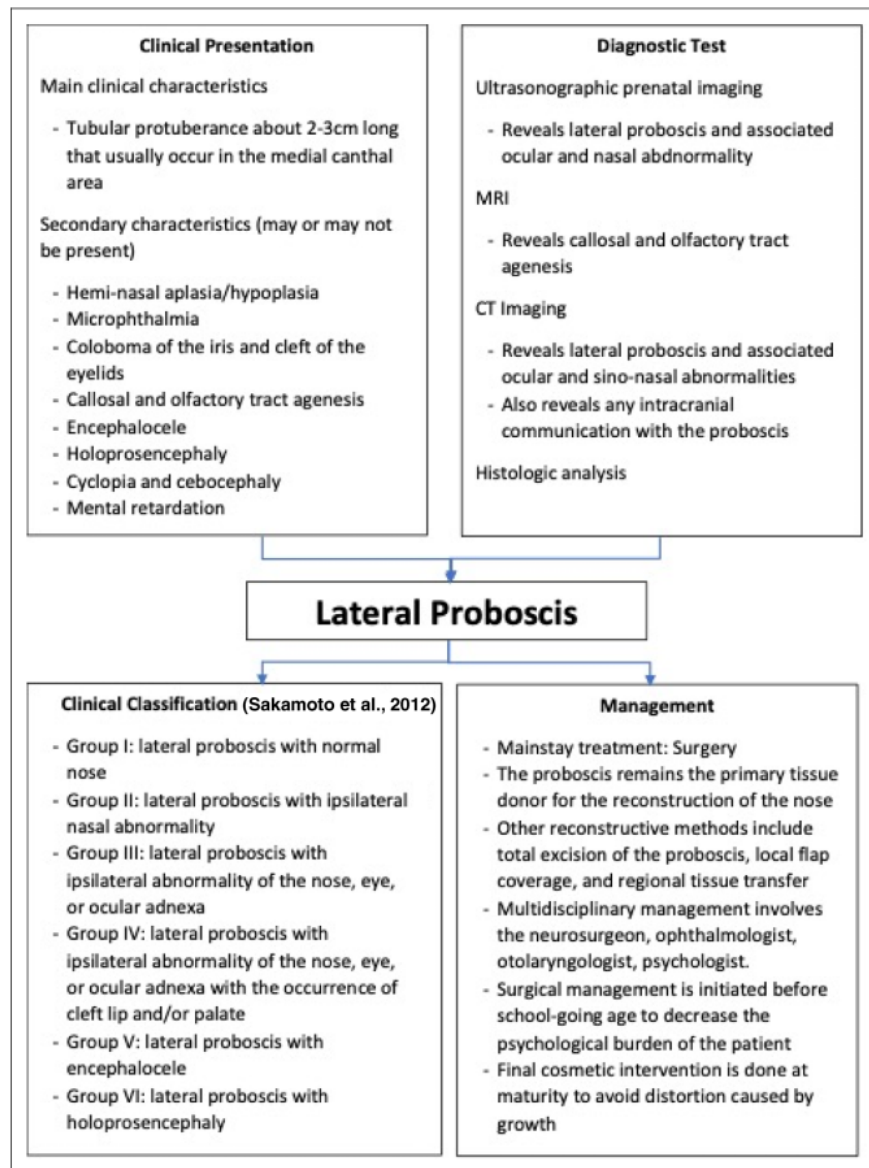
technique, Boahene et al. (2005) de-epithelialized the medial segment of the proboscis and a matching area on the normal side after splitting it along with its ventral surface. The nasal base width was measured from the normal side, and the medial and lateral proboscis segments were embedded in the de-epithelialized area. Hassani et al. (2014) used 2 flaps to repair the lateral proboscis. The first medial pedicled flap was rebuilt using skin from the face underneath the proboscis, while the second flap was de-epithelialized from the lateral half

of the proboscis. Following that, the second flap was sutured to the nasal septum beneath the first flap.

Some authors utilized the subcutaneous tunnel technique by gradually burying the de-epithelialized proboscis beneath the transverse bipedicled flap and in the final stage, correcting the alar rim, alar base, and nasal tip with excisions and Z plasty (Chong and Cramer, 1978; Singh et al., 2001; Eroğlu and Uysal, 2003). One drawback of this technique is the narrow opening of the nose. Boo-Chai (1985) suggests dilation



**Figure 5.** Above: The third stage surgery. (Left) Preoperative picture. (Centre) Implantation of cartilage framework. (Right) Postoperative results. Below: One year followed-up after the third surgery.



**Figure 6.** Diagnosis, classification, and management of lateral proboscis.

of the proboscis prior to beginning repair to avoid a narrow nostril. However, this will necessitate repeated dilatations at regular intervals and can lead to loss of elasticity of the proboscis (Vyas et al., 2003).

14. Acarturk et al. (2006) reported 2 cases of lateral proboscis reconstruction. In the first case, the proboscis was repaired by implanting de-epithelialized tissue into a raw area corresponding to the future nasal area. In the second case, the proboscis was degloved of its epithelium and tunneled subcutaneously, emerging near the opposing nostril. Thirteen

years after the surgery in the first case, there was a nasal deformity, but the patient declined further treatment.

In the first stage, we performed de-epithelialization of the ventromedial side of the proboscis, removing the bulky mucosal part, then covering it with a skin graft. Therefore, it wouldn't need a prior dilation, in contrast to Boo-Chai (1985). In the second stage, we closed the remaining bone defect using a pericranial flap and reconstructed the attached proboscis to match the growth of the normal side. Bone and cartilage grafts are required to support the nasal framework



(Martin et al., 2013), hence in the third stage, we created a structural framework for the newly constructed nose. Significant projection of the nose was achieved. A study used multiple bone graft procedures from ribs, iliac, and cranial bone to improve the appearance (David et al., 2008). Depending on the underlying anomalies, the reconstructive method must be tailored to each patient.

There were limited sources that evaluated the effects of surgery on the psychological well-being of patients with lateral proboscis. A report by Kirkpatrick (1970) revealed a case of proboscis showing a dissatisfied boy who was violent and jealous of other children. Therefore, an early repair is preferred. Overcorrection is recommended in the expectation that the growth of the normal side will be higher than the growth of the affected side, reducing the need for recurrent modifications. David et al. (2008) repaired a lateral proboscis case with 15 major surgeries, including bone grafts, to enhance the patient's appearance. The patient had grown bored of surgery and had accepted a less-than-ideal clinical outcome. Despite this, the patient graduated from college, obtained a full-time job, and is completely functional in society. They demonstrated that effective long-term surgical treatment planning combined with critical continuous reevaluation can result in an acceptable clinical outcome in terms of both anesthetic and functional outcomes.

Our patient was operated on as soon as possible after her first visit to the clinic. She was already pursuing school at that time and carrying out surgery was an urgent matter in order to alleviate her psychological burden of peer pressure. After the third surgery, the parents reported significant improvement in the patient's school grade. The patient was seen happier, more confident, and livelier. The patient is currently closely monitored through communication with her parents. We are planning further surgeries for better function and appearance, but they are being postponed because of the COVID pandemic. Subsequent follow-up will be planned until she reaches maturity.

## Conclusion

Only several cases of lateral proboscis have been reported in the current literature. Further evaluation of our patient is necessary to explore possible clinical outcomes and corresponding treatment options. Aesthetic modification will be scheduled when the nose and other facial features have matured. Multidisciplinary management involving the plastic surgeon, the neurosurgeon, the ophthalmologist, and the pediatric psychologist will be continued.



## Declaration of Conflicting Interests

The author(s) declared no potential conflicts of interest with respect to the research, authorship, and/or publication of this article.

## Funding

The author(s) received no financial support for the research, authorship and/or publication of this article.

## ORCID iDs

Indri Lakhsmi Putri  <https://orcid.org/0000-0001-6668-6496>  
Djoko Kuswanto  <https://orcid.org/0000-0003-4062-2237>

## References

- Abou-Elhamd KEA. Proboscis lateralis: a report of two cases. *Int J Pediatr Otorhinolaryngol*. 2004;68(4):503-505. doi:10.1016/j.ijporl.2003.11.021
- Acarturk S, Kivanc K, Atilla E, Sekucoglu T. Proboscis lateralis: evaluation of the anomaly and a review of two cases. *Plast Reconstr Surg*. 2006;117(7):140e-146e. doi:10.1097/01.prs.0000218801.38826.31
- Agarwal S, Latta S. Proboscis lateralis. *Indian J Otolaryngol Head Neck Surg*. 2010;62(1):79-80. doi:10.1007/s12070-010-0014-8
- Ajike SO, Mohammed R, Johnson AO, Chaha K, Samaila MO. Lateral Proboscis (Elephant Tusk) with Orofacial Clefts: A Report of a Rare Case. *Case Rep Pediatr*. 2018; 2018:6820972. doi:10.1155/2018/6820972. PMID: 30363727; PMCID: PMC6180999.
- Antonades K, Baraister M. Proboscis lateralis: a case report. *Teratology*. 1989;40(3):193-197. doi:10.1002/tera.1420400302
- Belet N, Belet U, Tekat A, Küçüködük U. Proboscis lateralis: radiological evaluation. *Pediatr Radiol*. 2002;32(2):99-101. doi:10.1007/s00247-001-0602-6
- Biber JJ. Proboscis lateralis: a rare malformation of the nose its genesis and treatment. *J Laryngol Otol*. 1949;63(12):734-741. doi:10.1001/s0022215100047125
- Bishop BW. Lateral nasal proboscis. *Br J Plast Surg*. 1964;17:18-21. doi:10.1016/s0007-1226(64)80004-7. PMID: 14103347.
- Boahene DKO, Bartley GB, Clay RP, Thompson DM. Heminasal proboscis with associated microphthalmos and encephalocele. *J Craniofac Surg*. 2005;16(2):300-306. doi:10.1097/00001665-200503000-00018
- Boo-Chai K. The proboscis lateralis—a 14-year follow-up. *Plast Reconstr Surg*. 1985;75(4):569-577.
- Bowe JJ. Lateral nasal proboscis. *Ann Plast Surg*. 1986;16(3):250-252. PMID: 3273040.
- Chauhan DS, Guruprasad Y. Proboscis lateralis. *J Maxillofac Oral Surg*. 2010;9(2):162-165. doi:10.1007/s12663-010-0046-3
- Chong JK, Cramer LM. Proboscis lateralis: staged management with a four-year follow-up. *Ann Plast Surg*. 1978;1(2):225-228.
- D'assumpção EA. Proboscis lateralis. Case report. *Plast Reconstr Surg*. 1975;55(4):494-497.
- David LR, Sanger C, Fisher D, Argenta LC. Proboscis lateralis: a rare craniofacial anomaly, reconstruction, and long-term evaluation. *J Craniofac Surg*. 2008;19(4):1107-1113. doi:10.1097/SCS.0b013e318176ac9f
- Eroğlu L, Uysal OA. Proboscis lateralis: report of two cases. *Br J Plast Surg*. 2003;56(7):704-708. doi:10.1016/s0007-1226(03)00356-4
- Galiè M, Clauser LC, Tieghi R, Kawamoto HK, Wolfe SA, Bianchi AE. The arhinias: proboscis lateralis literature review and surgical update. *J Craniomaxillofac Surg*. 2019;47(9):1410-1413. doi:10.1016/j.jcms.2018.12.013

- Hassani ME, Karimi H, Hassani H, Hassani A, Jalili-Manesh M. Heminasal proboscis, a rare craniofacial cleft. *J Craniofac Surg*. 2014;25(1):e7-e9. doi:10.1097/SCS.0b013e3182a2ec3a
- Jost G, Mookherjee R, Dionyssopoulos A. Proboscis lateralis: treatment of two atypical cases. *Aesthetic Plast Surg*. 1995;19(2):165-168. doi:10.1007/BF00450253
- Kirkpatrick TJ. Lateral nasal proboscis. *J Laryngol Otol*. 1970;84(1):83-89. doi:10.1017/s0022215100071668
- Magadum SB, Khairmar P, Hirugade S, Kassa V. Proboscis lateralis of nose—a case report. *Indian J Surg*. 2012;74(2):181-183. doi:10.1007/s12262-011-0279-5
- Martin S, Hogan E, Sorenson EP, Cohen-Gadol AA, Tubbs RS, Loukas M. Proboscis lateralis. *Childs Nerv Syst*. 2013;29(6):885-891. doi:10.1007/s00381-012-1989-0
- Meeker LH, Aebli R. Cyclopean eye and lateral proboscis with normal one-half face: report of a case. *Arch Ophthalmol*. 1947;38(2):159-173. doi:10.1001/archophth.1947.00900010164003
- Mehta L, Petrikovsky B, Tydings L, Lundberg J. Lateral nasal proboscis: antenatal diagnosis and counseling. *Obstet Gynecol*. 1999;94(5 Suppl. 1):815-817. doi:10.1016/S0029-7844(99)00328-2
- Sakamoto Y, Miyamoto J, Nakajima H, Kishi K. New classification scheme of proboscis lateralis based on a review of 50 cases. *Cleft Palate Craniofac J*. 2012;49(2):201-207. doi:10.1597/10-127.1
- Sakamoto Y, Nakajima T, Miyamoto J. A rare case of proboscis lateralis with median cleft lip. *Cleft Palate Craniofac J*. 2010;47(5):553-556. doi:10.1597/09-117
- Schinzel A, Savoldelli G, Briner J, Schmid W. Prenatal ultrasonographic diagnosis of holoprosencephaly two cases of cebocephaly and two of cyclopia. *Arch Gynecol*. 1984;236(1):47-53. doi:10.1007/BF02114868
- Singh I, Gathwala G, Kalra GS, Malhotra V. Proboscis lateralis of nose. *Indian J Pediatr*. 2001;68(5):467-468. doi:10.1007/BF02723031
- Vaid S, Shah D, Rawat S, Shukla R. Proboscis lateralis with ipsilateral sinonasal and olfactory pathway aplasia. *J Pediatr Surg*. 2010;45(2):453-456. doi:10.1016/j.jpedsurg.2009.10.044
- Verma P, Pal M, Goel A, Singh I, Bansal V. Proboscis lateralis: case report and overview. *Indian J Otolaryngol Head Neck Surg*. 2011;63(Suppl 1):36-37. doi:10.1007/s12070-011-0182-1
- Vyas UH, Raibagkar SC, Vora H, Bhavsar D. Case Report—Proboscis lateralis—A 17 years follow-up, a case report. 2003.

# A Case Report on Lateral Proboscis : A Rare Congenital Anomaly

## ORIGINALITY REPORT

14%

SIMILARITY INDEX

9%

INTERNET SOURCES

13%

PUBLICATIONS

3%

STUDENT PAPERS

## PRIMARY SOURCES

1	<a href="http://www.researchgate.net">www.researchgate.net</a> Internet Source	2%
2	<a href="http://link.springer.com">link.springer.com</a> Internet Source	1%
3	<a href="http://jcdr.net">jcdr.net</a> Internet Source	1%
4	Mohammad Esmail Hassani, Hamid Karimi, Hosein Hassani, Ali Hassani, Mohammad Jalili-Manesh. "Heminasal Proboscis, A Rare Craniofacial Cleft", Journal of Craniofacial Surgery, 2014 Publication	1%
5	Sanjay Vaid, Darshan Shah, Sudarshan Rawat, Rahul Shukla. "Proboscis lateralis with ipsilateral sinonasal and olfactory pathway aplasia", Journal of Pediatric Surgery, 2010 Publication	1%
6	<a href="http://ir.unilag.edu.ng">ir.unilag.edu.ng</a> Internet Source	1%



7	Submitted to Central Queensland University Student Paper	1 %
8	www.aijcr.com Internet Source	1 %
9	Indri Lakshmi Putri, Lavonia Berlina Adzalika, Rachmaniar Pramanasari, Citrawati Dyah Kencono Wungu. "Negative pressure wound therapy versus conventional wound care in cancer surgical wounds: A meta - analysis of observational studies and randomised controlled trials", International Wound Journal, 2022 Publication	1 %
10	S. Martin, E. Hogan, E. P. Sorenson, A. A. Cohen-Gadol, R. S. Tubbs, M. Loukas. "Proboscis lateralis", Child's Nervous System, 2013 Publication	1 %
11	"All Around the Nose", Springer Science and Business Media LLC, 2020 Publication	1 %
12	Garima Arora, Vipin Arora, Deepak Chawla. "Proboscis Lateralis-Like Appendage", Annals of Plastic Surgery, 2011 Publication	1 %
13	journal.um-surabaya.ac.id Internet Source	<1 %

14	<a href="http://www.thieme-connect.com">www.thieme-connect.com</a> Internet Source	<1 %
15	Tedy Apriawan, Abdul Hafid Bajamal, Yusuf Hermawan, Fitra Fitra et al. "Three-dimensional (3D)-printed model reconstruction in pre-operative planning for wooden penetrating brain injury", Bioprinting, 2021 Publication	<1 %
16	<a href="https://insights.ovid.com">insights.ovid.com</a> Internet Source	<1 %
17	Derek Kofi O. Boahene, George B. Bartley, Ricky P. Clay, Dana M. Thompson. "Heminasal Proboscis With Associated Microphthalmos and Encephalocele", Journal of Craniofacial Surgery, 2005 Publication	<1 %
18	<a href="http://bmcpediatr.biomedcentral.com">bmcpediatr.biomedcentral.com</a> Internet Source	<1 %
19	<a href="http://www.jeehp.org">www.jeehp.org</a> Internet Source	<1 %
20	<a href="http://www.omicsonline.org">www.omicsonline.org</a> Internet Source	<1 %
21	Kamal-Eldin Ahmed Abou-Elhamd, Mohammad Tharwat Al-Hewaige. "Proboscis	<1 %

lateralis: clinical and radiological features",  
The Journal of Laryngology & Otology, 2006

Publication

22

[docplayer.net](http://docplayer.net)

Internet Source

<1 %

23

[medical-dictionary.thefreedictionary.com](http://medical-dictionary.thefreedictionary.com)

Internet Source

<1 %

24

[www.ajnr.org](http://www.ajnr.org)

Internet Source

<1 %

25

"Liposuction", Springer Science and Business  
Media LLC, 2016

Publication

<1 %

26

David P. Kuehn, Karlind T. Moller. "Speech  
and Language Issues in the Cleft Palate  
Population: The State of the Art", The Cleft  
Palate-Craniofacial Journal, 2017

Publication

<1 %

27

Gary J. Lelli, Elizabeth A. Maher, James P.  
Milite, Robin Dyleski. "Proboscis Lateralis",  
Ophthalmic Plastic & Reconstructive Surgery,  
2008

Publication

<1 %

28

Shyam Gattani, Xiangyang Ju, Toby Gillgrass,  
Aileen Bell, Ashraf Ayoub. "An Innovative  
Assessment of the Dynamics of Facial  
Movements in Surgically Managed Unilateral

<1 %



# Cleft Lip and Palate Using 4D Imaging", The Cleft Palate-Craniofacial Journal, 2020

Publication

---

29

Submitted to Western Governors University

Student Paper

<1 %

---

30

J. J. Biber. "Proboscis Lateralis: A Rare Malformation of the Nose its Genesis and Treatment", The Journal of Laryngology & Otology, 2007

Publication

<1 %

---

31

Jamie Funamura, Travis Tollefson. "Congenital Anomalies of the Nose", Facial Plastic Surgery, 2016

Publication

<1 %

---

Exclude quotes Off

Exclude matches Off

Exclude bibliography On

# A Case Report on Lateral Proboscis : A Rare Congenital Anomaly

---

## GRADEMARK REPORT

---

FINAL GRADE

**/0**

GENERAL COMMENTS

**Instructor**

---

PAGE 1

---

PAGE 2

---

PAGE 3

---

PAGE 4

---

PAGE 5

---

PAGE 6

---

PAGE 7

---

PAGE 8

---

PAGE 9

---