

# Columella Reconstruction Using Double Nasolabial Flap And Costal Cartilage: A Case Report

*by* Indri Lakhsmi Putri

---

**Submission date:** 07-Apr-2023 04:24PM (UTC+0800)

**Submission ID:** 2058267723

**File name:** ng\_double\_nasolabial\_flap\_and\_costal\_cartilage\_A\_case\_report.pdf (1.76M)

**Word count:** 2483

**Character count:** 13647



Contents lists available at ScienceDirect

Annals of Medicine and Surgery

journal homepage: [www.elsevier.com/locate/amsu](http://www.elsevier.com/locate/amsu)



Case Report

# Columella reconstruction using double nasolabial flap and costal cartilage: A case report



Indri Lakhsmi Putri<sup>\*</sup>, Wilma Agustina, Magda Rosalina Hutagalung

*Department of Plastic Reconstructive and Aesthetic Surgery, Faculty of Medicine, Airlangga University, Surabaya, East Java, Indonesia*

## ARTICLE INFO

**Keywords:**  
Columella reconstruction  
Noma  
Double nasolabial flap

## ABSTRACT

Total loss of columella causes significant aesthetic and functional deformities due to its important functions which provides assistance and extension to the nose pointer. Noma is described as one of the developed sources of total columellar loss, and is also contagious, with the ability to intensely damage facial tissues and immediate structures. However, the condition is predominantly suffered in Africa, with an estimation of 20 instances per 100,000 individuals. Furthermore, the reformation of a columellar disorder offers a complex process, due to the structural features of the location.

A 24-year-old female patient with total columellar loss caused by Noma. We performed a two stage reconstruction. First, we used double nasolabial flaps to create a new columella. Second, we inserted costal cartilage and dermofat graft to support it.

The double nasolabial flap demonstrated 100% survival. Both nasal airway and the final appearance showed functionally and cosmetically remarkable results. The nasolabial angle projected better than the preoperative measurement. The patient was satisfied. The patient was followed up until a year after surgery.

The double nasolabial flaps combined with costal cartilage graft is one of the best surgical options to obtain astonishing columellar reconstruction.

## 1. Introduction

The columella is a fundamental part of nasal elements. It connects nasal tip and philtrum in the central part of the face. It consists cartilage and soft tissue component. It covers the inferior portion of the cartilaginous nasal septum. Septal cartilage and medial crus form the columellar cartilaginous structure. Based on aesthetic, columella appears as a very vital facial constituent. The structure delivers comfort and extension to the nose pointer. In essence, columellar defects tend to instigate significant visual appearance and functional abnormalities [1, 2].

Noma comes from the greek word which definitions 'to devour', also known as cancrum oris, and refers to an improper expression of the Latin term 'cancer oris' introduced into Great Britain in the 17th century [3]. It is an necrotizing infectious disease that destroys and mutilates the oro-facial tissues and surrounding structures in its fulminating view, and lethal if not promptly treated. Noma is the consequence of excess bacterial load of common micro-organisms in the mouth contributing to immune system breakdown. This further leads to the rapid spread of

infections with potentials to damage facial tissues or instigate severe disfigurement [4-7]. Facial disfigurement leads to psycho-social concerns that will impact the quality of life of Noma survivors.

Columella defect reconstruction remains a challenging procedure for surgeons, due to the anatomic site features. It is the most difficult off all nasal components to reconstruct [8]. Several techniques are readily available to treat the disorder, including grafts, local and free flaps. Composite graft is suggested if the size of defect <15 mm and Flaps are suggested if the size of defect >15 mm [9]. A number of author proposed columella reconstruction using nasolabial flap [9-13], it offers an option to close large columella defect in one stage, although the next stage is still often needed to achieve optimal aesthetic results. This case report has been reported in line with the SCARE Criteria [14].

## 2. Case presentation

A twenty-four-year old female presented to our clinic for reconstruction of a total columellar loss after suffering Noma at her youth, no surgical procedure was performed previously. She lived in rural areas

<sup>\*</sup> Corresponding author.

E-mail addresses: [indrilakhsmiputri@fk.unair.ac.id](mailto:indrilakhsmiputri@fk.unair.ac.id) (I.L. Putri), [wilmaagustina@gmail.com](mailto:wilmaagustina@gmail.com) (W. Agustina), [magdahutagalung@rocketmail.com](mailto:magdahutagalung@rocketmail.com) (M.R. Hutagalung).

<https://doi.org/10.1016/j.amsu.2021.102213>

Received 27 January 2021; Received in revised form 2 March 2021; Accepted 3 March 2021

Available online 13 March 2021

2049-0801/© 2021 The Authors. Published by Elsevier Ltd on behalf of IJS Publishing Group Ltd. This is an open access article under the CC BY-NC-ND license

<http://creativecommons.org/licenses/by-nc-nd/4.0/>

with limited access to healthcare service, came from low socioeconomic status and not well-educated. She complained the obvious columellar deformity. There were no left nasal floor and columella. There were thickness distinction and asymmetry of the left and right soft tissue. The left philtrum ridge was retracted due to the scar.

We performed two stages of surgery. The first surgery was to perform a double nasolabial flap (Fig. 1). Furthermore, the flap incision commences at the distal section adjacent of the nasal ala, and continues in a parallel direction along the melolabial fold. In addition, the individual flap width equates half the breadth of the defect. We incised the flap with ratio 4:1. After undermined the skin from the tissue beneath, we elevated the flap and transposed it to cover the defect.

Refinement was performed in second surgery (Fig. 2), inserting costal cartilage and dermofat graft. The costal cartilage graft from the 6th and 7th ribs was performed to restore and support the nose while dermofat graft taken from inguinal area was performed to fill the thickness distinction between left and right soft tissue. The length of the incision was adjusted to the amount we need to fill the defect. As the final touch the dermofat graft then inserted to the defect area. Both surgery were performed by craniofacial surgeons with 5 and 10 years of experience. The patient was discharged in both surgery 3 days post-op.

### 3. Results

The double nasolabial flap demonstrated 100% survival. There is no infection at the site of surgery. Both nasal airway and the final appearance (Fig. 3) were functionally and cosmetically acceptable. Post-op nasolabial angle is 90°, projected better than the pre-op with absent of columella. The patient was satisfied. The patient was followed up in outpatient clinic at one week, two weeks, a month, 3 months, 6 months and a year after surgery.

### 4. Discussion

Columellar defect restructuring poses a disturbance, due to a more complicated anatomic configuration and position. The columella is situated between the nostrils and exceeds the caudal site of septal cartilage, and is also comprised of a pair of fine-textured crural cartilages and thin skin covering [1,2]. Therefore, the tissues applied during reconstruction are expected to match the anatomic specifications, including skin and cartilage. Highly consideration in columellar reconstruction are adequate height of the columella so that the ideal nasal tip projection is achieved and adequate width and thickness of the columella so that airway obstruction does not occur. Another challenge is the feature of the location, which will make it very obvious, if there is a defect.

Composite grafts are useful for small alar rim and columellar defects, as well as contain at least two types of tissues, particularly skin and

cartilage [15,16]. These conditions are similar to simple skin grafts, but with less contraction, although, are also extremely reliable. However, certain limitations of composite grafts include, inadequate thickness and less application where strict tissue matching is demanded. Furthermore, the donor site of the cavum conchae [15] or retro-auricular area [] appears relatively concealed. Bergel et al. mentioned composite graft was the best option in treating columellar defect smaller than 10mm [9].

Alar rim flap can be considered as another option to restore the columellar defect [18]. The flaps are elevated and pivoted on the medially based pedicles, and then are jointly sealed to form the neo-columella. During the second phase, the opposite ala is possibly adjusted to match the general structure of the donor site. However, this flap has disadvantage that was the obvious scar results. It also made an asymmetrical appearance between alae that was used as a donor and another alae.

Forehead flap can be performed as an option also to restore columellar defect, but keep in mind the main disadvantage is the prominent donor scar [19].

Nasolabial flap has been used in columellar reconstruction resulting a decent color and texture match together with less noticeable donor scar. The original nasolabial flap occurs as a pure random transposition flap intended for a multi-staged process [19]. Several design modifications have produced a more simpler single-stage technique, with minimal complications or need for revisional surgery. The preferred single-stage nasolabial flap is designed primarily as a sliding cheek extension. Bilateral flaps may be required for adequate coverage. Nakamura et al. successfully used double nasolabial flap and auricular cartilage graft to reconstruct a mucoepidermoid carcinoma of the columella following surgical resection [8].

In this case multistaged surgery were performed. First, the double nasolabial flap to close the defect and mold the columella shape, double nasolabial flaps were transferred through transnasal route. Second, the 6th and 7th costal cartilage were harvested and inserted to support the columellar shape and projection, and dermofat grafts were harvested and inserted to augment left soft tissue in order to eliminate thickness distinction between left and right soft tissue. Preferring costal cartilage despite of auricular cartilage in this case is due to the need for a large cartilage donor and the need for stronger support to achieved fine nasal tip projection. Comparing to the other technique, this technique are simple, quick, easy to performed, has a trustworthy vascularization, matching color and hidden scar.

### 5. Conclusion

In conclusion, we propose that double nasolabial flap followed by costal cartilage graft can be a better option for columellar reconstruction. This technique is easy to performed resulting a decent color and

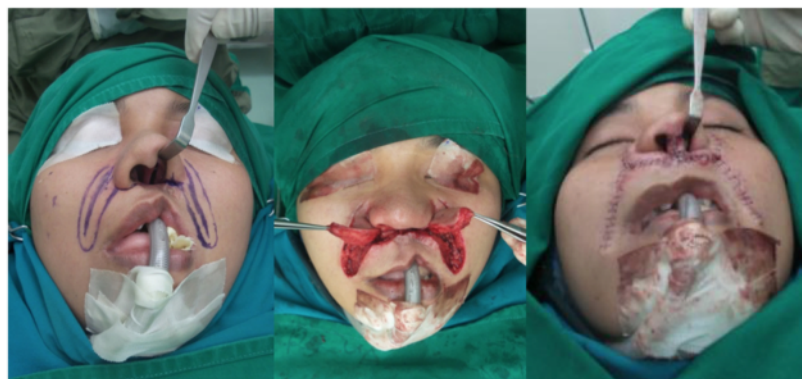

Fig. 1. Design of incision (Left), elevation of flap (center), flap transposition (Right).

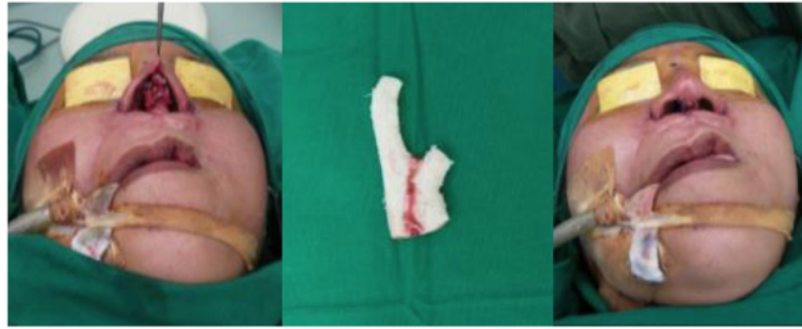

Fig. 2. Open rhinoplasty approach (left), 6th costal cartilage graft (center), post-op result (Right).

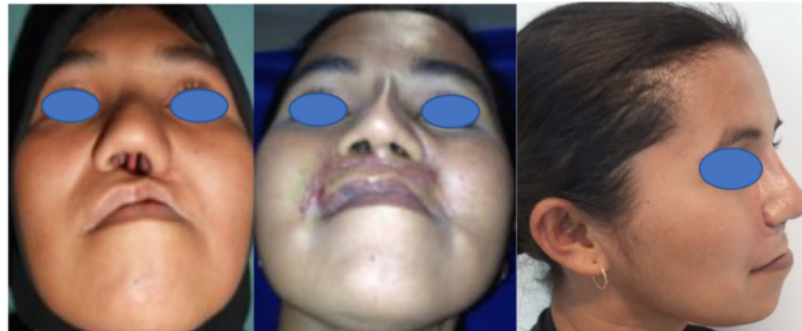


Fig. 3. Pre-op (left) and 1 year post op (center & right) pictures of patient.

texture match together with less noticeable donor scar and a better post-op nasolabial angle.

#### Ethical approval

It is declared in the written informed consent that patient data will be used for educational and research purposes. Our institution does not provide an ethical approval in the form of case report.

#### Source of funding

No funding source to declare.

#### Author contribution

Indri Lakhsmi Putri: Study concept, resources, data analysis, writing-review & editing, final approval of the version to be submitted. Wilma Agustina: Data collection, data analysis, writing-original draft. Magda Hutagalung: Resources. Registration of Research Studies.

#### Research registration number

This is not a 'first in humans' report, so it is not in need of registration.

#### Guarantor

Indri Lakhsmi Putri.

#### Consent

Written informed consent was obtained from the patient for publication of this case report and accompanying images. A copy of the written consent is available for review by the Editor-in-Chief of this journal on request.

#### Provenance and peer review

Not commissioned, externally peer reviewed.

#### Declaration of competing interest

No potential conflict of interest.

#### Acknowledgements

We thank patient and the staff who were engaged in the surgery and patient care.

#### Appendix A. Supplementary data

Supplementary data to this article can be found online at <https://doi.org/10.1016/j.amsu.2021.102213>.

#### References

- [1] U. Bilkay, C. Tokat, C. Ozek, O. Erdem, A. Cagdas, Reconstruction of congenital absent columella, *J. Craniofac. Surg.* 15 (1) (2004) 60–63, <https://doi.org/10.1097/00001665-200401000-00018>.
- [2] C. Ozek, H. Gundogan, U. Bilkay, M. Alper, A. Cagdas, Nasal columella reconstruction with a composite free flap from the root of auricular helix, *Microsurgery* 22 (2) (2002) 53–56, <https://doi.org/10.1002/micr.21724>.

- [3] L. Feller, R.A.G. Khammissa, M. Altini, J. Lemmer, Noma (cancerum oris): an unresolved global challenge, *Periodontol* 2000 80 (1) (2019) 189–199, <https://doi.org/10.1111/prd.12275>.
- [4] M.N. Tempest, *Cancerum oris*, *Br. J. Surg.* 53 (11) (1966) 949–969, <https://doi.org/10.1002/bjbs.1800531109>.
- [5] C.O. Enwonwu, Epidemiological and biochemical studies of necrotizing ulcerative gingivitis and noma (cancerum oris) in Nigerian children, *Arch. Oral Biol.* 17 (9) (1972) 1357–1371, [https://doi.org/10.1016/0003-9969\(72\)90169-0](https://doi.org/10.1016/0003-9969(72)90169-0).
- [6] C.O. Enwonwu, Noma: a neglected scourge of children in sub-Saharan Africa, *Bull World Health Organ* 73 (4) (1995) 541–545.
- [7] D.E. Barmes, C.O. Enwonwu, M.H. Leclercq, D. Bourgeois, W.A. Falkler, The need for action against oro-facial gangrene (noma), *Trop. Med. Int. Health* 2 (12) (1997) 1111–1114, <https://doi.org/10.1046/j.1365-3156.1997.d01-220.x>.
- [8] Y. Nakamura, Y. Nakamura, A. Saito, Y. Fujisawa, Y. Kawachi, F. Otsuka, High-grade mucocutaneous carcinoma of the columella successfully reconstructed using bilateral nasolabial flaps set up in a sandwich shape and an auricular cartilage graft after surgical resection, *J. Dermatol.* 40 (11) (2013) 911–914, <https://doi.org/10.1111/1346-8138.12274>.
- [9] C. Bergel, A. Alshukry, N. Kerfant, C. Philandrianos, J. Bardot, D. Casanova, B. Bertrand, Reconstruction of columellar defects: Which surgical technique to choose? A retrospective study of 18 patients, *J Plast Reconstr Aesthetic Surg* 71 (11) (2018) 1664–1678, <https://doi.org/10.1016/j.bjps.2018.07.019>.
- [10] D.R. Wesser, G.B. Burt Jr, Nasolabial flap for losses of the nasal ala and columella. Case report, *Plast. Reconstr. Surg.* 44 (3) (1969) 300–302, <https://doi.org/10.1097/00006534-196909000-00021>.
- [11] G. Da Silva, A new method of reconstructing the columella with a nasolabial flap, *Plast. Reconstr. Surg.* 34 (1964) 63–65.
- [12] J.P. Nicolai, Reconstruction of the columella with nasolabial flaps, *Head Neck Surg.* 4 (5) (1982) 374–379, <https://doi.org/10.1002/hed.2890040505>.
- [13] A. Yanai, S. Nagata, H. Tanaka, Reconstruction of the columella with bilateral nasolabial flaps, *Plast. Reconstr. Surg.* 77 (1) (1986) 129–132, <https://doi.org/10.1097/00006534-198601000-00020>. Available from: .
- [14] R.A. Agha, T. Franchi, C. Sohrabi, G. Mathew, for the SCARE Group, The SCARE 2020 guideline: updating consensus surgical Case Report (SCARE) guidelines, *Int. J. Surg.* 84 (2020) 226–230.
- [15] F.J. Stucker Jr, G.Y. Shaw, The perichondrial cutaneous graft: a 12-year clinical experience, *Arch Otolaryngol Neck Surg* 118 (3) (1992) 287–292, <https://doi.org/10.1001/archotol.1992.01880030075016>.
- [16] T.E. Rohrer, L.M. Dzubow, Conchal bowl skin grafting in nasal tip reconstruction: clinical and histologic evaluation, *J. Am. Acad. Dermatol.* 33 (3) (1995) 476–481, [https://doi.org/10.1016/0190-9622\(95\)91394-7](https://doi.org/10.1016/0190-9622(95)91394-7).
- [17] A. Odobescu, J.M. Servant, I.W. Danino, M.A. Danino, Nostril alar rim threshold flap for columellar reconstruction, *J Plast Reconstr Aesthet Surg* 64 (7) (2011) 929–933, <https://doi.org/10.1016/j.bjps.2011.01.004>.
- [18] R. Champion, Reconstruction of the columella, *Br. J. Plast. Surg.* 12 (1960) 353–355, [https://doi.org/10.1016/s0007-1226\(59\)80051-5](https://doi.org/10.1016/s0007-1226(59)80051-5).

# Columella Reconstruction Using Double Nasolabial Flap And Costal Cartilage: A Case Report

## ORIGINALITY REPORT

15%

SIMILARITY INDEX

11%

INTERNET SOURCES

13%

PUBLICATIONS

11%

STUDENT PAPERS

## PRIMARY SOURCES

1	Submitted to Associatie K.U.Leuven Student Paper	4%
2	Submitted to Universitas Airlangga Student Paper	4%
3	eprints.lums.ac.ir Internet Source	1%
4	A. Odobescu, J.-M. Servant, I. Weber Danino, M.A. Danino. "Nostril alar rim threshold flap for columellar reconstruction", Journal of Plastic, Reconstructive & Aesthetic Surgery, 2011 Publication	1%
5	Submitted to Universidad de Cartagena Student Paper	1%
6	f1000research.com Internet Source	1%
7	CO Enwonwu. "Noma (cancrum oris): questions and answers", Oral Diseases, 06/28/2008	1%

8

Rossella Sgarzani. "Microvascular reconstruction of the columella using a small radial forearm free flap: a case report", European Journal of Plastic Surgery, 08/01/2009

Publication

1 %

9

[www.sciencerepository.org](http://www.sciencerepository.org)

Internet Source

1 %

10

Salhadin Mohammed, Fasil Tesfaye Abebe, Hanna Assefa Negash, Thomas Bogale Megersa et al. "Tuberculoma masquerading as an en plaque Meningioma leading to a Diagnostic and Therapeutic Dilemma; a Case Report and a Multidisciplinary Perspective", Research Square Platform LLC, 2023

Publication

<1 %

11

Peter Berthold. "Noma: a forgotten disease", Dental Clinics of North America, 2003

Publication

<1 %

Exclude quotes Off

Exclude matches Off

Exclude bibliography On

# Columella Reconstruction Using Double Nasolabial Flap And Costal Cartilage: A Case Report

---

GRADEMARK REPORT

---

FINAL GRADE

**/0**

GENERAL COMMENTS

**Instructor**

---

PAGE 1

---

PAGE 2

---

PAGE 3

---

PAGE 4

---