

# Dog-ear's prevention during Inverted-T breast lift and reduction

*by* Indri Lakhsmi Putri

---

**Submission date:** 07-Apr-2023 03:54PM (UTC+0800)

**Submission ID:** 2058258284

**File name:** ear\_s\_prevention\_during\_Inverted-T\_breast\_lift\_and\_reduction.pdf (1.99M)

**Word count:** 1891

**Character count:** 10090



Contents lists available at ScienceDirect

Annals of Medicine and Surgery

journal homepage: [www.elsevier.com/locate/amsu](http://www.elsevier.com/locate/amsu)



How to Articles

## Dog-ear's prevention during Inverted-T breast lift and reduction



Indri Lakhsmi Putri<sup>a,\*</sup>, Laxminarayan Bhandari<sup>b</sup>, Heike Klepetko<sup>c</sup>

<sup>a</sup> Department of Plastic Reconstructive and Aesthetic Surgery, Faculty of Medicine, Airlangga University, Surabaya, East Java, Indonesia

<sup>b</sup> Department of Plastic Surgery, Govt Medical College Kozhikode, Kerala, 673008, India

<sup>c</sup> Plastic Reconstructive and Aesthetic Surgeon, The Veldhuis Private Clinic Rotterdam, The Radetzky Villa Vienna, Rotterdam, Netherlands

### ARTICLE INFO

#### Keywords:

Dog's ear  
Inverted-T breast lift  
Breast reduction  
Innovation

### ABSTRACT

There are several techniques for the prevention of dog-ear. All of the techniques have their own disadvantages, since mostly they lengthen the wound. The current technique prevents dog ear during inverted-T breast lift and reduction without lengthening the wound or creating tension while closing the wound.

### 1. Introduction

Breast lift and breast reduction are common surgical procedures worldwide. Although several techniques are reported for breast lift and breast reduction, many plastic surgeons favor the inverted-T technique [1]. The inverted-T technique commonly forms a 'dog-ear at the ends of the horizontal part of the inverted-T incision, due to length discrepancy between the adjacent wound margins leading to elevation of skin.

Meanwhile, a dog ear, as defined by surgeons, is an excess tissue and skin protruding at both ends following the closure of unequal margins of wound length [2]. It usually results from poor planning and execution of surgical incisions, an important aspect of wound closure. However, dog ears are sometimes inevitable as they are affected by the shape of the lesion to be excised and the skin's biological nature. This occurs regardless of the etiology, size or position of the wound. The term 'dog ear' was first described for wound closure by Borges in 1982 [3].

The senior author hereby presents her technique for preventing dog ears during inverted-T breast lift and reduction.

### 2. Idea

Standard inverted-T markings were made prior to surgery. The standard inverted T marking has the following parts: A vertical key-hole or wise pattern around the areola, a lower horizontal line corresponding to the inframammary fold (IMF) and two upper horizontal lines (medial and lateral) connecting the key-hole to the IMF line. We made the following modifications (Fig. 1).

The angle between the IMF line and its superior horizontal counterparts was 90° at both corners. This was done by making the superior horizontal lines to curve downwards so that it meets the IMF line at 90° at the corners. Thus, the upper horizontal line had a little "L" shape at the corner.

The angle between the key-hole pattern's superior horizontal lines and vertical lines was set at 90°.

Breast lift or breast reduction were performed in the standard fashion using a medio-cranial pedicle. The inframammary wound was closed starting from both corners. The subcutaneous buried sutures were placed first. The first stitch was taken in such a way that the distance from the corner to the stitch was the same (x) in both upper and lower flaps (Fig. 2). Thus, the curvilinear superior incision was made horizontal and parallel to the IMF incision. Care was taken to ensure that the first suture at each corner was taken in this fashion regardless of the length discrepancy between upper and lower horizontal incisions. Further subcutaneous buried sutures were placed by the standard halving method.

Finally, the inframammary wound was closed by running intracutaneous sutures (Fig. 3). Although this results in minor bunching up centrally, this settles well with time. Thus, the occurrence of dog ear was prevented by distributing the excess length centrally.

### 3. Discussion

This is commonly corrected by excising the dog-ear to lengthen the wound in the same direction as the long axis of the original defect [3],

8  
Abbreviations: IMF, inframammary fold; CDDE, circular defect with dog-ear deformities excision.

\* Corresponding author.

E-mail addresses: [indrilakshmiputri@fk.unair.ac.id](mailto:indrilakshmiputri@fk.unair.ac.id) (I.L. Putri), [lax321@gmail.com](mailto:lax321@gmail.com) (L. Bhandari), [heike.benditteklepetko@gmail.com](mailto:heike.benditteklepetko@gmail.com) (H. Klepetko).

<https://doi.org/10.1016/j.amsu.2021.102462>

Received 6 April 2021; Received in revised form 25 May 2021; Accepted 1 June 2021

Available online 11 June 2021

2049-0801/© 2021 The Authors. Published by Elsevier Ltd on behalf of IJS Publishing Group Ltd. This is an open access article under the CC BY-NC-ND license

<http://creativecommons.org/licenses/by-nc-nd/4.0/>

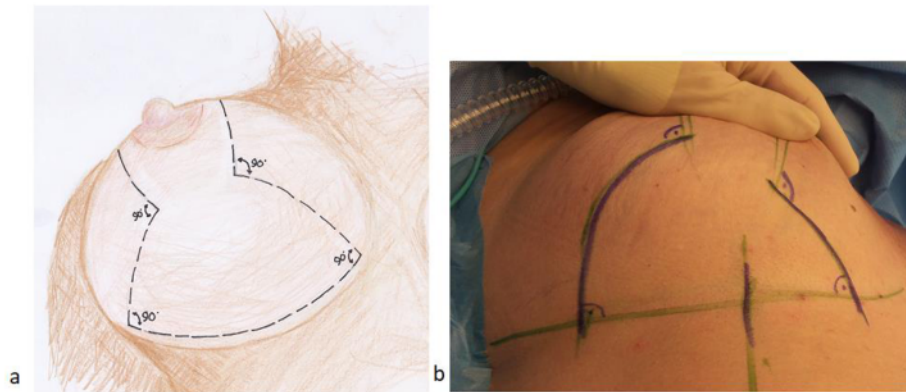


Fig. 1. The superior horizontal lines curve downwards meeting the IMF line at 90° at both corners (A, B).

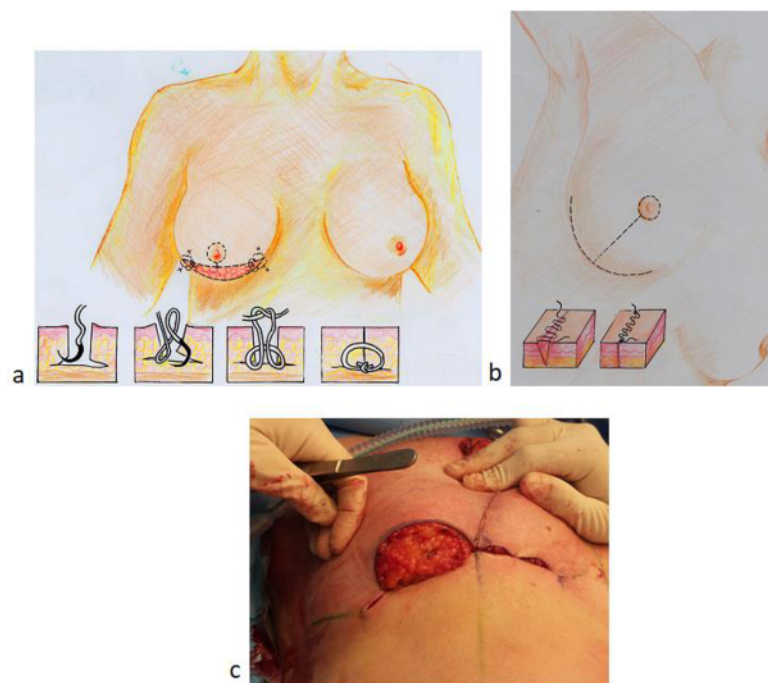


Fig. 2. The subcutaneous buried sutures were placed first from both corners, the distance from the corner to the stitch was same (x) in both upper and lower flaps (A). Further subcutaneous buried sutures were placed by the standard halving method (B). The curvilinear superior incision was made horizontal and parallel to the IMF incision (C).

Meanwhile, in pursuing a better aesthetic result, this is quite contradictory. To correct dog ears, the simplest approach is to do nothing when a spontaneous resolution is expected, further extension of the wound is needed and when immediate removal of dog ear is expected to jeopardize the viability of surrounding tissue [4]. In a previous study, dog-ears with an initial height of 8 mm were left in place to spontaneously regress [5]. Furthermore, other surgical procedures to correct dog ears include the hockey stick extension technique [4], M-plasty technique [6,7], inverted triangle technique [8], and 90° incision technique [9]. The disadvantage of all the mentioned techniques is that they create a longer scar at an angle to the original axis. The circular defect with dog-ear deformities excision (CDDE) technique [10] is a variation on fusiform

excision that produces a scar that is longer than the length of the original wound. Meanwhile, a previous study stated the three-bite suturing technique [11] is less than 15 mm from the skin surface and not exceeding a ratio of 3:1 between the dog ear's base and its projection. It was also reported that the tacking suture technique [12] was used in fixing the incipient dog-ear to the underlying periosteum. Another study also described de-epithelializing of the dog's ear portion to preserve the subdermal plexus by burying it in the dermis [13].

It would be wiser if we could prevent the occurrence of dog ears than to correct dog ears. Some of them are:

The triangular advancement technique [14], modified into Burrow's triangle excision. Meanwhile, the disadvantages of this technique

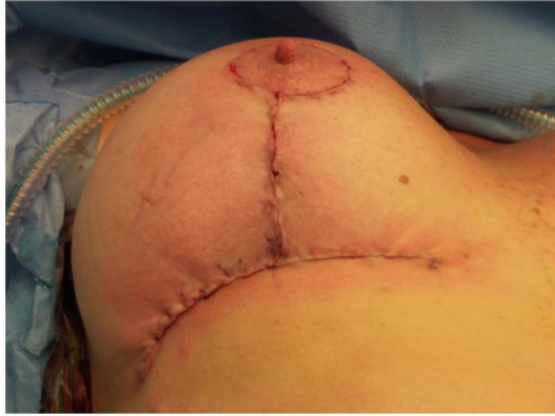

Fig. 3. The inframammary wound was closed by running intracutaneous sutures.

include lengthening of wound, complicated by skin necrosis, and involving additional scarring.

The diagonal mattress suture technique [15] at both sides of the wound. The disadvantages of this method are that there is a possibility of soft tissue excess in the central part of the wound at the end of closure, which can lead to difficulty closing the wound and higher tension in the central part of the wound, which can lead to wound dehiscence.

We offer a new method of dog ear prevention in breast lift and breast reduction surgery, which was developed by the senior author with more than 15 years of experience in breast surgery, without lengthening the wound or creating tension while closing the wound. By dispersing the surplus length centrally, dog ear was avoided. The only downside of this technique is small bunching up in the center, which will resolve with time. Finally, a novel technique for preventing dog ear during Inverted-T breast lift and breast reduction is the 90° angle connection line between keyhole and inframammary during Inverted-T breast lift and breast reduction.

10

#### Provenance and peer review

Not commissioned, externally peer-reviewed.

4

#### Ethical approval

The informed consent form was declared that patient data or samples will be used for educational or research purposes. Our institutional review board also do not provide an ethical approval in the form of case report/How To articles.

#### Sources of funding

The authors declare that this study had no funding source.

#### Author contribution

Indri Lakshmi Putri conceived the study and drafted the manuscript. Laxminarayan Bhandari and Heike Klepetko critically revised the

manuscript for important intellectual content. All authors read and approved the final draft. All authors facilitated all project-related tasks.

#### Registration of research studies

The manuscript is a How-To article, not considered a formal research involving participants.

#### Guarantor

Indri Lakshmi Putri.

2

#### Consent

Written informed consent was obtained from the patient for publication of this case report and accompanying images. A copy of the written consent is available for review by the Editor-in-Chief of this journal on request.

5

#### Declaration of competing interest

No potential conflict of interest relevant to this article was reported.

#### Acknowledgements

We would also like to thank Yugos Juli Fitra for drawing the pictures in this manuscript.

#### References

- [1] L.R. Bouwer, J.J. van der Biezen, C.A. Spronk, B. van der Lei, Vertical scar versus the inverted-T scar reduction mammoplasty: a 10-year follow-up, *J. Plast. Reconstr. Aesthetic Surg.* 65 (10) (2012) 1298–1304.
- [2] L. Dzubow, The dynamics of dog-ear formation and correction, *J. Dermatol. Surg. Oncol.* 11 (7) (1985) 722–728.
- [3] A.F. Borges, Dog-ear repair, *Plast. Reconstr. Surg.* 69 (4) (1982) 707–713.
- [4] N.K. Weisberg, K.S. Nehal, B.M. Zide, Dog-Ears: a review, *Dermatol. Surg.* 26 (4) (2000) 363–370.
- [5] K.S. Lee, N.G. Kim, P.Y. Jang, E.H. Suh, J.S. Kim, S.I. Lee, et al., Statistical analysis of surgical dog-ear regression, *Dermatol. Surg.* 34 (8) (2008) 1070–1076.
- [6] S.J. Salasche, L.C. Roberts, Dog-ear correction by M-plasty, *J. Dermatol. Surg. Oncol.* 10 (6) (1984) 478–482.
- [7] C.Y. Loh, A.Y. Loh, S.A. Mashhadi, A novel method for repairing the dog ear [Internet], *J. Plast Reconstr Aesthet Surg* 66 (11) (2013), <https://doi.org/10.1016/j.jbips.2013.06.047>. e341–2. Available from: .
- [8] F. Russo, Inverted triangle repair of dog-ear [Internet], *J Am Dermatology* 76 (3) (2017), <https://doi.org/10.1016/j.jaad.2016.09.016>. e95–7. Available from: .
- [9] L. Grasseti, D. Lazzeri, M. Torresetti, M. Bottoni, A. Scalise, G. Di Benedetto, Aesthetic refinement of the dog ear correction: the 90° incision technique and review of the literature, *Arch Plast Surg* 40 (3) (2013) 268–269.
- [10] T.S. Lee, C. Murakami, A.C. Suryadevara, Tissue conservation using circular defect with dog-ear deformities excision technique, *Laryngoscope* 121 (11) (2011) 2299–2304.
- [11] O. Jaber, M. Vischio, A. Faga, G. Nicoletti, The three-bite Technique: a novel method of dog ear correction, *Arch Plast Surg* 42 (2) (2014) 223–225.
- [12] Kantor J. The dog-ear tacking suture technique. *J Am Dermatology [Internet]*. 73 (1):e25–6. Available from: <https://doi.org/10.1016/j.jaad.2015.03.018>.
- [13] K. Kishi, H. Nakajima, N. Imanishi, A new dog ear correction technique, *J. Plast Reconstr Aesthet Surg* 61 (2008) 423–424.
- [14] L.C. Bennett, M.A. Biggar, A triangular advancement technique to avoid the dog-ear deformity following mastectomy in large breasted women, *Ann. R. Coll. Surg. Engl.* 93 (7) (2011) 554–555.
- [15] M.M. Dhandha, T. Mishra, D.H. Whitney, Use of the diagonal mattress suture to prevent dog-ear formation, e27–8, *J Am Acad Dermatol [Internet]* 73 (1) (2015), <https://doi.org/10.1016/j.jaad.2015.03.037>. Available from: .

# Dog-ear's prevention during Inverted-T breast lift and reduction

## ORIGINALITY REPORT

19%

SIMILARITY INDEX

16%

INTERNET SOURCES

13%

PUBLICATIONS

8%

STUDENT PAPERS

## PRIMARY SOURCES

1	Submitted to Pennsylvania State System of Higher Education Student Paper	3%
2	Submitted to Universitas Sebelas Maret Student Paper	3%
3	<a href="http://escholarship.umassmed.edu">escholarship.umassmed.edu</a> Internet Source	3%
4	<a href="http://oamjms.eu">oamjms.eu</a> Internet Source	2%
5	<a href="http://synapse.koreamed.org">synapse.koreamed.org</a> Internet Source	2%
6	<a href="http://www.e-aps.org">www.e-aps.org</a> Internet Source	1%
7	<a href="http://bmcgastroenterol.biomedcentral.com">bmcgastroenterol.biomedcentral.com</a> Internet Source	1%
8	Ajaipal S. Kang, Kevin S. Kang. "A Systematic Review of Cutaneous Dog Ear Deformity",	1%

# Plastic and Reconstructive Surgery - Global

Open, 2020

Publication

---

9	<a href="http://www.jove.com">www.jove.com</a> Internet Source	1 %
10	<a href="http://www.topdoctors.co.uk">www.topdoctors.co.uk</a> Internet Source	1 %
11	Charles Yuen Yung Loh, Alex Yuen Hua Loh, Syed Abuzar Mashhadi. "A novel method for repairing the dog ear", Journal of Plastic, Reconstructive & Aesthetic Surgery, 2013 Publication	1 %
12	Jonathan Kantor. "The dog-ear tacking suture technique", Journal of the American Academy of Dermatology, 2015 Publication	1 %
13	KYUNG SUK LEE. "Statistical Analysis of Surgical Dog-Ear Regression", Dermatologic Surgery, 5/6/2008 Publication	1 %
14	<a href="http://pdfcoffee.com">pdfcoffee.com</a> Internet Source	1 %

---

Exclude quotes Off

Exclude matches Off

Exclude bibliography On

# Dog-ear's prevention during Inverted-T breast lift and reduction

---

GRADEMARK REPORT

---

FINAL GRADE

**/0**

GENERAL COMMENTS

**Instructor**

---

PAGE 1

---

PAGE 2

---

PAGE 3

---