

C2.28

by Akhmad Taufiq Mukti

Submission date: 24-Oct-2020 03:49PM (UTC+0800)

Submission ID: 1425088943

File name: C2.28_IOP_Conf._Ser._Earth_Environ._Sci._236,_012093_2019.pdf (562.8K)

Word count: 2899

Character count: 14826

2

The effect of noni *Morinda citrifolia* L. fruit extracts on the gill histopathological changes of Nile tilapia *Oreochromis niloticus*

A T Mukti^{1*}, E Dewi², W H Satyantini¹, L Sulmartiwi³, Sudarno¹ and M Hassan⁴

¹ Department of Fish Health Management and Aquaculture, Faculty of Fisheries and Marine, Universitas Airlangga, Kampus C Unair, Jl. Mulyorejo Surabaya 60115, Indonesia

² Undergraduate, Study Program of Aquaculture, Faculty of Fisheries and Marine, Universitas Airlangga, Kampus C Unair, Jl. Mulyorejo Surabaya 60115, Indonesia

³ Department of Marine, Faculty of Fisheries and Marine, Universitas Airlangga, Kampus C Unair, Jl. Mulyorejo Surabaya 60115, Indonesia

⁴ Institut of Tropical Aquaculture, Universiti Malaysia Terengganu, 21030 Kuala Terengganu, Terengganu, Malaysia

*Corresponding Author: akhmad-t-m@fpk.unair.ac.id

Abstract. Noni (*Morinda citrifolia* L.) fruit has a bioactive compound potentially used as an immunostimulatory ingredient in fish. The toxicity of noni fruit extract is therefore important to determine. This study aimed to learn about the effects of noni fruit extract on the gill histopathological changes of Nile tilapia. The method used an experiment using a completely random design with six treatments of different noni fruit extract concentrations with four replications respectively. The fish were immersed in the noni fruit extract solution for 24 and 96 hours respectively. Then, the gill tissue was collected and stored in a BNF solution at room temperature for the histology. This study showed that a concentration of 18% and 20% (5.2 and 6.0 g/L, respectively) caused severe damage to the gill tissue, to the point where necrosis found. A concentration of less than 18% (5.2 g/L) was indicated by a decrease in the damage to the gill tissue after an immersion of 96 hours compared to the immersion for 24 hours. The increased concentration of noni fruit extract has therefore been shown to cause more damage to the tissues and organs.

1. Introduction

Noni fruit, also known as *Morinda citrifolia* L., contains scopoletin, polyphenols, carotenoids, flavonoids, tannins, anthocyanins, ascorbic acid, nitrate, oxalate, phytate, saponins, and free amino acids [1]. Noni fruit is known to contain several active compounds that are capable of affecting immunomodulators, which activate the immune system's bodily responses after pathogen infection [2], besides being antibacterial, antiviral, antifungal and antiparasitic [3].

Tilapia is an organism used for toxicity tests [4]; it has a widespread population and is a euryhaline [5]. Tilapia occupy a variety of habitats, including shallow freshwater waterways, ponds, rivers, and lakes. Toxicity tests using fish tilapia organisms have had an important impact on the development of aquaculture management [6].

The presence of a foreign substance in the form of the noni fruit extract received by the fish retrieved from the environment will affect the structure of the cells or tissues. Changes in the gills of the fish were one of the most common responses, in which it retaliated against the foreign substances in the environment [7]. A highly toxic substance concentration decreases the ability of the liver to



eliminate toxic substances, as this organ is particularly vulnerable to the influence of chemical substances, resulting in the frequently damaged and abnormal organ structure.

The toxicity test of the noni fruit aqueous extract using the immersion method was conducted to observe the impact of accidental poisoning from the noni fruit extract in the fish. Deng *et al.* [8] reported that the toxicity of the noni fruit extract using the Brine Shrimp Lethality Test (BLST) obtained a result that was 76.13% of LC₅₀. The LD₅₀ test results for the noni fruit extract after 24 hours showed that it was not toxic in the fish tilapia at a concentration of 1.42 g/L [9]. The active antimicrobial compounds at high concentrations could poison the fish seed due to the high level of toxic compounds, namely saponins [10].

The role of the noni fruit extract in tilapia is not widely known. This study was intended to observe the immersion influence of noni fruit extract on the gill histopathological changes of Nile tilapia fish.

2. Materials and methods

This study was conducted in the Laboratory of the Faculty of Fisheries and Marine, Universitas Airlangga and in Balai Karantina Ikan Kelas 1 Juanda, Surabaya, East Java, Indonesia.

2.1. Test organisms

In this study, the fish used were Nile tilapia that were 7 - 9 cm in size with an 11 g average weight originating from the Installation of Freshwater Aquaculture Umbulan, Pasuruan, East Java, Indonesia.

2.2. Noni fruit extract

The noni fruit was characterized by a white-yellowish color and slightly soft meat; they were used as the extraction object, as according to [11]. The noni fruit was washed and cut into small pieces. The aqueous extract method was conducted as according to [12]; i.e. 100 g/L of noni fruit pieces were mixed with aquadest using a blender and filtered using a filter cloth. The extract solution was then applied directly to the treatment.

2.3. Fish rearing

The tilapias were reared in a 10 L-volume aquarium at a density of 1 fish/L for each treatment. The fish were acclimated for two days before the treatment was done.

2.4. Treatment

This study used an experimental method using a complete randomized design with six treatments of noni fruit extract concentration and four replications respectively. The concentrations of the noni fruit extract were based on the preliminary trials that had been done to determine the LC₅₀ over 96 hours, resulting in 5.4 g/L. The treatments were done through the immersion of the tilapia in the noni extract solution (0.0 g/L as control, 3.6, 4.2, 4.8, 5.4, and 6.0 g/L) for 96 hours. Any sub-lethal effects on the fish's swimming and movement were measured by counting the tachyventilation for 24 and 96 hours respectively.

2.5. Histological preparation

The sampling of the fish's gill tissue was done after 24- and 96-hours. The gill tissue from each treatment of noni fruit extract concentration was separated into different sample bottles and fixated using a buffer neutral formalin (BNF) solution, as according to Junqueira and Carneiro [13]. The histological method was conducted by McCann [14] using hematoxylin and eosin staining [15].

2.6. Histopathological observation

The histology samples were observed under 100× and 400 × magnification using an Olympus microscope (Olympus Optical Ltd. Tokyo, Japan), which was equipped with a monitor. The histopathology was evaluated using the histopathological scoring standard according to Crawford [16], such as shown in Table 1.

Table 1. Histopathological scoring [17]

Field Area	Score of damage
Normal	0 (normal)
Abnormal <25%	1 (mild)
Abnormal 26 - 50%	2 (moderate)
Abnormal 51 - 75%	3 (heavy)
Abnormal 76 - 100%	4(very heavy)

2.7. Data analysis

The data were analyzed using the non-parametric statistical method of Kruskal-Wallis and continued using the Mann-Whitney test with the SPSS 16.0 computer software application.

3. Results and discation

3.1 Results

Based on the Kruskal-Wallis test, the concentration of 0.0 g/L was observed to show no damage with a histopathological scoring of 0.00. The other concentrations indicated that they had a histopathological scoring of more than zero, which means that the damage occurred on the gill organ ranged from mild to very heavy. The highest damage was observed in the concentration of 6 g/L, as there was a massive loss of gill tissue in the treatment. Significant histopathological damage was observed in the concentrations of 4.8 and 5.4 g/L, as shown in Table 2. The histopathological changes in the fish's gill after 24 and 96 hours have been shown in Figures 1 and 2, respectively.

Table2. Histopathological scoring of the tilapia's gills after the treatment of the different noni fruit extract concentrations

The concentration of noni fruit extract (g/L)	Damage score on observation time	
	24 hours	96 hours
0.0	0.00 ^a	0.00 ^a
3.6	0.75 ^b	1.00 ^b
4.2	1.00 ^c	1.25 ^c
4.8	1.75 ^d	1.50 ^d
5.4	3.50 ^e	3.75 ^e
6.0	3.75 ^f	4.00 ^f

Note: Different superscript in the same column indicates a significant difference (p<0.05).

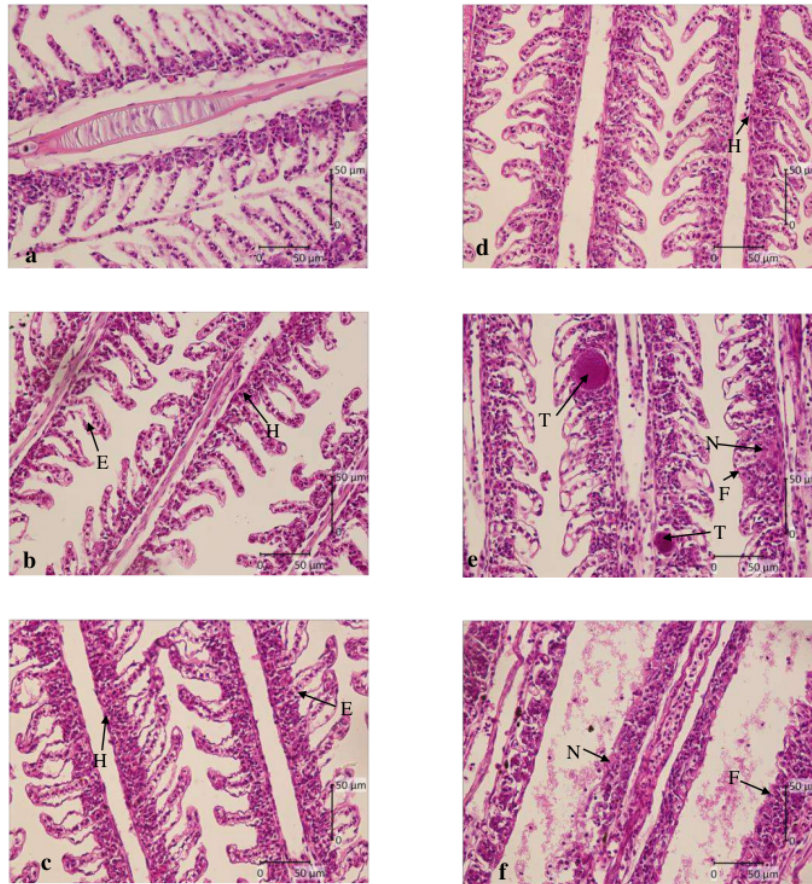


Figure 1. Gill histopathological changes in the tilapia after immersion in the noni extract concentration for 24 hours observed at 400 × magnification. a: 0.0 g/L, b: 3.6 g/L, c: 4.2 g/L, d: 4.8 g/L, e: 5.4 g/L, and f: 6.0 g/L; E = oedema, F = lamellae fusion, H = hyperplasia, N = necrosis, and T = telangiectasis. Bar scale = 50 µm.

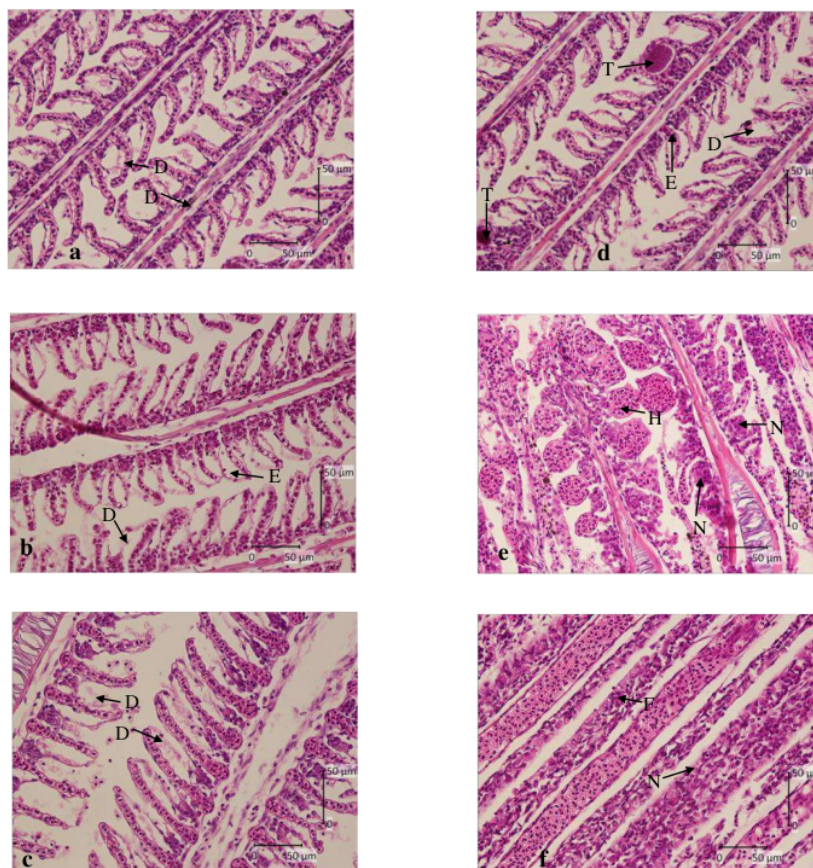


Figure 2. Gill histopathology changes in the tilapia after immersion in the noni extract concentration for 96 hours observed at 400 × magnification. a: 0.0 g/L, b: 3.6 g/L, c: 4.2 g/L, d: 4.8 g/L, e: 5.4 g/L, and f: 6.0 g/L; D = desquamation, E = oedema, F = lamellae fusion, H = hyperplasia, N = necrosis, and T = telangiectasis. Bar scale = 50 µm.

3.2 Discussion

Histopathological changes occurred in the gill tissue of the tilapia immersed in the noni fruit extract. Early damage which occurred on the gills was seen at 24 and 96 hours after immersion. Changes in the histopathological tissue included edema, hyperplasia, telangiectasis, lamellae fusion and necrosis. A thin layer of epithelial in the gill was directly related to the external environment, where the gill was exposed by and to the existing pollutants in the water. The slightest damage may lead to a disruption in the function of the gill as a regulator and this can lead to breathing difficulties [18].

The result of the scoring value related to the different immersion times came from the longer immersion in the noni fruit extract, where the greater tissue damage arose. Edema is a condition where there is an increased amount of fluid in the bodily tissues [19]. The extract contained saponin, which was a foreign substance to the fish in their environment. The function of the gill as an osmoregulation organ caused the gill to be highly influenced by the fish's environmental condition, including the concentration difference in the environment. Edema can cause tissue swelling and inflammation due to

fluid accumulation, as there is an electrolyte imbalance that exists in the aquatic environment [20]. Edema is usually followed by the desquamation of the secondary epithelial lamellae [21].

Hyperplasia in the treatments happened due as a response to reducing the extract diffusion. Lin and Randall [22] stated that mucous cell hyperplasia was due to the diffusion reduction of the active ingredients from the plant extracts through the branchial epithelium, besides the possibility of an electrolyte imbalance response caused by a large permeability branch. Hyperplasia resulted in an interlamellar space, resulting in the production of mucous being clogged. Hyperplasia can also cause epithelium thickening at the tip of the filament, which showed as having a shape like a baseball (distal clubbing) or tissue thickening located near the base of the lamellae (basal hyperplasia) [23].

Lamellae fusion occurred as the hyperplasia spread over the basal cells of the epithelium. This event resulted in the inhibition process of respiration as well as expiration. Branchial epithelial necrosis occurred due to direct cytotoxic effects [24] from the noni fruit extract and concurrently with the changes in cellular permeability caused by the surfactants/saponins [25]. Telangiectasis happened due to blood coagulation in the secondary lamellae, disrupting the respiration process.

Foreign substances in the form of the noni fruit extract were able to pass through the blood vessels of the gills and into the liver of the tilapia. The content of some of the active ingredients of noni extract was characterized as being toxic, such as the saponin, flavonoid, and polyphenol compounds. Necrosis is the low activity of cells that experience cell death, causing a loss of cell function in the area which has suffered necrosis.

Harborne [26] stated that saponin has active compounds like soap, which can be detected from their ability to shape the foam and to hemolyze the blood cells. Saponin is contained in the leaves. Saponin affects the fish, as it was used in an excess concentration, causing a toxic effect [10]. Saponin is toxic to cold-blooded organisms, as it was able to hemolyze the red blood cells [27]; this is a symptom of the toxicity caused by saponin as a respiratory toxin.

4. Conclusion

The immersion in the noni fruit extract caused significant gill histopathological changes in the tilapia fish. A high concentration of noni fruit extract significantly increased the histopathological damage. Damages to the [\[22\]](#) tissue included edema, desquamation, lamellae fusion, hyperplasia, telangiectasis, and necrosis. A [study on the effect of noni fruit extract on the liver and other tissues](#) is needed.

5. References

- [1] Singh D R, Singh S and Banu V S 2016 *British J. Pharma. Res.* **10**, 1-11
- [2] [\[10\]](#) Nyak S and Sushma M 2009 *Pharma. Biol.* **47**, 248-254
- [3] [\[10\]](#) Earle M, Earle R and Anderson A 2001 *Food Product Development* (England: [Woodhead Publishing Limited](#)) p 380
- [4] [\[14\]](#) hammad F 2002 *Majalah Ilmiah Biologi BIOMA* **4**, 54-58 (in Indonesian)
- [5] [\[7\]](#) Agah H, Leermakers M, Elskens M, Fatemi S M R and Baeyens W 2009 *Environ. Monitor. Assess.* **157**, 499-514
- [6] Lee J, Durst R W and Wrolstad R E 2005 *J. AOAC Inter.* **88**, 1269-1278
- [7] [\[13\]](#) D W T 2004 *Mar. Poll. Bull.* **48**, 817-834
- [8] [\[8\]](#) Deng S, West B J, Palu A K and Jensen C J 2012 *ISRN Analyt. Chemist.* doi:10.5402/2012/160871
- [9] [\[9\]](#) Muharrama A R W, Syawal H and Lukistyowati I 2015 *J. Online Mahasiswa FPIK Unri* **2**, 1-10 (in Indonesian)
- [10] [\[20\]](#) aneti R and Fajri N 2013 *Acta Aquatic.* **3**, 62-65 (In Indonesian)
- [11] [\[12\]](#) suma S F, Pawening R E and Dijaya R 2017 *J. Ilmiah Teknol. Sistem Info.*, **3**, 17-23
- [12] [\[8\]](#) Berkovich L, Earon G, Ron I, Rimmon A, Vexler A and Lev-Ar S 2013 *BMC Complement. Internat. Medic.* **13**, 1-7
- [13] [\[8\]](#) Junqueira C L and Carneiro J 2005 *Basic Histology Text and Atlas 11th edition* (New York: United States of America) p 502

- [14] McCann M T 2015 *Tools for Automated Histology Image Analysis Thesis Department of Biomedical Engineering* (PA: Carnegie Mellon University Pittsburgh)
- [15] Genten F, Terwinghe E and Danguy A 2009 *Atlas of Fish Histology Department of Histology and Biopathology of Fish Fauna Laboratory of Functional Morphology Université Libre de Bruxelles (ULB)* (Brussels Belgium: Science Publishers) p 104
- [16] Crawford J M 2005 *Liver and Biliary Tract In: Kumar V, Abbas A K and Fausto N Robbins and Juran Pathologic Basis of Disease 7th ed* (Philadelphia: Elsevier Saunders) p 1903
- [17] Corley K N G, Olivier A K and Meyerholz D K 2013 *Vet. Pathol.* **50**, 1007-1015
- [18] Sasanto E, Sidabalok I and Dewantoro E 2013 *J. Ruaya* **2**, 23-28 (in Indonesian)
- [19] Mason C 2002 *Biology of Freshwater Pollution Fourth edition* (England: Prentice Hall) p 200
- [20] Annika, Aunurohim and Abdugani N 2013 *J. Sains dan Seni Pomits* **2**, 2337-3520
- [21] Roberts R J 2001 *Fish Pathology 3rd ed* (London: WB Saunders) p 57
- [22] Lin H and Randall D 1995 Proton pumps in fish gills: 229-255 *In: Hoar W S, Randall D J and Farrell A P* (Ed) *Fish Physiology: Cellular and Molecular Approaches to Fish Ionic Regulation* (New York: Academic Press)
- [23] Ersu I M 2008 *Histopathological Picture of Gills, Intestines, and Muscles in Mujair Fish Oreochromis mossambicus in Ciampea Bogor Faculty of Veterinary Medicine* (Bogor: Bogor Agricultural University/IPB) p 50
- [24] Monroy C M, Cortés A C, Sicard D M and Groot de Restrepo H 2005 *Biomedica* **25**, 335-345
- [25] Stagg R M and Shuttleworth T J 1986 *J. Comp. Physiol. B* **156**, 727-733
- [26] Harborne J B 1987 *Phytochemical Methods Guides Modern Ways to Analyze Plants 2nd ed Padmawinata K and Soedira I* (translator) (Bandung: ITB Press) p 354
- [27] Musman M 2010 *Trop. Life Sci. Res.* **21**, 41-50

Acknowledgments

The authors would like to thank the Rector of Universitas Airlangga and the Dean of Fisheries and Marine Faculty, Universitas Airlangga, who sponsored this research through the Joint Research Grant Program.

ORIGINALITY REPORT

12%

SIMILARITY INDEX

11%

INTERNET SOURCES

8%

PUBLICATIONS

3%

STUDENT PAPERS

PRIMARY SOURCES

1	ejournal2.undip.ac.id Internet Source	1%
2	unair.ac.id Internet Source	1%
3	idoc.pub Internet Source	1%
4	sasvepm.org Internet Source	1%
5	Powell, M.D.. "Physiological effects of freshwater bathing of Atlantic salmon (<i>Salmo salar</i>) as a treatment for amoebic gill disease", <i>Aquaculture</i> , 20010801 Publication	1%
6	ejournal-balitbang.kkp.go.id Internet Source	1%
7	www.frontiersin.org Internet Source	1%
8	www.slideshare.net Internet Source	1%

9

Xin Ren, Pengyuan Dai, Aneela Perveen, Qian Tang, Liangyu Zhao, Xiao Jia, Yansen Li, Chunmei Li. "Effects of chronic glyphosate exposure to pregnant mice on hepatic lipid metabolism in offspring", Environmental Pollution, 2019

Publication

<1 %

10

sfamjournals.onlinelibrary.wiley.com

Internet Source

<1 %

11

www.bioflux.com.ro

Internet Source

<1 %

12

www.isca.in

Internet Source

<1 %

13

www.lrrd.org

Internet Source

<1 %

14

M. Lenhardt, I. Jarić, Ž. Višnjić-Jeftić, S. Skorić, Z. Gačić, M. Pucar, A. Hegediš.

"Concentrations of 17 elements in muscle, gills, liver and gonads of five economically important fish species from the Danube River", Knowledge and Management of Aquatic Ecosystems, 2013

Publication

<1 %

15

scholars.wlu.ca

Internet Source

<1 %

16

www.ijert.org

<1 %

17

Eman T. Mohammed, Khalid S. Hashem, Amr E. Ahmed, Mohamed Tarek Aly, Lotfi Aleya, Mohamed M. Abdel-Daim. "Ginger extract ameliorates bisphenol A (BPA)-induced disruption in thyroid hormones synthesis and metabolism: Involvement of Nrf-2/HO-1 pathway", *Science of The Total Environment*, 2020

Publication

<1 %

18

doi.org
Internet Source

<1 %

19

www.efsa.europa.eu
Internet Source

<1 %

20

Selvia Ferdiana Kusuma, Ratri Enggar Pawening, Rohman Dijaya. "Otomatisasi klasifikasi kematangan buah mengkudu berdasarkan warna dan tekstur", *Register: Jurnal Ilmiah Teknologi Sistem Informasi*, 2017

Publication

<1 %

21

bnrc.springeropen.com
Internet Source

<1 %

22

www.ijrasb.com
Internet Source

<1 %

23

Laurent A. F. Frantz, Anna Rudzinski, Abang Mansyursyah Surya Nugraha, Allowen Evin et al. "Synchronous diversification of Sulawesi's iconic artiodactyls driven by recent geological events", *Proceedings of the Royal Society B: Biological Sciences*, 2018

Publication

<1 %

Exclude quotes Off

Exclude matches Off

Exclude bibliography Off