



Source details

Acta Dermatovenerologica Alpina, Panonica et Adriatica

Formerly known as: Acta Dermatovenerologica Iugoslavica

Scopus coverage years: from 1994 to 2022

Publisher: Slovenian Medical Society

ISSN: 1318-4458 E-ISSN: 1581-2979

Subject area: Medicine: General Medicine

Source type: Journal

CiteScore 2021

1.7



SJR 2021

0.273



SNIP 2021

0.622



[View all documents >](#)

[Set document alert](#)

[Save to source list](#) [Source Homepage](#)

[CiteScore](#) [CiteScore rank & trend](#) [Scopus content coverage](#)

i Improved CiteScore methodology



CiteScore 2021 counts the citations received in 2018-2021 to articles, reviews, conference papers, book chapters and data papers published in 2018-2021, and divides this by the number of publications published in 2018-2021. [Learn more >](#)

CiteScore 2021

$$1.7 = \frac{282 \text{ Citations 2018 - 2021}}{162 \text{ Documents 2018 - 2021}}$$

Calculated on 05 May, 2022

CiteScoreTracker 2022

$$1.7 = \frac{263 \text{ Citations to date}}{154 \text{ Documents to date}}$$

Last updated on 05 January, 2023 • Updated monthly

CiteScore rank 2021

Category	Rank	Percentile
Medicine		
General Medicine	#363/826	56th

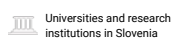
[View CiteScore methodology >](#) [CiteScore FAQ >](#) [Add CiteScore to your site](#)



Acta Dermatovenerologica Alpina, Panonica et Adriatica

COUNTRY

Slovenia

**SUBJECT AREA AND CATEGORY**

Medicine
 Dermatology
 Infectious Diseases
 Medicine (miscellaneous)

PUBLISHER

Slovenian Medical Society

H-INDEX**29****PUBLICATION TYPE**

Journals

ISSN

13184458, 15812979

COVERAGE

1994-2021

INFORMATION[Homepage](#)[How to publish in this journal](#)office@acta-apa.org**SCOPE**

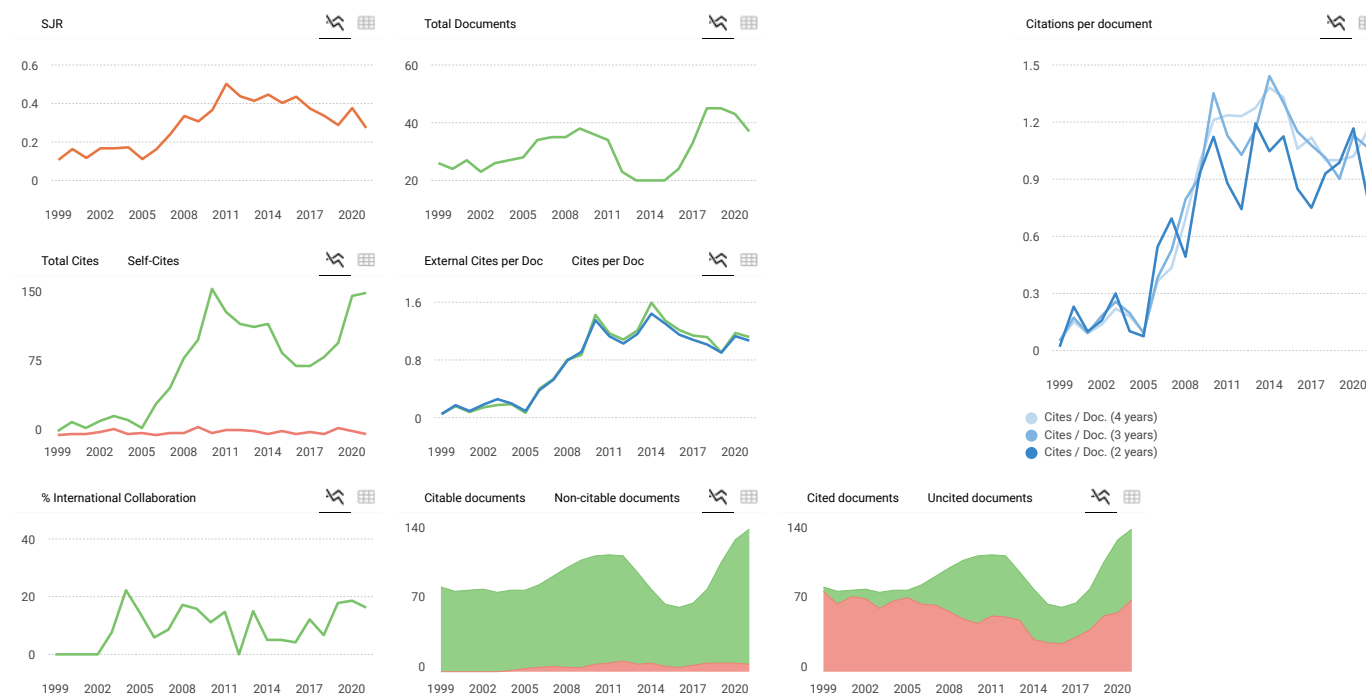
Acta Dermatovenerologica Alpina Pannonica et Adriatica (Acta Dermatovenerol APA) is an open access medical journal published quarterly by the Association of Slovenian Dermatovenerologists. The journal aims to publish papers describing all aspects of research in dermatology and venereology. Acta Dermatovenerol APA invites submissions under a broad scope of topics relevant to clinical and experimental research and publishes original articles, reviews, case reports and letters to the editors.

Join the conversation about this journal

FIND SIMILAR JOURNALS ⓘ

options ⋮

<p>1 Dermatologic Therapy GBR</p> <p style="font-size: 24px; color: green; font-weight: bold;">74%</p> <p>similarity</p>	<p>2 International Journal of Dermatology GBR</p> <p style="font-size: 24px; color: green; font-weight: bold;">73%</p> <p>similarity</p>	<p>3 Indian Journal of Dermatology, Venereology IND</p> <p style="font-size: 24px; color: green; font-weight: bold;">72%</p> <p>similarity</p>	<p>4 Dermatology Research and Practice EGY</p> <p style="font-size: 24px; color: green; font-weight: bold;">72%</p> <p>similarity</p>	<p>5 Journal of the Egyptian Women's Dermatologic USA</p> <p style="font-size: 24px; color: green; font-weight: bold;">71%</p> <p>similarity</p>
---	---	---	--	---



Acta Dermatovenerologica Alpina, Panonica et Adriatica

Q3 Dermatology

SJR 2021 0.27

powered by scimagojr.com

← Show this widget in your own website

Just copy the code below and paste within your html code:

```
<a href="https://www.scimagojr.com" style="color: #0070C0; text-decoration: none;">https://www.scimagojr.com
```

SCImago Graphica

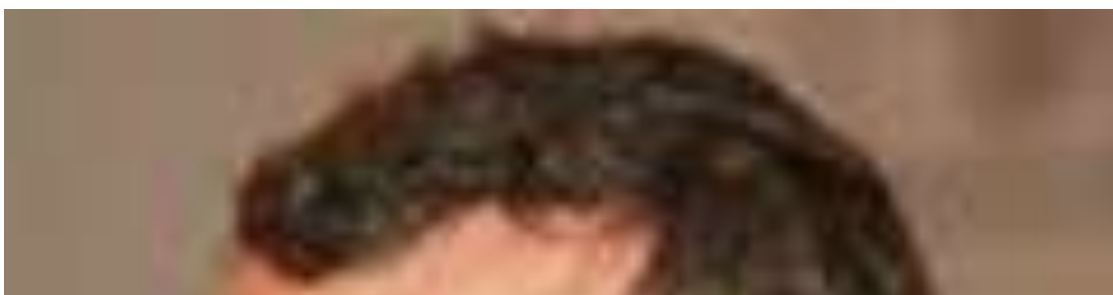Explore, visually communicate and make sense of data with our [new data visualization tool](#).



Metrics based on Scopus® data as of April 2022

Leave a comment

Advisory Board



Prof. Giovanni Abramo

[⌂](http://www.iasi.cnr.it/new/people.php/id_subject/85) (http://www.iasi.cnr.it/new/people.php/id_subject/85)
 [Sci](https://sciprofiles.com/profile/author/MDg0cnAvaERoMGINckt3TWk3U0cxWi8vWW91M1AycFhxNFNkODVIUWZnTT0=) (<https://sciprofiles.com/profile/author/MDg0cnAvaERoMGINckt3TWk3U0cxWi8vWW91M1AycFhxNFNkODVIUWZnTT0=>)

Affiliation

Institute for System Analysis and Computer Science (IASI-CNR), National Research Council of Italy, Via dei Taurini, 19 -00185 Roma, Italy

Research Interests

strategic management of research; research evaluation; technology transfer; bibliometrics



Dr. Yi Bu
[⌂](https://buyi08.wixsite.com/yi-bu) (<https://buyi08.wixsite.com/yi-bu>)
 [Sci](https://sciprofiles.com/profile/1029136) (<https://sciprofiles.com/profile/1029136>)

Affiliation

Department of Information Management, Peking University, Beijing 100871, China

Research Interests

science of science; research evaluation; scholarly communication



Dr. Aneta Drabek
[⌂](https://www.mdpi.com) (<https://www.mdpi.com>) (Basel, Switzerland) unless otherwise stated
 Disclaimers: [Terms & Conditions](https://www.mdpi.com/terms-and-conditions) (<https://www.mdpi.com/terms-and-conditions>) [Privacy Policy](https://www.mdpi.com/privacy) (<https://www.mdpi.com/privacy>)



Affiliation

Library of the University of Silesia, Bankowa 11a, 40 007 Katowice, Poland

Research Interests

library and information science; bibliometrics

**Dr. Robin Haunschild**

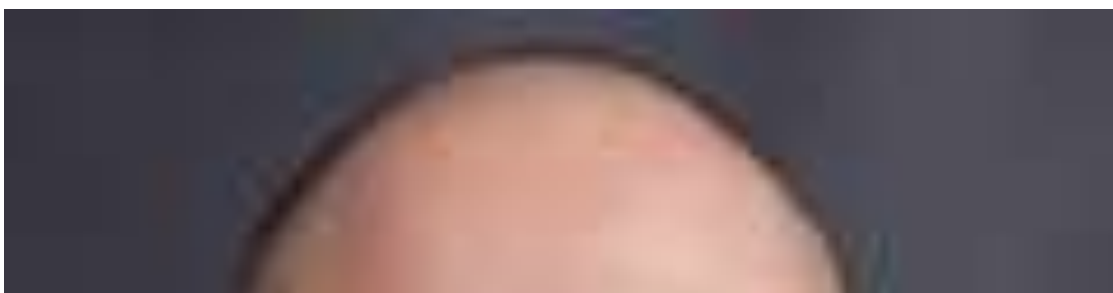
 (<https://www.fkf.mpg.de/person/37778/66149>)  (<https://sciprofiles.com/profile/184406>)



Affiliation

Max Planck Institute for Solid State Research, Heisenbergstraße 1, 70569 Stuttgart, Germany

Research Interests

scientometrics; bibliometrics; altmetrics

**Prof. Dr. Zhigang Hu**

 (http://faculty.dlut.edu.cn/huzhigang/zh_CN/zhym/827592/list/index.htm)  (<https://sciprofiles.com/profile/author/TlgwaUdTSnF5V3FueHF3M1B6cTJxbEZQQIVOVVp3MUVvWlQva21mQmwxST0=>)

Affiliation



Wise Lab, Dalian University of Technology, Dalian 116024, China

Research Interests

citation analysis; science of science; scientometrics; bibliometrics; mapping knowledge domains



Professor.Dr.Kun Lu

 (<https://www.ou.edu/cas/slis/faculty-staff/kun-lu>)  (<https://sciprofiles.com/profile/author/S1lacmZLZmxoWWZEZmRXS0pnN3QxZz09>)

Affiliation


School of Library and Information Studies, University of Oklahoma, Norman, OK 73019, United States

Research Interests

information access and retrieval; text mining; organization of information; science informatics



Prof. Dr. Yannis Manolopoulos

 (<https://www.yannismanolopoulos.eu/>)  (<https://sciprofiles.com/profile/1458389>)

Affiliation



1. Faculty of Pure and Applied Sciences, Open University of Cyprus, 2220 Nicosia, Cyprus
2. Data and Web Lab, Department of Informatics, Aristotle University of Thessaloniki, 54124 Thessaloniki, Greece

Research Interests

data management; data science; databases; data mining; scientometrics



Professor Dr. Jin Mao

 (<https://sim.whu.edu.cn/info/1050/8292.htm>)  (<https://sciprofiles.com/profile/jin-mao>)

Affiliation



Center for Studies of Information Resources, Wuhan University, Wuhan 430072, China

Research Interests

information organization; scholarly data mining; science of science



Prof. Dr. Candela Ollé

 (<https://www.uoc.edu/portal/en/news/kit-premsa/guia-experts/directori/candela-olle.html>)  (<https://sciprofiles.com/profile/473622>)

Affiliation

Faculty of Information and Communication Sciences, Universitat Oberta de Catalunya
08035 Barcelona, Spain

Research Interests

open access; open science; scientific communication, journalism, academic



Dr. José Luis Ortega

 (<http://jlortega.scienceontheweb.net/>)  (<https://sciprofiles.com/profile/author/N0Ztc05pd3IPdUxYVDZyS3Y5dTRKais0Ny9BMGs1TWtra3FBYzBPaitoOD0=>)

Affiliation

Institute for Advanced Social Studies (IESA-CSIC), Campo Santo de los Mártires, 7 14004
Córdoba, Spain

Research Interests

scientometrics; altmetrics; academic search engines; scholarly social networks



Dr. Vladimir Pislyakov

 (<https://www.hse.ru/en/staff/pislyakov>)  (<https://sciprofiles.com/profile/author/QWpIS1lvUEE4SVo2TnpiSkhSZTZMNnZPbE5STGxST25XUDBFY0tQSjR5ST0=>)

Affiliation



Library, HSE University, Moscow 109028, Russia

Research Interests

scientometrics; citation databases; bibliometric indicators; library and information science



Prof. Dr. Daniel Torres-Salinas

 (<https://sites.google.com/go.ugr.es/torressalinas>)  (<https://sciprofiles.com/profile/author/YktxbGpkaEdNeXMrbGRPd2NjNS9ka2tIQXBHSWZpeVIPZIk2aIJ4TU50UT0=>)

Affiliation



Department of Information and Communication, University of Granada, 18011 Granada, Spain

Research Interests

research evaluation; bibliometrics; altmetrics; scientific communication; scientific information sources



Dr. Nees Jan van Eck

 (<https://www.cwts.nl/people/neesjanvaneck>)  (<https://sciprofiles.com/profile/author/MEJack5yR1JGZXpBYkxSOWVyQk1rYVZmajJ1aThVbFVIZ1JuOHJITUUxRT0=>)

Affiliation



Centre for Science and Technology Studies (CWTS), Leiden University, Kolffpad 1, 2333
BN Leiden, The Netherlands

Research Interests

bibliometrics; big data; data mining; network analysis; scientometrics; text mining;
visualization



Professor Dr. Dangzhi Zhao

 (<http://www.ualberta.ca/~dzhao/>)  (<https://sciprofiles.com/profile/dangzhi-zhao>)

Affiliation

School of Library and Information Studies, University of Alberta, Edmonton T6G, Canada

Research Interests

information systems; bibliometrics; scholarly communication; knowledge network analysis



Prof. Dr. Ping Zhou

 (<https://person.zju.edu.cn/en/pingzhou>)  (<https://sciprofiles.com/profile/328423>)

Affiliation

Department of Information Resources Management, School of Public Affairs, Zhejiang
University, Hangzhou 310059, China

Research Interests

research evaluation; scientometrics and informetrics; science policy



Publishing in open access journals may not be financially feasible since article processing charges are often high. In Acta Dermatovenerol APA, we would like to promote original clinical and scientific research that would not be submitted otherwise because of authors' financial restrictions. Recently, we have observed a large increase in the number of manuscripts submitted to our journal. In order to assure timely publication of most influential research, we have decided to **reinstate article processing charges (250€ per manuscript) for all types of manuscripts (e.g. original articles, review articles, case reports and letters to the editor) submitted to Acta Dermatovenerol APA from September 3rd 2020 onward.**

Volume 32 (2023)

[Issue 1 \(/journals/acta-dermatovenerol-apa/papers/10.2478/volume32-issue1.pdf\)](/journals/acta-dermatovenerol-apa/papers/10.2478/volume32-issue1.pdf)

[Alterations in the spatiotemporal expression pattern of geminin during human epidermal morphogenesis \(/journals/acta-dermatovenerol-apa/papers/10.15570/actaapa.2023.1/actaapa.2023.1.pdf\)](/journals/acta-dermatovenerol-apa/papers/10.15570/actaapa.2023.1/actaapa.2023.1.pdf)

Efstathia Pasmatzis, Alexandra Monastirli, Zoi Lygerou, Stavros Taraviras, Stavros Kakkos, George Stamatiou, Dionysios Tsambaos

DOI: <http://dx.doi.org/10.15570/actaapa.2023.1> (<http://dx.doi.org/10.15570/actaapa.2023.1>)

[Serum survivin in acne versus post-acne scarring and the possible effect of isotretinoin therapy on its level \(/journals/acta-dermatovenerol-apa/papers/10.15570/actaapa.2023.2/actaapa.2023.2.pdf\)](/journals/acta-dermatovenerol-apa/papers/10.15570/actaapa.2023.2/actaapa.2023.2.pdf)

Tarek Mahmoud Hussein, Nourane Tawfik Abdelsalam Tawfik, Mennatullah Mohamed Abbas Abd-Rabboh, Alsayeda Alsayed Ahmad Taha

DOI: <http://dx.doi.org/10.15570/actaapa.2023.2> (<http://dx.doi.org/10.15570/actaapa.2023.2>)

[Dermoscopy: the ultimate tool for diagnosis of nail psoriasis? A review of the diagnostic utility of dermoscopy in nail psoriasis \(/journals/acta-dermatovenerol-apa/papers/10.15570/actaapa.2023.3/actaapa.2023.3.pdf\)](/journals/acta-dermatovenerol-apa/papers/10.15570/actaapa.2023.3/actaapa.2023.3.pdf)

Ahu Yorulmaz

DOI: <http://dx.doi.org/10.15570/actaapa.2023.3> (<http://dx.doi.org/10.15570/actaapa.2023.3>)

[Treatment of periorbital syringomas with intradermal botulinum toxin A monotherapy versus carbon dioxide laser: a case report \(/journals/acta-dermatovenerol-apa/papers/10.15570/actaapa.2023.4/actaapa.2023.4.pdf\)](#)

Sheila Hustadi Budiawan, Abraham Arimuko, Lilik Norawati, Asnawi Madjid, Widya Widita

DOI: <http://dx.doi.org/10.15570/actaapa.2023.4> (<http://dx.doi.org/10.15570/actaapa.2023.4>)

[Linear IgA bullous dermatosis in an acute myeloid leukemia patient: a rare case report \(/journals/acta-dermatovenerol-apa/papers/10.15570/actaapa.2023.5/actaapa.2023.5.pdf\)](#)

Deisy Vania Kianindra, Amelia Rosa, Dina Pebriany, Wiwiek Dewiyanti, Asnawi Madjid

DOI: <http://dx.doi.org/10.15570/actaapa.2023.5> (<http://dx.doi.org/10.15570/actaapa.2023.5>)

[Primary biliary cholangitis—cause or association with psoriasis: a case report \(/journals/acta-dermatovenerol-apa/papers/10.15570/actaapa.2023.6/actaapa.2023.6.pdf\)](#)

Patricija Tomše, Valerija Balkovec

DOI: <http://dx.doi.org/10.15570/actaapa.2023.6> (<http://dx.doi.org/10.15570/actaapa.2023.6>)

[Trigeminal trophic syndrome, a rare and often overlooked cause of facial ulceration: a case report and literature review \(/journals/acta-dermatovenerol-apa/papers/10.15570/actaapa.2023.7/actaapa.2023.7.pdf\)](#)

Laura Đorđević Betetto, Vid Bajuk

DOI: <http://dx.doi.org/10.15570/actaapa.2023.7> (<http://dx.doi.org/10.15570/actaapa.2023.7>)

[Regression of a pigmented Spitzoid lesion in an adolescent \(/journals/acta-dermatovenerol-apa/papers/10.15570/actaapa.2023.8/actaapa.2023.8.pdf\)](#)

Maruša Jerše, Liljana Mervic

DOI: <http://dx.doi.org/10.15570/actaapa.2023.8> (<http://dx.doi.org/10.15570/actaapa.2023.8>)

Volume 31 (2022)

[Issue 4 \(/journals/acta-dermatovenerol-apa/papers/10.2478/volume31-issue4.pdf\)](#)

[Analysis of top-cited articles on melanoma \(/journals/acta-dermatovenerol-apa/papers/10.15570/actaapa.2022.22/actaapa.2022.22.pdf\)](#)

Ka Siu Fan, Ka Hay Fan, Pak Lim Tse, Hao Ding, Runqing Su, Hiu Tat Kwok

DOI: <http://dx.doi.org/10.15570/actaapa.2022.22> (<http://dx.doi.org/10.15570/actaapa.2022.22>)

[Steroid abuse, quality of life, and various risk factors in dermatophytosis: a cross-sectional observational study from a tertiary care center in northern India \(/journals/acta-dermatovenerol-apa/papers/10.15570/actaapa.2022.23/actaapa.2022.23.pdf\)](#)

Dilip Meena, Neirita Hazarika, Payal Chauhan, Pratika Goyal

DOI: <http://dx.doi.org/10.15570/actaapa.2022.23> (<http://dx.doi.org/10.15570/actaapa.2022.23>)

Body-focused repetitive behaviors in children and adolescents, clinical characteristics, and the effects of treatment choices on symptoms: a single-center retrospective cohort study (</journals/acta-dermatovenerol-apa/papers/10.15570/actaapa.2022.24/actaapa.2022.24.pdf>)

Zehra Topal Hangül, Taha Can Tuman, Bengü Altunay-Tuman, Gizem Yılmaz Saygılı, Ali Evren Tufan
DOI: <http://dx.doi.org/10.15570/actaapa.2022.24> (<http://dx.doi.org/10.15570/actaapa.2022.24>)

Chronic radiation dermatitis induced by cardiac catheterization: a case report and literature review (</journals/acta-dermatovenerol-apa/papers/10.15570/actaapa.2022.25/actaapa.2022.25.pdf>)

Ting Ting Cheng, Hui-Ju Yang

DOI: <http://dx.doi.org/10.15570/actaapa.2022.25> (<http://dx.doi.org/10.15570/actaapa.2022.25>)

A diagnostic challenge in an atypical variant of microcystic adnexal carcinoma mimicking ulcerative basal cell carcinoma: a case report and brief literature review (</journals/acta-dermatovenerol-apa/papers/10.15570/actaapa.2022.26/actaapa.2022.26.pdf>)

Nurul Indah Pratiwi, Khairuddin Djawad, Jonathan Kurnia Wijaya, Mahmud Ghaznawie, Siswanto Wahab, Airin Nurdin

DOI: <http://dx.doi.org/10.15570/actaapa.2022.26> (<http://dx.doi.org/10.15570/actaapa.2022.26>)

Immunity after mRNA COVID-19 vaccine and immunosuppressive therapy: correspondence (</journals/acta-dermatovenerol-apa/papers/10.15570/actaapa.2022.27/actaapa.2022.27.pdf>)

Rujittika Mungmunpantipantip, Viroj Wiwanitkit

DOI: <http://dx.doi.org/10.15570/actaapa.2022.27> (<http://dx.doi.org/10.15570/actaapa.2022.27>)

Issue 3 (</journals/acta-dermatovenerol-apa/papers/10.2478/volume31-issue3.pdf>)

Metastatic melanoma: clinicopathologic features and overall survival comparison (</journals/acta-dermatovenerol-apa/papers/10.15570/actaapa.2022.14/actaapa.2022.14.pdf>)

Selin Kestel, Feriha Pınar Uyar Göçün, Betül Öğüt, Özlem Erdem

DOI: <http://dx.doi.org/10.15570/actaapa.2022.14> (<http://dx.doi.org/10.15570/actaapa.2022.14>)

Insulin resistance in various grades of acanthosis nigricans (</journals/acta-dermatovenerol-apa/papers/10.15570/actaapa.2022.15/actaapa.2022.15.pdf>)

Sudha Banti, T. K. Sumathy, Kalra Pramila

DOI: <http://dx.doi.org/10.15570/actaapa.2022.15> (<http://dx.doi.org/10.15570/actaapa.2022.15>)

Skin and gut microbiota dysbiosis in autoimmune and inflammatory skin diseases (</journals/acta-dermatovenerol-apa/papers/10.15570/actaapa.2022.16/actaapa.2022.16.pdf>)

Špela Šuler Baglama, Katarina Trčko

DOI: <http://dx.doi.org/10.15570/actaapa.2022.16> (<http://dx.doi.org/10.15570/actaapa.2022.16>)

Successful low-dose corticosteroid treatment of aggressive pyoderma gangrenosum with irritable bowel syndrome: a case report (</journals/acta-dermatovenerol-apa/papers/10.15570/actaapa.2022.17/actaapa.2022.17.pdf>)

Faridha Ilyas

DOI: <http://dx.doi.org/10.15570/actaapa.2022.17> (<http://dx.doi.org/10.15570/actaapa.2022.17>)
[A single dose of benzathine penicillin G as an effective treatment for malignant syphilis in an HIV-positive patient: a case report \(/journals/acta-dermatovenerol-apa/papers/10.15570/actaapa.2022.18/actaapa.2022.18.pdf\)](#)

Natalia Tanojo, Dwi Murtiastutik, Maylita Sari, Astindari, Septiana Widyantari, Afif Nurul Hidayati, Diah Mira Indramaya

DOI: <http://dx.doi.org/10.15570/actaapa.2022.18> (<http://dx.doi.org/10.15570/actaapa.2022.18>)

[A multidisciplinary approach to a patient with vulvodinia: a successful treatment and outcome \(/journals/acta-dermatovenerol-apa/papers/10.15570/actaapa.2022.19/actaapa.2022.19.pdf\)](#)

Ina Novak-Hlebar, Marija Crnković, Ivka Djaković, Tihana Magdić-Turković, Tomislav Petričević, Liborija Lugović-Mihić

DOI: <http://dx.doi.org/10.15570/actaapa.2022.19> (<http://dx.doi.org/10.15570/actaapa.2022.19>)

[Scrotal calcinosis in a patient treated with isotretinoin: a rare entity \(/journals/acta-dermatovenerol-apa/papers/10.15570/actaapa.2022.20/actaapa.2022.20.pdf\)](#)

Mohamad Abou Chakra, Mouatasem Jida, Elie Hanna, Michael Peyromaure, Nicolas Barry Delongchamps, Sabine Roux, Igor Duquesne

DOI: <http://dx.doi.org/10.15570/actaapa.2022.20> (<http://dx.doi.org/10.15570/actaapa.2022.20>)

[Humoral and cellular immunity after mRNA COVID-19 vaccine in psoriatic patients on biological or immunosuppressive therapy: a real-life experience \(/journals/acta-dermatovenerol-apa/papers/10.15570/actaapa.2022.21/actaapa.2022.21.pdf\)](#)

Giulio Rizzetto, Federico Diotallevi, Giulia Radi, Elisa Molinelli, Oriana Simonetti, Luca Butini, Andrea Costantini, Anna Maria Offidani

DOI: <http://dx.doi.org/10.15570/actaapa.2022.21> (<http://dx.doi.org/10.15570/actaapa.2022.21>)

[Issue 2 \(/journals/acta-dermatovenerol-apa/papers/10.2478/volume31-issue2.pdf\)](#)

[Uncombable hair syndrome and beyond \(/journals/acta-dermatovenerol-apa/papers/10.15570/actaapa.2022.7/actaapa.2022.7.pdf\)](#)

Manahel Mahmood Alsabbagh

DOI: <http://dx.doi.org/10.15570/actaapa.2022.7> (<http://dx.doi.org/10.15570/actaapa.2022.7>)

[Malassezia virulence factors and their role in dermatological disorders \(/journals/acta-dermatovenerol-apa/papers/10.15570/actaapa.2022.8/actaapa.2022.8.pdf\)](#)

Ivan Kurniadi, Wong Hendra Wijaya, Kris Herawan Timotius

DOI: <http://dx.doi.org/10.15570/actaapa.2022.8> (<http://dx.doi.org/10.15570/actaapa.2022.8>)

[Trends in dermatological practice in work with patients with skin diseases during the COVID-19 pandemic: our experience and observations \(/journals/acta-dermatovenerol-apa/papers/10.15570/actaapa.2022.9/actaapa.2022.9.pdf\)](#)

Liborija Lugović-Mihić, Vedrana Bulat, Nives Pondeljak

DOI: <http://dx.doi.org/10.15570/actaapa.2022.9> (<http://dx.doi.org/10.15570/actaapa.2022.9>)
[In-transit metastasis of cutaneous squamous cell carcinoma: report of two cases \(/journals/acta-dermatovenerol-apa/papers/10.15570/actaapa.2022.10/actaapa.2022.10.pdf\)](#)

Dua Cebeci, Şirin Yaşar, Pembegül Güneş, İlyas Enes Sılay

DOI: <http://dx.doi.org/10.15570/actaapa.2022.10> (<http://dx.doi.org/10.15570/actaapa.2022.10>)

[Diagnostic challenge of Strongyloides stercoralis hyperinfection syndrome: a case report](#)

[\(/journals/acta-dermatovenerol-apa/papers/10.15570/actaapa.2022.11/actaapa.2022.11.pdf\)](#)

Anja Šterbenc, Barbara Šoba, Urška Glinšek Biškup, Miša Fister, Urša Mikuž, Marko Noč, Boštjan Luzar

DOI: <http://dx.doi.org/10.15570/actaapa.2022.11> (<http://dx.doi.org/10.15570/actaapa.2022.11>)

[Cutaneous leukocytoclastic vasculitis following COVID-19 vaccination with Ad26.COV2.S vaccine: a case report and literature review \(/journals/acta-dermatovenerol-](#)

[apa/papers/10.15570/actaapa.2022.12/actaapa.2022.12.pdf\)](#)

Laura Đorđević Betetto, Boštjan Luzar, Živa Pipan Tkalec, Svjetlana Ponorac

DOI: <http://dx.doi.org/10.15570/actaapa.2022.12> (<http://dx.doi.org/10.15570/actaapa.2022.12>)

[Skin involvement in Francisella tularensis infection: a case report of two clinical cases \(/journals/acta-dermatovenerol-apa/papers/10.15570/actaapa.2022.13/actaapa.2022.13.pdf\)](#)

Maja Prah, Ana Kenk, Jana Rejc Marko

DOI: <http://dx.doi.org/10.15570/actaapa.2022.13> (<http://dx.doi.org/10.15570/actaapa.2022.13>)

[Issue 1 \(/journals/acta-dermatovenerol-apa/papers/10.2478/volume31-issue1.pdf\)](#)

[Thoracoabdominal computed tomography neoplasia detection in patients with paraneoplastic](#)

[pemphigus: the importance of collaboration between specialists \(/journals/acta-dermatovenerol-](#)

[apa/papers/10.15570/actaapa.2022.1/actaapa.2022.1.pdf\)](#)

Corrado Tagliati, Giulio Rizzetto, Giuseppe Lanni, Matteo Marcucci, Giulio Argalia, Gabriella Lucidi Pressanti, Oriana Simonetti, Annamaria Offidani

DOI: <http://dx.doi.org/10.15570/actaapa.2022.1> (<http://dx.doi.org/10.15570/actaapa.2022.1>)

[The association between bullous pemphigoid and comorbidities: a case-control study in Moroccan](#)

[patients \(/journals/acta-dermatovenerol-apa/papers/10.15570/actaapa.2022.2/actaapa.2022.2.pdf\)](#)

Hicham Titou, Hasna Kerrouch, Rachid Frikh, Naoufal Hjira

DOI: <http://dx.doi.org/10.15570/actaapa.2022.2> (<http://dx.doi.org/10.15570/actaapa.2022.2>)

[The role of cytokines in atopic dermatitis: a breakthrough in immunopathogenesis and treatment](#)

[\(/journals/acta-dermatovenerol-apa/papers/10.15570/actaapa.2022.3/actaapa.2022.3.pdf\)](#)

Manahel Alsabbagh, Amina Ismaeel

DOI: <http://dx.doi.org/10.15570/actaapa.2022.3> (<http://dx.doi.org/10.15570/actaapa.2022.3>)

[Unrecognized Bowen's disease in previously treated condylomata acuminata: indication of a common etiology?](http://dx.doi.org/10.15570/actaapa.2022.4) (/journals/acta-dermatovenerol-apa/papers/10.15570/actaapa.2022.4/actaapa.2022.4.pdf)

Melita Vukšić Polić, Nataša Cutvarić, Ksenija Marjanović, Martina Mihalj

DOI: <http://dx.doi.org/10.15570/actaapa.2022.4> (<http://dx.doi.org/10.15570/actaapa.2022.4>)

[Incontinentia pigmenti / Bloch–Sulzberger syndrome: a case report](http://dx.doi.org/10.15570/actaapa.2022.5) (/journals/acta-dermatovenerol-apa/papers/10.15570/actaapa.2022.5/actaapa.2022.5.pdf)

Dyah Ayu Nirmalasari, Farida Tabri, Nurelly Waspodo, Sri Rimayani, Anni Adriani

DOI: <http://dx.doi.org/10.15570/actaapa.2022.5> (<http://dx.doi.org/10.15570/actaapa.2022.5>)

[Trichorhinophalangeal syndrome: a case report and brief literature review](http://dx.doi.org/10.15570/actaapa.2022.6) (/journals/acta-dermatovenerol-apa/papers/10.15570/actaapa.2022.6/actaapa.2022.6.pdf)

Oriana Simonetti, Giulia Radi, Elisa Molinelli, Federico Diotallevi, Annamaria Offidani

DOI: <http://dx.doi.org/10.15570/actaapa.2022.6> (<http://dx.doi.org/10.15570/actaapa.2022.6>)

[Supplement](#) (/journals/acta-dermatovenerol-apa/papers/supplement/supplement_032022)

Volume 30 (2021)

[Issue 4](http://dx.doi.org/10.15570/actaapa.2021.31) (/journals/acta-dermatovenerol-apa/papers/10.2478/volume30-issue4.pdf)

[Obtaining an impact factor: mission impossible for Acta Dermatovenerologica Alpina, Pannonica et Adriatica](http://dx.doi.org/10.15570/actaapa.2021.31) (/journals/acta-dermatovenerol-apa/papers/10.15570/actaapa.2021.31/actaapa.2021.31.pdf)

Jovan Miljković, Anja Šterbenc

DOI: <http://dx.doi.org/10.15570/actaapa.2021.31> (<http://dx.doi.org/10.15570/actaapa.2021.31>)

[Cicatricial alopecia: do clinical, trichoscopic, and histopathological diagnosis agree?](http://dx.doi.org/10.15570/actaapa.2021.32) (/journals/acta-dermatovenerol-apa/papers/10.15570/actaapa.2021.32/actaapa.2021.32.pdf)

Ahmed Abdel Bary, Marwa Eldeeb, Eman Hassan

DOI: <http://dx.doi.org/10.15570/actaapa.2021.32> (<http://dx.doi.org/10.15570/actaapa.2021.32>)

[Clinical profile of cutaneous tuberculosis at Nashik](http://dx.doi.org/10.15570/actaapa.2021.33) (/journals/acta-dermatovenerol-apa/papers/10.15570/actaapa.2021.33/actaapa.2021.33.pdf)

Vikrant M Jadhav, Manoj T Waghmare

DOI: <http://dx.doi.org/10.15570/actaapa.2021.33> (<http://dx.doi.org/10.15570/actaapa.2021.33>)

[Prevalence of and risk factors for sexually transmitted infection with Chlamydia trachomatis to guide control measures: findings from the Slovenian National Survey of Sexual Lifestyles, Attitudes, and Health in 2016–2017](http://dx.doi.org/10.15570/actaapa.2021.34) (/journals/acta-dermatovenerol-apa/papers/10.15570/actaapa.2021.34/actaapa.2021.34.pdf)

A single dose of benzathine penicillin G as an effective treatment for malignant syphilis in an HIV-positive patient: a case report

Natalia Tanojo¹, Dwi Murtiastutik¹, Maylita Sari¹, Astindari¹, Septiana Widyantari¹, Afif Nurul Hidayati¹, Diah Mira Indramaya¹✉

¹Department of Dermatology and Venereology, Faculty of Medicine, Universitas Airlangga/Dr. Soetomo General Academic Hospital, Surabaya, Indonesia.

Abstract

Malignant syphilis (MS) is a rare, atypical manifestation of secondary syphilis. Ulcerative lesions should be suspected as MS when found with supporting microscopic morphology, a high syphilis serology titer test, a Jarisch–Herxheimer reaction (JHR), and rapid disease resolution. To date, there is no specific recommendation for treatment for MS. A 24-year-old HIV-positive MSM patient with a CD4 count of 470 cells/ μ l presented with a chief complaint of necrotic, ulcerative lesions and oyster shell–like surface plaques on his face, trunk, groin, and extremities. The patient also developed various typical presentations of secondary syphilis. Dark-field microscopy revealed spirochetes. Histopathological examination showed spongiotic dermatitis with many neutrophil cells in the dermis, together with endarteritis and fibrin micro-thrombus in the blood vessels. The patient had a high venereal disease research laboratory (VDRL) titer of 1:512. There was rapid disease resolution following a single injection of 2,400,000-unit benzathine penicillin G (BPG); together with anti-retroviral therapy, this was supportive treatment for MS. JHR was not observed in this study and many other reports. This case showed that ulcerative lesions with an oyster shell–like surface presenting in HIV-positive patients along with supporting microscopic morphology, high VDRL titer, and a dramatic improvement after antibiotic treatment is highly suggestive of MS. JHR may no longer be a characteristic of MS. A single dose of 2,400,000-unit BPG is sufficient for MS treatment.

Keywords: sexually transmitted diseases, syphilis, secondary syphilis, HIV, MSM

Received: 15 February 2022 | Returned for modification: 10 May 2022 | Accepted: 15 June 2022

Introduction

Malignant syphilis (MS) is a rare, atypical manifestation of secondary syphilis more commonly found in immunocompromised individuals (1). In 1989, Fishers et al. proposed that clinical findings of syphilis with ulcerative lesions and an oyster shell–like surface resembling skin malignancy are suggestive of MS when found together with supporting microscopic morphology, a high syphilis serology titer, a Jarisch–Herxheimer reaction (JHR), and rapid disease resolution (2). To date, there is no specific recommended treatment for MS (3). Although the most commonly used treatment regimen is three consecutive weekly intramuscular injections of 2,400,000-unit benzathine penicillin G (BPG), a single dose of BPG, which follows the recommendation of secondary syphilis treatment, may be adequate to treat MS (3, 4). JHR is a transient reaction following antibiotic treatment, which may result from a high serology titer in MS (3). We report a case of secondary syphilis in an HIV-positive MSM (men who have sex with men) patient that was eventually diagnosed as MS. The case showed rapid resolution following a single dose of BPG injection with no JHR.

Case report

A 24-year-old HIV-positive MSM patient presented with a chief complaint of generalized rash on his body for the previous 2 months that had not been itchy or painful. His primary concern was visible generalized lesions, which hindered his occupation as a salesperson and part-time model. The lesions were initially

believed to be herpes zoster infection; however, no improvement was seen after oral acyclovir treatment. The initial hospital then tested the patient for HIV before referring him to our hospital. The patient had engaged in sexual behavior with no protection with the same male partner for the previous 2 years before breaking up 2 months before referral. The HIV status of the male partner was unknown. He denied having multiple partners.

Dermatological examination revealed multiple ulcerated lesions with an oyster shell–like surface on the patient's face, trunk, inguinal area, and upper extremities (Fig. 1a, 1b), erythematous macules and papules with a crown-like pattern on the frontalis region (corona veneris; Fig. 2a), multiple, well-demarcated, annular erythematous macules on the palms and soles (syphilitic roseola; Fig. 2b, 2d), painless penile and scrotal ulcers varying in size from 1 × 1 cm to 2 × 2 cm, with a depth of 0.2–0.5 cm, some of which had coalesced to form islands with a granulated base without pus (Fig. 2c), and multiple flat-topped lenticular papules measuring 0.8–1 cm in diameter surrounding his anus (condylomata lata; Fig. 2e) without lymph node enlargement.

We performed further analysis on the ulcerated lesions and anal papules and found flat spirochete bacteria that moved in a corkscrew pattern on darkfield microscopy. The skin biopsy and histopathological examination on the ulcerated lesions indicated spongiotic dermatitis with abundant neutrophils in the dermis, endarteritis, and fibrin micro-thrombus in the blood vessels (Fig. 1c, 1d). The anal papules showed characteristics of condylomata lata with acanthosis, spongiosis, rete ridge lengthening, no koilocytosis or papillomatosis, dilated capillary vessels in the dermis, and inflammatory cell infiltrates of neutrophils, eosinophils, and

✉ Corresponding author: idiahmira@yahoo.com

lymphocytes (Fig. 2f). Blood examination showed a Venereal Disease Research Laboratory (VDRL) titer of 1:512 with reactive *Treponema pallidum* hemagglutination assay (TPHA). The patient had positive HIV serology testing with a CD4 count of 470 cells/ μ l.

Based on these findings, the patient was diagnosed with malignant syphilis and HIV. He was treated with a single intramuscular injection of 2,400,000-unit BPG in addition to antiretroviral drugs consisting of efavirenz 600 mg, lamivudine 300 mg, and tenofovir 300 mg. One month after BPG treatment, a remarkable clearance with only residual hyperpigmented patches was observed. The serology test showed a dramatic decrease in VDRL titer to 1:32. We continued the observation for a month before referring the patient back to the initial hospital to continue his HIV medication. The patient was relieved of his primary concern but decided to continue the medication, especially to improve the hyperpigmentation of his skin.

Discussion

The clinical manifestations of secondary syphilis in HIV-positive populations may follow typical presentations such as syphilitic roseola, Biètt's collarette, corona veneris, clavi syphilitici, moth-eaten alopecia, plantar lesions, and condylomata lata (5). However, atypical or a more severe form of syphilis may develop due to the decrease in CD4+ T-cell count and increased HIV viral load (3, 6). Although MS cases were more common in HIV-positive indi-

viduals, the CD4+ T-cell count was relatively high (200–499 cells/ μ l) (3). Immunocompetent individuals are also at risk of MS (7). These findings are in line with our case, in which MS was found in an HIV-positive individual with a CD4+ count of 470 cells/ μ l, supporting the possibility of a more virulent strain of *Treponema* as the etiology (3, 7).

The underlying pathogenesis of MS may differ from classic syphilis due to CD4 T-cell depletion, which leads to an exaggerated action of cytotoxic T cells and neutrophils (3, 8). The most common histopathological finding of MS is lymphohistiocytic infiltrate rich in plasma cells in the dermis (3). Other findings may include endothelial cell swelling, proliferation, necrosis, and lumen occlusion by thrombus in blood vessels (8).

Treatment of syphilis with HIV coinfection follows that of non-HIV patients (9). The Centers for Disease Control and Prevention recommends that HIV-coinfected secondary syphilis be treated with a single-dose of intramuscular 2,400,000-unit BPG injection (5). However, a survey indicated that physicians in the United States and Europe opted for a more intensive regimen of antibiotics for HIV co-infected individuals. Major concerns lie in the difference in clinical features in HIV, impaired host immunity, a higher rate of asymptomatic neurological involvement, and slower serological response (4). There was no notable serological difference in treatment of single-dose versus three-dose BPG in HIV co-infected individuals, suggesting that the international recommendation of a single dose of BPG is sufficient in acute infection

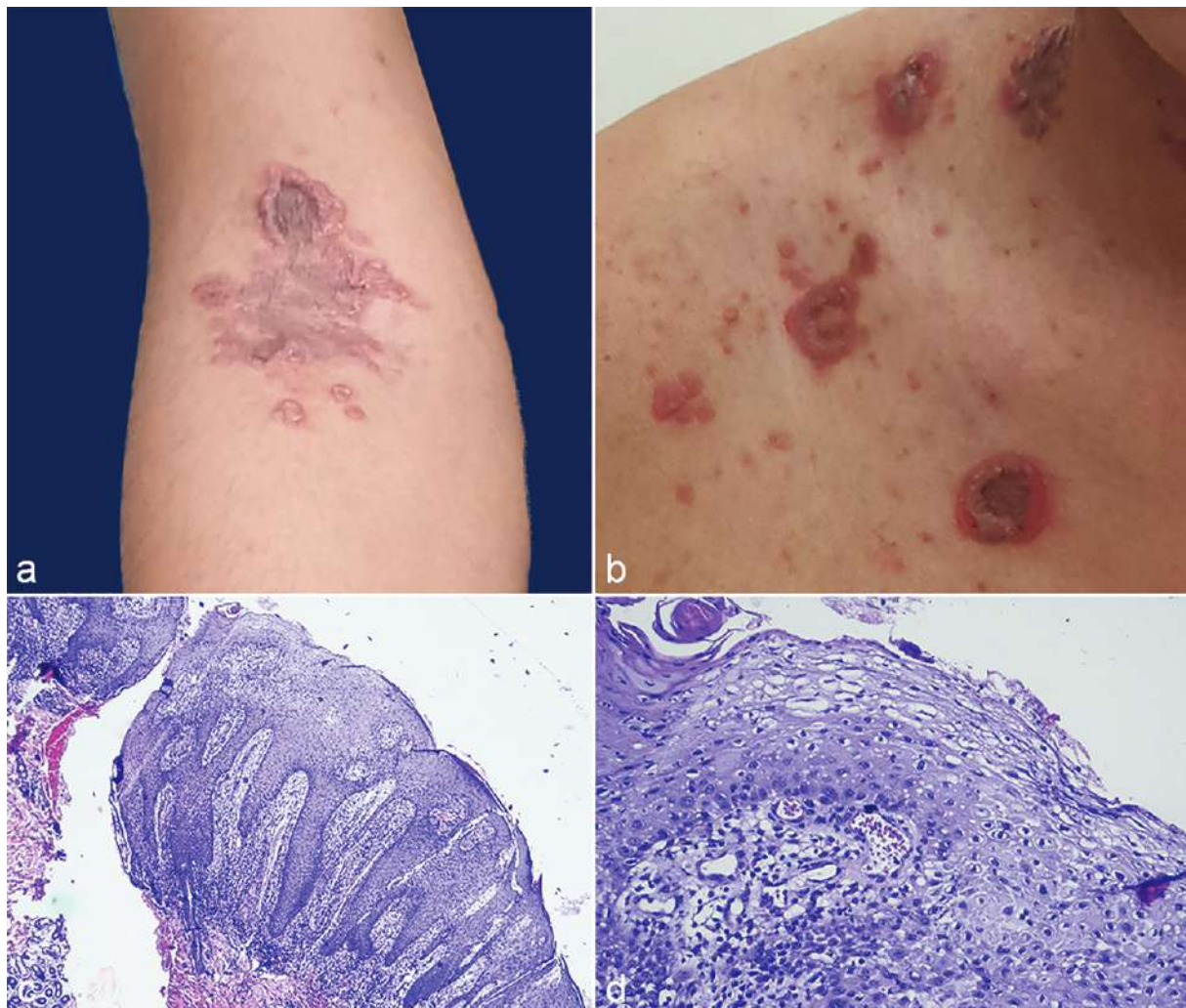


Figure 1 | Multiple erythematous to copper-colored annular maculopapular lesions, some with a necrotic, ulcerative center and an oyster shell-like surface on the (a) arm and (b) trunk. Histopathological examination of the lesions on the arm are shown at (c) 40 \times and (d) 100 \times .

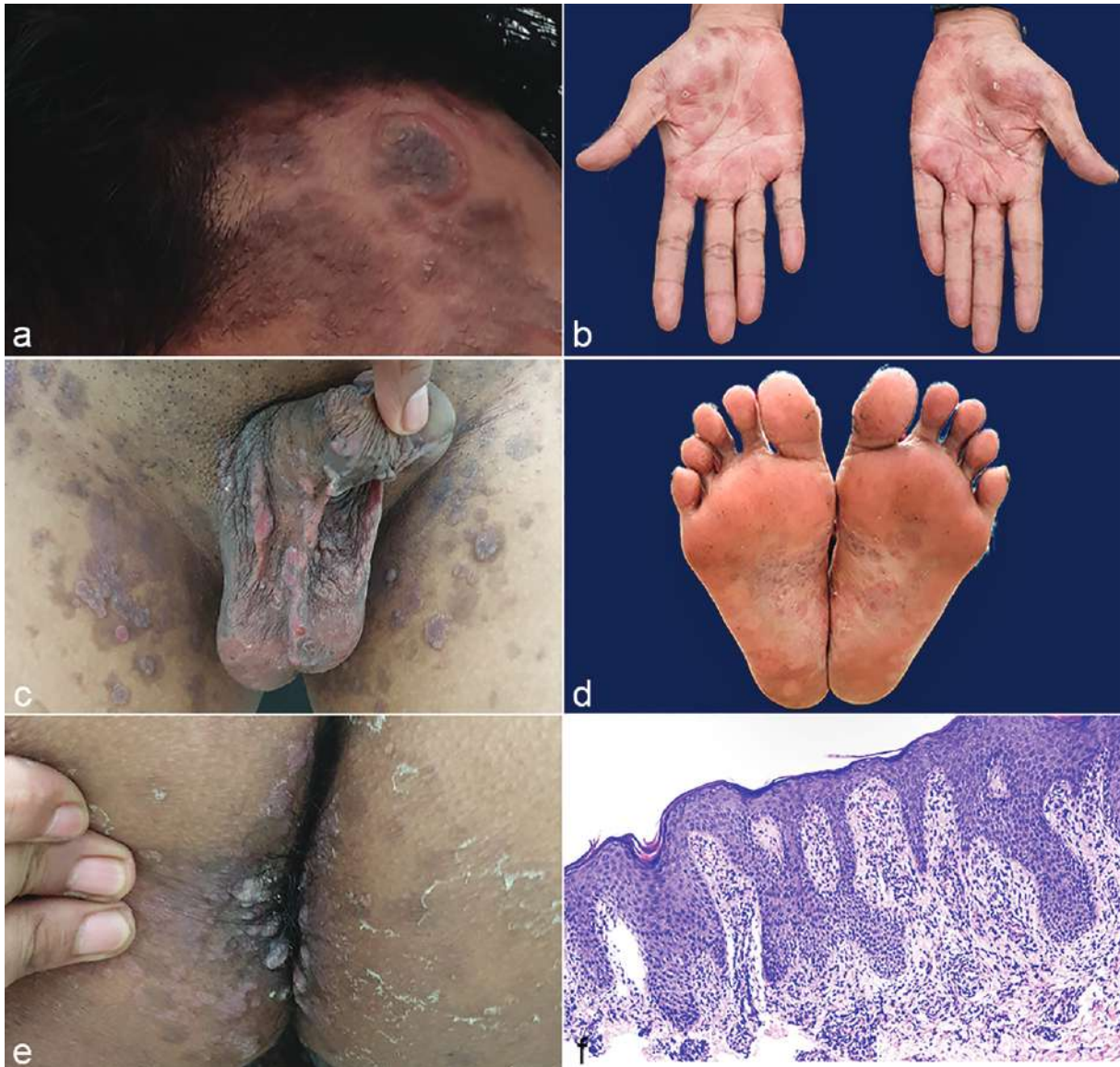

Figure 2 | Lesions of primary and secondary syphilis, showing (a) corona veneris, (b, d) syphilitic roseola, (c) penile and scrotal ulcers, and (e) condylomata lata, as well as (f) histopathological examination of the condylomata lata.

(10). Out of 28 reported MS cases that were treated with BPG in 2014–2018, 71.4% received three doses of BPG whereas only 28.6% had a single dose of BPG. Nevertheless, all cases displayed clinical improvement, regardless of the dose (3). A remarkable clinical improvement with a dramatic decrease in VDRL titer after a single dose of BPG treatment, as in this case, supports the notion that MS can be treated with the same dose as typical secondary syphilis without the need for additional doses.

JHR is a transient immunologic phenomenon hypothesized to result from cytokine release following death of *T. pallidum* microorganisms (5). Clinical manifestations of JHR include high fever accompanied by headache, chills, myalgia, and rigors within 24 hours after initiating therapy (5, 9). Although the high serologic titer found in MS is suggestive of abundant bacteria, the death of which may elicit the JHR formation, a more recent finding has suggested that JHR only occurred in 20% of MS cases (3). The reaction was also not observed in our case.

Rapid disease resolution can be observed in MS patients, in

contrast to the slower rate of serologic decline that is more common in syphilis with HIV coinfection (3, 9). Clinical improvement of MS can be observed in as soon as 2 days to 3 months following antibiotic treatment (3). In our case, we observed rapid clinical resolution that completely resolved 4 weeks after treatment.

Conclusions

MS should be suspected in HIV patients presenting with ulcerative lesions with an oyster shell-like surface. A greater action of cytotoxic T cells and neutrophils on the skin with MS may explain the histopathological findings of neutrophil infiltrate in the dermis and lumen occlusion by thrombus in blood vessels found in our case. A single dose of BPG intramuscular injection is a sufficient MS treatment in immunocompromised individuals. High VDRL with dramatic improvement following antibiotic treatment could be observed in this case. JHR may no longer be characteristic of MS, as supported by other studies.

References

1. Mitteldorf C, Plumbaum H, Zutt M, Schön MP, Kaune KM. CD8-positive pseudo-lymphoma in lues maligna and human immunodeficiency virus with monoclonal T-cell receptor-beta rearrangement. *J Cutan Pathol.* 2019;46:204–10.
2. Fisher DA, Chang LW, Tuffanelli DL. Lues maligna: presentation of a case and a review of the literature. *Arch Dermatol.* 1969;99:70–3.
3. Wibisono O, Idrus I, Djawad K. Malignant syphilis: a systematic review of the case reports published in 2014–2018. *Actas Dermosifiliogr (Engl Ed).* 2021;S0001-7310(21)00135-6.
4. Cresswell FV, Fisher M. Management of syphilis in HIV-positive individuals. *Sex Health.* 2015;12:135–40.
5. Tuddenham SA, Zenilman JM. Syphilis. In: Kang S, Amagai M, Bruckner AL, Enk AH, Margolis DJ, McMichael AJ, et al., editors. *Fitzpatrick's dermatology in general medicine.* 9th ed. New York: McGraw Hill; 2019. p. 3145–72.
6. Yancheva N, Petrova E, Tchervenyakova T. Atypical secondary syphilis presentation in a patient with human immunodeficiency virus infection: a case report. *J Med Case Rep.* 2019;13:360.
7. Requena CB, Orasmo CR, Ocanha JP, Barraviera SRCS, Marques MEA, Marques SA. Malignant syphilis in an immunocompetent female patient. *An Bras Dermatol.* 2014;89:970–2.
8. Barros D'Elia Zanella LGFA, Facchini Lellis R, Khoury Z, Keiko Matsuka Oyafuso L, Figueiredo-Mello C. Rupoid lesions, PLEVA and superposition phenomenon in malignant syphilis: two case reports in HIV-infected patients. *J Eur Acad Dermatol Venereol.* 2018;32:e91–2.
9. Janier M, Unemo M, Dupin N, Tiplica GS, Potočník M, Patel R. 2020 European guideline on the management of syphilis. *J Eur Acad Dermatol Venereol.* 2021;35:574–88.
10. Costa-Silva M, Azevedo C, Azevedo F, Lisboa C. Early syphilis treatment in HIV-infected patients: single dose vs. three doses of benzathine penicillin G. *J Eur Acad Dermatol Venereol.* 2016;30:1805–9.