

13. Condyloma acuminata overlapping

by Frizka Eliza

Submission date: 09-Apr-2023 09:45AM (UTC+0800)

Submission ID: 2059276212

File name: 13._Condyloma_acuminata_overlapping.pdf (269.31K)

Word count: 2486

Character count: 13707

How to Cite:

Eliza, F., Damayanti, D., Misalina, K., Widyantari, S., Hidayati, A. N., & Murtiastutik, D. (2022). Condyloma acuminata overlapping bacterial vaginosis under steroid therapy for SLE: A case report. *International Journal of Health Sciences*, 6(S9), 179–185.
<https://doi.org/10.53730/ijhs.v6nS9.12180>

Condyloma acuminata overlapping bacterial vaginosis under steroid therapy for SLE: A case report

Frizka Eliza

Department of Dermatology and Venereology, Faculty of Medicine, Universitas Airlangga/Dr. Soetomo General Academic Hospital, Surabaya, Indonesia

Damayanti

Department of Dermatology and Venereology, Faculty of Medicine, Universitas Airlangga/Dr. Soetomo General Academic Hospital, Surabaya, Indonesia
Corresponding author email: damayanti@fk.unair.ac.id

Kartika Misalina

Department of Dermatology and Venereology, Faculty of Medicine, Universitas Airlangga/Dr. Soetomo General Academic Hospital, Surabaya, Indonesia

Septiana Widyantari

Department of Dermatology and Venereology, Faculty of Medicine, Universitas Airlangga/Dr. Soetomo General Academic Hospital, Surabaya, Indonesia

Afif Nurul Hidayati

Department of Dermatology and Venereology, Faculty of Medicine, Universitas Airlangga/Dr. Soetomo General Academic Hospital, Surabaya, Indonesia

Dwi Murtiastutik

Department of Dermatology and Venereology, Faculty of Medicine, Universitas Airlangga/Dr. Soetomo General Academic Hospital, Surabaya, Indonesia

Abstract--Infections of the genitals, including infections caused by the human papillomavirus (HPV) are still quite common in Indonesia country. The general population that is often found in this case is HPV 16 and 18. Condyloma acuminata (CA) is an infection of HPV in the vaginal region that causes a cauliflower-like benign tumor. Infection is one of the causes of morbidity and mortality in individuals with systemic lupus erythematosus (SLE), and this illness might increase the risk of human papillomavirus (HPV) infection, particularly condyloma acuminatum.

Keywords---condyloma acuminata, HPV, bacterial vaginosis, SLE, sexually transmitted diseases.

Introduction

Human papilloma virus (HPV) is the most common sexually transmitted disease (STD). Of the more than 100 distinct human papillomavirus 1 (HPV) types, at least 40 predominantly infect the genital epithelium (Widia et al., 2017). Infections of the genitalia, such as those caused by the human papillomavirus, are a major cause of morbidity and mortality in persons with systemic lupus erythematosus (SLE)(Rachman & Hasan, 2016). Bacterial vaginosis is the most common cause of abnormal vaginal discharge in women of reproductive age (BV). Infestations of this type are characterized by the destruction of the normal (hydrogen peroxide-producing) Lactobacillus-dominated vaginal microflora and the subsequent proliferation of huge numbers of anaerobic bacteria. The most prevalent ones are Atopobium vaginae, Mycoplasma hominis, Mobiluncus species, and Gardnerella vaginalis. At least 50% of patients are asymptomatic (Gillet et al., 2011).

Case Report

The author describes the case of a 49-year-old woman who presented with the major complaint of a lump around her genitalia. According to the patient, a lump in the genital area appeared for about 1 year ago, sometimes accompanied by itching, but the pain was denied. Initially the patient said that since the first lump appeared, there was no significant increase in size, but now the lump is getting bigger and bigger. Before the patient came to the skin and genital outpatient clinic, Dr. Soetomo Surabaya, since one month earlier the patient went to the internal medicine polyclinic to get SLE therapy which had been treated for the last 1 month. Currently, the patient is receiving treatment with Methylprednisolone 16 mg taken at a dose of 3 times daily and qhloroquine 250 mg per day. Since the patient took these drugs, the lesions were going to be getting bigger and more obvious like flesh that appeared to be the color of the skin. The lesions become more and more cauliflower-like and spread over several areas.

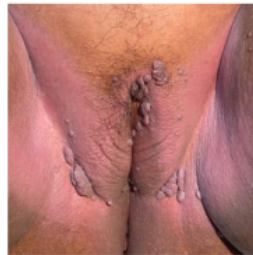

Figure 1. Dermatological status. Multiple nodul vary size with diameter 0,5 – 4 cm, verrucose surface and filiformis. The color of lession was like skin and form cauliflower like appearance.

Currently the patient also has a history of suffering from vaginal discharge since 2 years ago, the complaint of vaginal discharge was examined at the local health center and had improved, but the vaginal discharge did not take long to reappear and had not been treated until the patient came to the hospital. At the puskesmas, the patient also complained about the lump and only received topical medication, but the patient claimed that forgotten the name of the drug.

The patient has a husband and is the first wife, the patient's husband has 2 wives so that he often has sex alternately with his second wife since 2 years ago. According to the patient, her husband also had the same nodules or lumps as the patient on his genitals which was known for the past few years, but the husband refused to be treated or to be examined by a doctor. There were complaints of sores on the genitals, he denied, pain when urinating or discharge or pus from the penis was denied.

On physical examination, there were nodules of varying size with a diameter of 0.5-4 cm, clear boundaries, verrucous and filiform surfaces, the color of the lesions was the same as skin color and shaped like cauliflower. Histopathological examination showed that the squamous epithelium had hyperkeratosis and parakeratosis, as well as papillomatosis and acanthosis, which results were consistent with condyloma acuminata. From the results of the examination of fluor albus, in gram and wet preparations, clue cells are obtained which are a sign of confirming the diagnosis of bacterial vaginosis, and the whiff test also shows positive results.

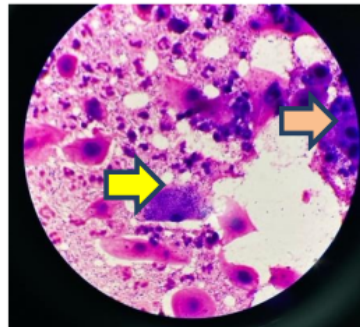


Figure 2. Gram staining result. Clue cell (yellow arrow) and poor lactobacillus (green arrow)

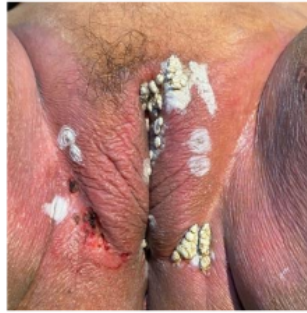

Figure 3. The current therapeutic procedure was performed with a combination of hefyrycauter and 90% TCA of the lesion

Discussion

In Indonesia, cervical cancer affects more women than any other type of cancer, although little is known about how frequent HPV is there. One study looked at the frequency of different forms of HPV and potential risk factors for HPV positivity in a population sample of 2686 women in Jakarta, Tasikmalaya, and Bali, Indonesia, spanning the ages of 15 to 70. Overall, the prevalence of HPV was 11.4%, with an age standard of 11.6% for the global population (Handayani et al., 2020; Vet et al., 2008).

One of the most prevalent types of STIs caused by HPV are genital warts (Lube et al., 2014) known as condylomata acuminata or venereal warts. Sexual contact is the main method of transmission for genital HPV infections. Barrett et al. studied on 24 women with genital warts who discovered the warts 4-6 weeks after their husbands had returned from the Far East, they first identified sexual transmission of clinically detectable HPV infection in 1954. All of the spouses admitted to having intercourse with women while traveling, and all of the husbands had recently developed penile warts (Rachman & Hasan, 2016; Toral, 2019). It's the same with in this case that the patient's husband also had the same lump complaint but refused to be treated and also one of the risk factor that occurs was having had more than one sexual partner (Vet et al., 2008)

According to some studies, 88 partners of people with genital warts saw a 64 percent wart development rate, with newly acquired warts being more contagious than older lesions (Winer & Koutsky, 2008). There have been few research that look at the association between immunosuppressive and steroid therapy in SLE patients and the incidence of condyloma acuminata. It could be due of its rarity, accounting for barely 0.1 percent of the total population (Rachman & Hasan, 2016)

In this patient, we did combination treatment with hefyrycauter and combined with TCA 90% for genital warts for 5 sessions, while for complaints of vaginal discharge in this patient we were given Metronidazole 500 mg twice a day for up to 7 days. Based on our experience, the results of this combination treatment for condyloma acuminata have quite satisfactory results, as well as bacterial vagino.

Rarely do people who have genital warts report any symptoms other than the development of fresh bumps or growths on their genitalia. Patients may occasionally complain of stinging, burning, discomfort, or bleeding. Some people with genital warts—possibly the majority—never become aware of them. The abnormal vaginal discharge that some women with external genital warts experience is likely caused by a concurrent vaginal infection, such as bacterial vaginosis, rather than by HPV (Winer & Koutsky, 2008).

⁴ The human papillomavirus is a double-stranded DNA virus that is not enclosed. So far, more than 200 different genotypes have been found. The genital tract can be infected by more than 40 mucosal HPV genotypes (Widia et al., 2017). According to their capacity to cause cancer, HPVs are categorized as either high or low risk. HPV types 6 and 11 cause around 90% of genital warts, while HPV types 16 and 18 cause cervical cancer (le Poole et al., 2008; Niazy et al., 2015; Yanofsky et al., 2012). After infection, HPV typically requires an incubation period ranging from a few weeks to 8 months before the appearance of clinical manifestations. Lesions appear approximately 2 to 3 months after initial contact (Kilic & Mete Ural, 2019)

¹¹ SLE is a systemic autoimmune disease characterized by a wide spectrum of clinical symptoms produced by a high level of autoantibodies that affect various internal organs. The risk of contracting the HPV is increased by steroid medication in people with SLE. Therefore, their correlation is still unclear. Steroids and immunosuppressants are commonly used to treat the condition. The risk of HPV infection in SLE patients may be increased by immunosuppressant and steroid therapy, according to certain studies (Rachman & Hasan, 2016).

The factors that relating condyloma in women <40 years to malignant disorders and immunosuppression are discussed in Durham. Within a population of 77 women with recalcitrant condyloma acuminatum, 16 women over the age of 40 were the subjects of the study. In conclusion, it has been stated that women over 40 with recurring condyloma acuminatum should be checked for immunosuppression as an underlying cause. For the best possible infection control, it's critical to look for concurrent diabetes mellitus or drugs that can make someone more susceptible to immunosuppression (Marshburn & Trofatter, 1988). In one study, an association between immunosuppression and malignancy in condyloma infection was described, particularly in older patients who had the most frequent infection recurrence, whereas patients with malignancy often received long-term immunosuppressive therapy (le Poole et al., 2008; Marshburn & Trofatter, 1988).

BV is a clinical syndrome due to the turnover of *Lactobacillus* spp. producing hydrogen peroxidase (H₂O₂) in the normal vagina (Karim & Barakbah, 2016). In women of childbearing age, bacterial vaginosis (BV) is among the most common causes of vaginal symptoms. BV alters the vaginal flora by decreasing *Lactobacilli* and increasing anaerobic bacteria. Certain genital infections can be spread by exposure to BV, as is well-known. There has been some conflicting evidence about the link between BV and HPV infection in the cervical region. In SLE patients, immunosuppressive and steroid medication may increase the chance of

contracting HPV. Contrary to popular belief, the link between BV and HPV infection has been inconsistent across research (Gillet et al., 2011).

Conclusion

In SLE patients, immunosuppressive and steroid medication may raise HPV infection risk and provoke bacterial vaginosis. External genital warts may cause an atypical vaginal discharge, which is most often caused by a concomitant vaginal infection such as bacteriophagesis. Due to the lack of research related to condyloma acuminata and its relationship with steroid administration in SLE patients and also relationship between the incidence of BV in condyloma acuminata, further research is needed in the future.

Acknowledgments

None.

References

- Gillet, E., Meys, J. F. A., Verstraelen, H., Bosire, C., de Sutter, P., Temmerman, M., & Broeck, D. v. (2011). Bacterial vaginosis is associated with uterine cervical human papillomavirus infection: A meta-analysis. *BMC Infectious Diseases*, *11*. <https://doi.org/10.1186/1471-2334-11-10>
- Handayani, S., Dewi, R., Wibowo, H., Dany, F., Kipuw, N., Adelina, R., Adam, K., Yunarto, N., Idaiani, S., & Kristanto, A. (2020). Cervical cancer risk factor: HPV infection among indonesian urban women. *Advances in Health Sciences Research*, *22*, 452–454.
- Karim, A., & Barakbah, J. (2016). Studi Retrospektif: Vaginosis Bakterial (Retrospective Study: Bacterial Vaginosis). *Berkala Ilmu Kesehatan Kulit Dan Kelamin*, *28*(3), 1–8.
- Kilic, A., & Mete Ural, U. (2019). Anogenital Warts: An Update on Human Papilloma Virus, Clinical Manifestations and Treatment Strategies. *Mucosa*, *30*–40. <https://doi.org/10.33204/mucosa.580103>
- le Poole, C., Denman, C. J., & Arbiser, J. L. (2008). Immunosuppression may be present within condyloma acuminata. *Journal of the American Academy of Dermatology*, *59*(6), 967–974. <https://doi.org/10.1016/j.jaad.2008.08.011>
- Lube, G. E., Aikawa, N. E., Tacla, M., Laurenco, B., Silva, L. E. V., & Queiroz, L. B. (2014). *Condyloma acuminatum in childhood-systemic lupus erythematosus patients* (Vol. 39).
- Marshburn, P. B., & Trofatter, K. F. (1988). Recurrent condyloma acuminatum in women over age 40: Association with immunosuppression and malignant disease. *American Journal of Obstetrics and Gynecology*, *159*(2), 429–433. [https://doi.org/10.1016/S0002-9378\(88\)80101-7](https://doi.org/10.1016/S0002-9378(88)80101-7)
- Muslimin, K. D., Baso, Y. S., Hidayanty, H., Syarif, S., Aminuddin, A., & Bahar, B. (2022). The effect of HIV/AIDS education prevention using web-based she smart on knowledge, attitudes, and practice in adolescent girls. *International Journal of Health & Medical Sciences*, *5*(1), 31–36. <https://doi.org/10.21744/ijhms.v5n1.1830>
- Niazy, F., Rostami, K., & Motabar, A. R. (2015). Giant Condyloma Acuminatum of Vulva Frustrating Treatment Challenge. In *World J Plast Surg* (Vol. 4, Issue 2). www.wjps.ir

- Rachman, A., & Hasan, N. (2016). Giant Condyloma Acuminata in Indonesian Females with SLE under Immunosuppressant and Steroid Therapy. *Case Reports in Immunology*, 2016, 1–6. <https://doi.org/10.1155/2016/4710979>
- Suryasa, I. W., Rodríguez-Gámez, M., & Koldoris, T. (2021). Get vaccinated when it is your turn and follow the local guidelines. *International Journal of Health Sciences*, 5(3), x-xv. <https://doi.org/10.53730/ijhs.v5n3.2938>
- Toral, J. A. B. (2019). *Prevalence of high-risk HPV in women with biopsy-proven condyloma acuminata* (J. A. B. Toral, Ed.; 1st ed., Vol. 43). PJOG.
- Vet, J. N. I., de Boer, M. A., van den Akker, B. E. W. M., Siregar, B., Lisnawati, Budiningsih, S., Tyasmorowati, D., Moestikaningsih, Cornain, S., Peters, A. A. W., & Fleuren, G. J. (2008). Prevalence of human papillomavirus in Indonesia: A population-based study in three regions. *British Journal of Cancer*, 99(1), 214–218. <https://doi.org/10.1038/sj.bjc.6604417>
- Widia, Y., Dewi Rahmadhani, S., & Nurul Hidayati, A. (2017). Kondilomata Akuminata pada Anak: Laporan Dua Kasus Jarang (Condylomata Acuminata in Children: Report of Two Rare Cases). *Berkala Ilmu Kesehatan Kulit Dan Kelamin*, 29(2), 175–181.
- Winer, R. L., & Koutsky, L. A. (2008). Genital Human Papillomavirus Infection. In *Sexually Transmitted Diseases* (Vol. 4, pp. 489–501).
- Yanofsky, V. R., Patel, R. v, & Goldenberg, G. (2012). Genital Warts. *The Journal Clinical Aesthetic Dermatology*, 6(6), 25–36. <https://jamanetwork.com/>

13. Condyloma acuminata overlapping

ORIGINALITY REPORT

13%

SIMILARITY INDEX

11%

INTERNET SOURCES

9%

PUBLICATIONS

0%

STUDENT PAPERS

PRIMARY SOURCES

1	downloads.hindawi.com Internet Source	1%
2	H. Dobrev. "Organization of the dermal matrix impacts the biomechanical properties of skin", <i>British Journal of Dermatology</i> , 2017 Publication	1%
3	Laura A. Koutsky, Pål WØlner-Hanssen. "Genital Papillomavirus Infections:", <i>Obstetrics and Gynecology Clinics of North America</i> , 1989 Publication	1%
4	ndl.ethernet.edu.et Internet Source	1%
5	www.slideshare.net Internet Source	1%
6	www.causesofcervicalcancer.com Internet Source	1%
7	diversityhealthcare.imedpub.com Internet Source	1%
8	www.hindawi.com Internet Source	1%

9	www.mdpi.com Internet Source	1 %
10	www.science.gov Internet Source	1 %
11	www.koreascience.or.kr Internet Source	1 %
12	pubmed.ncbi.nlm.nih.gov Internet Source	1 %
13	stii.dost.gov.ph Internet Source	1 %
14	amirkolalib.mubabol.ac.ir Internet Source	<1 %
15	balimedicaljournal.org Internet Source	<1 %
16	www.ijrcog.org Internet Source	<1 %
17	www.pubmedcentral.nih.gov Internet Source	<1 %

Exclude quotes On

Exclude matches Off

Exclude bibliography On

13. Condyloma acuminata overlapping

GRADEMARK REPORT

FINAL GRADE

/100

GENERAL COMMENTS

Instructor

PAGE 1

PAGE 2

PAGE 3

PAGE 4

PAGE 5

PAGE 6

PAGE 7
