

[Join as an Editor/Reviewer \(https://www.ijrp.org/join\)](https://www.ijrp.org/join)

Successful Treatment of Tinea Capitis Caused by *Microsporum canis* Using Griseofulvin

Volume: 93 , **Issue:** 1 , January **Published Date:** 20 January 2022**Publisher Name:** IJRP**Views:** 186 , **Download:** 148 , **Pages:** 134 - 142**DOI:** 10.47119/IJRP100931120222776 (<https://doi.org/10.47119/IJRP100931120222776>)

Authors

#	Author Name
1	Brigita Ika Rosdiana
2	Yuri Widia
3	Linda Astari
4	Evy Ervianti
5	Dwi Murtiastutik

[Download PDF \(https://www.ijrp.org/filePermission/fileDownload/4/a965f41eaf418666a0b8f6cee965a702/2\)](https://www.ijrp.org/filePermission/fileDownload/4/a965f41eaf418666a0b8f6cee965a702/2)

Abstract

Tinea capitis is a scalp and hair follicle dermatophyte infection caused by Trichophyton sp. and Microsporum sp. that more commonly affect children than adults. Microsporum canis is the most common dermatophyte causing tinea capitis reported in Asia that respond well to griseofulvin. We report one case of an 8-year-old child with a history of patchy scaling lesion on the head, alopecia, and pruritus. Dermatological examination revealed multiple scaly erythematous macules, circular shape, sharply marginated, with a diameter of 2?6 cm, along with alopecia in each lesion. KOH preparation, wood lamp examination, trichoscopy, and fungal culture were performed. The diagnosis of tinea capitis grey patch type with an etiology of Microsporum canis was established. The patient was significantly improved clinically and mycologically with four weeks course of oral griseofulvin and adjuvant treatment using ketoconazole 2% scalp solution. Griseofulvin is effective to treat tinea capitis caused by Microsporum sp. Comprehensive examination in tinea capitis is necessary to confirm the diagnosis and the etiology as well to determine the best treatment for the case

Keywords

- children; dermatophyte infection; griseofulvin; Microsporum; tinea capitis

Login (<https://www.ijrp.org/login>)

Search Here...



Medicine, Health & Food

Home (<https://www.ijrp.org/>) ◦ Journal List (<https://www.ijrp.org/journallist>) ◦ **Medicine, Health & Food**

Medicine, Health & Food

Home (<https://www.ijrp.org/>) / Journal List (<https://www.ijrp.org/journallist>)

/ Medicine, Health & Food (<https://www.ijrp.org/paper/Medicine--Health---Food/3/home>) / **Editor**

Editorial Board (24)

Behzad (<https://www.ijrp.org/user/Behzad/230>)

Shahroud University of Medical Sciences, Iran

Assistant Professor

Dr SONALI CHATURVEDI (<https://www.ijrp.org/user/Dr-SONALI-CHATURVEDI/239>)

UNIVERSITY OF CALIFORNIA- San Francisco, USA

Dr. Estari Mamidala, Ph.D, PDF (USA) ([https://www.ijrp.org/user/Dr.-Estari-Mamidala- Ph.D-PDF-USA-/240](https://www.ijrp.org/user/Dr.-Estari-Mamidala-Ph.D-PDF-USA-/240))

Metabolic Disorders & Infectious Diseases Research Lab, USA

Assistant Professo

India

Mahavir Singh (<https://www.ijrp.org/user/Mahavir-Singh/241>)

CSIR-National Physical Laboratory, New Delh, India

Sr. Principal Scientist & Head,

India

Dr. Simon Obwatho (<https://www.ijrp.org/user/Dr.-Simon-Obwatho/244>)

AFRICA NAZARENE UNIVERSITY

Director of Postgraduate Programs

Rifky A.L.M (<https://www.ijrp.org/user/Rifky-A.L.M/54>)

Eastern University, Sri Lanka

Lecturer

Sri Lanka

Jiban Shrestha (<https://www.ijrp.org/user/Jiban-Shrestha/245>)

Nepal Agricultural Research Council

Scientist (Plant Breeding & Genetics)

Md. Saiful Islam (<https://www.ijrp.org/user/Md.-Saiful-Islam/49>)

Daffodil International University

Software Engineer

Bangladesh

KAVYACHAND YALAMUDI (<https://www.ijrp.org/user/KAVYACHAND-YALAMUDI/1155>)

Q1HOSPITALS-HEALTHCITY-VIZAG-ANDHRAPRADESH

CONSULTANT PHYSICIAN AND DIABETOLOGIST

India

Dr. S. Azhagu Madhavan (<https://www.ijrp.org/user/Dr.-S.-Azhagu-Madhavan/1504>)

A. V. V. M. Sri Pushpam College (Autonomous), Poondi, Thanjavur Dt, Pin -613504

Sadekur Rahman (<https://www.ijrp.org/user/Sadekur-Rahman/1665>)

IJRP

Editor

Nihad Khalawe Tektook (<https://www.ijrp.org/user/Nihad-Khalawe-Tektook/965>)

MIDDLE TECHNICAL UNIVERSITY

Middle Technical University Co

Iraq

KHIN THANDAR AUNG (<https://www.ijrp.org/user/KHIN-THANDAR-AUNG/1837>)

International Islamic University, Malaysia(IIUM)

lecturer

Malaysia

Dr Owais Yousuf (<https://www.ijrp.org/user/Dr-Owais-Yousuf/1677>)

Integral University

Assistant Professor

India

Sanjay Pandey (<https://www.ijrp.org/user/Sanjay-Pandey/3275>)

Albert Einstein college of medicine

Research Fellow

USA

KUMAR AVINASH CHANDRA (<https://www.ijrp.org/user/KUMAR-AVINASH-CHANDRA/2079>)

Dr. A.P.J.A.K. WOMEN'S INSTITUTE OF TECHNOLOGY

ASSISTANT PROFESSOR

India

ASHWIN SINGH CHOUHAN (<https://www.ijrp.org/user/ASHWIN-SINGH-CHOUHAN/3750>)

Jai narain vyas university jodhpur rajasthan

Assistant Professor (Pharmacology)

India

Heba Muwafaq Attash (<https://www.ijrp.org/user/Heba-Muwafaq-Attash/4143>)

Rudaina Ismail Osman Ahmed (<https://www.ijrp.org/user/Rudaina-Ismail-Osman-Ahmed/4364>)

Napata College
Medical Researcher and Teaching Assistant
Sudan

Sheryl J. Contreras (<https://www.ijrp.org/user/Sheryl-J.-Contreras/4519>)

Antonio A. Maceda Integrated School (JHS)
Head Teacher III
Philippines

Dr. Isiaka Sanni Oluwasegun (<https://www.ijrp.org/user/Dr.-Isiaka-Sanni-Oluwasegun/4846>)

Makkah Specialist Eye Hospital Bauchi
Kobi street, Bauchi
Nigeria

SULEIMAN IBRAHIM KARAYE (<https://www.ijrp.org/user/SULEIMAN-IBRAHIM-KARAYE/5427>)

Federal College of Agricultural Produce Technology, Kano.
Junior Director CTA
Nigeria

Luma M. Al-Obaidy (<https://www.ijrp.org/user/Luma-M.-Al-Obaidy/5520>)

University of Mosul
Lecturer at University of Mosul
Iraq

EVIYATI AINI MURIANA (<https://www.ijrp.org/user/EVIYATI-AINI-MURIANA/5943>)

Universitas Gadjah Mada
Master of Applied Midwifery
Indonesia

Quick Contact

✉ editor.ijrp@gmail.com, editor@ijrp.org (<mailto:editor.ijrp@gmail.com>, editor@ijrp.org)

Pages: 7 , **Published Online:** 25 Jan 2022

DOI: 10.47119/IJRP100931120222802 (<https://doi.org/10.47119/IJRP100931120222802>) , **Views:** 246 ,

Download: 131

 **Paper Download** (<https://www.ijrp.org/filePermission/fileDownload/4/ac76c891c467a2b07722d59e4dadc585/1>)

Analysis of Adiponectin Levels in Covid-19 Patients and Their Relationship to the Occurrence of Multi-Organ Failure and Mortality (https://www.ijrp.org/paper_detail/2759)

Pages: 9 , **Published Online:** 22 Jan 2022

DOI: 10.47119/IJRP100931120222792 (<https://doi.org/10.47119/IJRP100931120222792>) , **Views:** 248 ,

Download: 127

 **Paper Download** (<https://www.ijrp.org/filePermission/fileDownload/4/edddfb585df74a13691785d696a4961e/3>)

Comparison of the acute response of morning and evening outdoor exercise to oxygen saturation (SpO2) after aerobic activity (https://www.ijrp.org/paper_detail/2754)

Pages: 6 , **Published Online:** 20 Jan 2022

DOI: 10.47119/IJRP100931120222772 (<https://doi.org/10.47119/IJRP100931120222772>) , **Views:** 229 ,

Download: 117

 **Paper Download** (<https://www.ijrp.org/filePermission/fileDownload/4/317d200214d5f57fab8f4de262b26b41/3>)

Spontaneous pyogenic granuloma on port wine stain: case report (https://www.ijrp.org/paper_detail/2750)

Pages: 3 , **Published Online:** 19 Jan 2022

DOI: 10.47119/IJRP100931120222763 (<https://doi.org/10.47119/IJRP100931120222763>) , **Views:** 196 ,

Download: 116

 **Paper Download** (<https://www.ijrp.org/filePermission/fileDownload/4/0b4c023d93f23f07f078fb8badff56cd/1>)

FINE NEEDLE ASPIRATION EXAMINATION PROFILE OF SOFT TISSUE TUMOR IN THE ANATOMICAL PATHOLOGY DEPARTMENT OF DR. SOETOMO GENERAL ACADEMIC HOSPITAL SURABAYA DURING 1 JANUARY 2014 ? 31 DECEMBER 2018 (https://www.ijrp.org/paper_detail/2746)

Pages: 12 , **Published Online:** 18 Jan 2022

DOI: 10.47119/IJRP100931120222753 (<https://doi.org/10.47119/IJRP100931120222753>) , **Views:** 206 ,

Download: 113

 **Paper Download** (<https://www.ijrp.org/filePermission/fileDownload/4/aa3742337e00f5f7cca8ed840f48a60b/2>)

Profile of Domestic Violence Cases Examined At Langsa Hospital in 2019-2020 (https://www.ijrp.org/paper_detail/2745)

Pages: 5 , **Published Online:** 18 Jan 2022

DOI: 10.47119/IJRP100931120222752 (<https://doi.org/10.47119/IJRP100931120222752>) , **Views:** 218 ,

Download: 120

Anhidrotic Ectodermal dysplasia - A Case Report (https://www.ijrp.org/paper_detail/2737)**Pages:** 6 , **Published Online:** 15 Jan 2022**DOI:** 10.47119/IJRP100931120222773 (<https://doi.org/10.47119/IJRP100931120222773>) , **Views:** 193 ,**Download:** 117 [Paper Download \(https://www.ijrp.org/filePermission/fileDownload/4/a87c293a774667c4be3a5840c7949293/2\)](https://www.ijrp.org/filePermission/fileDownload/4/a87c293a774667c4be3a5840c7949293/2)**Moderate-intensity Treadmill And Ergocycle Exercise Reduce Fasting Blood Glucose Levels In Obese Women**
(https://www.ijrp.org/paper_detail/2736)**Pages:** 7 , **Published Online:** 15 Jan 2022**DOI:** 10.47119/IJRP100931120222782 (<https://doi.org/10.47119/IJRP100931120222782>) , **Views:** 280 ,**Download:** 144 [Paper Download \(https://www.ijrp.org/filePermission/fileDownload/4/0574bf553259e67d01e825e55de21759/2\)](https://www.ijrp.org/filePermission/fileDownload/4/0574bf553259e67d01e825e55de21759/2)**Correlation of Neutrophil Elastase to D-Dimer, Pao2/Fio2 Ratio and SOFA Score In COVID-19 Patients**
(https://www.ijrp.org/paper_detail/2734)**Pages:** 7 , **Published Online:** 15 Jan 2022**DOI:** 10.47119/IJRP100931120222783 (<https://doi.org/10.47119/IJRP100931120222783>) , **Views:** 253 ,**Download:** 143 [Paper Download \(https://www.ijrp.org/filePermission/fileDownload/4/f583334e4da59204d8c72829667c64b4/1\)](https://www.ijrp.org/filePermission/fileDownload/4/f583334e4da59204d8c72829667c64b4/1)**The Practice of Female Genital Mutilation/Cutting (FGM/C) in the Work Area of the Tangerang City Health Center** (https://www.ijrp.org/paper_detail/2724)**Pages:** 6 , **Published Online:** 14 Jan 2022**DOI:** 10.47119/IJRP100931120222778 (<https://doi.org/10.47119/IJRP100931120222778>) , **Views:** 217 ,**Download:** 121 [Paper Download \(https://www.ijrp.org/filePermission/fileDownload/4/515d3447caad153258afbda9a0f96b08/1\)](https://www.ijrp.org/filePermission/fileDownload/4/515d3447caad153258afbda9a0f96b08/1)**Effects of a 4-Week Moderate-Intensity Swimming Exercise Increase Serotonin Levels in Mice (Mus musculus)**
(https://www.ijrp.org/paper_detail/2722)**Pages:** 7 , **Published Online:** 13 Jan 2022**DOI:** 10.47119/IJRP100931120222781 (<https://doi.org/10.47119/IJRP100931120222781>) , **Views:** 248 ,**Download:** 149 [Paper Download \(https://www.ijrp.org/filePermission/fileDownload/4/c494b4c84bfbeb2823a34629101be097/1\)](https://www.ijrp.org/filePermission/fileDownload/4/c494b4c84bfbeb2823a34629101be097/1)**The Effectiveness of Online Counseling Methods to Improve the Knowledge of Covid 19 Vaccination in High School Students** (https://www.ijrp.org/paper_detail/2721)**Pages:** 8 , **Published Online:** 13 Jan 2022**DOI:** 10.47119/IJRP100931120222797 (<https://doi.org/10.47119/IJRP100931120222797>) , **Views:** 177 ,**Download:** 118

Moderate-Intensity Swimming Exercises Decrease Body Weight and Lee's Obesity Index in Female Mice (*Mus musculus*) (https://www.ijrp.org/paper_detail/2718)

Pages: 10 , Published Online: 12 Jan 2022

DOI: 10.47119/IJRP100931120222779 (<https://doi.org/10.47119/IJRP100931120222779>) , Views: 215 ,

Download: 146

 Paper Download (<https://www.ijrp.org/filePermission/fileDownload/4/c6b239a3b536f91388d453dcfce54bdd/1>)

Correlation between Body Mass Index and Physical Performance of Lower Extremity in Adult Athletes (https://www.ijrp.org/paper_detail/2717)

Pages: 8 , Published Online: 12 Jan 2022

DOI: 10.47119/IJRP100931120222777 (<https://doi.org/10.47119/IJRP100931120222777>) , Views: 177 ,

Download: 136

 Paper Download (<https://www.ijrp.org/filePermission/fileDownload/4/5e20dbed6d95fd4284cbd023d96f8f12/2>)

EFFECT OF INDUCTION WITH OXYTOCIN DRIP ON INCIDENCE OF POSTPARTUM HEMORRHAGE IN BUNDA ASY SYIFA MOTHER AND CHILD HOSPITAL BANDAR LAMPUNG (https://www.ijrp.org/paper_detail/2714)

Pages: 5 , Published Online: 11 Jan 2022

DOI: 10.47119/IJRP100931120222787 (<https://doi.org/10.47119/IJRP100931120222787>) , Views: 195 ,

Download: 133

 Paper Download (<https://www.ijrp.org/filePermission/fileDownload/4/c4da4757fa140432aca23c412c973987/3>)

Parturition Premature Imminens Management : A Review Article (https://www.ijrp.org/paper_detail/2704)

Pages: 6 , Published Online: 10 Jan 2022

DOI: 10.47119/IJRP100931120222756 (<https://doi.org/10.47119/IJRP100931120222756>) , Views: 306 ,

Download: 209

 Paper Download (<https://www.ijrp.org/filePermission/fileDownload/4/175f7d744a497b13112c999a94483932/2>)

Collagen type II expression in the intervertebral disc after cigarette smoke exposure: An experimental study using wistar rats (https://www.ijrp.org/paper_detail/2701)

Pages: 6 , Published Online: 09 Jan 2022

DOI: 10.47119/IJRP100931120222759 (<https://doi.org/10.47119/IJRP100931120222759>) , Views: 184 ,

Download: 139

 Paper Download (<https://www.ijrp.org/filePermission/fileDownload/4/8869b2698e34ccc81cc6e9b421719ce8/1>)

The Relationship Between Utilization of Information Center and Youth Counseling (PIK-R) towards Adolescents Attitude and Practice of Pre-Marital Sex (https://www.ijrp.org/paper_detail/2700)

Pages: 10 , Published Online: 09 Jan 2022

DOI: 10.47119/IJRP100931120222761 (<https://doi.org/10.47119/IJRP100931120222761>) , Views: 173 ,

Download: 160

Waardenburg Syndrome Type 1: A Case Report (https://www.ijrp.org/paper_detail/2699)**Pages:** 4 , **Published Online:** 09 Jan 2022**DOI:** 10.47119/IJRP100931120222770 (<https://doi.org/10.47119/IJRP100931120222770>) , **Views:** 168 ,**Download:** 137 **Paper Download** (<https://www.ijrp.org/filePermission/fileDownload/4/da1a72c8e9c86cfd9e10ae5067e78dc4/1>)**Body posture knowledge and habits during the pandemic in productive age webinar participant****(**https://www.ijrp.org/paper_detail/2696**)****Pages:** 9 , **Published Online:** 08 Jan 2022**DOI:** 10.47119/IJRP100931120222740 (<https://doi.org/10.47119/IJRP100931120222740>) , **Views:** 231 ,**Download:** 149 **Paper Download** (<https://www.ijrp.org/filePermission/fileDownload/4/3d5bdee27d151fe80bd55ef0d832820f/2>)**Burnout Levels and Knowledge Analysis Regarding Burnout Prevention During Work from Home in Young Adults****(**https://www.ijrp.org/paper_detail/2691**)****Pages:** 6 , **Published Online:** 07 Jan 2022**DOI:** 10.47119/IJRP100931120222742 (<https://doi.org/10.47119/IJRP100931120222742>) , **Views:** 193 ,**Download:** 143 **Paper Download** (<https://www.ijrp.org/filePermission/fileDownload/4/94ab319b43f8848c3d7d81010b6cca0/2>)**Serum Interleukin-6 Level Raise Up In Time With Muscle Soreness at 24 Hours Recovery From Vigorous****Exercise: Does It Correlate ?** (https://www.ijrp.org/paper_detail/2683)**Pages:** 5 , **Published Online:** 06 Jan 2022**DOI:** 10.47119/IJRP100931120222810 (<https://doi.org/10.47119/IJRP100931120222810>) , **Views:** 129 ,**Download:** 112 **Paper Download** (<https://www.ijrp.org/filePermission/fileDownload/4/dd9a9fc5cfb6bde223ca4cbbca0b2281/1>)**ERECTILE FUNCTION OF BPH PATIENTS UNDERGOING A LASER PROCEDURE COMPARED TO A STANDARD TRANSURETHRAL RESECTION OF THE PROSTATE (TURP): A SYSTEMATIC REVIEW AND META-ANALYSIS****(**https://www.ijrp.org/paper_detail/2651**)****Pages:** 11 , **Published Online:** 03 Jan 2022**DOI:** 10.47119/IJRP100931120222793 (<https://doi.org/10.47119/IJRP100931120222793>) , **Views:** 154 ,**Download:** 122 **Paper Download** (<https://www.ijrp.org/filePermission/fileDownload/4/ebbf26cd2f002f75017beacf8ac79e7f/4>)**ORTHOPAEDIC IMPLANT RELATED INFECTION** (https://www.ijrp.org/paper_detail/2649)**Pages:** 7 , **Published Online:** 02 Jan 2022**DOI:** 10.47119/IJRP100931120222751 (<https://doi.org/10.47119/IJRP100931120222751>) , **Views:** 167 ,**Download:** 142

A Systematic Review and Meta-Analysis of the Efficacy of Intraoperative Vascular Doppler Ultrasonography for Vein Ligations and Artery Preservations in Microsurgical Subinguinal Varicocelectomy (https://www.ijrp.org/paper_detail/2648)

Pages: 9 , Published Online: 01 Jan 2022

DOI: 10.47119/IJRP100931120222771 (<https://doi.org/10.47119/IJRP100931120222771>) , Views: 188 ,

Download: 143

 Paper Download (<https://www.ijrp.org/filePermission/fileDownload/4/7d3ca8bb8a0e3fe24be06648fc9cca5f/3>)

The Role of ?Meta Wing? Webinar to Improve Public Knowledge about Mental Health during Covid-19 Pandemic (https://www.ijrp.org/paper_detail/2624)

Pages: 10 , Published Online: 30 Dec 2021

DOI: 10.47119/IJRP100931120222741 (<https://doi.org/10.47119/IJRP100931120222741>) , Views: 214 ,

Download: 154

 Paper Download (<https://www.ijrp.org/filePermission/fileDownload/4/84721e9cebf961c21dc0b4fc5831c00/2>)

CORRELATION OF NLR AND PROCALCITONIN WITH SECONDARY INFECTION, SEVERITY, AND MORTALITY IN COVID-19 (https://www.ijrp.org/paper_detail/2620)

Pages: 14 , Published Online: 30 Dec 2021

DOI: 10.47119/IJRP100931120222750 (<https://doi.org/10.47119/IJRP100931120222750>) , Views: 206 ,

Download: 160

 Paper Download (<https://www.ijrp.org/filePermission/fileDownload/4/ba5b0d89c32ee5c96803be1efa42d20b/2>)

A GLOBAL PERSPECTIVE IN CONTROLLING HEPATITIS B VIRUS THROUGH VACCINATION: A REVIEW WITH A FOCUS ON INDONESIA (https://www.ijrp.org/paper_detail/2617)

Pages: 6 , Published Online: 29 Dec 2021

DOI: 10.47119/IJRP100931120222789 (<https://doi.org/10.47119/IJRP100931120222789>) , Views: 191 ,

Download: 136

 Paper Download (<https://www.ijrp.org/filePermission/fileDownload/4/e586b245ce9f7e90226a562a79343eff/2>)

Physical Exercise and High-Calorie Diet on Kidney Histopathology (https://www.ijrp.org/paper_detail/2611)

Pages: 8 , Published Online: 29 Dec 2021

DOI: 10.47119/IJRP100931120222768 (<https://doi.org/10.47119/IJRP100931120222768>) , Views: 168 ,

Download: 149

 Paper Download (<https://www.ijrp.org/filePermission/fileDownload/4/f57f79ccd76a618f376653c8c7af6f0/2>)

THE ROLE OF KETOACID ANALOGS WITH DIETARY PROTEIN RESTRICTION IN CHRONIC KIDNEY DISEASE PATIENTS (https://www.ijrp.org/paper_detail/2598)

Pages: 11 , Published Online: 25 Dec 2021

DOI: 10.47119/IJRP100931120222788 (<https://doi.org/10.47119/IJRP100931120222788>) , Views: 158 ,

Successful Treatment of Tinea Capitis Caused by *Microsporum canis* Using Griseofulvin

Brigita Ika Rosdiana^a, Yuri Widia^b, Linda Astari^c, Evy Ervianti^d, Dwi

Murtiastutik^e

- a. *Department of Dermatology and Venereology, Faculty of Medicine, Universitas Airlangga – Dr. Soetomo General Hospital, Surabaya, Indonesia, dvikaros@gmail.com*
- b. *Department of Dermatology and Venereology, Faculty of Medicine, Universitas Airlangga – Dr. Soetomo General Hospital, Surabaya, Indonesia, widia_yuri@yahoo.com*
- c. *Department of Dermatology and Venereology, Faculty of Medicine, Universitas Airlangga – Dr. Soetomo General Hospital, Surabaya, Indonesia, lindaaastari@yahoo.com*
- d. *Department of Dermatology and Venereology, Faculty of Medicine, Universitas Airlangga – Dr. Soetomo General Hospital, Surabaya, Indonesia, evy_if@yahoo.co.id*
- e. *Department of Dermatology and Venereology, Faculty of Medicine, Universitas Airlangga – Dr. Soetomo General Hospital, Surabaya, Indonesia*

Corresponding author:

Dr. Dwi Murtiastutik

Department of Dermatology and Venereology, Faculty of Medicine, Universitas Airlangga – Dr. Soetomo General Hospital, Surabaya, Indonesia
Mayjend Prof. Dr. Moestopo Street No. 6-8, Airlangga, Gubeng, Surabaya, East Java, Indonesia 60285
E-mail: dwimurtiastutik@yahoo.co.id

Abstract

Tinea capitis is a scalp and hair follicle dermatophyte infection caused by *Trichophyton sp.* and *Microsporum sp.* that more commonly affect children than adults. *Microsporum canis* is the most common dermatophyte causing tinea capitis reported in Asia that respond well to griseofulvin. We report one case of an 8-year-old child with a history of patchy scaling lesion on the head, alopecia, and pruritus. Dermatological examination

revealed multiple scaly erythematous macules, circular shape, sharply marginated, with a diameter of 2–6 cm, along with alopecia in each lesion. KOH preparation, wood lamp examination, trichoscopy, and fungal culture were performed. The diagnosis of tinea capitis grey patch type with an etiology of *Microsporum canis* was established. The patient was significantly improved clinically and mycologically with four weeks course of oral griseofulvin and adjuvant treatment using ketoconazole 2% scalp solution. Griseofulvin is effective to treat tinea capitis caused by *Microsporum sp.* Comprehensive examination in tinea capitis is necessary to confirm the diagnosis and the etiology as well to determine the best treatment for the case.

Keywords

children; dermatophyte infection; griseofulvin; *Microsporum*; tinea capitis

Introduction

Tinea capitis is a dermatophyte infection that affects the scalp, hair follicles, and intervening skin.¹ The incidence of tinea capitis globally is approximately 28%. Although it can affect any age group, it remains a common dermatophyte infection affecting primarily children, among 4 – 14 years old.²

Tinea capitis is caused by various dermatophytes classified into three genera: *Trichophyton sp.*, *Microsporum sp.*, and *Epidermophyton*. They may be anthropophilic (usually infects humans and rarely affects animals), zoophilic (infects animals but can be transmitted to humans), and geophilic (inhabit soil and infect both humans and animals) based on their host preference and natural habitat.³ The etiology of tinea capitis varies in different geographic regions, and this predominant causative agent is dependent on climates, socioeconomic condition, immune status of the host, hygiene, drug resistance,

and dermatophyte characteristic factors.⁴ The leading etiological zoophilic agent worldwide reported is *Microsporum canis*, while *Trichopython violaceum* and *Trichopython tonsurans* are the most frequent anthropophilic causative agents.³ Therapeutic regimen options for tinea capitis in children, including griseofulvin, terbinafine, itraconazole, and fluconazole. Griseofulvin has been reported to be more effective in treating tinea capitis caused by *Microsporum sp.*⁵

Case History

An eight-year-old boy presented to the dermatology outpatient clinic of Dr. Soetomo General Hospital with chief complaint of scaling on the head, patchy alopecia, and pruritus. His first visit to the hospital was October 1st, 2019. At first, the patient felt an itchy sensation and localized hair loss on the scalp one month before the first visit. Two weeks before he came to the hospital, he went to a general practitioner and got steroid ointment and shampoo, but there was no improvement. One week before the first visit, white scales were noted on his scalp. He had never experienced this condition before, and no one in the same household was experiencing any skin or scalp problems. The mother reported that their neighbour has a cat as a pet and frequently interacts with the child. Physical examination showed a normal body mass index and stable vital sign. Dermatological examination revealed multiple scaly erythematous macules, circular shape, sharply margined, with a diameter of 2-6 cm, along with alopecia in each lesion (Fig. 1a). There was no palpable lymph node enlargement in the retroauricular region. Supportive examination using KOH preparation was performed, with the result of ectothrix pattern in the hair shaft. Wood lamp examination showed positive yellow-green fluorescence. Trichoscopy of the lesions showed the pattern of diffuse scaling,

perifollicular scaling, morse code-like hair, zigzag hair, black dot, broken hair, and comma hair (Fig. 2). Fungal culture results revealed the species of *Microsporum canis*. Based on history taking, clinical manifestation, and supportive examination, the diagnosis of tinea capitis grey patch type was established. The patient was treated using griseofulvin 250 mg per day for four weeks with adjuvant treatment using ketoconazole 2% scalp solution. Patient's condition was significantly improved both clinically and mycologically in two months. There were no adverse effects to the child reported by the parents.

Discussion

Tinea capitis, also known as ringworm, is a dermatophyte infection of the hair and the scalp.^{1,3} The clinical manifestation can be classified as non-inflammatory and inflammatory type. The non-inflammatory type is often uncomplicated with the classic presentation that includes one or more scaly patches of alopecia with black dots (broken hair at the skin line) or grey patch. In contrast, the inflammatory type (kerion) usually takes the form of a painful pustule and plaques and is followed by scarring alopecia as a complication.^{1,6} The diagnosis of tinea capitis can be made with clinical suspicion, especially if a child presents with patchy alopecia that is followed by scaling, erythema, or pustule. However, sometimes determining the diagnosis is difficult in cases with mild symptoms. Clinical manifestations that resemble another differential diagnosis like alopecia areata, trichotillomania, or seborrheic dermatitis also make it harder to diagnose tinea capitis.^{6,7} Based on the signs and symptoms, this case was classified as non-inflammatory type, with the specific grey patch type. Non-inflammatory tinea capitis is more common than the inflammatory type. The grey patch type is commonly seen with

an anthropophilic organism such as *Microsporum canis* and *Microsporum audouinii*. These two organisms cause an ectothrix pattern that will fluoresce bright green colour in the Wood light examination.^{1,6} On physical examination, no lymphadenopathy was found. Lymphadenopathy generally presents in a child with tinea capitis. However, this should not delay the diagnosis of tinea capitis as lymphadenopathy can also occur in nonfungal disease.⁶ Moreover, if the infection signs are notably apparent, then the suspicion towards tinea capitis should be established. Trichoscopy was performed to ensure the suspicion of tinea capitis and to exclude the differential diagnosis. Trichoscopy is an easy, fast, and non-invasive diagnosis tool suitable for pediatric patients and can be useful for the diagnosis before being confirmed by the mycological culture result so the treatment would not be delayed by the diagnostic process, considering the long duration of therapy for fungal infections.⁸ The characteristic trichoscopy findings of *Microsporum* tinea capitis include morse code-like hairs, bent hair, zigzag hair, and diffuse scaling that were also present in this case.⁹

Some physicians diagnose tinea capitis based on clinical findings if the signs and symptoms are apparent and typical. However, additional laboratory tests such as KOH examination and mycological culture are still essential to determine the etiologic agent and treatment options (e.g. determine the effective antifungal type in certain dermatophytes; for example, griseofulvin is more effective in *Microsporum* than *Trichophyton*).^{6,10} In many tinea capitis cases, the clinical aspects might not be associated with the expected agent; thus, the fungal culture is still necessary as a gold standard diagnostic test.¹¹ The clinical and supportive findings in this case then finally were being confirmed with the fungal culture result, which showed spindle-shaped macroconidia with terminal knobs and more than 6 cells leading to the species *Microsporum canis* (Fig

3). *Microsporium canis* is zoophilic; thus, we might suspect the transmission came from the cat that frequently interacted with the patient as cats and dogs may play a role as reservoir or source of infection of *Microsporium canis*, and the transmission between human is considered rare.¹² This finding is in line with a previous 5-year retrospective study by Sari et al. in Indonesia which showed that *Microsporium canis* was the most common causative species of tinea capitis that affect the age group of 0-14 years old.¹³ Systemic antifungal drugs are required to treat tinea capitis because topical agents do not penetrate well to hair shafts and follicles.^{6,14} Topical treatment like topical selenium sulphide or ketoconazole may be used as an adjunct to systemic treatments. It has proven beneficial to reduce the viable spores responsible for the contagion and reinfection that may shorten the cure rate.¹⁵ Oral antifungal treatment, griseofulvin, is considered the most effective therapy for *Microsporium* tinea capitis due to griseofulvin's ability to concentrate in sweat since the location of the infection is ectothrix, in which the drug must reach the location of infection through sweat or sebum.⁵ Griseofulvin also has a good safety profile with lower adverse effects. The most common side effects are headache and gastrointestinal discomfort, that is usually mild and disappear along with the treatment.⁵

Conclusion

Griseofulvin is effective to treat tinea capitis caused by *Microsporium sp.* Comprehensive examination in tinea capitis is necessary to confirm the diagnosis and the etiology as well, in order to choose the best treatment for the case.

Figures

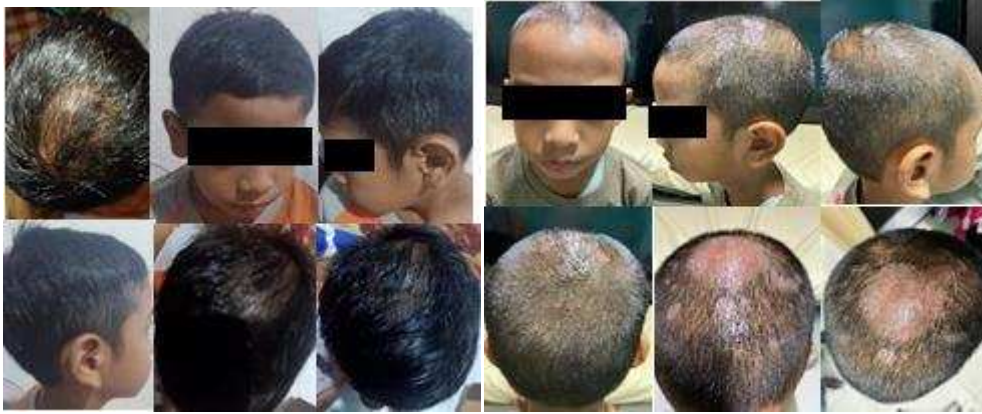

Figure 1. (a) Before treatment, (b) After treatment

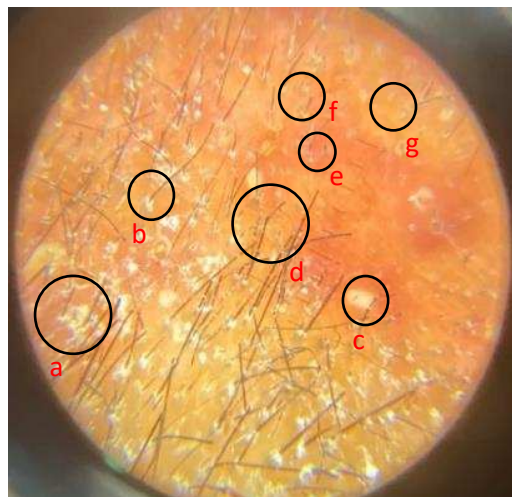


Figure 2. The trichoscopy result: a) Diffuse scaling, b) Perifollicular scaling, c) Morse code-like hair, d) Zigzag hair, e) Black dot, f) Broken hair, g) Comma hair

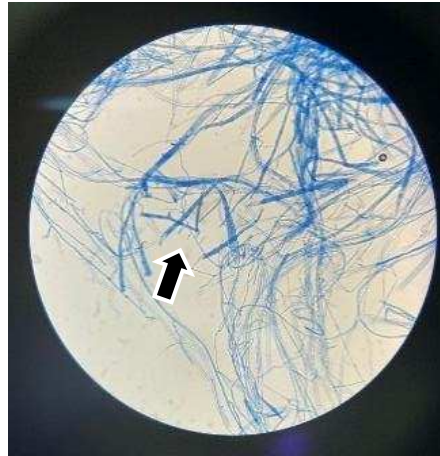


Figure 3. Lactofenol cotton blue staining showed macroconidia of *M. canis* with terminal knobs and more than 6 cells

References

1. Goldsmith LA, Katz SI, Gilchrest barbara A, Paller AS, Leffel DJ, Wolff K. Fitzpatrick's Dermatology in General Medicine. 8th ed. New York: McGraw-Hill; 2011.
2. Andrews MD, Burns M. Common tinea infections in children. *Am Fam Physician*. 2008;77(10):1415–20.
3. Rodríguez-Cerdeira C, Martínez-Herrera E, Szepietowski JC, Pinto-Almazán R, Frías-De-León MG, Espinosa-Hernández VM, et al. A systematic review of worldwide data on tinea capitis: analysis of the last 20 years. *J Eur Acad Dermatology Venereol*. 2020;
4. Bhat Y, Zeerak S, Kanth F, Yaseen A, Hassan I, Hakak R. Clinicoepidemiological and mycological study of tinea capitis in the pediatric population of kashmir valley: A study from a tertiary care centre. *Indian Dermatol Online J*. 2017;8(2):100.
5. Alkeswani A, Cantrell W, Elewski B. Treatment of Tinea Capitis. *Ski Appendage Disord*. 2019;5(4):201–10.
6. Ely JW, Rosenfeld S, Stone MS. Diagnosis and Management of Tinea Infection. *Am Fam Physician*. 2014;90(10):702–10.
7. Ginter-Hanselmayer G, Smolle J, Gupta A. Itraconazole in the treatment of tinea capitis caused by *Microsporum canis*: Experience in a large cohort. *Pediatr Dermatol*. 2004;21(4):499–502.
8. Brasileiro A, Campos S, Cabete J, Galhardas C, Lencastre A, Serrão V. Trichoscopy as an additional tool for the differential diagnosis of tinea capitis: a prospective clinical study. *Br J Dermatol*. 2016;175(1):208–9.

9. Xiao H, Pradhan S, Ran X, Ran Y. Tinea capitis: dermoscopy and calcium fluorescent microscopy as highly efficient and precise diagnostic tools. *An Bras Dermatol.* 2020;95(3):332–5.
10. James SL, Abate D, Abate KH, Abay SM, Abbafati C, Abbasi N, et al. Global, regional, and national incidence, prevalence, and years lived with disability for 354 Diseases and Injuries for 195 countries and territories, 1990-2017: A systematic analysis for the Global Burden of Disease Study 2017. *Lancet.* 2018;392(10159):1789–858.
11. Veasey JV, Muzy G de SC. Tinea capitis: Correlation of clinical presentations to agents identified in mycological culture. *An Bras Dermatol.* 2018;93(3):465–6.
12. Gürtler TGR, Diniz LM, Nicchio L. Tinea capitis micro-epidemic by *Microsporum canis* in a day care center of Vitória - Espírito Santo (Brazil). *An Bras Dermatol.* 2005;80(3):267–72.
13. Sari AB, Widaty S, Bramono K, Miranda E, Ganjardani M. TINEA KAPITIS DI POLIKLINIK KULIT DAN KELAMIN RSUPN DR CIPTO MANGUNKUSUMO JAKARTA PERIODE TAHUN 2005 – 2010. 2012;39(3):113–7.
14. Tan CW, Foong AY, Liew HM, Koh MJ. A Review of Tinea Capitis in a Cohort of Asian Children. *Ann Acad Med Singapore.* 2018;47(4):156–8.
15. Kakourou T, Uksal U, Oranje AP. Guidelines for the management of tinea capitis in children. *Pediatr Dermatol.* 2010;27(3):226–8.