

# MALAYSIAN ORTHOPAEDIC JOURNAL



*Official Journal of the  
Malaysian Orthopaedic Association*

The Journal is indexed/abstracted by PubMed Central, PubMed, SCOPUS, Emerging Source Citation Index (ESCI),  
Directory Open Access Journal (DOAJ), AFRAMED Central, Western Pacific Region Index Medicus (WPRIM),  
Index Copernicus, ASIAN Citation Index (ACI), Google Scholar, MyBio and MyData

---

Volume 14

---

Issue Number 2

---

July 2020

---

ISSN No: 1985-2533

---

EISSN No: PP 15451/06/2013(02012)

# MALAYSIAN ORTHOPAEDIC JOURNAL

*Vol 14 No 2, July 2020*

Official Journal of Malaysian Orthopaedic Association and ASEAN Orthopaedic Association

## CHIEF EDITOR

Saw Aik

## EDITORIAL BOARD

Abdul Hamid Abdul Kadir  
Abdul Razak Sulaiman  
Aree Tanavalee  
Awang Bulgiba  
Azlina Amir Abbas  
Chris Chan Yin Wei  
Edward HM Wang  
Ifraan Saleh  
Ismail Hadisoebroto Dilogo  
Joyce Koh Suang Bee  
Kamarul Ariffin Khalid  
Maung Mg Htwe  
Mohamed Razif Mohamed Ali  
Mohammad Anwar Hau Abdullah  
Mohd Imran Yusof  
Ng Kwan Hoong  
Sharaf Ibrahim  
Sharifah Roohi Syed Waseem Ahmad  
Srijit Das  
Tunku Kamarul Zaman Tunku Zainol Abidin  
Tunku Sara Ahmad  
Wan Faisham Nu'man Wan Ismail

## COPY EDITOR

Gracie Ong Siok Yan  
Marzida Mansor  
Nor'azim Mohd Yunos  
Rafidah Atan  
Roshan Gunalan

## ASEAN REGIONAL EDITORIAL BOARD

Howe Tet Sen (Singapore)  
James Hui (Singapore)  
Ketan Pande (Brunei)  
Luthfi Gatam (Indonesia)  
Myint Thaung (Myanmar)  
Nathaniel Orillaza (Philippines)  
Nguyen Le Bao Tien (Vietnam)  
Saranatra Waikakul (Thailand)  
Vo Van Thanh (Vietnam)

## INTERNATIONAL ADVISORY BOARD

Aziz Nather (Singapore)  
Benjamin Joseph (India)  
Christopher Mow (USA)  
Kaye E Wilkins (USA)  
Ken N Kuo (USA)  
Lee Eng Hin (Singapore)  
Wilfred Peh (Singapore)

## EDITORIAL SECRETARY

Ain Syuhada Kalip

## EDITORIAL ASSISTANT

Nursyafeira Nabella Shofian

## ADMINISTRATION SECRETARY

Uma Sundaram

## MOJ WEBMASTER

Teng Kim Teck

## PUBLISHER

Malaysian Orthopaedic  
Association

---

Secretariat

Malaysian Orthopaedic Association

Unit 2-6, Level 2, Enterprise 3B, Technology Park Malaysia (TPM), Jalan Inovasi 1,

Lebuhraya Puchong-Sg. Besi, 57000 Bukit Jalil, Kuala Lumpur

Tel: +603 8996 6300 Fax: +603 8996 6400

Email: [morthoj@gmail.com](mailto:morthoj@gmail.com) Website: [www.morthoj.org/](http://www.morthoj.org/)

KDN No : PP 15451/06/2013(032812)

---

Printed by: Digital Perspective Sdn. Bhd.

42-1, Level 1, Plaza Sinar, Taman Sri Sinar, 51200 Kuala Lumpur.

Tel: 03-6272 3767 Email: [dpsbkl@gmail.com](mailto:dpsbkl@gmail.com)

**EDITORIAL**

- The Perils of Predatory Journals and Conferences 1  
*Ibrahim S, Saw A*

**SPECIAL ARTICLES**

- COVID-19 in Singapore and Malaysia: Rising to the Challenges of Orthopaedic Practice in an Evolving Pandemic 7  
*Tay K, Kamarul T, Woo YL, Mansor M, Li X, Wong J, Saw A*

- N95 Filtering Facepiece Respirators during the COVID-19 Pandemic: Basics, Types, and Shortage Solutions 16  
*Srinivasan S, Peh WCG*

**ORIGINAL ARTICLES**

- Influence of Infraspinatus and Subscapularis Pathologies on Supraspinatus Muscle Atrophy - A Retrospective Cohort Study 23  
*Altan E, Nayman A, Yildirim A, Ozbaydar MU, Ciftci S, Karahan M*

- Displaced Physeal and Metaphyseal Fractures of Distal Radius in Children. Can Wire Fixation Achieve Better Outcome at Skeletal Maturity than Cast Alone? 28  
*Syurahbil AH, Munajat I, Mohd EF, Hadizie D, Salim AA*

- What is the Quality of Life of Transtibial Amputees in Brunei Darussalam? 39  
*Ng SS, Naing L, Idris FI, Pande K*

- Acute Shortening and Re-Lengthening (ASRL) in Infected Non-union of Tibia - Advantages Revisited 47  
*Baruah RK, Baruah JP, Shyam-Sunder S*

- Comparative Evaluation of Two Different Post-Operative Analgesia after Hallux Valgus Correction in Day Surgery Patients 57  
*Galli M, Vergari A, Vitiello R, Nestorini R, Peruzzi M, Chierichini A, Spinazzola G, Rossi M*

- Scranton Type V Osteochondral Defects of Talus: Does one-stage Arthroscopic Debridement, Microfracture and Plasma Rich in Growth Factor cause the Healing of Cyst and Cessation of Progression to Osteoarthritis? 64  
*Singh N, Pandey CR, Tamang B, Singh R*

- Modified Short Proximal Femoral Nail for Intertrochanteric Fractures of Femur in Indian Patients - our Experience 72  
*Jha V, Ahmed T*

- Comparative Study of Different Drills for Bone Drilling: A Systematic Approach 83  
*Pazarci O, Torun Y, Ozturk A, Oztemur Z*

- Functional Outcomes Following Posterior Cruciate Ligament and Posterolateral Corner Reconstructions. A Three-year Experience in Seremban, Malaysia 90  
*Ng JW, Ahmad AR, Solayar GN*

<b>CONTENTS</b>	<b>Page</b>
-----------------	-------------

Comparison of Thessaly Test with Joint Line Tenderness and McMurray Test in the Diagnosis of Meniscal Tears	94
---	----

*Shekarchi B, Panahi A, Raeissadat SA, Maleki N, Nayeabbas S, Farhadi P*

Cauda Equina Syndrome: A Review of 15 Patients Who Underwent Percutaneous Transforaminal Endoscopic Lumbar Discectomy (PTELD) Under Local Anaesthesia	101
---	-----

*Krishnan A, Kohli R, Degulmadi D, Mayi S, Ranjan R, Dave B*

Acute Deterioration of Kidney Function after Total Hip Arthroplasty	111
---	-----

*Takeshita S, Sonohata M, Kitajima M, Kawano S, Eto S, Mawatari M*

Cubitus Valgus with Tardy Ulnar Nerve Palsy – Functional Outcome of Milch Osteotomy without Anterior Transposition of Ulnar Nerve	120
---	-----

*Gupta RK, Khyani R, Majumdar KP, Potalia R*

## CASE REPORTS

Cubitus Valgus with Tardy Ulnar Nerve Palsy - Is Anterior Transposition of the Ulnar Nerve Always Necessary? A Case Report	126
--	-----

*Anuar-Ramdhan IM, Remli R, Abdul-Rashid AH, Ibrahim S*

Isolated Peroneus Longus Tear - Commonly Missed Diagnosis of Lateral Ankle Pain: A Case Report	130
--	-----

*Abd-Rasid AF, Bajuri MY*

Femoral Neck Non-Union - A Biomechanical Solution with Valgus Sliding Subtrochanteric Osteotomy: A Case Report	134
--	-----

*Teh KH, Ruben JK, Chan CK, Abbas AA*

A Cost-Effective Alternative for Lateral Femoral Wall Perforation in Anterior Cruciate Ligament (ACL) Reconstruction: A Case Report	138
---	-----

*Tan SY, Leong WH, Ong LH, Mohd-Amin MZ*

Vertebrae Destruction with Cauda Equina Syndrome Secondary to Spinal Gouty Arthritis: A Case Report	141
---	-----

*Thuraikumar K, Wan KL, Ong KL, Lim SW*

Low Tibial and Fibular Osteotomy for Treating Varus-Type Post-Traumatic Ankle Osteoarthritis: A Case Report	145
---	-----

*Chilmi MZ, Desnantyo AT, Widhiyanto L, Wirashada BC*

## LETTER TO EDITOR

A Simple External Fixator Construct for Assessment of Intra-operative Hip-Knee-Ankle Axis Alignment in Lower Limb Deformity Correction Surgery	149
--	-----

*Verma T, Chavali VH*

Orthopaedic Surgery in Times of COVID-19 in India	151
---	-----

*Majumdar PK, Gupta RK*

<b>CONTENTS</b>	<b>Page</b>
Alternative Strategies of Home Therapy in Clinical Orthopaedics during COVID-19 Pandemic: a Hand Surgeon Perspective <i>Cilli V</i>	154
Challenges of Orthopaedic Practice during COVID-19 Outbreak: Multidisciplinary Collaboration is Required <i>Joob B, Wiwanitkit V</i>	156
Reminder: Interpret the “Science” with Caution <i>Kow RY, Low CL</i>	157
<b>ORTHOPAEDIC CLINICAL QUIZ</b>	158
<b>ANSWERS TO ORTHOPAEDIC CLINICAL QUIZ</b>	160
<b>INSTRUCTIONS FOR AUTHORS</b>	162
<b>FUTURE EVENTS</b>	164
<b>EXECUTIVE COMMITTEE OF MALAYSIAN ORTHOPAEDIC ASSOCIATION 2020-2021</b>	165

# Low Tibial and Fibular Osteotomy for Treating Varus-Type Post-Traumatic Ankle Osteoarthritis: A Case Report

Chilmi MZ, MD, Desnantyo AT, MD, Widhiyanto L, MD, Wirashada BC, MD

Department of Orthopaedic and Traumatology, Universitas Airlangga, Surabaya, Indonesia



This is an open-access article distributed under the terms of the Creative Commons Attribution License, which permits unrestricted use, distribution, and reproduction in any medium, provided the original work is properly cited

Date of submission: 22nd April 2019

Date of acceptance: 20th May 2020

## ABSTRACT

In Indonesia, arthrodesis becomes a choice of treatment in the absence of ankle arthroplasty implants for young adults. Arthrodesis on ankle osteoarthritis (OA) often leads to functional impairment. Low tibiofibular osteotomy is an alternative and it has been known to be the preferable option for those in the productive-ages. A 22-year-old male with a previous history of a motorbike accident, operated eight years ago, came with persistent pain on the left ankle that has worsened over the years. Plain radiography with a tibial-ankle surface angle (TAS) of 74° (normally 88°-93°) indicated varus deformity. Osteotomy was performed on distal tibia above the syndesmotic joint, as well as on the middle third of fibula. Open wedge osteotomy of the tibia was corrected until the normal TAS angle was reached by fluoroscopy. Cortical allograft was used to fill the osteotomy gap. Instrumentation was performed using a clover leaf® plate with 6 screws insertion for fixation stability. All results were satisfactory. Twelve weeks post-operatively, the patient was performing activities normally. Four-month post-operative radiological evaluation showed fusion of graft and the angle of TAS of 89°. Post-operative functional assessment using the American Academy of Orthopaedic Surgeon (AAOS) Foot and Ankle Measurement (FAM) questionnaires showed significant improvement (pre 89, post 38).

### Keywords:

*low tibial osteotomy, post-traumatic ankle osteoarthritis, tibial-ankle surface angle (TAS), ankle arthritis*

## INTRODUCTION

Ankle osteoarthritis (OA) occurs in one percent of the world adult population. In contrast to OA in the pelvis and knee, ankle OA is often caused by trauma<sup>1</sup>. Malunion and intra-articular fractures are the common causes. Flatfoot in the

adult is a predisposing factor of idiopathic valgus osteoarthritis and varus osteoarthritis, or supramalleolar abnormality<sup>2</sup>.

Treatments include conservative bracing, pain relief injection, while surgeries include tibial and fibular osteotomy, arthroscopy and ankle arthroplasty or ankle arthrodesis<sup>3</sup>. Arthroplasty has a good outcome but not suitable for patients under 50 years old. Low osteotomy is a procedure to preserve the joints previously in asymmetric valgus deformity or ankle arthritis that forms varus deformity. This procedure aims to reduce pain, harmful mechanics of joints and inhibits joint degeneration<sup>1</sup>.

Angular deformity was evaluated using Tibial Ankle Surface (TAS) angle or tibial-distal-lateral angle, talar-tilted angle, and Talar-Lateral Surface (TLS) angle. TAS connects the tibial axis with tibial ceilings (normally 89°); the talus slope is the angle between tibial-ceiling and the talar dome (normal <4°); TLS connects the tibial axis and lines of anterior aspect and posterior aspect of tibial ceiling (normally 81.5°)<sup>2</sup>.

Studies showed low tibial osteotomy decreases pain, improves function, and corrects varus deformity<sup>3</sup>. Cheng reported satisfactory results in 18 low tibial osteotomy patients<sup>4</sup>. Knupp *et al* supported with 94 ankle OA patients who underwent low tibial osteotomy with significant statistical and clinical pain relief calculated by American Orthopaedic Foot and Ankle Society (AOFAS) Ankle-Hindfoot score after follow-up for 3.6 years<sup>1</sup>. This report emphasised the advantage of the low tibiofibular osteotomy.

## CASE REPORT

We report a 22-year-old male with left ankle pain since the last two years before admission. Pain is especially felt in the morning, while moving from sit to stand position; sometimes

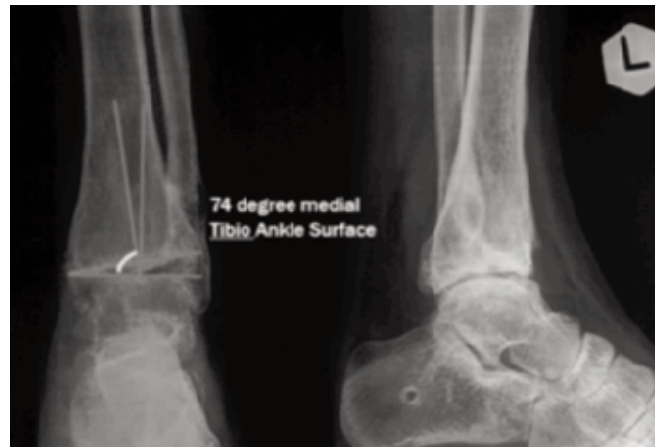


Fig. 1: Pre-operative condition. Left ankle pre-operative imaging, showed varus deformity with TAS angle 74° (internal documentation).

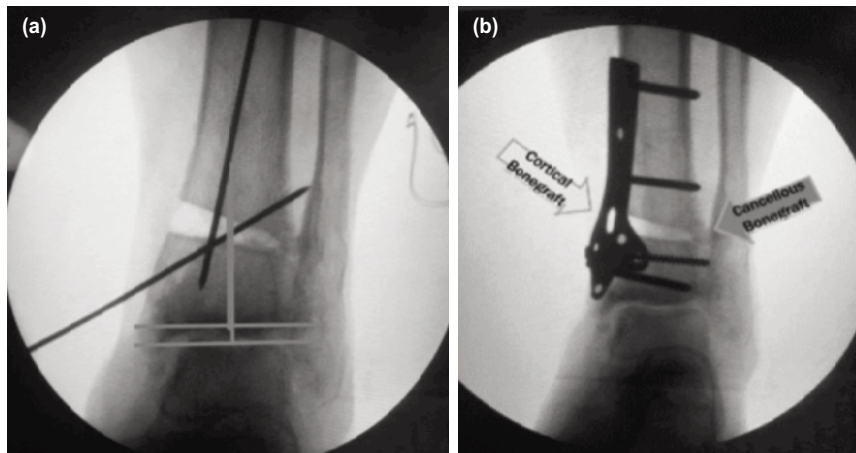


Fig. 2: Intra-operative imaging. (a) Open wedge osteotomy on distal tibia until normal TAS angle reached; K-wire used for temporary fixation. (b) Cortical allograft used to fill the gap and cancellous bone graft, fixated using plate and screw (internal documentation).

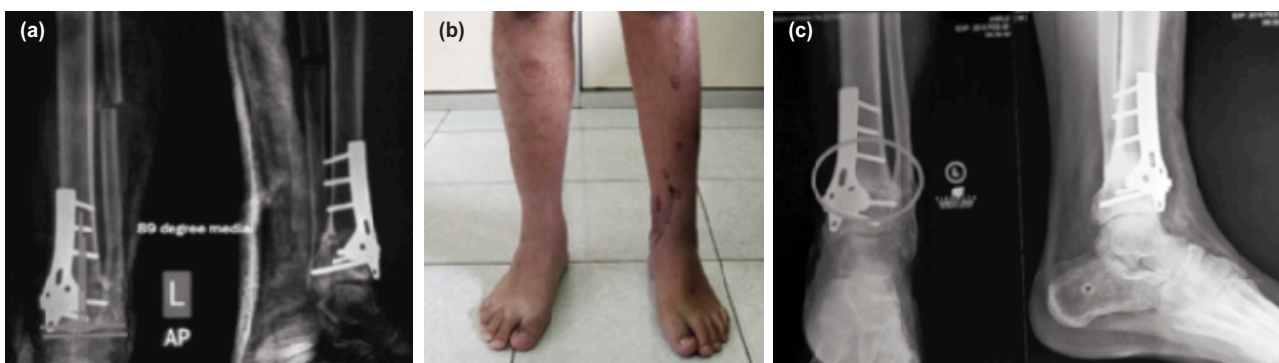


Fig. 3: Post-operative follow-up (a) Post-operative imaging of left ankle with TAS angle of 89°. (b) Four weeks post-operative clinical condition, varus deformity is corrected. (c) Four months post-operative evaluation showed graft fusion and normal TAS angle (internal documentation).

the patient is also unable to walk. He had a motorcycle accident eight years ago, was diagnosed with ankle fracture AO 44B2.1 and underwent internal fixation. Implant removal was done a year later. Upon admission to our hospital, we performed thorough

anamnesis, physical examination of ankle range of motion (ROM), and radiologic imaging. Left ankle varus deformity, positive talar tilt test, tenderness, and limited ROM was observed during physical examination. Radiologically, stage 3 ankle OA was seen. Varus deformity (TAS) was confirmed

to be 74° (normal 88°-93°) (Fig. 1). No history of diabetes mellitus, corticosteroid, and alcohol consumption were obtained. The pre-operative questionnaire of AAOS FAM was taken to measure ankle-foot function objectively.

Few procedures have been described and although it has the disadvantage of joint motion loss, ankle arthrodesis is still preferred by experts. In order to maintain the joint motion, the authors performed low-tibial osteotomy.

The open wedge osteotomy was performed on the left distal tibia above the syndesmotic joint as well as on the middle third of the fibula under fluoroscopic guidance until normal TAS was achieved (Fig. 2a).

After the normal TAS was achieved, cortical allograft and cancellous bovine bone graft were used to fill the osteotomy gap on distal tibia, the graft were temporarily stabilised with wire. For the final fixation, a clover-leaf® plate with six screws were used (Fig. 2b).

Immediate post-operative evaluation showed satisfactory 89o TAS and reduced AAOS FAM disability index scores. The scale improved from 89 to 38 post-operatively which indicated significant improvement of patient's ankle-foot function (Fig. 3a). Four weeks post-operative clinical condition showed healed scar and corrected varus deformity (Fig. 3b).

Full weight-bearing and return to activities were achieved at 12 weeks post-operative, while radiological union with complete graft fusion was achieved 4 months post-operative (Fig. 3c).

## DISCUSSION

Post-traumatic ankle osteoarthritis is very rare. Varus type osteoarthritis of the ankle originates from both traumatic and idiopathic causes. Varus type osteoarthritis can be classified into stage I (no joint space narrowing yet sclerosis and osteophyte presents), stage II (reduction of medial joint space), stage III (joint space obliterated medial aspect and contact between adjacent subchondral bone), or stage IV (loss of joint space with connection between tibia and talus)<sup>4</sup>.

Treatment of ankle OA in the severe stage is debatable. Ankle arthrodesis often becomes the expert's choice due to the unavailability of arthroplasty implant for the ankle in many countries.

Hongmou *et al* reported the treatment of OA at mid-ankle to maintain half or more tibiotalar joint surface is challenging and controversial. Supramalleolar osteotomy (SMOT) is an effective procedure for the treatment of an asymmetric ankle OA, aimed at realigning the mechanical axis of the ankle joint<sup>1,4,5</sup>.

The minimally invasive posteromedial approach in combination with minimally invasive plate osteosynthesis (MIPO) may minimise soft tissue dissection to reduce wound complications. In such cases, the osteotomy is performed through fibula, tibia, and synostosis in between. The anteromedial incision to complement the medial part of the osteotomy. The elastic plate can be used to protect the neurovascular bundle (protecting anterior tibial artery and peroneal nerve)<sup>5</sup>.

Takakura *et al* reported 18 patients with OA ankles who underwent low tibial osteotomy surgery, which showed satisfactory results at 6 years follow up. In another study, there was an improvement in radiological features where the TAS angle was corrected from 82.7° to 98.2° and TLS angle from 78.5° to 84.7°. Varus angle also improved from 7.3° to 5.0° post-operatively<sup>4</sup>.

Tibial open wedge osteotomy is recommended rather than lateral closing wedge osteotomy in treating the varus deformity. The complexity of the anterolateral compartment of the knee becomes the main risk factor for lateral muscle weakness in many reported lateral closing wedge procedure.

Due to its advantage of preserved joint motion compared to arthrodesis, low tibial osteotomy could be considered as a surgical choice for severe ankle osteoarthritis in productive age patients. Fibular osteotomy provides an additional advantage in ankle joint angle correction<sup>1-3,5</sup>. The result is good and we achieved the main surgical goal of this technique.

## CONFLICT OF INTEREST

The authors declare no potential conflict of interest.



## REFERENCES

1. Colin F, Bolliger L, Horn-Lang T, Knupp M, Hintermann B. Effect of supramalleolar osteotomy and total ankle replacement on talar position in the varus osteoarthritic ankle: a comparative study. *Foot Ankle Int.* 2014; 35(5): 445-52. doi: 10.1177/1071100713519779
2. Ewalefo SO, Dombrowski M, Hirase T, Rocha JL, Weaver M, Kline A, et al. Management of posttraumatic ankle arthritis: literature review. *Curr Rev Musculoskelet Med.* 2018; 11(4): 546-57. doi: 10.1007/s12178-018-9525-9
3. Cheng YM, Huang PJ, Hong SH, Lin SY, Liao CC, Chiang HC, et al. Low tibial osteotomy for moderate ankle arthritis. *Arch Orthop Trauma Surg.* 2001; 121(6): 355-8. doi: 10.1007/s004020000243
4. Hongmou Z, Xiaojun L, Yi L, Hongliang L, Junhu W, Cheng L. Supramalleolar osteotomy with or without fibular osteotomy for varus ankle arthritis. *Foot Ankle Int.* 2016; 37(9): 1001-7. doi: 10.1177/1071100716649926
5. Ahn TK, Yi Y, Cho JH, Lee WC. A cohort study of patients undergoing distal tibial osteotomy without fibular osteotomy for medial ankle arthritis with mortise widening. *J Bone Joint Surg.* 2015; 97(5): 381-8. doi: 10.2106/JBJS.M.01360