

# Excellent Result of Revision Total Hip Replacement with Unexpected Metallosis

*by* Mohammad Zaim Chilmi

---

**Submission date:** 07-Sep-2022 04:20PM (UTC+0800)

**Submission ID:** 1894263520

**File name:** 4.\_Article.pdf (1.33M)

**Word count:** 2693

**Character count:** 15015

## Case Report

Hip Knee J. Vol. 2, No. 2, 2021, pp. 83-88

p-ISSN: 2723-7818

e-ISSN: 2723-7826

<http://dx.doi.org/10.46355/hipknee.v2i2.90>



# Excellent Result of Revision Total Hip Replacement with Unexpected Metallosis

Azmi Farhadi<sup>1</sup>, Kuku Dwiputra Hernugrahanto<sup>1</sup>, Jifaldi AMD Sedar<sup>1</sup>, Mohammad Zaim Chilmi<sup>1</sup>

13

Department of Orthopedic and Traumatology, Faculty of Medicine Airlangga University, Dr. Soetomo Surabaya General Hospital

## ABSTRACT

**Background:** Metallosis is a syndrome of metal-induced synovitis with infiltration and accumulation of metallic debris into the periprosthetic structures, including soft and bony tissues. The debris causes a chronic inflammatory reaction due to joint instability, pain, osteolysis, implant loosening, or implant failure. The absence of a specific sign or symptom that indicates metallosis causes difficulty to diagnose.

**Presentation of Case:** A 35-year-old female, history of primary left total hip replacement since seven years ago after avascular necrosis of the femoral head, presented with an eight-month history of left hip pain and limited range of motion. Radiograph results showed that there is no evidence of periprosthetic fracture or infection. The patient underwent a left revision total hip replacement, which revealed extensive necrotic black metal debris throughout the joint space.

**Discussion:** Effective treatment requires a revision of total hip replacement to remove metal debris, bone graft area osteolysis, and to address the mechanical failure. The greatest possible of metallic debris during debridement is vital to avoid further osteolysis and prevent more extensive damage. Excellent clinical result was evaluated by Harris's hip score in 18 months postoperatively.

**Conclusion:** This case is a rare example of chronic metallosis presenting seven years following total hip replacement. Revision total hip replacement is the consensus management choice to avoid further destruction of the bone and joint capsule that can occur with metal-induced inflammation.

**Keywords:** *Metallosis; hip replacement; osteolysis; revision*

**Level of Evidence:** IV



This is an open access article under the [CC-BY-SA](https://creativecommons.org/licenses/by-sa/4.0/) license.

### Article history:

Submission : June 2<sup>nd</sup>, 2021  
Revision : July 17<sup>th</sup>, 2021  
Accepted : July 27<sup>th</sup>, 2021

### Corresponding Author:

Mohammad Zaim Chilmi, MD, PhD  
Department of Orthopaedic and Traumatology, Faculty of  
Medicine, Universitas Airlangga, Dr. Soetomo General  
Hospital, Jl. Mayjend Prof. Dr. Moestopo No. 6-8, Airlangga,  
Surabaya 60286, Indonesia. e-mail: [chilmi.orth@yahoo.co.id](mailto:chilmi.orth@yahoo.co.id)

## Introductions

Metallosis defined as aseptic fibrosis, local necrosis or loosening of a device secondary to metallic corrosion and release of wear debris.<sup>1</sup> Metallosis arises in the joint capsule, around the acetabular cup and the femoral stem.<sup>2</sup> Metallosis is used to label infiltration metallic wear debris secondary to metal-on-metal wear into the bone, synovium, and periprosthetic soft tissues.<sup>3</sup> Debris due to a chronic inflammatory response leading to joint instability, swelling, pain and may cause osteolysis, implant loosening, and eventually implant.<sup>4,5</sup>

The rare incidence of metallosis usually causes diagnosis challenges, especially after a long time procedure.<sup>6</sup> The prevalence of metallosis after THR is unidentified because of the minimal number of literature, generally showing chronic symptoms between 5 to 10 years out from the primary procedure.<sup>1</sup> Low clinical doubt because of the absence of specific sign or symptom indicates metallosis, which can be suspected only after careful history appraisal.<sup>4,7</sup>

Radiographs evaluation, blood examination, and joint aspiration performed to rule out aseptic loosening, implant failure, trauma, and most importantly, infection.<sup>4</sup> Furthermore, serological tests and arthrocentesis are essential to rule out an infectious etiology.<sup>8</sup> As such, in the presence of radiographic signs of metallosis and a lack of infectious markers, a diagnosis of metallosis can be made with relative accuracy.<sup>8</sup> We describe a case report of metallosis in a 33-year-old patient and detail the diagnostic, proper treatment, postoperative protocols, and follow-up evaluation after 1-year revision surgery.

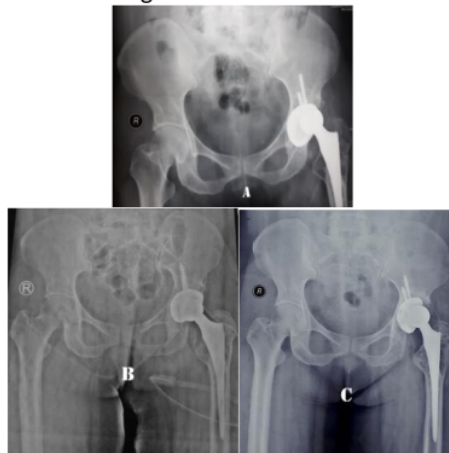There are still few journals that have not discussed metallosis even though the number of cases undergoing THR surgery is increasing. So that this research can be a pioneer and make other orthopedics consent to the occurrence of metallosis.

## Presentation of Case

In this case report, The subject is consented for report and publication and the subject has signed the informed consent. A 33-year-old female presented with an inability to walk

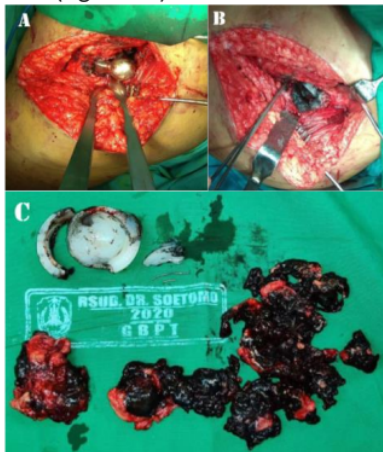
along with severe persistent pain around the left hip region and "click" audible crepitus for eight months. The patient had a history of primary left THR had performed seven years ago to treat avascular necrosis of the left femoral head because of a left neck femoral fracture before. The patient reported severe pain with weight-bearing, took the analgetic medication as needed, and used a cane for ambulation. She denied any constitutional symptoms indicative of infection. There were slight joint line tenderness groin region, palpable crepitus, and grinding when ranging the hip. The patient had passive flexion hip range of motion from 0 degrees to 100 degrees on physical exam, and also suffered pain while internal, external rotation, abduction and adduction testing.

Hip radiographs revealed amorphous densities in the anterosuperior capsule and the posteromedial consistent with the "cloud sign" and curved radio densities around the acetabular cup and femoral stem, consistent with the "bubble sign." There was osteolysis with the loosening of both the acetabular and femoral components (figure 1A). Blood work was obtained, with CRP and ESR levels within the normal range. Given the severe pain, signs of osteolysis and unstable implant, the recommendation was made for the patient to undergo revision THR.

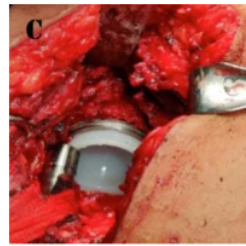
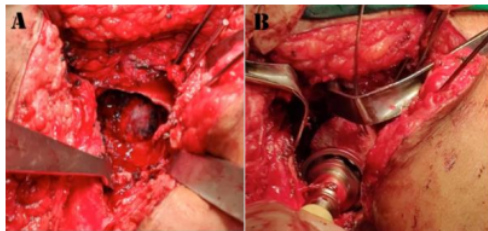


**Figure 1:** A) Pelvic radiograph before revision surgery showing osteolysis and amorphous density around the implant. B) Pelvic radiograph after revision surgery showing acetabular and femoral implant stable and fixed. C) Pelvic radiograph after 1-year follow-up showing acetabular component a little shear.

Unexpected findings during the operation were extensive necrotic black material overlying the entire hip joint after arthrotomy (figure 2A). A complete synovectomy was performed at the anterosuperior, posteromedial around acetabular, and femoral component regions to remove metallic debris. The acetabular polyethylene liner was severely worn, and the screw of acetabular metal had broken (figure 2B). After component removal, there was evidence of severe osteolysis of the inner acetabulum and extensive metal debris (figure 2C). After irrigation and debridement, most of the metal debris was removed, the acetabulum bony surface showed destruction (figure 3A). It was considered reconstruction bone loss using augmentation of femoral head allograft and restore the acetabulum's anatomical joint line by reamed it (figure 3B). The revision implants included long press-fit fitting stems in the acetabulum and femur cementless (figure 3C).



**Figure 2:** A) Metallic debris material after capsulotomy. B) Black necrotic metallic debris at acetabular component. C) Macroscopic appearance of the tissue excised



**Figure 3:** A) Osteolysis of acetabulum B) Reconstruction acetabular using augmentation femoral head allograft. C) Placement of the acetabular and femoral component.

12  
The patient was allowed to be non-weight bearing using two crutches until 6-8 weeks. She was able to ambulate, perform quadriceps muscle strengthening and range of motion exercises with physical therapy, and was discharged on the third day postoperative. At eight weeks follow-ups, her incision was healed, she was ambulating good weight-bearing with an assistance device two crutches, and her range of motion was 0-110 degrees. After 1-year follow-up, the patient was able to ambulate without any device, the patient walked with a limp but no discrepancy, able to puts on shoes and socks with ease, railing climbing up the stairs without using the railing, comfortably sitting on the ordinary chair for one hour, no limitation walked distance but felt slight pain occasionally with no compromise inactivity. Patients could use a transportation bus and ride a motorcycle, patients able to rise from a squatting position without holding a device and normal activities sexual intercourse. Patients can feel fully flexion of the hip 140 degrees, abduction 20 degrees, adduction 10 degrees, and external rotations 15 degrees (figure 4). Pelvic radiograph performed after revision surgery and 1-year follow up an expected position with no evidence of hardware failure or loosening (figure 1BC). She reported that she was satisfied with her prosthesis.

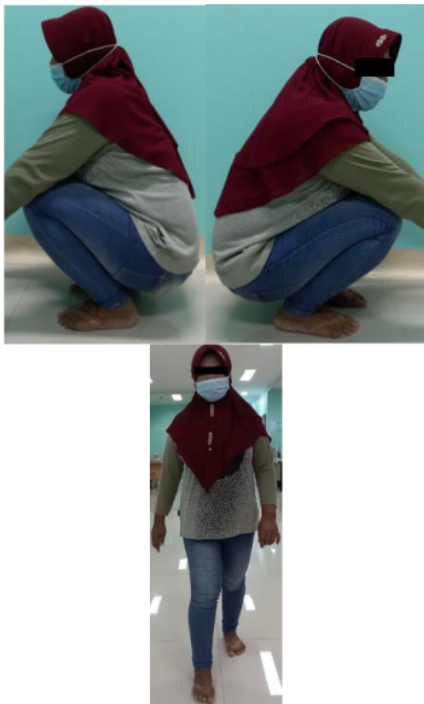

Figure 4: Clinical picture of a patient after 1 year follow up

Table 1: Evaluation of Harris Hip Score (HSS) after 6 months, 12 months, and 18 months follow up

	Pain	Mobility and Walking	Joint Movement	Absence of Deformity	Total
6 months	39	38	4	4	85
12 months	42	42	4	4	92
18 months	42	43	4	4	93

The patients were clinical evaluated using the Harris Hip Score at 6, 12, and 18 months postoperatively. HSS score is divided into 4 assessments, namely pain, mobility and walking, joint movement, and absence of deformity. The HSS interpretation is the more, the score the better the results. In the 6th month, the HSS score was obtained 85. HSS scores were better at months 12th (92) and 18th (93) (Table 1).

### Discussion

Metallosis, a chronic infiltration of metallic wear debris reactively is a pathologic phenomenon that can occur as a rare complication of failed arthroplasties due to articulation and wear of nonbearing surfaces.<sup>1</sup> Chang et al.,

reported the total incidence of metallosis as an outcome of THR failures was approximately 5.3%, is a type of scrape that is prevalent in patients with unsuccessful metal-on-metal implants, where both the metallic femoral and acetabular components are primary bearing surfaces.<sup>2,9</sup> Osteolysis of the periprosthetic osseous matter is also a common phenomenon that can occur due to severe metallosis.<sup>9</sup> There are still few journals that have not discussed metallosis even though the number of cases undergoing THR surgery is increasing. so the number of unexpected metallosis will also increase. We hope this research can be a pioneer and make other orthopedics consent to the occurrence of metallosis.

The rare incidence of metallosis usually causes diagnosis challenges, especially after a long-time operation. In this case report, we describe a patient with discomfort symptoms, "click" audible sound when the patient was walking, and limited range of motion of the hip.<sup>6</sup> Metallosis is a gradually evolving process that takes months to develop and present clinically.<sup>10</sup> Low clinical thought may be no specific sign or symptom that indicates metallosis, which can be suspected only after a careful review of history.<sup>7</sup> Metallosis usually poses a diagnostic that can be challenging, and, on most occasions, even experts in the field tend to misdiagnose it.<sup>11</sup> Any audible sounds can represent a significant complication.<sup>10</sup> Other less specific symptoms include a limited range of motion and hip pain. It is critical to differentiate metallosis from infection.<sup>8</sup>

Metallosis can be supposed preoperatively with radiographic signs such as the "cloud sign," "bubble sign," and the "metal-line signs".<sup>3,4</sup> Additionally, bubbly appearing radio densities representing metal deposition outlining the synovium are known as the "bubble" sign.<sup>4,8</sup> The "cloud" sign is the most commonly cited radiographic indication of possible metallosis and is interpreted as amorphous, fluffy densities in periprosthetic soft tissues, most commonly found posterior to the hip implant.<sup>8</sup> Finally, the "metal-line" sign represent a reedy linear radiodense line that outlines part of the joint capsule and is relatively specific for metal-induced synovitis.<sup>8</sup>

Evidence of these signs on imaging should prompt a close assessment for metallosis.<sup>8</sup> Serology and arthrocentesis are equally essential to rule out infectious etiology.<sup>8</sup> At the same time, the persistent elevation of ESR, with abnormal levels defined as > 30 mm/hr three months to one year after THR, is often indicative of infection (specificity of 87%).<sup>8</sup> As such, in the presence of radiographic signs of metallosis and absence of infectious markers, a diagnosis of metallosis can be made with relative accuracy.<sup>8</sup>

Successful treatment involves surgical revision with the suitable replacement of the prosthesis components, complete surgical debridement of osteolytic lesions, irrigation, synovectomy, and bone grafting through allograft chips.<sup>4,8</sup> Complete removals of all metal debris is challenging and may result in extensive tissue damage.<sup>6</sup>

Chang et al., reported 31 patients noted at revision surgery hip joint metallosis, acetabular and femoral component revision for metallosis has satisfactorily established good outcomes at intermediate-term follow-up, with no evidence of osteolysis or cup relocation.<sup>2</sup> At a mean follow-up of 5.6 years, none of the revised hips demonstrated radiolucent lines, acetabular cup migration, osteolysis, or necessary alteration in inclination. Replacement of the polyethylene liner, debridement of osteolytic lesions, and augments bone grafting with allograft chips are adequate the first five years after revision surgery if the implant was not loose at revision.<sup>2</sup> If the implant is well fixed, leaving metallogenic tissue appears not to affect the long-term revision surgery results for metallosis.<sup>2,4</sup>

Clinical evaluation of this patient was successful based on HHS. This patient got HSS 83 in 6 months, 92 in 12 months, and 93 in 18 months. This research uses HSS due to its ease of use by patients, most widely used hip scoring system in the literature, and excellent arrangement amid patient self-report and physician assessment of pain and function founded on items in the HHS.<sup>12</sup> Excellent clinical result was evaluated by Harris's hip score in 18 months postoperatively.

### Conclusion

Metallosis after THR is an uncommon complication that can lead to significant functional impairment. The orthopedic surgeons should be aware of the pertinent clinical and radiographic signs and be prepared to perform extensive revision surgery to restore joint function. Routine follow-up is ideal, and earlier detection of orthopedic surgeon's conditions is essential, as earlier limited surgical intervention can prevent the development of severe osteolysis and gross implant loosening, necessitating more complex revision.

### Consent of Patient

The patients have agreed to be documented and participated in this study

### References

1. Black J, Sherk H, Bonini J, Rostoker WR, Schajowicz F, Galante JO. Metallosis associated with a stable titanium-alloy femoral component in total hip replacement. A case report. *JBJS*. 1990;72(1):126–30.
2. Chang J-D, Lee S-S, Hur M, Seo E-M, Chung Y-K, Lee C-J. Revision total hip arthroplasty in hip joints with metallosis: a single-center experience with 31 cases. *J Arthroplasty*. 2005;20(5):568–73.
3. Birkett N, El-Daly I, Ibraheim H, Mbubaegbu C. Metallosis following full thickness wear in total hip arthroplasty. *J Surg case reports*. 2015;2015(9):rjv122.
4. Cipriano CA, Issack PS, Beksaç B, Della Valle AG, Sculco TP, Salvati EA. Metallosis after metal-on-polyethylene total hip arthroplasty. *Am J Orthop (Belle Mead NJ)*. 2008;37(2):E18–25.
5. Drummond J, Tran P, Fary C. Metal-on-metal hip arthroplasty: a review of adverse reactions and patient management. *J Funct Biomater*. 2015;6(3):486–99.
6. Oliveira CA, Candelária IS, Oliveira PB, Figueiredo A, Caseiro-Alves F. Metallosis: A diagnosis not only in patients with metal-

- on-metal prostheses. *Eur J Radiol open*. 2015;2:3–6.
7. Vaz R, Xavier P, Brito S, Dantas J, Duque S, Consciência JG, et al. Metallosis: A New Form of Autoimmune/Autoinflammatory Syndrome Induced by Adjuvants Syndrome (ASIA)? *Eur J case reports Intern Med*. 2019;6(3).
  8. Sharareh B, Phan DL, Goreal W, Schwarzkopf R. Metallosis presenting as knee pain 26 years after primary total knee arthroplasty. *J Orthop case reports*. 2015;5(2):62.
  9. Paydar A, Chew FS, Manner PA. Severe periprosthetic metallosis and polyethylene liner failure complicating total hip replacement: the cloud sign. *Radiol case reports*. 2007;2(4):115.
  10. Kumar A, Zaidi SMH, Sahito B, Kumar D, Ali M. A Case Report of Metallosis With a Failed Distal Femur Plate. *Cureus*. 2020;12(9).
  11. Winston BA, Kagan RP, Huff TW. Delayed diagnosis of catastrophic ceramic liner failure with resultant pelvic discontinuity and massive metallosis. *Arthroplast today*. 2017;3(2):77–82.
  12. Mahomed NN, Arndt DC, McGrory BJ, Harris WH. The Harris hip score: comparison of patient self-report with surgeon assessment. *J Arthroplasty*. 2001;16(5):575–80.

# Excellent Result of Revision Total Hip Replacement with Unexpected Metallosis

## ORIGINALITY REPORT

12%

SIMILARITY INDEX

6%

INTERNET SOURCES

11%

PUBLICATIONS

0%

STUDENT PAPERS

## PRIMARY SOURCES

- 1** FIRAT OZAN, Murat Kahraman, Ali Baktır, Kürşat Gençer. "Catastrophic Failure and Metallosis of the Acetabular Component in Total Hip Arthroplasty", Research Square Platform LLC, 2021  
Publication 1%
- 2** [assets.cureus.com](https://assets.cureus.com)  
Internet Source 1%
- 3** Mahomed, N.N.. "The Harris hip score", The Journal of Arthroplasty, 200108  
Publication 1%
- 4** Pungky Mulawardhana, Poedjo Hartono, Hari Nugroho, Atika Ayuningtyas. "Death of 43 Indonesian women with ovarian cancer: A case series", International Journal of Surgery Case Reports, 2021  
Publication 1%
- 5** [www.mdpi.com](https://www.mdpi.com)  
Internet Source 1%



6	Chang, J.D.. "Revision Total Hip Arthroplasty in Hip Joints With Metallosis", The Journal of Arthroplasty, 200508 Publication	1 %
7	s3-eu-west-1.amazonaws.com Internet Source	1 %
8	www.radiologycases.com Internet Source	1 %
9	Bone-Implant Interface in Orthopedic Surgery, 2014. Publication	1 %
10	Charles Riviere, Martin Lavigne, Ahmed Alghamdi, Pascal-André Vendittoli. "Early Failure of Metal-on-Metal Large-Diameter Head Total Hip Arthroplasty Revised with a Dual-Mobility Bearing", JBJS Case Connector, 2013 Publication	1 %
11	ejournal.unitomo.ac.id Internet Source	1 %
12	Eustathios Kenanidis, Panagiotis Kakoulidis, Eleftherios Tsiridis, Bülent Atilla et al. "Chapter 5 Acetabular Dysplasia", Springer Science and Business Media LLC, 2018 Publication	1 %
13	www.coursehero.com Internet Source	1 %

---

14 D. J. Langton, T. J. Joyce, S. S. Jameson, J. Lord, M. Van Orsouw, J. P. Holland, A. V. F. Nargol, K. A. De Smet. "Adverse reaction to metal debris following hip resurfacing", The Journal of Bone and Joint Surgery. British volume, 2011  
Publication

1 %

---

15 docksci.com  
Internet Source

<1 %

---

Exclude quotes Off

Exclude matches < 10 words

Exclude bibliography On

# Excellent Result of Revision Total Hip Replacement with Unexpected Metallosis

---

GRADEMARK REPORT

---

FINAL GRADE

**/0**

GENERAL COMMENTS

**Instructor**

---

PAGE 1

---

PAGE 2

---

PAGE 3

---

PAGE 4

---

PAGE 5

---

PAGE 6

---