

# Diagnostic Dilemma of Pericarditis Concurrent With ST Elevation Myocardial Infarction

*by Mochamad Yusuf Alsagaff*

---

**Submission date:** 03-Mar-2023 10:51AM (UTC+0800)

**Submission ID:** 2027556438

**File name:** icarditis\_Concurrent\_With\_ST\_Elevation\_Myocardial\_Infarction.pdf (832.91K)

**Word count:** 1627

**Character count:** 9314

## Challenges in Clinical Electrocardiography

## Diagnostic Dilemma of Pericarditis Concurrent With ST Elevation Myocardial Infarction

Mochamad Yusuf Alsagaff, MD, PhD; Yudi Her Oktaviono, MD, PhD; Terrence Timothy Evan Lusida, MD

## Case Presentation

A 57-year-old man presented to the emergency department with persistent diffuse ST elevation (STE) after failed treatment with streptokinase therapy that was administered the day prior (the onset of chest pain to lytic bolus was 8 hours). The pain was persistent, radiated to the back, and was exacerbated by coughing. He had normal blood pressure (100/60 mm Hg), mild dyspnea with bibasilar rales (22 breaths per minute), elevated jugular venous pulse, and pericardial friction rub. A 12-lead electrocardiogram (ECG) was obtained (Figure, A).

**Question:** What ECG characteristics help distinguish STE myocardial infarction (STEMI) from the simultaneous occurrence of pericarditis and STEMI?

## Interpretation

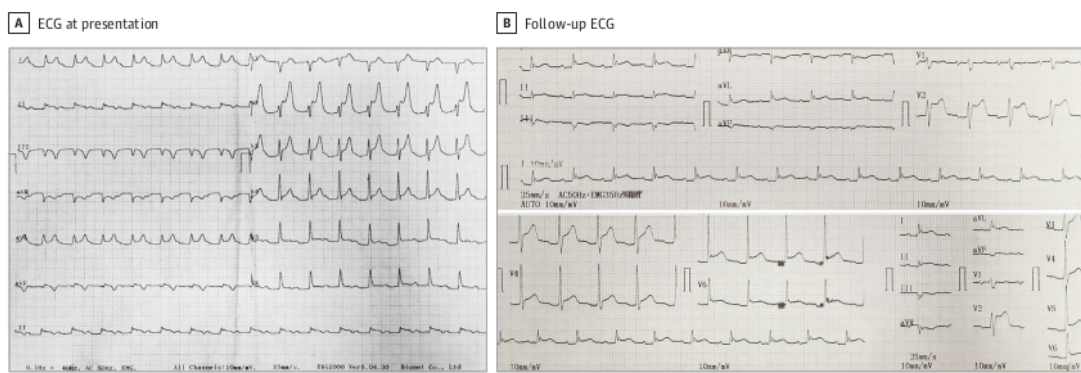
The ECG indicated diffuse STE in most leads and knuckle sign (PR-segment elevation and ST-segment depression in aVR) (Figure, A). Laboratory test results revealed elevated levels of cardiac troponin (0.46 ng/mL [to convert to  $\mu\text{g/L}$ , multiply by 1]; reference value, 0.001 ng/mL), leukocytes ( $27 \times 10^3/\mu\text{L}$  [to convert to  $\times 10^9/\text{L}$ , multiply by 0.001]), and C-reactive protein (2.0 mg/dL [to convert to mg/L, multiply by 10]; reference value, <10 mg/L). Transthoracic echocardiography (TTE) demonstrated minimal-to-moderate pericardial effusion (PE) and regional wall motion abnormalities in the inferior and posterior regions. Diagnostic coronary angiography was performed because of persistent chest pain, and the progression of ECG features to an intermittent total atrioventricular (AV) block (TAVB). Critical stenosis (99% diameter) of the distal right coro-

nary artery (RCA) and moderate-to-high critical calcified stenosis (99% diameter) of the proximal left circumflex artery (LCX) with grade 2 collaterals from the distal left anterior descending artery were observed. No signs of thrombus or plaque rupture were detected. The obstruction was recanalized with balloon angioplasty followed by use of drug-eluting stents to the RCA and LCX to achieve acceptable angiographic results. Inferior STEMI with pericarditis was diagnosed. The patient was treated with high-dose aspirin (750 mg, 3 times a day), colchicine (0.5 mg, once daily), ticagrelor, furosemide, ramipril, atorvastatin, and lansoprazole. The follow-up ECG after rescue percutaneous coronary intervention revealed a return to baseline of the STE with a new Q wave in the inferior leads, PR-segment depression, knuckle sign in aVR, and persistence of STE and an upright T wave in the anterolateral leads (Figure, B). The patient recovered and was discharged on the fifth day.

## Discussion

The ST-segment changes observed in patients with STEMI and pericarditis may present a diagnostic dilemma for emergency physicians. Furthermore, pericarditis may complicate the course of myocardial infarction (MI), and, in this case, pericarditis might mask the STEMI-derived need for reperfusion.<sup>1</sup> The working diagnosis of pericarditis in this case was made based on diffuse STE, pericardial friction rub, and PE.<sup>2</sup> However, the patient's complaints of chest pain were confusing. Although chest pain is one of the most common symptoms of pericarditis, it may be occasionally difficult to use this factor to differentiate pericarditis from MI, especially if there is pericarditis-associated myocardial involvement.<sup>3</sup> In this case,

Figure. Serial 12-Lead Electrocardiogram (ECG)



A, The ECG demonstrated sinus tachycardia, diffuse ST-segment elevation (except leads III and V<sub>1</sub>), knuckle sign in aVR (PR-segment elevation and ST-segment depression), and a prolonged PR-segment interval (280 milliseconds). B, The ECG recordings performed 24 hours after rescue percutaneous coronary intervention demonstrated sinus rhythm, a return to baseline of the ST-segment elevation with a new Q wave in the inferior leads (II, III, aVF), PR-segment depression, knuckle sign in aVR, and the persistence of ST-segment elevation and an upright T wave in the anterolateral leads (V<sub>2</sub>-V<sub>6</sub>, lead I, and aVL).

the elevated troponin I level, regional wall motion abnormalities, transient TAVB, and critical stenosis in the LCX and RCA ultimately led to the diagnosis of inferior STEMI with pericarditis.

Electrocardiography is the mainstay of the initial diagnosis of pericarditis or MI. In contrast to STEMI, pericarditis is characterized by diffuse and concave STE in most or all precordial and limb leads. There was no reciprocal ST-segment depression and no abnormal Q waves. In addition, the T wave in pericarditis displays normal morphology and may be inverted after a variable period (weeks or months). Other essential clues of pericarditis include PR-segment depression in most leads and knuckle sign in aVR.<sup>4-6</sup>

By contrast, the STE in STEMI usually displays a convex morphology and appears according to the anatomical groupings, which correspond to the vascular territory of infarction. Nevertheless, a less specific concave morphology can also be observed. Moreover, reciprocal ST-segment depression in opposing leads has high diagnostic specificity for STEMI. In inferior MI, the conduction disturbance can cause transient sinus bradycardia and TAVB, because the sinoatrial node, AV node, and his bundle are primarily supplied by the RCA.<sup>7</sup> Such weakening of electrical activity in the infarcted myocardium decreases the R wave amplitude. When myocardial cells are no longer active, as in the case of extensive infarction, only the activity of opposing areas appears in the ECG as Q waves.<sup>4</sup>

In the case described in this article, the diffuse and concave STE in the anterior leads led to the diagnosis of pericarditis. However, the convex STE, different evolution of T and Q waves in the inferior leads, and conduction disturbance resulting in intermittent TAVB might indicate inferior STEMI. When STEMI and pericarditis occur together, the typical ECG changes observed in pericarditis are often overshadowed by STEMI-associated changes. However, a persistently elevated ST-segment with persistent upright T waves or early gradual reversal of inverted T waves may aid in the early rec-

ognition and diagnosis of pericarditis (sensitivity, 100%; specificity, 77%) (Figure, B). Concurrent STEMI and pericarditis present a further diagnostic challenge because no ECG criteria exist to confirm this condition.<sup>5,8</sup> Therefore, the final diagnosis depends on the clinical context and additional supporting findings.

Transthoracic echocardiography aids in the diagnosis of pericarditis and STEMI. This technique can differentiate between these 2 diagnoses by excluding PE and regional wall motion abnormalities that match the distribution of coronary blood flow. However, the absence of PE does not rule out pericarditis, as it may only occur in 60% of cases.<sup>2</sup> Regional wall motion abnormalities support the diagnosis of MI when co-occurring with increased cardiac troponin levels.<sup>9</sup> Troponin elevation is seen in patients with myocardial involvement that is caused by pericarditis (perimyocarditis) and MI. Differentiating perimyocarditis and STEMI might be challenging because both share elevated levels of cardiac markers, regional wall motion abnormalities, conduction disturbance, and STE. To confirm the diagnosis of perimyocarditis, diagnostic coronary angiography is required to exclude coronary occlusion. Cardiovascular magnetic resonance imaging is also recommended to verify myocardial involvement and rule out ischemic myocardial necrosis in the absence of substantial coronary disease. Lastly, an endomyocardial biopsy is necessary for definitive confirmation of perimyocarditis.<sup>3,8</sup>

#### Take-home Points

- ST elevation myocardial infarction and pericarditis may occur together.
- In most cases, ECG, TTE, and cardiac markers may help in differentiating acute pericarditis from STEMI.
- In cases of pericarditis with suspected myocardial involvement, invasive coronary angiography is recommended to exclude STEMI diagnosis.

#### ARTICLE INFORMATION

**Author Affiliations:** Department of Cardiology and Vascular Medicine, Faculty of Medicine, Universitas Airlangga-Dr Soetomo General Hospital, Surabaya, Indonesia.

**Corresponding Author:** Mochammad Yusuf Alsagaff, MD, PhD, Department of Cardiology and Vascular Medicine, Faculty of Medicine, Universitas Airlangga-Dr Soetomo General Hospital, Mayjen Prof Dr Moestopo St No. 47, Surabaya 60132, Indonesia (yusuf\_505@fk.unair.ac.id).

**Published Online:** March 21, 2022.  
doi:10.1001/jamainternmed.2022.0318

**Conflict of Interest Disclosures:** None reported.

**Additional Contributions:** We thank the patient for granting permission to publish this information.

#### REFERENCES

1. Witting MD, Hu KM, Westreich AA, Tewelde S, Farzad A, Mattu A. Evaluation of Spodick's sign and other electrocardiographic findings as indicators of STEMI and pericarditis. *J Emerg Med.* 2020;58(4):562-569.
2. Chiabrando JG, Bonaventura A, Vecchié A, et al. Management of acute and recurrent pericarditis. *J Am Coll Cardiol.* 2020;75(1):76-92.
3. Imazio M, Brucato A, Barbieri A, et al. Good prognosis for pericarditis with and without myocardial involvement. *Circulation.* 2013;128(1):42-49.
4. de Blik EC. ST elevation: differential diagnosis and caveats: a comprehensive review to help distinguish ST elevation myocardial infarction from nonischemic etiologies of ST elevation. *Turk J Emerg Med.* 2018;18(1):1-10.
5. Oliva PB, Hammill SC, Edwards WD. Electrocardiographic diagnosis of postinfarction regional pericarditis. *Circulation.* 1993;88(3):896-904.
6. George A, Arumugham PS, Figueredo VM. aVR—the forgotten lead. *Exp Clin Cardiol.* 2010;15(2):e36-e44.
7. Zimetbaum PJ, Josephson ME. Use of the electrocardiogram in acute myocardial infarction. *N Engl J Med.* 2003;348(10):933-940.
8. Adler Y, Charron P, Imazio M, et al; ESC Scientific Document Group. 2015 ESC guidelines for the diagnosis and management of pericardial diseases. *Eur Heart J.* 2015;36(42):2921-2964.
9. Kontos MC, Diercks DB, Kirk JD. Emergency department and office-based evaluation of patients with chest pain. *Mayo Clin Proc.* 2010;85(3):284-299.

# Diagnostic Dilemma of Pericarditis Concurrent With ST Elevation Myocardial Infarction

## ORIGINALITY REPORT

17%

SIMILARITY INDEX

10%

INTERNET SOURCES

15%

PUBLICATIONS

0%

STUDENT PAPERS

## PRIMARY SOURCES

- 1** Brian M. Clemency, David J. Koster, Michael S. Blaiss. "Inhaled Ciclesonide for Patients With Asthma or Chronic Obstructive Pulmonary Disease and COVID-19—Reply", *JAMA Internal Medicine*, 2022  
Publication 1%
- 2** [www.binasss.sa.cr](http://www.binasss.sa.cr)  
Internet Source 1%
- 3** Robert C. Ward, Megha Prasad, Robert L. Frye. "71-Year-Old Man Presenting With Postoperative Chest Tightness", *Mayo Clinic Proceedings*, 2019  
Publication 1%
- 4** [curezone.org](http://curezone.org)  
Internet Source 1%
- 5** [pagepress.org](http://pagepress.org)  
Internet Source 1%
- 6** Julia H. Indik, Joseph S. Alpert. "Post-myocardial infarction pericarditis", *Current* 1%

# Treatment Options in Cardiovascular Medicine, 2000

Publication

---

7	Myopericardial Diseases, 2016. Publication	1 %
8	R. Verma. "Disseminated Mycobacterium avium-intracellulare Infection Presenting as Multiple Ring-Enhancing Lesions on Brain MRI", Mayo Clinic Proceedings, 05/01/2009 Publication	1 %
9	Stress Echocardiography, 2015. Publication	1 %
10	vdoc.pub Internet Source	1 %
11	wecoc.web.id Internet Source	1 %
12	Curtis B. Williams, Jung-in Choi, Farshad Hosseini, James Roberts, Krishnan Ramanathan, Kevin Ong. "Acute Myocarditis Following mRNA-1273 SARS-CoV-2 Vaccination", CJC Open, 2021 Publication	1 %
13	Gul H. Dadlani, Thomas C. Edwards, Steven Fishberger, Amos Epelman, Nicholas Erbrich. "Pediatric Electrocardiograms for the General Practitioner: The Importance of the T-Wave", Pediatric Annals, 2018	1 %

14

[hal-univ-rennes1.archives-ouvertes.fr](http://hal-univ-rennes1.archives-ouvertes.fr)

Internet Source

1 %

---

15

"2015 ESC Guidelines for the diagnosis and management of pericardial diseases : The Task Force for the Diagnosis and Management of Pericardial Diseases of the European Society of Cardiology (ESC)Endorsed by: The European Association for Cardio-Thoracic Surgery (EACTS)",  
European Heart Journal, 2015.

Publication

1 %

---

16

Chan, T.C.. "Electrocardiographic manifestations: acute myopericarditis",  
Journal of Emergency Medicine, 199909/10

Publication

1 %

---

17

[tgkdc.dergisi.org](http://tgkdc.dergisi.org)

Internet Source

1 %

---

18

"Manual of Outpatient Cardiology", Springer  
Science and Business Media LLC, 2012

Publication

1 %

---

19

Gauravkumar Divani, Anunay Gupta, Ankit Jain. "Tachycardiomyopathy—The Eye Cannot See What the Mind Does Not Know", JAMA  
Internal Medicine, 2022

Publication

1 %

---

20

[assets.cureus.com](http://assets.cureus.com)

Internet Source

1 %

21

[www.amboss.com](http://www.amboss.com)

Internet Source

1 %

22

Oliva, P.B.. "Cardiac rupture, a clinically predictable complication of acute myocardial infarction: Report of 70 cases with clinicopathologic correlation", *Journal of the American College of Cardiology*, 199309

Publication

1 %

Exclude quotes On

Exclude matches Off

Exclude bibliography On

# Diagnostic Dilemma of Pericarditis Concurrent With ST Elevation Myocardial Infarction

---

GRADEMARK REPORT

---

FINAL GRADE

**/100**

GENERAL COMMENTS

**Instructor**

---

PAGE 1

---

PAGE 2

---