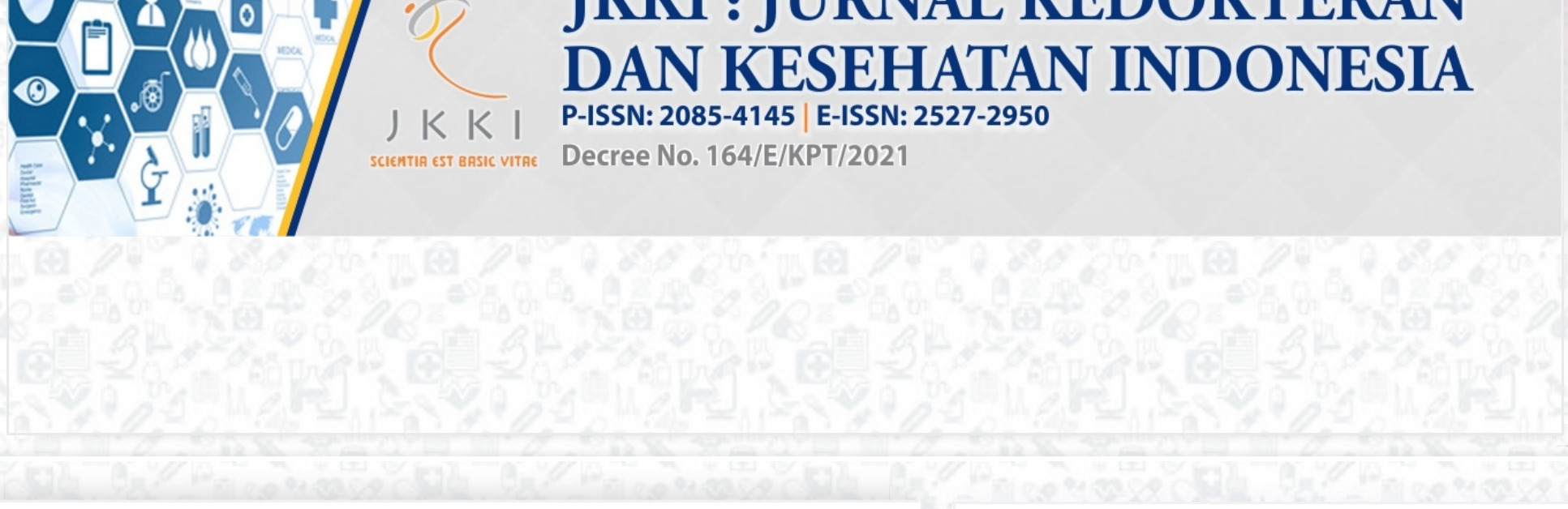



Home / Archives / JKJI, Vol 11, No 2, (2020)

Published: August 31, 2020

Editorials

Pathophysiological and clinical findings of Covid-19 virus infection in respiratory system: A anatomist's view point

Takashi Yashiro (1), Endin Nokik Stujanna (2), Leli Hesti Indriyati (3), Wawang Setiawan Sukarya (4)
(1) Jichi Medical University School of Medicine,
(2) Faculty of Medicine, Universitas Muhammadiyah Prof.DR. Hamka, City of South Jakarta,
(3) Faculty of Medicine, Universitas Muhammadiyah Prof.DR. Hamka, City of South Jakarta,
(4) Faculty of Medicine, Universitas Muhammadiyah Prof.DR. Hamka, City of South Jakarta
105-106
PDF
Read Statistic: 535

Original Article

Multidrug-resistant Klebsiella pneumoniae from clinical isolates at dr. Soeradij Tirtonegoro central hospital Klaten

Handi Wirawan (1), Titik Nuryastuti (2), Hera Nirwati (3)
(1) Undergraduate Student of Faculty of Medicine, Public Health and Nursing, Universitas Gadjah Mada, Yogyakarta,
(2) Department of Microbiology, Faculty of Medicine, Public Health and Nursing, Universitas Gadjah Mada, Yogyakarta,
(3) Department of Microbiology, Faculty of Medicine, Public Health and Nursing, Universitas Gadjah Mada, Yogyakarta
109-120
PDF
Read Statistic: 1290

Nutritional profile in Indonesian elderly subpopulation

Deasy Irawati (1), Ardiana Ekawanti (2), Anom Josafat (3)
(1) Department of Public Health, Faculty of Medicine, Universitas Mataram, Mataram,
(2) Department of Biochemistry, Faculty of Medicine, Universitas Mataram, Mataram,
(3) Department of Public Health, Faculty of Medicine, Universitas Mataram, Mataram
121-129
PDF
Read Statistic: 930

Relationship between thyroid hormone and lipid profile in patients with struma at the iodine deficiency disorder (IDD) clinic of research and development center Magelang

Yusi Dwi Nurcahyani (1), Prihanto Broto Sukandar (2), Raden Edi Fitriyanto (3), Syaefudin Ali Akhmad (4)
(1) Health Research and Development Center, Magelang,
(2) Health Research and Development Center, Magelang,
(3) Department of Biochemistry, Faculty of Medicine, Universitas Islam Indonesia, Yogyakarta,
(4) Department of Biochemistry, Faculty of Medicine, Universitas Islam Indonesia, Yogyakarta
130-140
PDF
Read Statistic: 824

Prevalence of constipation and lifestyle risk factors related to constipation in an adult population of South Tangerang

Hoirun Nisa (1)
(1) Department of Public Health, Faculty of Health Sciences, Universitas Islam Negeri Syarif Hidayatullah, Jakarta
141-149
PDF
Read Statistic: 891

Effectiveness of neem (Azadirachta indica ajuss) bark extract as a gastroprotector

Elisa Nuraida (1), Dwi Sutningsih (2), Mohammad Hadi (3)
(1) Students of Master of Epidemiology, Universitas Diponegoro, Semarang,
(2) Faculty of Public Health, Universitas Diponegoro, Semarang,
(3) Faculty of Science and Mathematics, Universitas Diponegoro, Semarang
150-156
PDF
Read Statistic: 538

Assessments of quality of life in burn patients after hospital treatment in Jember

Agnellia Maulidya Utami (1), Ulfa Elfiah (2), Desie Dwi Wisudanti (3)
(1) Faculty of Medicine, Universitas Jember, Jember,
(2) Department of Plastic Surgery, Faculty of Medicine, Universitas Jember, Jember,
(3) Department of Pharmacology, Faculty of Medicine, Universitas Jember, Jember
157-164
PDF
Read Statistic: 817

Influences of oral cryotherapy on mucositis prevention in cancer patients with chemotherapy

Nataria Yanti Silaban (1), Siti Saidah Nasution (2), Cholinda Trisa Siregar (3)
(1) Master Program, Faculty of Nursing, Universitas Sumatera Utara, Medan,
(2) Faculty of Nursing, Universitas Sumatera Utara, Medan,
(3) Faculty of Nursing, Universitas Sumatera Utara, Medan
165-171
PDF
Read Statistic: 733

The hypoglycemic effects of tapak liman (Elephantopus scaber L) plant extract on albino rat (Rattus novergicus) models of diabetes mellitus

Tri Agustri Sholikah (1), Sri Wulandari (2), Indah Ariesta (3), Muhammad Arif Rakhman Hakim (4), Muhammad Haifizan (5)
(1) Department of Histology, Faculty of Medicine, Universitas Sebelas Maret, Surakarta,
(2) Department of Physiology, Faculty of Medicine, Universitas Sebelas Maret, Surakarta,
(3) Undergraduate student, Faculty of Medicine, Universitas Sebelas Maret, Surakarta,
(4) Undergraduate student, Faculty of Medicine, Universitas Sebelas Maret, Surakarta,
(5) Undergraduate student, Faculty of Medicine, Universitas Sebelas Maret, Surakarta
172-179
PDF
Read Statistic: 695

Effects of methanol extracts of insulin leaves (Tithonia diversifolia (hems.) A. Gray) on insulin resistance and secretion of alloxan induced-obese diabetic rats

Raden Edi Fitriyanto (1), Sugiarto Sugiarto (2), Dwi Tonang Ardianyanto (3)
(1) Department of Biochemistry, Faculty of Medicine, Universitas Islam Indonesia, Yogyakarta,
(2) Nutrition Science Postgraduate Program, Universitas Sebelas Maret, Surakarta,
(3) Nutrition Science Postgraduate Program, Universitas Sebelas Maret, Surakarta
180-190
PDF
Read Statistic: 646

Review Articles

Phylogeny magnitude of Mycobacterium tuberculosis based on genomic analysis

Budi Yanti (1), Mulyadi Mulyadi (2), Soetijpto Soetijpto (3), Ni Made Mertaniasih (4), Muhammad Amin (5)
(1) Department of Pulmonology and Respiratory Medicine, School of Medicine, Universitas Syiah Kuala, Banda Aceh,
(2) Faculty of Medicine, Universitas Nahdhatul Ulama Surabaya, Surabaya,
(3) Medical Biochemistry, Faculty of Medicine, Universitas Airlangga, Surabaya,
(4) Department of Clinical Microbiology, Faculty of Medicine, Universitas Airlangga, Surabaya,
(5) Department of Pulmonology and Respiratory Medicine, Faculty of Medicine, Universitas Airlangga
191-197
PDF
Read Statistic: 714

Case Report

Rhabdomyosarcoma metastases to the bone marrow of a 2-year-old male patient: A case report


Tri Ratnaningsih (1), Wirimena Hurimah (2)
(1) Departement of Clinical Pathology and Laboratory Medicine, Faculty of Medicine, Public Health, and Nursing, Universitas Gadjah Mada, Yogyakarta,
(2) Departement of Clinical Pathology and Laboratory Medicine, Faculty of Medicine, Public Health, and Nursing, Universitas Gadjah Mada, Yogyakarta
198-203
PDF
Read Statistic: 566

Percutaneous retrieval of intracardiac fragmented hemodialysis catheter using a snare-loop catheter: A case report

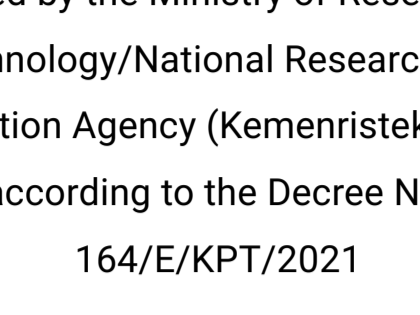
Adhitya Ginting (1), Ketut Putu Yasa (2), Yan Efrata Sembiring (3)
(1) Department Thoracic Cardiac and Vascular Surgery, Faculty of Medicine, Universitas Airlangga/dr.Soetomo General Hospital, Surabaya,
(2) Division of Thoracic, Cardiac, and Vascular Surgery, Department of Surgery, Faculty of Medicine, Universitas Udayana/ Sanglah General Hospital, Denpasar, Bali, Indonesia,
(3) Department Thoracic Cardiac and Vascular Surgery, Faculty of Medicine, Universitas Airlangga/dr.Soetomo General Hospital, Surabaya
204-213
PDF
Read Statistic: 450

Adjuvant chemotherapy-associated febrile neutropenia in a patient with breast malignancy: A case report

Esravila Ariya Wibisono (1), Onggo Wiliyanto (2)
(1) Pantli Wilasa Citarum Hospital, Semarang,
(2) Pantli Wilasa Citarum Hospital, Semarang
214-218
PDF
Read Statistic: 528



ACCREDITATION



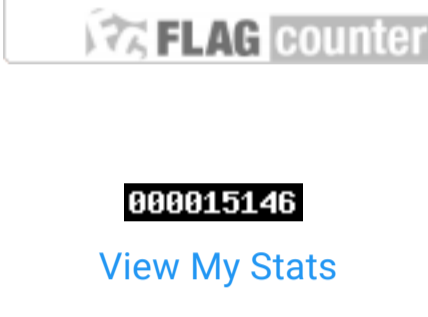
This journal has been accredited by the National Journal Accreditation (ARJUNA) Managed by the Ministry of Research and Technology/National Research and Innovation Agency (Kemristek/BRIN), according to the Decree No. 164/E/KPT/2021

- Aims & scopes | Submission | Manuscript template | Publication ethics | Plagiarism | Article processing charges | Editorial team | Indexing | Statistics

Editorial Team


- Novyan Lusiyana, Editor in Chief; Miranti Dewi Pramaningtyas, Managing Editor; Asri Hendrawati, Associate Editor

WEB STATISTICS

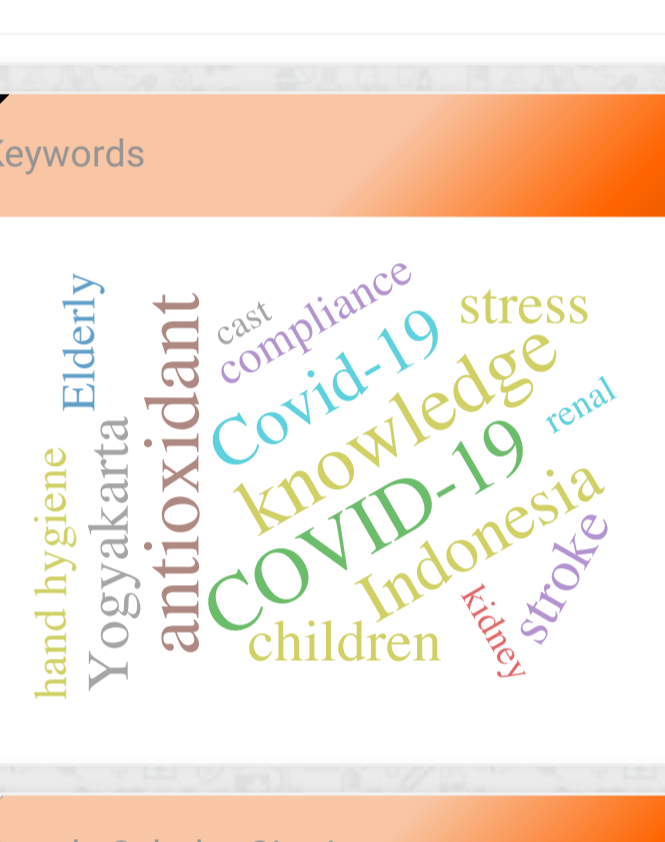


088915146 View My Stats

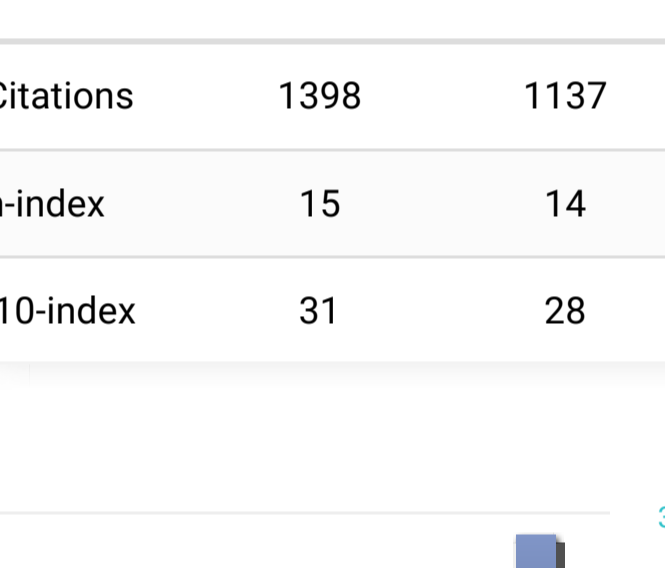
RECOMMENDED TOOLS



Published Volume By Year



Keywords



Google Scholar Citation

Table with columns: Citations, h-index, i10-index for All and Since 2018





Editorial Team

Editor-in-Chief

Novyan Lusiyana, (Scopus ID: 57192110115), Faculty of Medicine, Universitas Islam Indonesia, Yogyakarta, Indonesia

Advisory Editorial Board

Abu Khouldun Al-Mahmood, (Scopus ID: 12809783500), Ibn Sina Medical College, Bangladesh

Editorial Boards

Bharat Bhusan Aggarwal, (Scopus ID: 35375758200), Founding Director, Anti-inflammation Research Institute, San Diego, California

Zahia Kabouche,, Algeria

Irawan Satriotomo, (Scopus ID: 6603653795), Department of Physical Therapy, University of Florida, United States

Jajah Fachiroh, (Scopus ID: 8645842200), Department of Physiology and Cell Biology, Faculty of Medicine, Public Health, and Nursing, Universitas Gadjah Mada, Yogyakarta, Indonesia

Mustofa Mustofa, (Scopus ID: 6507664916), Faculty of Medicine, Public Health, and Nursing, Universitas Gadjah Mada, Yogyakarta, Indonesia

Teguh Haryo Sasongko, (Scopus ID: 12786227400), Division of Human Biology, School of Medicine, International Medical University, Malaysia

Nadeem Ahmad Afzal, (Scopus ID: 7006158291), Department of Immunology, University of Health Sciences, Lahore, Pakistan

Fezah Othman, (Scopus ID: 55056108800), Department of Biomedical Sciences, Faculty of Medicine & Health Sciences, Universiti Putra Malaysia, Selangor, Malaysia

Viera Wardhani, (Scopus ID: 57193545567) Department of Public Health, Faculty of Medicine, Universitas Brawijaya, Malang, Indonesia

Kintoko Kintoko, (Scopus ID: 55440497100), Faculty of Pharmacy, Universitas Ahmad Dahlan, Yogyakarta, Indonesia

Muhammad Yazli Yuhana, (Scopus ID: 56771500100), Department of Internal Medicine, Universiti Teknologi MARA, Malaysia

Sufi Desrini, (Scopus ID: 57193001337), Faculty of Medicine, Universitas Islam Indonesia, Yogyakarta, Indonesia

Asri Hendrawati, (Scopus ID: 57193545567), Faculty of Medicine, Universitas Islam Indonesia, Yogyakarta, Indonesia

Miranti Dewi Pramaningtyas, (Scopus ID: 57160319800), Faculty of Medicine, Universitas Islam Indonesia, Indonesia

Ika Fidiansingih, (Scopus ID: 57193001337), Faculty of Medicine, Universitas Islam Indonesia, Yogyakarta, Indonesia

Dwi Nur Ahsani, (Scopus ID: 57201617718), Faculty of Medicine, Universitas Islam Indonesia, Yogyakarta, Indonesia

Evy Sulistyoningrum, (Scopus ID: 57191907220), Faculty of Medicine, Universitas Islam Indonesia, Yogyakarta, Indonesia

Managing Editor

Miranti Dewi Pramaningtyas, (Scopus ID: 57160319800), Faculty of Medicine, Universitas Islam Indonesia, Indonesia

Language Editors

Yuliana Yakobus, (Scopus ID: 55037276700), Department of Cardiothoracic Surgery, Universitätsklinikum Halle und Medizinische Fakultät, Halle, Germany

Bedy Qantha, Faculty of Medicine, Universitas Islam Indonesia, Yogyakarta, Indonesia

Razmaeda Sarastry, University College London, UK, Indonesia

Fahrurrazi Fahrurrazi, Indonesia

Reviewers

dr. Baiq Rohaslia Rhadiana, M.Sc, Faculty of Medicine, Universitas Islam Indonesia, Indonesia

dr. Eska Agustin Putri Susanti, Sp.KJ, Faculty of Medicine, Universitas Islam Indonesia, Indonesia

dr. Sani Rachman Soleman, Department of Public Health, Universitas Islam Indonesia, Indonesia

dr. Dian Kesumapramudya Nurputra Sp.A, M, Department of Child Health Faculty of Medicine, Universitas Gadjah Mada, Indonesia

Dr. dr. Sri Mulatsih, Sp.A(K), (Scopus ID: 36629131000) Department of Pediatrics, Faculty of Medicine, University Gadjah Mada, Yogyakarta, Indonesia

Rajesh Ramasamy, (Scopus ID: 26024442700), Department of Pathology, Faculty of Medicine and Health Sciences Universiti Putra Malaysia, Selangor, Malaysia

Dr. Hana Morrissey, (Scopus ID: 55323424400), School of Pharmacy, University of Wolverhampton, St. Wulfruna, United Kingdom

dr. Dito Anurogo, M.Sc, (Scopus ID: 57224408026) (1)Faculty of Medicine and Health, Universitas Muhammadiyah (Unismuh) Makassar, Indonesia (2)International Ph.D. Program for Cell Therapy and Regeneration Medicine (IPCTRM), College of Medicine, Taipei Medical University (TMU), Taiwan, Indonesia

Rasjid Soeparwata, (Scopus ID: 6602558276), Department of Surgery, Faculty of Medicine, Universitas Indonesia, Jakarta, Indonesia

Totok Utoro, (Scopus ID: 6506477162), Department of Histology and Cell Biology, Faculty of Medicine, Public Health, and Nursing, Universitas Gadjah Mada, Yogyakarta, Indonesia

Dr. Dwiwarso Rubiyanto, (Scopus ID: 56287098700), Department of Chemistry, Faculty of Mathematics and Natural Sciences, Universitas Islam Indonesia, Yogyakarta, Indonesia

Gunadi Gunadi, (Scopus ID: 24337866800), Department of Surgery, Faculty of Medicine, Public Health, and Nursing, Universitas Gadjah Mada, Yogyakarta, Indonesia

Lutfan Lazuardi, (Scopus ID: 6506658334), Department of Health Policy and Management, Faculty of Medicine, Public Health, and Nursing, Universitas Gadjah Mada, Yogyakarta, Indonesia

Deshinta Putri Mulya, (Scopus ID: 55185291600), Department of Internal Medicine, Faculty of Medicine, Universitas Gadjah Mada, Yogyakarta, Indonesia

Jarir Ath Thobari, (Scopus ID: 6503901953), Department of Pharmacology & Therapeutics, Faculty of Medicine, Public Health, and Nursing, Universitas Gadjah Mada, Yogyakarta, Indonesia

Supanji Supanji, (Scopus ID: 55710928300), Department of Ophthalmology, Faculty of Medicine, Public Health, and Nursing, Universitas Gadjah Mada, Yogyakarta, Indonesia

Tri Wibawa, (Scopus ID: 6507271804), Department of Clinical Microbiology, Faculty of Medicine, Public Health, and Nursing, Universitas Gadjah Mada, Yogyakarta, Indonesia

Syaefudin Ali Akhmad, (Scopus ID: 55735744200), Department of Biochemistry, Faculty of Medicine, Universitas Islam Indonesia, Yogyakarta, Indonesia

Dr. Farida Hayati, (Scopus ID: 57151056100), Department of Pharmacy, Universitas Islam Indonesia, Yogyakarta, Indonesia

Neni Trilusiana Rahmawati, (Scopus ID: 6504816137), Department of anatomy, Faculty of Medicine, Public Health, and Nursing, Universitas Gadjah Mada, Yogyakarta, Indonesia

Mae Sri Hartati Wahyuningsih, (Scopus ID: 56674527800), Department of Pharmacology & Therapeutics, Faculty of Medicine, Public Health, and Nursing, Universitas Gadjah Mada, Yogyakarta, Indonesia

Astri Ferdiana, (Scopus ID: 56268818700), Department of Health, Environment and Social Medicine, Faculty of Medicine, Public Health, and Nursing, Universitas Gadjah Mada, Yogyakarta, Indonesia

Sitti Rahmah Umniyati, (Scopus ID: 35096948300), Department of Parasitology, Faculty of Medicine, Public Health, and Nursing, Universitas Gadjah Mada, Yogyakarta, Indonesia

dr. Linda Rosita, M.Kes., Sp.PK, (Scopus ID: 57188827827), Departement of Pathology Clinic, Faculty of Medicine, Universitas Islam Indonesia, Yogyakarta, Indonesia

Barmawi Hisyam, (Scopus ID: 12778118700), Department of Internal Medicine, Faculty of Medicine, Universitas Islam Indonesia, Yogyakarta, Indonesia

Ismail Setyopranoto, (Scopus ID: 57038928800), Department of Neurology, Faculty of Medicine, Public Health, and Nursing, Universitas Gadjah Mada, Yogyakarta, Indonesia

Titis Nurmasitoh, (Scopus ID: 57200084103), Department of Physiology, Faculty of Medicine, Universitas Islam Indonesia, Yogyakarta, Indonesia

Farida Juliantina Rachmawati, (Scopus ID: 56505407000), Department of Microbiology, Faculty of Medicine, Universitas Islam Indonesia, Yogyakarta, Indonesia

Rusdi Lamsudin, (Scopus ID: 16734719500), Department of Neurology, Faculty of Medicine, Universitas Islam Indonesia, Yogyakarta, Indonesia

Isnatin Miladiyah, (Scopus ID: 57200500004), Department of Pharmacology, Faculty of Medicine, Universitas Islam Indonesia, Yogyakarta, Indonesia

Wahyudi Istiono, Department of Family Medicine, Community and Bioethics, Faculty of Medicine, Public Health, and Nursing, Universitas Gadjah Mada, Yogyakarta, Indonesia

Rul Afiah Syarif, Department of Pharmacology & Therapeutics, Faculty of Medicine, Public Health, and Nursing, Universitas Gadjah Mada, Yogyakarta, Indonesia

Ari Wibowo, Department of Pharmacy, Faculty of Mathematics and Natural Sciences, Universitas Islam Indonesia, Yogyakarta, Indonesia

Denny Agustiningih, Department of Physiology, Faculty of Medicine, Public Health, and Nursing, Universitas Gadjah Mada, Yogyakarta, Indonesia

Ngatijan Ngatijan, Department of Pharmacology & Therapeutics, Faculty of Medicine, Public Health, and Nursing, Universitas Gadjah Mada, Yogyakarta, Indonesia

Nur Aisyah Jamil, Department of Public Health, Faculty of Medicine, Universitas Islam Indonesia, Yogyakarta, Indonesia

Pariawan Lutfi Ghazali, Department of Public Health, Faculty of Medicine, Islamic University of Indonesia, Indonesia

Annisa Fitria, Department of Pharmacy, Faculty of Mathematics and Natural Sciences, Universitas Islam Indonesia, Yogyakarta, Indonesia

Yeny Dyah Cahyaningrum, Medical Education Unit, Faculty of Medicine, Universitas Islam Indonesia, Yogyakarta, Indonesia

Umatul Khoiriyah, Medical Education Unit, Faculty of Medicine, Universitas Islam Indonesia, Yogyakarta, Indonesia

Dr. dr. Andaru Dahesih Dewi, M.Kes, Sp.PK., Department of Clinical Pathology, Faculty of Medicine, Public Health, and Nursing, Universitas Gadjah Mada, Yogyakarta, Indonesia

Gandes Retno Rahayu, Department of Medical Education, Faculty of Medicine Universitas Gadjah Mada, Medical and Health Professional Education, Indonesia

Mahardika Agus Wijayanti, Department of Parasitology, Faculty of Medicine, Universitas Gadjah Mada, Yogyakarta, Indonesia

Dr. dr. Woro Rukmi Pratiwi, M.Kes., Sp.PD, Department of Pharmacology, Faculty of Medicine, Public Health, and Nursing, Universitas Gadjah Mada, Yogyakarta, Indonesia

Rita Cempaka, Department of Anatomical Pathology, Faculty of Medicine, Public Health, and Nursing, Universitas Gadjah Mada, Yogyakarta, Indonesia

Soewadi Soewadi, Department of Mental Health, Faculty of Medicine, Public Health, and Nursing, Universitas Gadjah Mada, Yogyakarta, Indonesia

Silas Henry Ismanto, Department of Mental Health, Faculty of Medicine, Public Health, and Nursing, Universitas Gadjah Mada, Yogyakarta, Indonesia

Wiryatun Lestariyana, Departemen of Biochemistry, Faculty of Medicine, Universitas Islam Indonesia, Yogyakarta, Indonesia

Titik Kuntari, Department of Public Health, Faculty of Medicine, Universitas Islam Indonesia, Yogyakarta, Indonesia

Ana Fauziyati, Department of Internal Medicine, Faculty of Medicine, Universitas Islam Indonesia, Yogyakarta, Indonesia

Evi Nurhayatun, Department of Internal Medicine, Faculty of Medicine, Sebelas Maret University (UNS), Indonesia, Indonesia

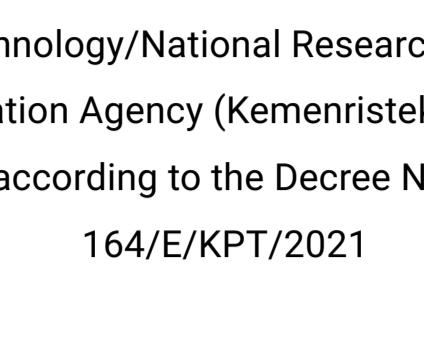
Technical Support

Muhammad Zainudin Al Amin, Faculty of Medicine, Universitas Islam Indonesia, Yogyakarta, Indonesia

Dinda Luki Tiara Isti, Faculty of Medicine, Universitas Islam Indonesia, Yogyakarta, Indonesia

Make Submission

ACCREDITATION



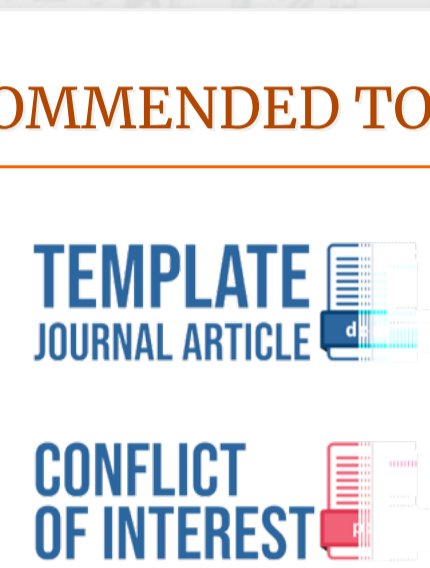This journal has been accredited by the National Journal Accreditation (ARJUNA) Managed by the Ministry of Research and Technology/National Research and Innovation Agency (Kemristek/BRIN), according to the Decree No. 164/E/KPT/2021

- Aims & scopes
Submission
Manuscript template
Publication ethics
Plagiarism
Article processing charges
Editorial team
Indexing
Statistics

Editorial Team

- Novyan Lusiyana, Editor in Chief
Miranti Dewi Pramaningtyas, Managing Editor
Asri Hendrawati, Associate Editor

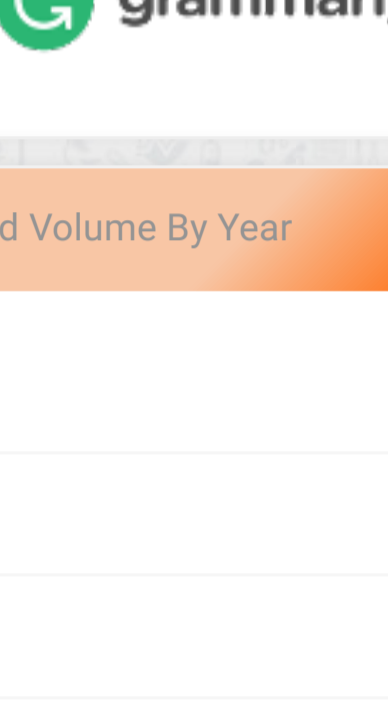
WEB STATISTICS



000015145

View My Stats

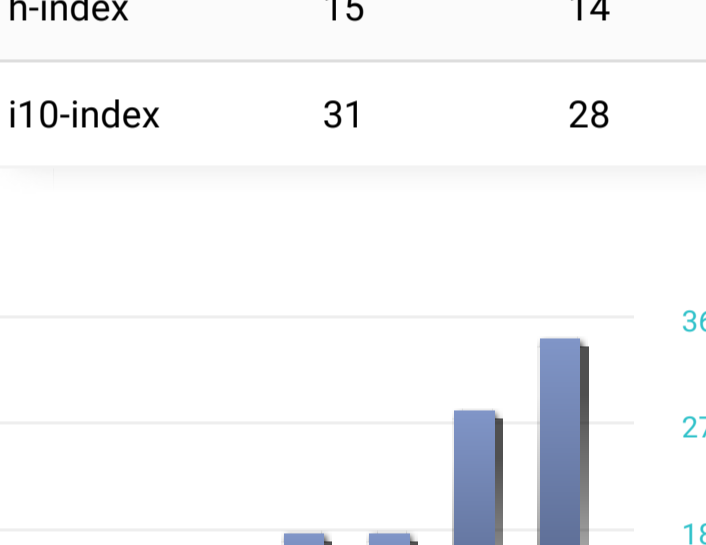
RECOMMENDED TOOLS



Published Volume By Year

Table with 2 columns: Year (2019-2023) and Volume count.

Keywords



Google Scholar Citation

Table with 2 columns: Metric (Citations, h-index, i10-index) and values for All and Since 2018.





JKKI : JURNAL KEDOKTERAN DAN KESEHATAN INDONESIA

UNIVERSITAS ISLAM INDONESIA

P-ISSN : 20854145 <> E-ISSN : 25272950 Subject Area : Health, Science



0.523
81

Impact Factor



1368

Google Citations

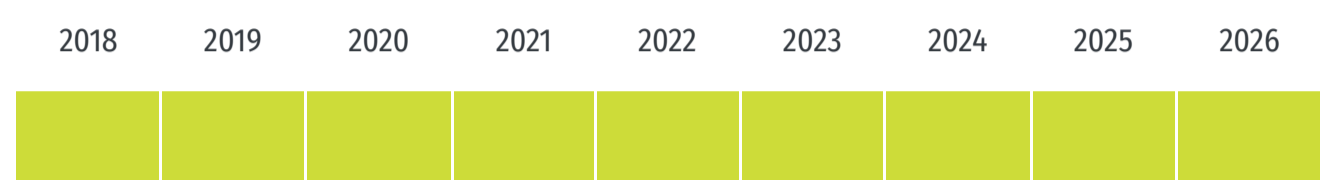

Sinta
2

Current Accreditation

- Google Scholar
- Garuda
- Website
- Editor URL

History Accreditation



Garuda Google Scholar

The Impact of the COVID-19 Pandemic on Services in the Department of Orthopaedics and Traumatology: A Systematic Review

Faculty of Medicine, Universitas Islam Indonesia [JKKI : Jurnal Kedokteran dan Kesehatan Indonesia JKKI, Vol 13, No 1, \(2022\)](#)

2022 DOI: - Accred : Sinta 2

RELATIONSHIP POLYMORPHISM EXON 17 OF RECEPTOR INSULIN (INSR) GENE WITH POLYCYSTIC OVARIAN SYNDROM IN MALAY ETHNIS SOUTH SUMATERA

Faculty of Medicine, Universitas Islam Indonesia [JKKI : Jurnal Kedokteran dan Kesehatan Indonesia JKKI, Vol 13, No 1, \(2022\)](#)

2022 DOI: - Accred : Sinta 2

The art of onconeuroepitrancriptomics

Faculty of Medicine, Universitas Islam Indonesia [JKKI : Jurnal Kedokteran dan Kesehatan Indonesia JKKI, Vol 13, No 1, \(2022\)](#)

2022 DOI: 10.20885/JKKI.Vol13.Iss1.art2 Accred : Sinta 2

PARENTING DURING THE COVID-19 PANDEMIC ERA: A LITERATURE REVIEW

Faculty of Medicine, Universitas Islam Indonesia [JKKI : Jurnal Kedokteran dan Kesehatan Indonesia JKKI, Vol 13, No 1, \(2022\)](#)

2022 DOI: - Accred : Sinta 2

Initial Screening of COVID-19 Patients with Diabetes Type-2 and Evaluation of Clinical Characteristics

Faculty of Medicine, Universitas Islam Indonesia [JKKI : Jurnal Kedokteran dan Kesehatan Indonesia JKKI, Vol 13, No 1, \(2022\)](#)

2022 DOI: - Accred : Sinta 2

URINARY TRACT STONES AND WELL WATER CONSUMPTION IN PATIENTS ATTENDING ZAENOEL ABIDIN HOSPITAL BANDA ACEH

Faculty of Medicine, Universitas Islam Indonesia [JKKI : Jurnal Kedokteran dan Kesehatan Indonesia JKKI, Vol 13, No 1, \(2022\)](#)

2022 DOI: - Accred : Sinta 2

Association between severity and locations of primary hyperhidrosis and quality of life among medical students

Faculty of Medicine, Universitas Islam Indonesia [JKKI : Jurnal Kedokteran dan Kesehatan Indonesia JKKI, Vol 13, No 1, \(2022\)](#)

2022 DOI: - Accred : Sinta 2

LATE LATENT SYPHILIS WITH EARLY SYPHILIS TITER IN PREGNANCY : A CASE REPORT

Faculty of Medicine, Universitas Islam Indonesia [JKKI : Jurnal Kedokteran dan Kesehatan Indonesia JKKI, Vol 13, No 1, \(2022\)](#)

2022 DOI: - Accred : Sinta 2

ANTIBACTERIAL ACTIVITY OF EXTRACT SANGKAREHO LEAVES (CALLICARPA LONGIFOLIA LAM.) ON SALMONELLA TYPHI AND STAPHYLOCOCCUS EPIDERMIDIS

Faculty of Medicine, Universitas Islam Indonesia [JKKI : Jurnal Kedokteran dan Kesehatan Indonesia JKKI, Vol 13, No 1, \(2022\)](#)

2022 DOI: - Accred : Sinta 2

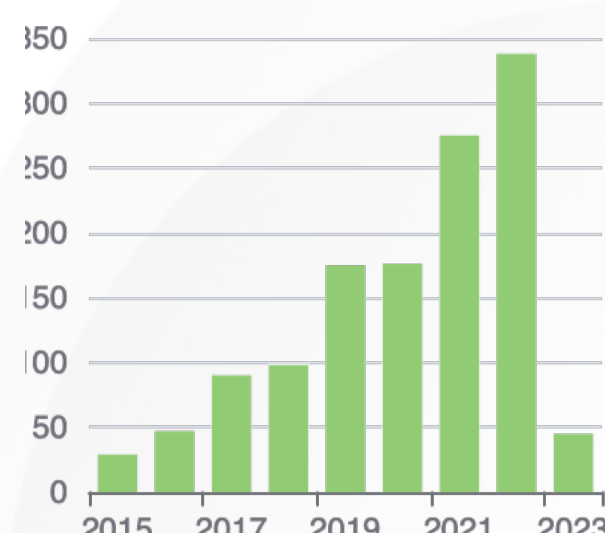
GENETIC FACTORS, OBESITY, LOW FIBER DIET, AND LACK OF PHYSICAL ACTIVITY INCREASE THE RISK OF PCOS

Faculty of Medicine, Universitas Islam Indonesia [JKKI : Jurnal Kedokteran dan Kesehatan Indonesia JKKI, Vol 13, No 1, \(2022\)](#)

2022 DOI: - Accred : Sinta 2

View more ...

Citation Per Year By Google Scholar



Journal By Google Scholar

	All	Since 2018
Citation	1368	1110
h-index	15	14
i10-index	31	28

Percutaneous retrieval of intracardiac fragmented hemodialysis catheter using a snare-loop catheter: A case report

Adhitya Ginting*¹, Ketut Putu Yasa², Yan Efrata Sembiring¹

¹Department of Thoracic, Cardiac and Vascular Surgery, Faculty of Medicine, Universitas Airlangga/ dr.Soetomo General Hospital, Surabaya, Indonesia

²Division of Thoracic, Cardiac, and Vascular Surgery, Department of Surgery, Faculty of Medicine, Universitas Udayana/ Sanglah General Hospital, Denpasar, Bali, Indonesia

Case Report

ABSTRACT

ARTICLE INFO

Keywords:

endovascular procedures,
intracardiac catheters,
equipment failure

*Corresponding author:

adhitya.ginting@gmail.com

DOI: 10.20885/JKKI.Vol11.Iss2.art14

History:

Received: December 31, 2019

Accepted: August 13, 2020

Online: August 31, 2020

Copyright ©2020 Authors.

This is an open access article distributed under the terms of the Creative Commons Attribution-NonCommercial 4.0 International Licence (<http://creativecommons.org/licenses/by-nc/4.0/>).

We presented a 60-year-old woman with an history of end-stage renal disease on regular hemodialysis, twice a week, came with a tunneled dialysis catheter (TDC) that was attached to the right internal jugular vein. TDC has been dysfunction since one week ago that was suspected as a result of thrombosis in the lumen of TDC. TDC was trimmed at the insertion of the jugular vein. And then a wire was inserted into TDC that has been trimmed. From Chest x-ray imaging, migration of fragmented TDC was found inside the heart chamber with wire inside the lumen. Fluoroscopy showed a picture of a fragmented TDC in the heart chamber with a wire inside the lumen. Retrieval of fragmented TDC used percutaneous snare loop method with wire guiding that was inserted through the left femoral vein. Fragmented TDC was removed successfully. Retrieval of the fragmented TDC through endovascular techniques is classified as a simple. Simple snare loop method is quite effective and very cheap compared to the commercial snare, open surgery or laparoscopic surgery that can be avoided.

Kami melaporkan seorang wanita 60 tahun dengan riwayat penyakit saat ini adalah gagal ginjal kronik dengan hemodialisa reguler dua kali seminggu. TDC terpasang di vena jugularis interna kanan. TDC mengalami disfungsi sejak 1 minggu lalu, dicurigai akibat dari trombosis yang terbentuk di dalam lumen kateter hemodialisa.

TDC kemudian digunting sebagian pada insersi vena jugular dan wire dimasukkan ke dalam kateter hemodialisa tersebut. Dari pencitraan X-ray didapatkan migrasi bagian kateter hemodialisa berada di dalam ruang jantung dengan wire di dalam lumen kateter hemodialisa. Fluoroskopi menunjukkan gambaran sebagian kateter hemodialisa berada di ruang jantung dengan wire terpasang di dalam potongan lumen kateter hemodialisa. Ekstraksi sebagian kateter hemodialisa dilakukan menggunakan metode loop snare dengan akses guiding wire yang dimasukkan melalui vena femoralis kiri. Fragmen kateter kemudian berhasil dikeluarkan. Pengambilan fragmen melalui endovaskular tergolong teknik yang sederhana. Loop snare yang sederhana sudah cukup efektif dan murah dibanding komersial snare, sehingga pembedahan terbuka ataupun laparoskopik dapat dihindari.

INTRODUCTION

Hemodialysis requires access to the patient's blood vessels. Access to these vessels can be

done through surgery or special procedures that can be performed by specialists. There are three common types of vascular access,

they are Arterio-venous fistula (AV fistula), Arterio-venous graft (AV graft), and central venous catheter (also known as hemodialysis catheter). In this study, we will discuss about hemodialysis catheters and their complications. Hemodialysis catheter is a man-made flexible tube that is usually inserted into a large vein in the chest. Hemodialysis catheters can be inserted into a vein in the neck or in the groin. Every hemodialysis catheter has two holes called ports. One of the ports drain blood from the body that be cleaned through a dialysis machine and then the clean blood is returned to the body through the other ports. The place where the catheter enters the skin is also called the exit site.¹

Hemodialysis catheter is a temporary hemodialysis access while waiting for AV fistula or AV graft surgery. Hemodialysis catheter is also used as an option if AV fistula or AV graft cannot be done. Hemodialysis catheter is inserted by the surgeon with ultrasound guiding or X-ray imaging in the operating room. Hemodialysis catheter can be used immediately after being inserted into a vein. The risk of infection increases in the area where hemodialysis catheter is attached both at the entrance to the body and in the bloodstream. In addition, there can be damage to the vein where the hemodialysis catheter is inserted. Hemodialysis catheter is inserted with the help of ultrasound so that they can be installed properly. The anesthetic use local anesthetic techniques.¹

In general, the most preferred blood vessel access is AV fistula, because of the high average blood flow that can be achieved, and the low risk of infection problems and thrombosis. In addition, AV graft is the preferred blood vessel access, because the average blood flow that can be achieved is similar to the AV fistula. Hemodialysis catheter is blood vessel access last choice for hemodialysis because it can cause non-infectious complications which will be discussed later and compile infection, except for the initiation of hemodialysis while awaiting surgery. Tunneled Dialysis Catheter (TDC) is associated with higher rates of complications, morbidity and mortality

compared to AV fistula or AV graft, and these complication are high costs of management.^{2,3}

The most common non-infectious complication of TDC is hemodialysis catheter dysfunction. According to The National Kidney Foundation (NKF/DOQI) guidelines, hemodialysis catheter dysfunction is defined if extracorporeal blood flow cannot reach 300 ml/min, with arterial pressure before pumping is less than negative 250 mmHg. The most common cause is thrombosis either inside or outside of the hemodialysis catheter lumen. Complication from the removal of hemodialysis catheters can also occur because the adhesion process in the cuff is not adequately formed.²

The rarest complication is migration of fragmented hemodialysis catheter into the heart. This can be caused by a fragile hemodialysis catheter tip or because a fragmented catheter is released into the heart during the replacement process from hemodialysis catheter.²

CASE DESCRIPTION

Our patient was a 60-year-old woman complaining about her TDC dysfunction since one week ago. She has history of end-stage renal disease on regular hemodialysis, twice a week, came with TDC that was attached to the right internal jugular vein about six months. Consent was taken from her legal guardian.

The patient came by herself to our hospital because of TDC dysfunction during hemodialysis. The patient was asymptomatic. Physical examination showed a body temperature of 37.5°C, TDC has been dysfunctional since 1 week ago because at that time, the extracorporeal blood flow hemodialysis was less than 300 ml/min. Laboratory tests showed ureum 45 mg/dl, creatinine 14 mg/dl, and potassium 5 meq/liter. The patient was planned for a replacing of the TDC with a temporary hemodialysis catheter in the operating room under local anesthesia.

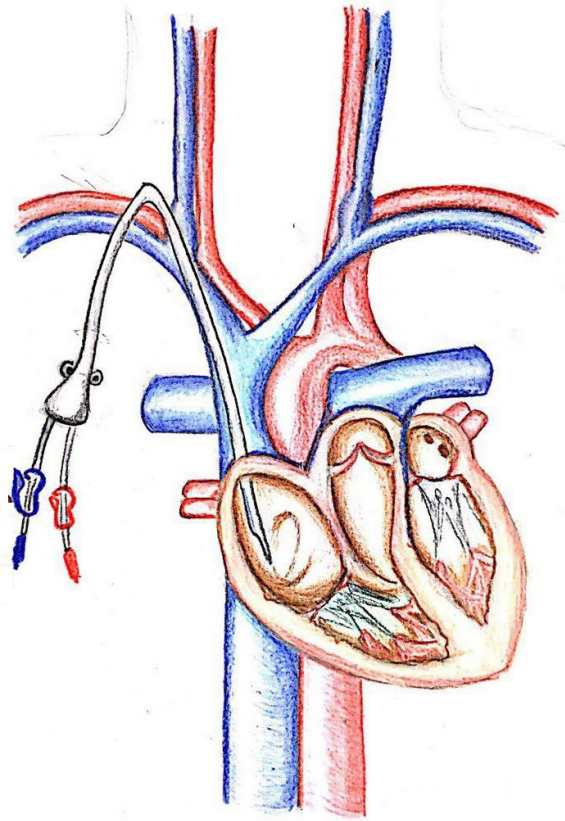


Figure 1. Tunneled Dialysis Catheter (TDC) inserted into central vein.²

Patient was taken to the operating theater with stable blood pressure was 150/90 mmHg, heart rate was 98 times per minute, respiratory rate was 22 times per minute, oxygen saturation was 99% without O₂ support. ECG monitoring was installed on patient. Disinfection of the operating area used povidone iodine and alcohol. Then, draping of the patient used sterile ducts. TDC could not be aspirated using a 10cc syringe. This was suspected as a result of thrombosis that forms in the TDC lumen. TDC was trimmed at the insertion area (in the jugular vein). Wire was inserted into the fragmented TDC which has been trimmed, because the fragmented TDC was not good, then the fragmented TDC was aspirated

into the blood vessels. Wire was retained, and then the patient was carried out on imaging using X-ray with a mobile C-Arm system. X-ray imaging revealed migration of the fragmented TDC inside the cardiac chamber with a wire in the lumen of the fragmented TDC (Figure 2 and 3). The procedure was stopped and the patient was planned for an extraction of the fragmented TDC in the hybrid operating theater. The condition of patient was stable with blood pressure was 140/90 mmHg, heart rate was 92 times per minute, respiratory rate was 20 times per minute, and oxygen saturation was 99% saturation without hemodynamic support.

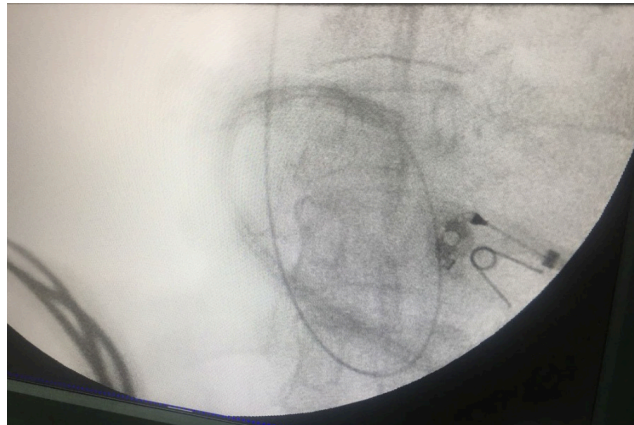

Figure 2. Fragmented TDC showed in Mobile C-arm X-ray

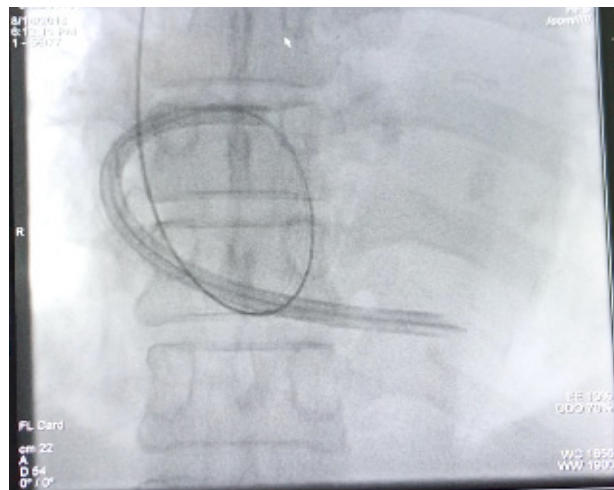


Figure 3. Fluoroscopy imaging showed fragmented TDC in heart chamber using the Mobile C-arm X-ray

The patient was prepared entering the hybrid operating theater for extraction of fragmented TDC. Once ready, the patient was brought into the hybrid operating theater with stable blood pressure was 140/90 mmHg, heart rate was 90 times per minute, respiratory rate was 20 times per minute, and the oxygen saturation was 99% without hemodynamic support. ECG monitoring were installed on the patient. Disinfection of the operating area used povidone iodine and alcohol and then draping used sterile ducts. Fluoroscopy showed a picture of a fragmented TDC in the heart chamber with a wire attached to the lumen of the fragmented TDC (Figure 3).

From fluoroscopy, the patient needed

extraction of the fragmented TDC using the snare loop method (Figure 4) with wire guiding through the left femoral vein. After 11 Fr sheath was inserted to the left femoral vein, the guiding wire was inserted into the femoral vein until they reached the fragmented TDC. Then a snare loop was inserted until it bound to the fragmented TDC and then the snare loop was locked. The snare loop was pulled slowly until it approached the left femoral vein. Fragmented TDC were extracted through an incision in the left femoral vein and then the incision area was covered layer by layer, the skin was covered by simple continuous suture.

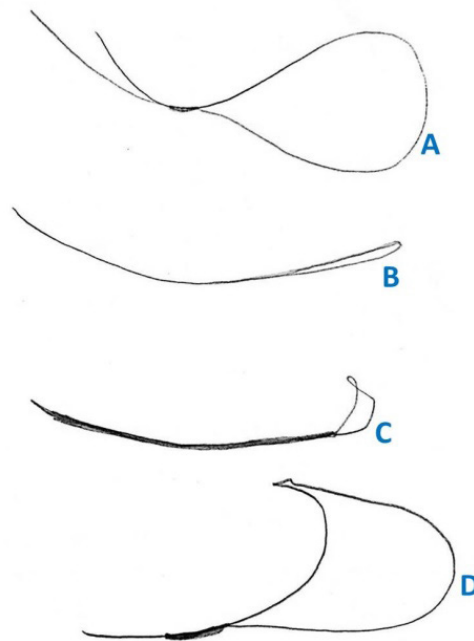


Figure 4. Four type of snare loops. From above, (A) a simple snare loop is made with a 5-F, 0.038-inch Cobra 2 catheter endhole and an 18-inch, 180-cm-long guidewire. (B) Snare loop originates from the endoscopic set. (C) Cook Medical (Bloomington, IN) IVC retrieval filter set. (D) The last snare is the same snare loop as the first snare loop, only the apex of the guidewire loop is made kinking using forceps.⁴

After the procedure, we evaluated the fragmented TDC, that entered the patient's heart, was completely removed. There was no remaining fragmented TDC from the evaluation via fluoroscopy during the operation. After the operation, the patient was monitored in the ICU. The electrocardiogram and the physical examination were normal. There were not any major or minor complications such as arrhythmia, bleeding, vascular or cardiac perforation, or local hematoma. Two weeks after the patient discharged, the patient came to the outpatient and had no complaints.

DISCUSSION

The main complications of TDC are infection, occlusion, and mechanical.⁵ The infection consists of bacteremia and sepsis. The occlusion consists

of either thrombosis or stenosis of the vein. Mechanical complications consist of bleeding due to previous puncture of blood vessels, pneumothorax, and very rarely is the migration of the catheter into the heart chamber.⁶

Using hemodialysis catheters in proper is very important because it can reduce the likelihood of complications. Repair of catheter dysfunction is preferred rather than try to replace the hemodialysis catheter and re-inserting in a different place. The causes of hemodialysis catheter dysfunction are fibrin formation in the lumen of the hemodialysis catheter, a curved catheter or malposition catheter, and acute or chronic thrombosis. Central venous stenosis resulting from an endothelial injury associated with central venous catheter placement. It can be decreased AV fistula flow or AV graft flow in

the extremities. It is usually asymptomatic, but clinical symptoms can occur when it becomes getting more flow than it should, especially from AV fistula or AV graft. The risk factor is a long duration when inserting the catheter.⁶

Fibrin in the lumen of the hemodialysis catheter can be removed when the guiding wire was inserted during the replacement procedure or using balloon angioplasty. In the case of acute thrombosis, thrombolytic agent or thrombectomy can be used to retaining the patency, even with slight risk of bleeding during the procedure. Endovascular interventions such as percutaneous angioplasty are the best choice in the management of chronic central venous stenosis.⁶

TDC is associated with infectious and non-infectious complications. It would increased morbidity and mortality of patient.⁷ These complications can occur right after inserting or can occur slowly during TDC usage.⁸ Thrombus can form in the lumen of hemodialysis catheters, which can lead to tissue complications such as pulmonary embolism, septic embolism, central venous stenosis, and cardiac arrhythmias. Optimal management of thrombus in the hemodialysis catheter lumen is still being debated. When a thrombus in a hemodialysis catheter is detected, patients are usually given anticoagulant therapy, using INR with the same target as patients with deep vein thrombosis for three months. Mostly, TDC is not removed (unless it is no longer needed). The duration of anticoagulation can vary depending on the severity of thrombosis, the risk of bleeding, and the need for using a hemodialysis catheter.⁹

Thrombus in the right atrium associated with a hemodialysis catheter is a serious complication, related to an average mortality rate of around 18%. In a systematic review, about 71 reported cases has thrombus in the right atrium associated with a hemodialysis catheter; the authors recommend for removal of a hemodialysis catheter and using anticoagulation if the thrombus is less than 6 cm. If patients have contraindications to anticoagulants (thrombus greater than 6 cm or abnormalities of the heart),

thrombectomy can be considered.^{9,10}

Although the effort to make AV fistulas in hemodialysis patients increase, the prevalence of tunneled hemodialysis catheters remains high (National Vascular Access Initiative, Fistula First). In the United States, the use of TDC was 62.3% in hemodialysis patients in 2006. Infection associated with catheter placement and central venous stenosis is a common complication of TDC that makes them unfavorable compared to AV fistula and AV graft. Therefore TDC is only used while waiting for vascular access surgery or kidney transplantation. However, there are groups of patients who use TDC as long-term hemodialysis access because these patients have not a vascular access site remaining, poor vascular access for hemodialysis, or refusing to make vascular access. In these patients, unusual complications associated with the use of TDC may occur, for example, migration of TDC fragment into the heart.¹¹

Chawla reviewed and proved that the interruption of TDC causing migration to the heart was very rare unless deliberately cut during the procedure to replace the TDC. A severed catheter tip can settle in the right heart chamber, vena cava or migrate to the pulmonary artery and its branches depending on its size and weight.¹² Potential complications that can occur are perforation of the heart, valves, and blood vessels including the formation of thrombus and the phenomenon of embolism due to fragments that are cut off. Catheter fragments can be seen using X-ray. An echocardiogram or CT scan may be needed if fragments are not visible between the shadows of the heart.^{11,13}

Taking a fragmented TDC that migrates depends on how long the fragment in the heart (the longer the likelihood of adhesions), there are risk factors for complications, and the site of the cut is located. Cutting is required if the fragment is in the right heart space and the proximal branches of the pulmonary artery due to complications that can occur there (infection, perforation, thrombosis, and arrhythmias). These complications can occur within a year, mostly within a month, and rarely within 2 years.

Nellore and Trerotola described an unusual case of migrating fragments from the left to the pulmonary artery after 2 years of release. In his review of catheter embolism, Richardson noted that the highest mortality occurred in emboli in the right heart. Extracting fragments is needed either through percutaneous or through surgery. However, not all fragment embolization needs to be removed. If the fragment cannot be percutaneously removed because it is localized in a very distal place or has been present for a long time without symptoms and the patient decides not to operate (or surgery is contraindicated because of too high a risk of morbidity and mortality at that location), then the patient must be monitored closely strict. Prophylaxis of endocarditis and low-dose warfarin (1 mg/day) for at least 2 years (or low-dose aspirin) are highly recommended in such cases. High vigilance is needed in these patients because fragments that have long been able to migrate and cause complications.^{11,13}

Every endovascular specialist will be confronted with a problem of a malfunctioning, interrupted, or migrating device that requires retrieval. The cause of migration from the catheter is very numerous, in this case, a fragmented TDC migrates into the cardiac chamber. The method for retrieval of fragments is various, in this case, we used the loop snare method.^{4,14}

Snare and graspers for extracting fragments are widely sold in the market. However, it is easy to make a snare loop with standard 5-F and 180-cm, 0.018-inch guide wire angiographic catheters (Figure 4). Mallmann has reported success using this snare loop up to 100%. The advantage of this type of snare loop are many size choices for this loop and the cost is not expensive. If the end of this loop is made kinking using forceps, this snare can be directed to the desired side.^{4,14}

In almost all cases, it is possible to extract fragments without the need for surgery. In some cases, a large or stiff fragment can be taken and taken to a more superficial site where simple surgery with local anesthesia can be performed. The best time to extract fragments is just after the incident. A fragment becomes an alien corpus

in the patient's body which can be a source of complications in the patient. Deciding which steps to take depends on what fragments will be taken, the position of the instrument system used, the approach to the fragment, and the process of bringing the fragment out through the safest and most easily accessible exit points. The loop snare used is a modified loop snare (Figure 5). In this case, the operator uses the endovascular loop snare technique (Figures 6 and 7).

Retrieval of intravascular or intracardiac of tunneled double lumen catheter fragment has various techniques. In the 2019, the retrieval of the fragment of the catheter procedure was performed by Semadi. The procedure was performed under general anaesthesia and C-Arm guidance. About 7 cm Golf stick incision was made at the right Sedillot's triangle. The incision was done until the internal jugular vein was exposed. Purse string was made around prior incision with 4-0 non-absorbable monofilament suture. Under C-arm guidance, a mixer right angle clamp was inserted to retrieve the distal tip of dislodging double lumen catheter. The fragment of the catheter can be retrieved smoothly.¹⁵ No techniques have been recommended for retrieval procedure up until now in this case. The technique that will be used depends on the type and location of the hemodialysis catheter; it also depends on the experience of the operator.

In our case, the patient comorbid was end-stage renal disease, so the patient needed a hemodialysis catheter for regular hemodialysis. But there are no any comorbid directly related to the procedure. Based on the location of the fragment of the catheter, the most likely complication is cardiac arrhythmia. Meanwhile, the complication for retrieval of intravascular or intracardiac of tunneled double lumen catheter fragment is the injury to the blood vessels so that thrombosis and bleeding can occur.

Our study has limitations. It is a single study, observational, and non-comparative study. This case is still rare. If there is another study found, it is better to use a case series or comparative study. The management of this case

remains a challenge, endovascular specialists who experience a similar case can apply this procedure and it must be done by a competent doctor. Intracardiac or intravascular foreign body

is a dangerous situation, but it could be managed early by knowing the exact site of the foreign body using a chest radiograph.

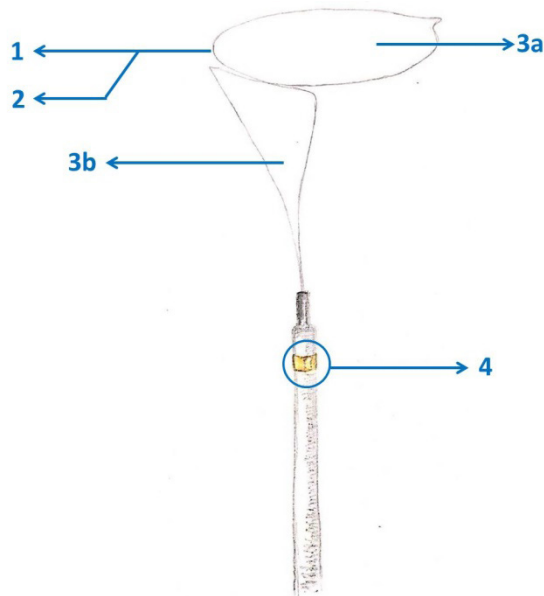


Figure 5. The modified loop snare parts. (1) variable diameter loop, (2) radioopaque loop, (3a) first plane, (3b) second plane, (4) gold marker.¹⁶

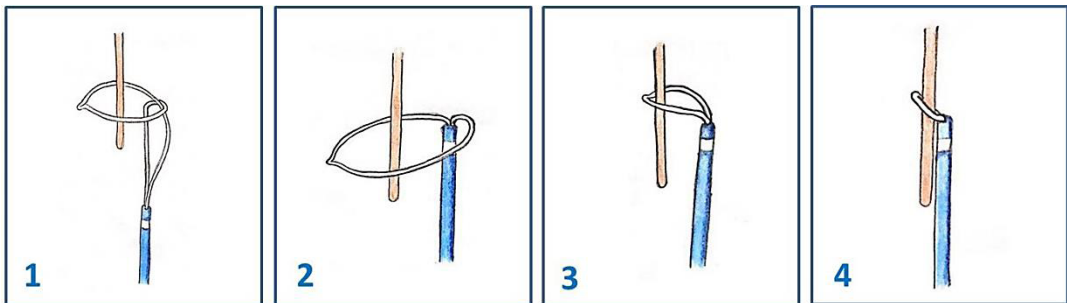


Figure 6. Endovascular loop snare technique uses first plane.¹⁶

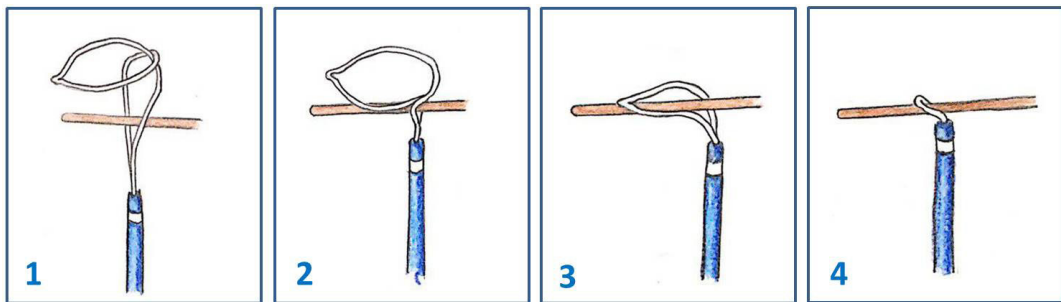


Figure 7. Endovascular loop snare technique uses the second plane.¹⁶

CONCLUSION

In conclusion, if there is a fragmented TDC, it is necessary to identify the location of the fragment using X-ray, fluoroscopy, or CT scan. After informing the patient, the fragments can be taken using snare especially in high-risk patients (patients at risk of endocarditis and fragments that are in the right heart and proximal to the pulmonary artery).

Retrieving fragments through endovascular techniques is simple, and there are many kinds of instruments for this purpose. Almost in all situations, a simple snare loop is quite effective and the cost is very cheap compared to commercial snare. Open surgery can be avoided but it depend on the cases.

CONFLICT OF INTEREST

The Authors have none to declare.

ACKNOWLEDGEMENTS

The Authors have none to declare.

REFERENCES

1. Barret B. Some facts about central venous catheters (hemodialysis catheters). *Yhe Kidney Fund Canada*. 2010;(February 2010):1-3.
2. Banerjee S. Dialysis catheters and their common complications: An update. *ScientificWorldJournal*. 2010;9:1294-9.
3. Zhu LN, Mou LJ, Ying-Hu LJ, Wei GN, Sun JF. Failure to place a tunneled hemodialysis catheter due to malformation of right internal jugular vein draining to subclavian vein. *Journal of International Medical Research*. 2018;46(6):2481-5.
4. Thompson K. Non-surgical retrieval of devices and foreign bodies. *Endovascular Today*. 2010;(July):29-32.
5. Adeel Ebad C, Davitt S, Gnanasekaran R, Khan A, Moran AM. Application of Hong's technique for removal of stuck hemodialysis tunneled catheter to pacemaker leads. *Radiology Case Reports*. 2017;12(1):97-101.
6. Pereira K, Osiason A, Salsamendi J. Vascular access for placement of tunneled dialysis catheters for hemodialysis: A Systematic approach and clinical practice algorithm. *Journal of Clinical Imaging Science*. 2015;5(1):1-12.
7. Hong JH. An easy technique for the removal of a hemodialysis catheter stuck in central veins. *Journal of Vascular Access*. 2010;11(1):59-62.
8. Forneris G, Savio D, Quaretti P, Fiorina I, Cecere P, Pozzato M, et al. Dealing with stuck hemodialysis catheter: State of the art and tips for the nephrologist. *Journal of Nephrology*. 2014;27(6):619-25.
9. Miller LM, MacRae JM, Kiaii M, Clark E, Dipchand C, Kappel J, et al. Hemodialysis tunneled catheter noninfectious complications. *Canadian Journal of Kidney Health and Disease*. 2016;3(1).
10. Wang L, Wei F, Jiang A, Chen H, Sun G, Bi X. Longer duration of catheter patency, but similar infection rates with internal jugular vein versus iliac vein tunneled cuffed hemodialysis catheters: A single-center retrospective analysis. *International Urology and Nephrology*. 2015;47(10):1727-34.
11. Sequeira A, Sachdeva B, Abreo K. Uncommon complications of long-term hemodialysis catheters: Adhesion, migration, and perforation by the catheter tip. *Seminars in Dialysis*. 2010;23(1):100-4.
12. Hong JH. A breakthrough technique for the removal of a hemodialysis catheter stuck in the central vein: Endoluminal balloon dilatation of the stuck catheter. *Journal of Vascular Access*. 2011;12(4):381-4.
13. Zhou L, Yu S, Gou S, Shi M, Cui T, Fu P. Removing the incarcerated tunneled cuffed venous catheters: An experience from a single center. *Blood Purification*. 2018;46(3):246-7.
14. Amoretti N, Hauger O, Marcy PY, Hovorka I, Lesbats-Jacquot V, Fonquerne ME, et al. Foreign body extraction from soft tissue by using CT and fluoroscopic guidance: A new technique. *European Radiology*. 2010;20(1):190-2.
15. Semadi IN, Koerniawan HS, Irawan H. Retrieval of intravascular fractured fragment of tunnelled double lumen catheter.

- ter in hemodialysis patient. Open Access Macedonian Journal of Medical Sciences. 2019;7(1):124–6.
16. Micro M. objects from any angle . Three different types in various sizes make our snare the ideal interventional solution for use in middle-sized to large vessels (Multi-Snare ®), in distal smaller vessels (Multi-Snare ® Micro) and for supporting the implan. Multi-Snare®. 2015. <http://www.pfmmedical.com>