

PNEUMOMEDIASTINUM

by Paul L Tahalele

Submission date: 10-Apr-2023 09:21PM (UTC+0800)

Submission ID: 2060535105

File name: PNEUMOMEDIASTINUM.pdf (1.1M)

Word count: 1663

Character count: 9202

PNEUMOMEDIASTINUM*

Paul L Tahalele¹⁾, Merlinda Dwintasari¹⁾, Y Motulo²⁾, Yan Efrata Sembiring³⁾,
Dihintia Jiwangga Suta³⁾

ABSTRACT

Mediastinum is defined as the area demarcated by the thoracic inlet superiorly, the diaphragm inferiorly, and the pleural cavities laterally. The mediastinum is a division of the thoracic cavity that contains thymus gland, the heart, trachea and portions of the esophagus, and other structures. Mediastinum divided into 3 region, anterior, posterior, superior, and middle regions.

Pneumomediastinum or emphysematous mediastinum is existence of free air in the mediastinum due to spontaneous or secondary reasons. That can be confirmed with thorax X-Ray or CT- Scan thorax. The symptoms are severe central chest pain, shortness of breath, subcutaneous emphysema, laboured breathing and voice distortion. In physical diagnosis, especially on auscultation, there is spesific sign called "Hamman's Crunch" (crunching sound corresponding with the cardiac cycle (Hamman's Crunch)).

Pneumomediastinum can lead to pneumopericardium, pneumotoraks, pneumoretroperitonium or pneumoperitonium. Air in the mediastinal cavity can be absorbed by itself slowly, so pneumomediastinum can treated non-operatively.

Keywords : Mediastinum, Pneumomediastinum, Treated Conservatively

1) Department of Surgery Faculty of Medicine, Widya Mandala Catholic University Surabaya Indonesia, 2) Division of Thoracic, Cardiac & Vascular-Endovascular, PHC Teaching Hospital Surabaya Indonesia, 3) Department of Thoracic, Cardiac, & Vascular Surgery, Faculty of Medicine Universitas Airlangga Surabaya Indonesia

INTRODUCTION

Pneumomediastinum or emphysematous mediastinum is existence of free air in the mediastinum due to spontaneous or secondary reasons.^{3,5,11} Pneumomediastinum diagnosed in 1/100.000 of natural births, more frequent

in children (1/800-1/15.500) or 1/44.500 of accident. Incidence in ages between 5-34 years is 1/25.000 and 76% of cases are males.²

Pneumomediastinum can caused spontaneously or traumatically. Spontaneous pneumomediastinum is the

5 presence of air into the mediastinum without an obvious causative factor like an operation, presence of infection, trauma, or air following a viscous perforation. When a causative factor is identified, this condition known as secondary pneumomediastinum.^{1,11,12}

6 Usual including factor include asthma, Chronic Obstructive Pulmonary Disease(COPD), interstitial lung disease, bronchiectasis, lung cysts or lung malignancy, trauma, and excessive vomiting. The use of recreational drugs, like cocaine, marijuana, methamphetamine can cause penumo mediastinum.^{10,15}

CAUSE OF PNEUMOMEDIASTINUM

Pneumomediastinum can be caused due to an abnormal increase in pressure in the pneumomediastinum. Pressure on pleural cavity becomes low and negative, so the air is trapped in mediastinal structure.⁴

3 Gas can enter to mediastinal cavity from rupture of alveoli, from rupture of the gastrointestinal tract or the tracheobronchial tree, or from extraluminal gas into the toraks from the chest wall, neck, or retroperitoneum.^{3,5,6}

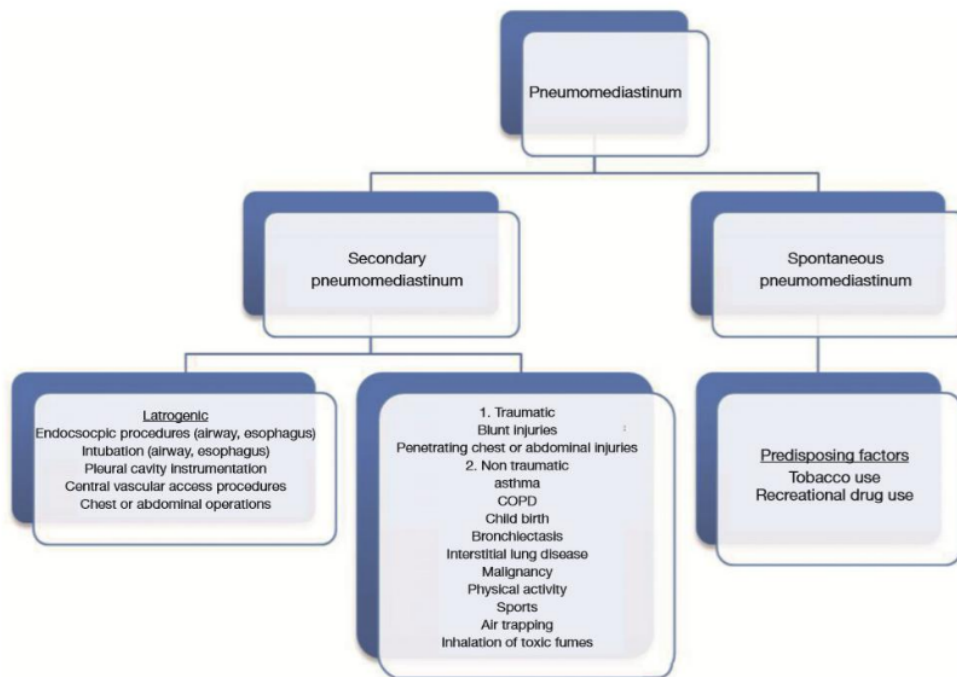


Figure 1. Pneumo mediastinum Etiology (Adopted From Koaritas VK)¹

Table 1. Cause of Pneumomediastinum (Adopted From Bejvan SM)

Cause	Underlying Condition	Source of Underlying Condition
Alveolar rupture associated with elevated alveolar pressure	Airway obstruction	Asthma; foreign body; acute obstructive laryngitis; congenital stenosis
	Mechanical ventilation	General anesthesia; positive end-expiration pressure
	Thoracic trauma	Blunt trauma; penetrating trauma (e.g., from rib fracture with pulmonary laceration or from lung biopsy)
	Deep respiratory maneuvers	Strenuous activity; vital-capacity maneuvers; acidosis (Kussmaul respiration)
	Valsalva maneuver	Weight lifting; Heimlich maneuver; defecation; parturition; inhalation of nitrous oxide, marijuana, or cocaine
	Vomiting	Diabetic ketoacidosis; anorexia nervosa
	Change in atmospheric pressure	Caisson disease; rapid change in altitude
Alveolar rupture associated with alveolar disease	Infection	Bacteria; viruses (measles, influenza, smallpox, chickenpox); mycobacteria (tuberculosis); lung abscess
	Aspiration	
	Adult respiratory distress syndrome	
	Emphysema	
Tracheobronchial injury	Interstitial lung disease	Sarcoidosis; silicosis
	Trauma	
Esophageal perforation	Instrumentation	Bronchoscopic biopsy
	Tracheal or bronchial neoplasm	
	Vomiting	
Head and neck injury or surgery	Iatrogenic injury	
	Trauma (penetrating)	
	Neoplasm	
	Perforation of nasopharynx	Traumatic intubation
Abdominal or retroperitoneal injury or surgery	Facial fractures or surgery	
	Dental procedures	
	Neck surgery	Thyroid surgery; tonsil surgery; tracheostomy
	Bowel perforation	
	Diverticulitis	
	Hernia	
	Ulcer	
	Trauma	
	Rectosigmoid surgery	

CLINICAL PRESENTATION

The main symptom of pneumomediastinum is chest pain, spread into the neck or the back. Other symptoms are coughing spells, dyspnea, neck pain, dysphagia or emesis. Subcutaneous emphysema can be detected in 70% cases. Other sign are rhinolalia (nasally sounding voice), neck swelling and hoarseness.^{11,20}

Clinical evaluation may identify tachycardia, tachypnea or anxiety. Spesific sign can be found in physical examination, there was click present or mediastinal crunch in left sternal border and apex same with heart beat on auscultation, known as the Hamman's Sign.^{7, 11, 19}

DIAGNOSIS

Chest X-Ray can showing lucent streaks, visible mediastinal pleura, and bubbles of air outlining mediastinal structure. Chest CT Scan can be used for confirm the chest X-ray, and it is important to differentiate between pneumopericardium and pneumomediastinum. Bronchoscopy or esophagoscopy are not routinely required. Ultrasound of the mediastinum can be done in emergency room to identify pneumomediastinum.^{6,8,11}

There are the other sign (on X-ray or CT-Scan), such as ring sign (air surrounding the pulmonary artery), thymic

sail (because of air, the thymus elevated), continuous diaphragm sign, double bronchial wall, or air adjacent to spine or hemidiaphragm.^{16,17} In laboratory there

was leukocytosis or elevated C-Reactive protein. Sometimes, an abnormal ECG can be found.^{11,17}

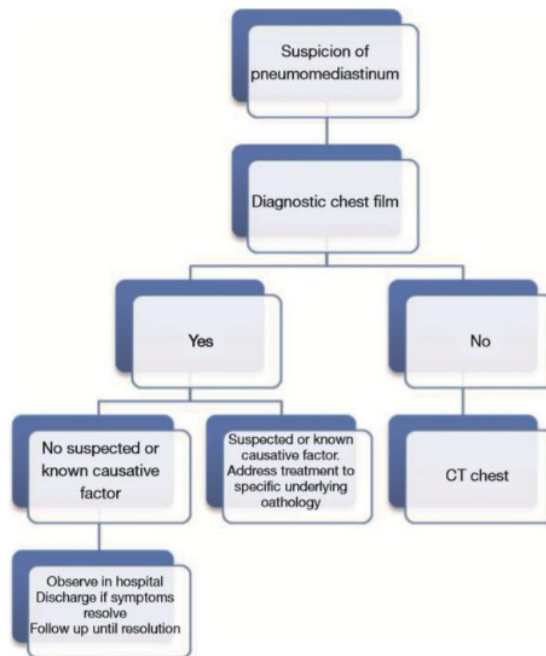


Figure 2. Diagnosis for Pneumomediastinum(Adopted From Koaritas VK)¹¹

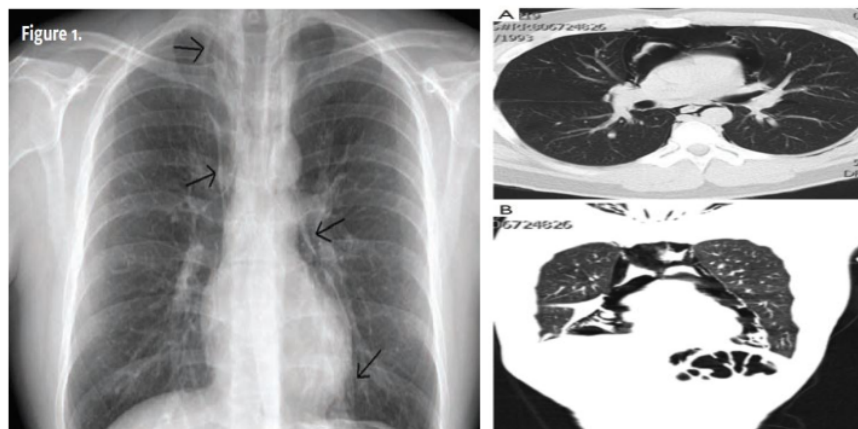


Figure 3. Pneumomediastinum: Mediastinal air throughout the medial border of the descending aorta (Adopted From Koaritas VK)¹¹

MANAGEMENT

Air in the mediastinal cavity can be absorbed by itself slowly, so pneumomediastinum can be treated non-operatively. Patient must be hospitalized for a minimum of 24 hours observation. Pain can be controlled with analgesics. Anti-anxiety drug can also be administered. Antitussives for cough and administration of oxygen can increase gas absorption. In some other cases that require decompression, VATS or thoracotomy can be done.^{11,13,18}

COMPLICATION

The complications of pneumomediastinum are pneumothorax (air passes the pleura or peritoneum resulting in pneumoperitoneum), subcutaneous emphysema (the air penetrates to the skin, neck, or upper abdomen via the loose alveolar fat tissue). This condition usually requires minor intervention, like chest tube drainage and skin incision.^{2,9,14}

Table 2. Pneumomediastinum versus Pneumothorax (Adopted From Bejvan SM)³

Feature	Characteristic	
	Pneumomediastinum	Pneumothorax
Configuration of gas	Multiple thin, lucent streaks; can be confused with pneumothorax when streaks extend along diaphragm, over lung apex, or behind sternum	Apical lucency (upright); medial basal lucency (supine); deep-sulcus sign (supine)
Distribution	Outlines mediastinal structures (pulmonary artery, aorta, esophagus, and airway)	Never outlines mediastinal structures; anteromedial (supine); apical (upright)
Change in distribution with change in patient position?	No	Yes

Table 3. Pneumomediastinum versus Pneumopericardium (Adopted From Bejvan SM)³

Feature	Characteristic	
	Pneumomediastinum	Pneumopericardium
Configuration of gas	Multiple thin, lucent streaks	Broad band; halo sign (gas surrounding heart)
Distribution ^a	Outlines mediastinal structures, including aortic arch, trachea, and bronchi; commonly extends into neck	Because limited to pericardium, outlines ascending aorta and main pulmonary artery but does not extend to aortic arch, along trachea or bronchi, or into neck
Change in distribution with change in patient position?	No	Yes
Associated findings	See text	Visible thickening of pericardium; hydropneumopericardium

CASE REPORT OF PNEUMOMEDIASTINUM CASES IN DR. SOETOMO GENERAL HOSPITAL

CASE 1

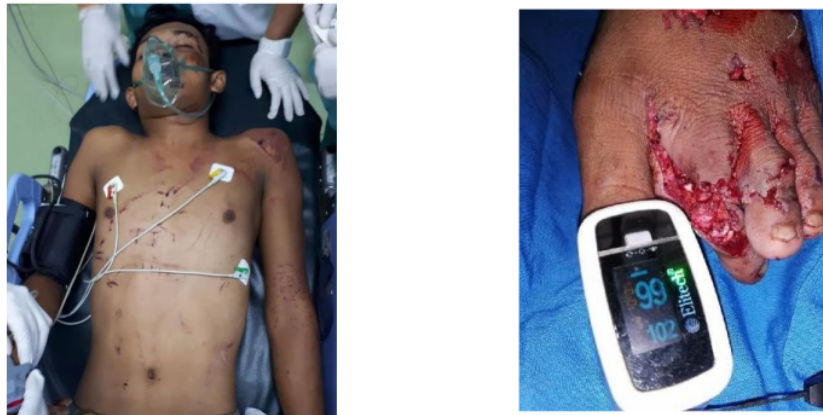

Figure 4. Man, 21 years old, post traffic accident. Patient from Mojokerto General Hospital to Emergency Room DR. Soetomo General Hospital with shortness of breath, decreased awareness and stable hemodynamics (Pulse 102x/minute, Blood Pressure 115/70 mmHg, RR 30x/minute, and Saturation 99%), resuscitation and chest x ray examination were performed. The patient was diagnosed with pneumomediastinum and left pneumothorax

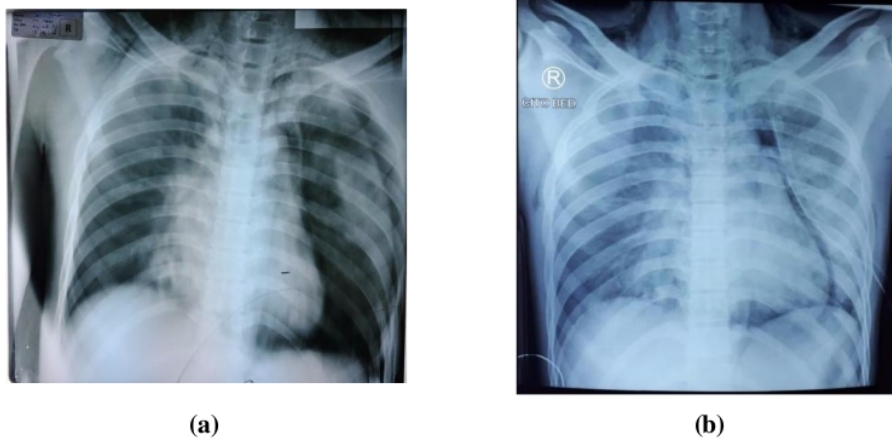


Figure 5. Thorax X-Ray (a) Before Chest Tube insertion, visible air in the mediastinal region, pulmonary collapse 40%, (b) after Chest Tube insertion, lung expand almost 100%, air lines appear on the left mediastinal edge

CASE 2

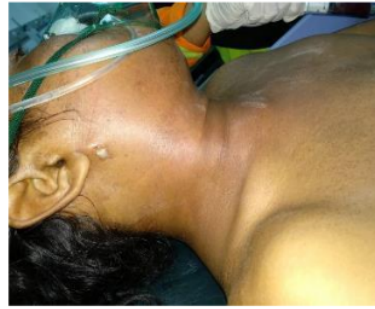
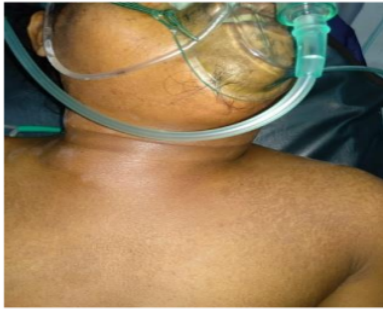
Figure 6. 35-year-old male with pain in the lower right tooth for 3 weeks and swelling in the lower jaw for about 1 week, the patient has been treated at the Mojokerto hospital by a general surgeon, the right neck has been pricked and pus is removed, then the patient was referred to the Dr. Soetomo Hospital. Diagnosis for this patient are mouth floor phlegmon + mediastinitis + pneumomediastinum

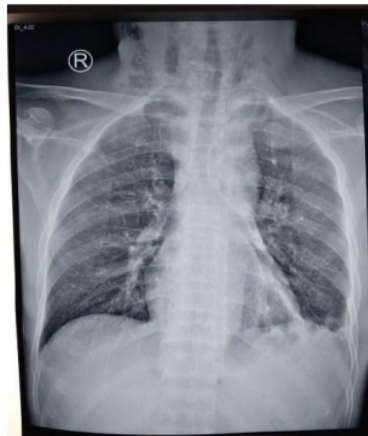
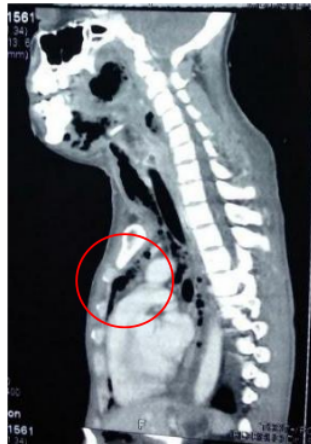
Figure 7.

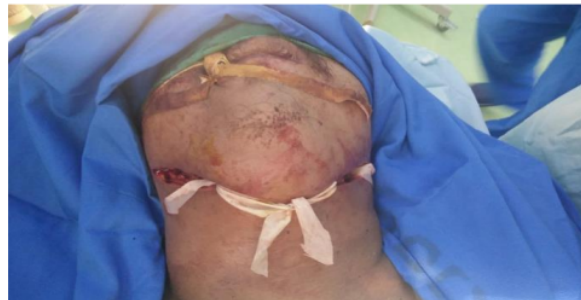
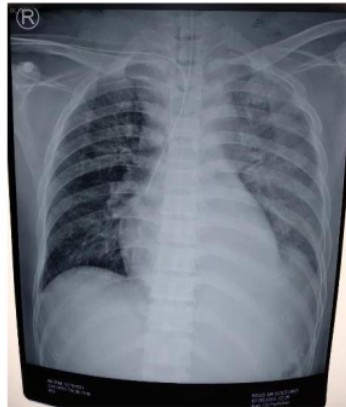

Figure 8. Operation site**Figure 9.** Chest X-Ray 4 days after mediastinal drain insertion**REFERENCES**

1. Agut A, Talavera J, Buendia A, et al. Imaging diagnosis spontaneous pneumomediastinum secondary to primary pulmonary pathology in a dalmatian dog. *Vet Radiol Ultrasound* 2014. [Epub ahead of print].
2. Al-Mufarrej F, Gharagozloo F, Tempesta B, et al. Spontaneous cervicothoracolumbar pneumorrhachis, pneumomediastinum and pneumoperitoneum. *Clin Respir J* 2009;3:239-43.
3. Bejvan SM, Godwin JD. Pneumomediastinum: Old Sign and New Sign. *American Journal of Roentgenology*. 1996;166:1041-1048.
4. Caceres M, Ali SZ, Braud R, et al. Spontaneous pneumomediastinum: a comparative study and review of the literature. *Ann Thorac Surg* 2008;86:962-6.
5. Cakmak M, Yuksel M, Kandemir MN. Analysis of Patients With Spontaneous Pneumomediastinum. *Turk Thorac J*. 2016;17:105-108.
6. Carolan PL. Pneumomediastinum. *Medscape*. 2019. 4-11.
7. Chu CM, Leung YY, Hui JY, et al. Spontaneous pneumomediastinum in patients with severe acute respiratory syndrome. *Eur Respir J* 2004;23:802-4.
8. Hamman L. Spontaneous mediastinal emphysema. *Bull Johns Hopkins Hosp* 1939;64:1-21.
9. Hammond DI. The "ring-around-the-artery" sign in pneumomediastinum. *J Can Assoc Radiol* 1984;35:88-9.
10. Iyer VN, Joshi AY, Ryu JH. Spontaneous pneumomediastinum: analysis of 62 consecutive adult

- patients. *Mayo Clin Proc* 2009;84:417-21.
11. Koaritas VK, Papagiannopoulos K, Lazaridis G, et al. Pneumomediastinum. *Journal of Thoracic Disease*. 2015; 7(S1): S44-S49.
 12. Kobashi Y, Okimoto N, Matsushima T, et al. Comparative study of mediastinal emphysema as determined by etiology. *Intern Med* 2002;41:277-82.
 13. Langwieler TE, Steffani KD, Bogoevski DP. Spontaneous Pneumomediastinum. *Ann Thorac Surg*. 2004;78:71-3.
 14. Lee YJ, Jin SW, Jang SH, et al. A Case of Spontaneous Pneumomediastinum & Pneumopericardium in A Young Adult. *The Korea Journal of Internal Medicine*. 2001; 16:4-6
 15. Macia I, Moya J, Ramos R, et al. Spontaneous pneumomediastinum: 41 cases. *Eur J Cardiothorac Surg* 2007;31:1110-4.
 16. Macklin MT, Macklin CC. Malignant interstitial emphysema of the lungs and mediastinum as an important occult complication in many respiratory diseases and other conditions: an interpretation of the clinical literature in the light of laboratory experiment. *Medicine* 1944;23:281-358.
 17. Meireles J, Neves S, Castro A, et al. Spontaneous Pneumomediastinum Revisited. *Respiratory Medicine CME*. 2011;5:181-183
 18. Pooyan P, Puruckherr M, Summers JA, et al. Pneumomediastinum, pneumopericardium, and epidural pneumatosis in DKA. *J Diabetes Complications* 2004;18:242-7.
 19. Russo A, Del Vecchio C, Zaottini A, et al. Role of emergency thoracic ultrasonography in spontaneous pneumomediastinum. Two case report. *G Chir* 2012;33:285-96.
 20. Sahni S, Verma S, Grullon J, et al. Spontaneous Pneumomediastinum: Time For Concensus. *North American Journal of Medical Sciences*. 2013;5:460-463.

PNEUMOMEDIASTINUM

ORIGINALITY REPORT

9%

SIMILARITY INDEX

4%

INTERNET SOURCES

7%

PUBLICATIONS

0%

STUDENT PAPERS

PRIMARY SOURCES

- | | | |
|---|--|----|
| 1 | f1000researchdata.s3.amazonaws.com
Internet Source | 1% |
| 2 | Konstantinos Grapatsas, Zoi Tsiligianni, Vasileios Leivaditis, Sotirios Kotoulas et al. "Hamman's syndrome (spontaneous pneumomediastinum presenting as subcutaneous emphysema): A rare case of the emergency department and review of the literature", Respiratory Medicine Case Reports, 2018
Publication | 1% |
| 3 | S M Bejvan, J D Godwin. "Pneumomediastinum: old signs and new signs.", American Journal of Roentgenology, 1996
Publication | 1% |
| 4 | europepmc.org
Internet Source | 1% |
| 5 | Haichun Ma, Chengluan Xuan, Kan He, Dan Wang, Qunshu Zhang. "Secondary pneumomediastinum and bilateral tension | 1% |

pneumothorax following aneurysmal subarachnoid hemorrhage surgery: a report of five cases", Research Square, 2019

Publication

6	patents.google.com Internet Source	1 %
7	bmcproc.biomedcentral.com Internet Source	1 %
8	www.pagepressjournals.org Internet Source	1 %
9	Lane, A. S., B. Champion, S. Orde, and D. Dravec. "Diabetic ketoacidosis due to fulminant type 1 diabetes: A rare subtype of type 1 diabetes leading to unusual sequelae", Journal of the Intensive Care Society, 2014. Publication	1 %
10	Bertho Nieboer, Nail Aboosy, Louis Verschoor, Aad Huisman. "Pneumomediastinum as a cause of acute chest pain postpartum", The Journal of Maternal-Fetal & Neonatal Medicine, 2009 Publication	1 %
11	"Abstracts", Hepatology International, 2020 Publication	1 %
12	Molly James. "Spontaneous Pneumomediastinum", Journal of Hospital Medicine, 07/2007	1 %

Publication

Exclude quotes On

Exclude bibliography On

Exclude matches Off

PNEUMOMEDIASTINUM

GRADEMARK REPORT

FINAL GRADE

/100

GENERAL COMMENTS

Instructor

PAGE 1

PAGE 2

PAGE 3

PAGE 4

PAGE 5

PAGE 6

PAGE 7

PAGE 8

PAGE 9
