

JURNAL WIDYA MEDIKA

Print ISSN 2338-0373
Online ISSN 2623-2723



[Home \(http://jurnal.wima.ac.id/index.php/JWM/index\)/](http://jurnal.wima.ac.id/index.php/JWM/index/) [Archives](#)
(<http://jurnal.wima.ac.id/index.php/JWM/issue/archive/>) / [Vol 5, No 2 \(2019\)](#)
(<http://jurnal.wima.ac.id/index.php/JWM/issue/view/268>)

[Submit an Article](#)
(<http://jurnal.wima.ac.i>

Vol 5, No 2 (2019)

DOI: <https://doi.org/10.33508/jwm.v5i2>
(<https://doi.org/10.33508/jwm.v5i2>)

[Article V](#)
(<https://drive.goo>
[T0w32h0il](#)

[Public:](#)
(</index.php/JWM/abc>

[ABOUT THE JOUR](#)

[Onlin](#)
(</index.php/JWM/about>

[Editorial Team \(/inde:](#)

[Reviewer \(/index.p\]](#)

[Foc](#)
(</index.php/JWM/about>

[Oper](#)
(</index.php/JWM/about/>

[Publication Ethics](#)
[index.php/JWM/abc](#)

[Peer I](#)
(</index.php/JWM/abc>

[Cop](#)
(</index.php/JWM/aboi>

Table of Contents

COVER

COVER

[PDF](#)

(<http://jurnal.wima.ac.id/index.php/JWM/article/view/2209/1978>)

Sekapur Sirih

EDITORIAL

[PDF](#)

(<http://jurnal.wima.ac.id/index.php/JWM/article/view/2208/1977>)

Articles

When Do We Need Pleural Surgery?

(<http://jurnal.wima.ac.id/index.php/JWM/article/view/2200>), (<http://jurnal.wima.ac.id/i>

Paul L Tahalele, Merlinda Dwintasari, Y Motulo, Yan Efrata Sembiring,
Dhihintia Jiwangga Suta

([https://www.statcounter.](https://www.statcounter)

Pneumomediastinum

(<http://jurnal.wima.ac.id/index.php/JWM/article/view/2201>), (<http://jurnal.wima.ac.id/i>
[View Jurnal Widya](http://jurnal.wima.ac.id/i)
[Medika Stats](http://jurnal.wima.ac.id/i)

Paul L Tahalele, Merlinda Dwintasari, Y Motulo, Yan Efrata Sembiring,
Dhihintia Jiwangga Suta

(<http://statcounter.com/p>
[quest=1](http://statcounter.com/p))

Progress In Knowledge Of Microscopic Tuberculosis

Diagnosis Laboratory Training Participants

(<http://jurnal.wima.ac.id/index.php/JWM/article/view/2202>), (<http://jurnal.wima.ac.id/i>

Silvia Sutandhio, Ni Made Mertaniasih, Eko Budi Koendhori, Deby
Kusumaningrum, Titiek Sulistyowati, Lindawati Alimsardjono, Pepy Dwi
Endraswari, Manik Retno Wahyunitisari, Rebekah Juniati Setiabudi

Analisis Hambatan Perkembangan Stadium

Plasmodium Falciparum Terhadap Pemberian Ekstrak

Daun Salam Badak (Acmena Acuminatissima) In Vitro (<http://jurnal.wima.ac.id/i>

(<http://jurnal.wima.ac.id/index.php/JWM/article/view/2203>),

Laura Wihanto, Hilkatul Ilmi, Aty Widyawaruyanti, Achmad Fuad Hafid,
Indah Tantular

Staphylococcus Aureus Colonization On An

Erythrodermic Psoriasis Patient

(<http://jurnal.wima.ac.id/index.php/JWM/article/view/2204>), (<http://jurnal.wima.ac.id/i>

Dave Gerald Oenarta, NN Sri Budayanti, NN Dwi Fatmawati, NM Adi
Tarini

Intravascular Lymphoma, Jenis Limfoma Yang Jarang

Dijumpai Dengan Prognosis Buruk

(<http://jurnal.wima.ac.id/i>

<http://jurnal.wima.ac.id/index.php/JWM/article/view/2205>

Willy Sandhika, Aries Sasongko, Irene Lingkan Parengkuan

Visitors

 ID 39,131	 IE 14
 US 1,673	 NZ 13
 IN 355	 PE 12

Peranan Vaksinasi Human Papillomavirus (HPV) Sebagai Penatalaksanaan Pada Penderita Infeksi Human Immunodeficiency Virus (HIV), Bagian 1: Manifestasi Infeksi HIV Dan HPV

<http://jurnal.wima.ac.id/i>

<http://jurnal.wima.ac.id/index.php/JWM/article/view/2206>

Dave Gerald Oenarta

The Relationship Between Breastfeeding Patterns And Incidence Of Diarrhea In Children Aged 7-23 Months

<http://jurnal.wima.ac.id/index.php/JWM/article/view/2207>

Filipus Michael Yofrido, Hanung Aryana, Jessica Hoetama Jaya, Rachmat Ageng Prastowo, Rynda Kirana Satwikaputri, Pirlina Umiastuti, Indawan Setyono Hadi

 HK 37	 HU 7
 IR 36	 BE 7
 EG 36	 CY 6
 NL 35	 LK 6
 MX 33	 BD 6
 BR 33	 LY 6
 IT 26	 SI 6
 PK 25	 MG 5
 PL 22	 GH 5
 TW 22	 KG 5
 NG 21	 JO 5
 TL 17	 RS 5
 VN 17	 KH 4
 SA 16	 TT 4
 ZA 16	 NO 4
 IQ 15	 OM 4
 RO 15	 SD 4
 UA 15	 DK 4

Pageviews: 94,645



<https://info.flagcounter.c>

User

Username

Password

Remember me

Information

» [For Readers](#)

(<http://jurnal.wima.ac.id/>)

» [For Authors](#)

(<http://jurnal.wima.ac.id/>)

» [For Librarians](#)

(<http://jurnal.wima.ac.id/>)

Keywords

[ADEM](#)

(<http://jurnal.wima.ac.id/?subject=ADEM>)

[Artificial Intelligence](#)

(<http://jurnal.wima.ac.id/?subject=Artificial%20Intel>

[Beating Heart Surgery](#)

(<http://jurnal.wima.ac.id/?subject=Beating%20Heart>

[COVID-19](#)

(<http://jurnal.wima.ac.id/?subject=COVID-19>)

[D-](#)

[dimer](#)

(<http://jurnal.wima.ac.id/?subject=D-dimer>)

[DPT](#)

[Vaccination](#)

(<http://jurnal.wima.ac.id/?subject=DPT%20Vaccinati>

[EAT thickness and Syntax](#)

[score](#)

(<http://jurnal.wima.ac.id/?subject=EAT%20thickness>

[Stable Angina Pectoris](#)

(<http://jurnal.wima.ac.id/?subject=Stable%20Angina>

[T lymphocytes](#)

(<http://jurnal.wima.ac.id/?subject=T%20lymphocyte>

[T lymphocytes](#)

(<http://jurnal.wima.ac.id/?subject=T%20lymphocyte>

[T lymphocytes](#)

(<http://jurnal.wima.ac.id/?subject=T%20lymphocyte>

[T lymphocytes](#)

(<http://jurnal.wima.ac.id/?subject=T%20lymphocyte>

Wound

(<http://jurnal.wima.ac.id/index.php/wima/article/view/1147>)
subject=Wound) atopic

dermatitis

(<http://jurnal.wima.ac.id/index.php/wima/article/view/1148>)
subject=atopic%20dermatitis

children

(<http://jurnal.wima.ac.id/index.php/wima/article/view/1149>)
subject=children)

cinnamaldehyde

(<http://jurnal.wima.ac.id/index.php/wima/article/view/1150>)
subject=cinnamaldehyde)

encephalitis

(<http://jurnal.wima.ac.id/index.php/wima/article/view/1151>)
subject=encephalitis)

inflammation

(<http://jurnal.wima.ac.id/index.php/wima/article/view/1152>)
subject=inflammation)

macrophage

(<http://jurnal.wima.ac.id/index.php/wima/article/view/1153>)
subject=macrophage)

prebiotics

(<http://jurnal.wima.ac.id/index.php/wima/article/view/1154>)
subject=prebiotics)

probiotics

(<http://jurnal.wima.ac.id/index.php/wima/article/view/1155>)
subject=probiotics)

symbiotic

(<http://jurnal.wima.ac.id/index.php/wima/article/view/1156>)
subject=symbiotic)

symptoms of encephalitis

(<http://jurnal.wima.ac.id/index.php/wima/article/view/1157>)
subject=symptoms%20of%20encephalitis)

ulcer

(<http://jurnal.wima.ac.id/index.php/wima/article/view/1158>)
subject=ulcer)

Notifications

» [View](http://jurnal.wima.ac.id/)
(<http://jurnal.wima.ac.id/>)

» [Subscribe](http://jurnal.wima.ac.id/)
(<http://jurnal.wima.ac.id/>)

Journal Content

Search

Search Scope

All

Browse

» [By Issue](http://jurnal.wima.ac.id/)
(<http://jurnal.wima.ac.id/>)

» [By Author](http://jurnal.wima.ac.id/)
(<http://jurnal.wima.ac.id/>)

» [By Title](http://jurnal.wima.ac.id/)
(<http://jurnal.wima.ac.id/>)

» [Other Journals](http://jurnal.wima.ac.id/)
(<http://jurnal.wima.ac.id/>)



Jurnal Widya Medika is licensed under a [Creative Commons Attribution-ShareAlike 4.0 International License](https://creativecommons.org/licenses/by-sa/4.0/)

ISSN: 2623-2723

JURNAL

WIDYA MEDIKA

Print ISSN 2338-0373

Online ISSN 2623-2723



[Home \(http://jurnal.wima.ac.id/index.php/JWM/index/\)](http://jurnal.wima.ac.id/index.php/JWM/index/) / [About the Journal \(http://jurnal.wima.ac.id/index.php/JWM/about/\)](http://jurnal.wima.ac.id/index.php/JWM/about/) / [Editorial Team \(http://jurnal.wima.ac.id/index.php/JWM/about/editorialTeam/\)](http://jurnal.wima.ac.id/index.php/JWM/about/editorialTeam/)

Submit an Article
(<http://jurnal.wima.ac.i>)

Editorial Team

Editor in Chief

- **[Paul L Tahalele](#)**

([javascript:openRTWindow\('http://jurnal.wima.ac.id/index.php/JWM/about/editorialTeamBio/824/'\)](http://jurnal.wima.ac.id/index.php/JWM/about/editorialTeamBio/824/))

, Faculty of Medicine, Widya Mandala Surabaya Catholic University, Indonesia

Managing Editor

- **[Lukas Slamet Rihadi](#)**

([javascript:openRTWindow\('http://jurnal.wima.ac.id/index.php/JWM/about/editorialTeamBio/825/'\)](http://jurnal.wima.ac.id/index.php/JWM/about/editorialTeamBio/825/))

, Faculty of Medicine, Widya Mandala Catholic University Surabaya, Indonesia

- **[Jakobus Gerick Pantouw](#)**

([javascript:openRTWindow\('http://jurnal.wima.ac.id/index.php/JWM/about/editorialTeamBio/826/'\)](http://jurnal.wima.ac.id/index.php/JWM/about/editorialTeamBio/826/))

, Faculty of Medicine, Widya Mandala Catholic University Surabaya, Indonesia

- **[Filipus Michael Yofrido](#)**

([javascript:openRTWindow\('http://jurnal.wima.ac.id/index.php/JWM/about/editorialTeamBio/827/'\)](http://jurnal.wima.ac.id/index.php/JWM/about/editorialTeamBio/827/))

, Faculty of Medicine, Widya Mandala Catholic University Surabaya, Indonesia

- **[Vincentius Widya Iswara](#)**

([javascript:openRTWindow\('http://jurnal.wima.ac.id/index.php/JWM/about/editorialTeamBio/835/'\)](http://jurnal.wima.ac.id/index.php/JWM/about/editorialTeamBio/835/))

Article V

(<https://drive.goo>

T0w32h0il

Public:

(</index.php/JWM/abr>

[ABOUT THE JOUR](#)

Onlin

(</index.php/JWM/about>

[Editorial Team \(/inde:](#)

[Reviewer \(/index.pl](#)

Foc

(</index.php/JWM/about>

Oper

(</index.php/JWM/about/>

Publication Ethics

(</index.php/JWM/abr>

Peer I

(</index.php/JWM/abr>

Cop

bor

Editorial Boards

- **Inge Watimena**
([javascript:openRTWindow\('http://jurnal.wima.ac.id/index.php/JWM/about/editorialTeamBio/828'\)](http://jurnal.wima.ac.id/index.php/JWM/about/editorialTeamBio/828))
, Faculty of Medicine, Widya Mandala Catholic University
Surabaya, Indonesia
Visitors (since Oct 19, 2018): **88899653**
(<https://www.statcounter.com>)
- **Bernadette Dian Novita**
([javascript:openRTWindow\('http://jurnal.wima.ac.id/index.php/JWM/about/editorialTeamBio/850'\)](http://jurnal.wima.ac.id/index.php/JWM/about/editorialTeamBio/850))
, Faculty of Medicine, Widya Mandala Catholic University
Surabaya, Indonesia
[View Jurnal Widya Medika Stats](#)
(<http://statcounter.com/p/guest=1>)
- **Gladdy L Waworuntu**
([javascript:openRTWindow\('http://jurnal.wima.ac.id/index.php/JWM/about/editorialTeamBio/3128'\)](http://jurnal.wima.ac.id/index.php/JWM/about/editorialTeamBio/3128))
, Faculty of Medicine, Widya Mandala Catholic University
Surabaya, Indonesia
- **Dyana Sarvasti**
([javascript:openRTWindow\('http://jurnal.wima.ac.id/index.php/JWM/about/editorialTeamBio/857'\)](http://jurnal.wima.ac.id/index.php/JWM/about/editorialTeamBio/857))
, Faculty of Medicine, Widya Mandala Catholic University
Surabaya, Indonesia
- **Bambang Wasito Tjipto**
([javascript:openRTWindow\('http://jurnal.wima.ac.id/index.php/JWM/about/editorialTeamBio/2641'\)](http://jurnal.wima.ac.id/index.php/JWM/about/editorialTeamBio/2641))
, Faculty of Medicine, Widya Mandala Catholic University
Surabaya, Indonesia
- **Chrisdina Puspita Sari**
([javascript:openRTWindow\('http://jurnal.wima.ac.id/index.php/JWM/about/editorialTeamBio/3129'\)](http://jurnal.wima.ac.id/index.php/JWM/about/editorialTeamBio/3129))
, Faculty of Medicine, Widya Mandala Catholic University
Surabaya, Indonesia

Visitors

 ID 39,131	 IE 14
 US 1,673	 NZ 13
 IN 355	 PE 12
 JP 300	 ES 12
 MY 171	 CO 11
 KR 155	 GR 11
 PH 121	 EC 11
 TR 115	 IL 10
 SG 102	 KE 10
 CN 94	 PT 10
 RU 88	 NP 9
 CA 75	 DZ 9
 DE 64	 CH 8
 GB 61	 ET 8
 FR 59	 BA 8
 AU 44	 AR 7
 HK 37	 HU 7
 IR 36	 BE 7
 EG 36	 CY 6
 NL 35	 LK 6
 MX 33	 BD 6
 BR 33	 LY 6
 TH 31	 SE 6
 IT 26	 SI 6
 PK 25	 MG 5
 PL 22	 GH 5
 TW 22	 KG 5
 NG 21	 JO 5
 TL 17	 RS 5
 VN 17	 KH 4
 SA 16	 TT 4
 ZA 16	 NO 4
 IQ 15	 OM 4
 RO 15	 SD 4
 UA 15	 DK 4

Pageviews: 94,643



<https://info.flagcounter.c>

User

Username

Password

Remember me

Information

» [For Readers](#)

(<http://jurnal.wima.ac.id/>)

» [For Authors](#)

(<http://jurnal.wima.ac.id/>)

» [For Librarians](#)

(<http://jurnal.wima.ac.id/>)

Keywords

[ADEM](#)

(<http://jurnal.wima.ac.id/>)

[subject=ADEM\) Artificial Intelligence](#)

(<http://jurnal.wima.ac.id/>)

[subject=Artificial%20Intel](#)

[Beating Heart Surgery.](#)

(<http://jurnal.wima.ac.id/>)

[subject=Beating%20Heart](#)

[**COVID-19**](#)

(<http://jurnal.wima.ac.id/>)

[subject=COVID-19\) D-](#)

[dimer](#)

(<http://jurnal.wima.ac.id/>)

[subject=D-dimer\) DPT](#)

[Vaccination.](#)

(<http://jurnal.wima.ac.id/>)

[subject=DPT%20Vaccinati](#)

[EAT thickness and Syntax](#)

[score](#)

(<http://jurnal.wima.ac.id/>)

[subject=EAT%20thickness](#)

[Stable Angina Pectoris](#)

(<http://jurnal.wima.ac.id/>)

[subject=Stable%20Angina](#)

[T Lymphocytes](#)

(<http://jurnal.wima.ac.id/>)

[subject=T%20lymphocyte](#)

Wound

(<http://jurnal.wima.ac.id/index.php/wima/article/view/10000>)
subject=Wound) atopic
dermatitis

(<http://jurnal.wima.ac.id/index.php/wima/article/view/10001>)
subject=atopic%20dermatitis
children

(<http://jurnal.wima.ac.id/index.php/wima/article/view/10002>)
subject=children),
cinnamaldehyde

(<http://jurnal.wima.ac.id/index.php/wima/article/view/10003>)
subject=cinnamaldehyde),
encephalitis

(<http://jurnal.wima.ac.id/index.php/wima/article/view/10004>)
subject=encephalitis),
inflammation

(<http://jurnal.wima.ac.id/index.php/wima/article/view/10005>)
subject=inflammation),
macrophage

(<http://jurnal.wima.ac.id/index.php/wima/article/view/10006>)
subject=macrophage),
prebiotics

(<http://jurnal.wima.ac.id/index.php/wima/article/view/10007>)
subject=prebiotics),
probiotics

(<http://jurnal.wima.ac.id/index.php/wima/article/view/10008>)
subject=probiotics),
symbiotic

(<http://jurnal.wima.ac.id/index.php/wima/article/view/10009>)
subject=symbiotic),
symptoms of encephalitis

(<http://jurnal.wima.ac.id/index.php/wima/article/view/10010>)
subject=symptoms%20of:
ulcer

(<http://jurnal.wima.ac.id/index.php/wima/article/view/10011>)
subject=ulcer)

Notifications

» [View](http://jurnal.wima.ac.id/)
(<http://jurnal.wima.ac.id/>)

» [Subscribe](http://jurnal.wima.ac.id/)
(<http://jurnal.wima.ac.id/>)

Journal Content

Search

Search Scope

All

Browse

» [By Issue](http://jurnal.wima.ac.id/)
(<http://jurnal.wima.ac.id/>)

» [By Author](http://jurnal.wima.ac.id/)
(<http://jurnal.wima.ac.id/>)

» [By Title](http://jurnal.wima.ac.id/)
(<http://jurnal.wima.ac.id/>)

» [Other Journals](http://jurnal.wima.ac.id/)
(<http://jurnal.wima.ac.id/>)



Jurnal Widya Medika is licensed under a [Creative Commons Attribution-ShareAlike 4.0 International License](https://creativecommons.org/licenses/by-sa/4.0/)

ISSN: 2623-2723



JURNAL WIDYA MEDIKA

UNIVERSITAS KATOLIK WIDYA MANDALA SURABAYA

P-ISSN : 23380373 < > E-ISSN : 26232723

0 Impact Factor

116 Google Citations

Sinta 4 Current Accreditation

- Google Scholar Garuda Website Editor URL

History Accreditation

2018 2019 2020 2021 2022

Garuda Google Scholar

ROLE OF PROBIOTICS, PREBIOTICS AND SYNBOTICS IN ATOPIC DERMATITIS

FAKULTAS KEDOKTERAN UNIVERSITAS KATOLIK WIDYA MANDALA SURABAYA JURNAL WIDYA MEDIKA Vol 8, No 1 (2022): April 76-85

2022 DOI: 10.33508/jwm.v8i1.3571 Accred : Sinta 4

THE EFFECT OF CINNAMALDEHYDE MEMBRANE APPLICATION ON THE NUMBER OF MACROPHAGES ON THE INFLAMMATION PROCESS OF LABIAL ULCUS OF WISTAR RATS

FAKULTAS KEDOKTERAN UNIVERSITAS KATOLIK WIDYA MANDALA SURABAYA JURNAL WIDYA MEDIKA Vol 8, No 1 (2022): April 44-55

2022 DOI: 10.33508/jwm.v8i1.3712 Accred : Sinta 4

SARCOPENIA IN THE ELDERLY: PATHOGENESIS, DIAGNOSIS AND TREATMENT

FAKULTAS KEDOKTERAN UNIVERSITAS KATOLIK WIDYA MANDALA SURABAYA JURNAL WIDYA MEDIKA Vol 8, No 1 (2022): April 1-18

2022 DOI: 10.33508/jwm.v8i1.3551 Accred : Sinta 4

CITOMEGALOVIRUS (CMV) ENCEPHALITIS: A CASE REPORT

FAKULTAS KEDOKTERAN UNIVERSITAS KATOLIK WIDYA MANDALA SURABAYA JURNAL WIDYA MEDIKA Vol 8, No 1 (2022): April 67-75



2022 DOI: 10.33508/jwm.v8i1.3826 Accred : Sinta 4

THE EFFECTS OF PINUS MASSONIANA (PINE POLLEN) AS ADJUVANT THERAPY ON LEUKOCYTES, T LYMPHOCYTES, C-REACTIVE PROTEIN, AND D-DIMERS IN HOSPITALIZED COVID-19 PATIENTS



FAKULTAS KEDOKTERAN UNIVERSITAS KATOLIK WIDYA MANDALA SURABAYA JURNAL WIDYA MEDIKA Vol 8, No 1 (2022): April 31-43

2022 DOI: 10.33508/jwm.v8i1.3626 Accred : Sinta 4

[RELATIONSHIP OF EPICARDIAL ADIPOSE TISSUE THICKNESS AND NEUTROPHIL TO LYMPHOCYTE RATIO WITH CORONARY LESION SEVERITY IN STABLE CORONARY HEART DISEASE](#)

FAKULTAS KEDOKTERAN UNIVERSITAS KATOLIK WIDYA MANDALA SURABAYA  [JURNAL WIDYA](#)
MEDIKA Vol 8, No 1 (2022): April 86-98
📅 2022 [DOI: 10.33508/jwm.v8i1.3825](#)  [Accred : Sinta 4](#)

[ACUTE DISSEMINATED ENCEPHALOMYELITIS FOLLOWING A DIPHTHERIA-PERTUSSIS-TETANUS VACCINATION: A CASE REPORT](#)

FAKULTAS KEDOKTERAN UNIVERSITAS KATOLIK WIDYA MANDALA SURABAYA  [JURNAL WIDYA](#)
MEDIKA Vol 8, No 1 (2022): April 56-66
📅 2022 [DOI: 10.33508/jwm.v8i1.3827](#)  [Accred : Sinta 4](#)



[ANALYSIS FACTORS OF BREAST LESION CASE IN RSUD DR. SOETOMO SURABAYA](#)

FAKULTAS KEDOKTERAN UNIVERSITAS KATOLIK WIDYA MANDALA SURABAYA  [JURNAL WIDYA](#)
MEDIKA Vol 8, No 1 (2022): April 19-30
📅 2022 [DOI: 10.33508/jwm.v8i1.3615](#)  [Accred : Sinta 4](#)

[PHAGO PHARMACOLOGY ON THE GO. GAMIFICATION APPROACH IN CASE LEARNING PROCESS](#)

FAKULTAS KEDOKTERAN UNIVERSITAS KATOLIK WIDYA MANDALA SURABAYA  [JURNAL WIDYA](#)
MEDIKA Vol 8, No 1 (2022): Supplement Juni 28-33
📅 2022 [DOI: 10.33508/jwm.v8i1.4024](#)  [Accred : Sinta 4](#)

[OVERVIEW OF THE FIRST 1000 DAYS OF LIFE FOR EXPECTANT MOTHERS AND TODDLERS AGED 0-2 YEARS IN GIANYAR REGENCY, BALI, INDONESIA](#)

FAKULTAS KEDOKTERAN UNIVERSITAS KATOLIK WIDYA MANDALA SURABAYA  [JURNAL WIDYA](#)
MEDIKA Vol 8, No 1 (2022): Supplement Juni 1-11
📅 2022 [DOI: 10.33508/jwm.v8i1.4020](#)  [Accred : Sinta 4](#)

[View more ...](#)

WHEN DO WE NEED PLEURAL SURGERY?*

*Paul L Tahalele¹⁾, Merlinda Dwintasar¹⁾, Y Motulo²⁾, Yan Efrata Sembiring³⁾,
Dihintia Jiwangga Suta³⁾*

ABSTRACT

Pleural sac is an enclosed sac covering the lung that consist of two membranes, i.e. parietal and visceral pleura. It has a cavity filled with small amount fluid that plays important role to provide smooth sliding of lung during respiration. Change or disturbance in the pleural cavity and or the pleura itself may result in restriction of lung expansion causing ventilation compromise.

Pathology of pleura may result from varying etiology. It may present as inflammatory pleural effusion, non-inflammatory pleural effusion, pneumothorax, hemothorax, fibrothorax, pleural tumors, and cylothorax. Diagnostic tool for pleural diseases may be made from the simplest chest x-ray, ultrasound, computed tomography, MRI and histopathological studies.

There are several treatment options for managing pleural diseases. It consist non operatif treatment, pleural drainage, decortication or pleurectomy, pleurodesis, and/ or resection of pleural tumor through procedure VATS, or open thoracotomy. Indications for surgery are traumatic or spontaneous pneumothorax, hemothorax, cylothorax, failure of non operatif treatment, fibrothorax or schwarte limiting lung expansion, mesothelioma, and recurrent pneumothorax or malignant pleural effusion. Decision for surgery need appropriate timing and planning regarding different pathology and different etiology.

Keywords: *pleural surgery, decortication, pleurectomy*

1) Department of Surgery Faculty of Medicine Widya Mandala Catholic University Surabaya Indonesia, 2) Division of Thoracic, Cardiac & Vascular-Endovascular PHC Teaching Hospital Surabaya Indonesia, 3) Department of Thoracic, Cardiac, & Vascular Surgery Faculty of Medicine Universitas Airlangga Surabaya Indonesia

INTRODUCTION

Pleural disease is one of the most common diseases, every year in the UK there are 3000 people per million population affected. Pleural disease comes from a broad pathological scope and is a

systematic approach and requires proper examination and management.³ Surgery in pleural disease has developed quite slowly, with many not following modern advances in pleural surgery.²

Techniques that are less invasive that can be used and provide good results are thoracoscopy and VATS (Video-Assisted Thoracic Surgery). VATS is very widely accepted among surgeons and is liked by many patients because the technique is less invasive.⁷

1. Pleural Surgery in Pneumothorax or Pleural Effusion

Pleural effusion is a collection of fluid in the pleural cavity between the chest wall and the lung. This causes chest discomfort, coughing, or shortness of breath.²⁴ Recurrent pleural effusion often occurs. This is caused by a process that is benign or malignant in the pleura. Management that can be done in the form of **pleural drainage, thoracentesis, pleurectomy, pleurodesis, or pleuroperitoneal shunt.**²⁴

Pleurodesis is a minor surgical procedure that can be a permanent solution this

for recurrent malignant pleural effusion (MPE). This technique is done by inserting an inflammatory chemical into the pleural cavity which causes the formation of a scar between the lung and chest wall as an inflammatory response. This scar causes space in the lung and chest wall to be closed so that the fluid no longer collects here. The liquid inside can be absorbed more easily by the body. this technique has a success rate of 30%.²³

2. Pleural Surgery for Infection (Empyema)

Empyema is an inflammatory process in the visceral or parietal pleura. Empyema has complex things to discuss and have unique clinical symptoms. there is a dominant inflammatory process, ptatological differences and there are various treatment techniques for

case.¹²

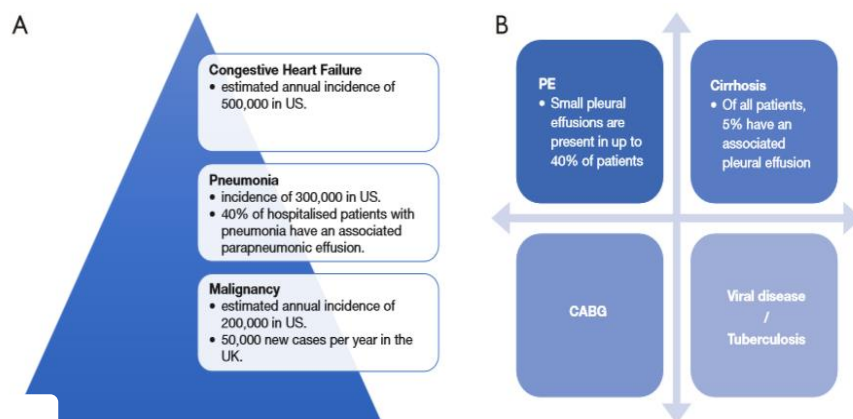
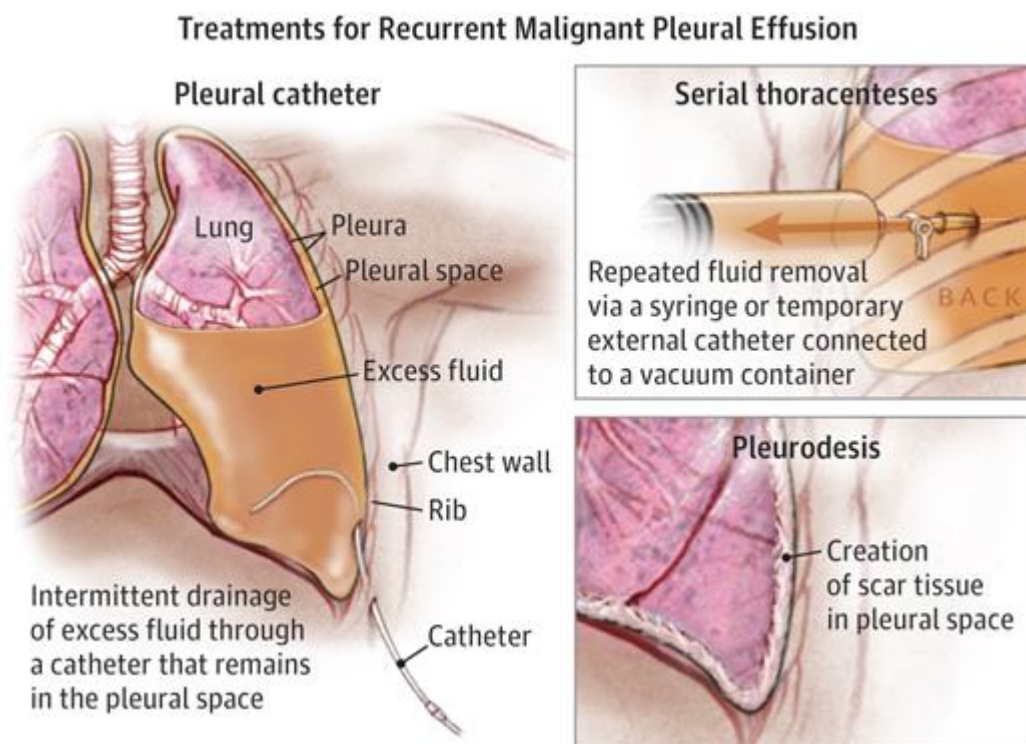


Figure 1 Causes of pleural effusion. (A) Leading causes (2,3); (B) Common causes (4-6). PE, pulmonary embolism; CABG, coronary artery bypass graft.

Figure 1. Cause of Pleural Effusion (Adopted from Perikleous P)¹⁴**Figure 2.** Treatments for Recurrent Malignant Pleural Effusion (Adopted From West H.

)²⁴Pneumonia and subsequent parapneumonic effusion are the most common causes of empyema.

Other causes are penetrating or blunt chest injury, bronchogenic carcinoma, mediastinitis, esophageal rupture, expansion of below diaphragm, thoracic, and cervical spine infection, congenital cysts from the airway and infected esophagus. The use of broad spectrum antibiotics and vaccines for pneumococci should be given to patients with empyema.²¹

Patients with pleural empyema who have a risk of Methicillin Resistant Staphylococcus Aureus and gram negative infection, can be given a third generation of cephalosporin (ceftriaxone) or aminopenicillin with β -lactamase inhibitors

(ampicillin / sulbactam). Anaerobic organisms must be treated empirically, where ampicillin / sulbactam can be given to these organisms, whereas ceftriaxone must be given in conjunction with other drugs such as metronidazole. if anaerobic bacterial infection occurs in respiratory or upper gastrointestinal, clindamycin can be used instead of metronidazole. If postsurgical infection occurs, the antibiotics that can be used are vancomycin, flagyl and cefepime, or vancomycin and piperacillin / tazobactam (very adequate for *Pseudomonas aeruginosa*). For patients with a history or suspect extended spectrum β -lactamase-producing organisms can be

given vancomycin and meropenem. Aminoglycosides are not recommended because they are not active in empyema fluid. Until now there is still no evidence base that proves that direct administration of antibiotics to pleural space provides better results than systemic antibiotics.²¹

Decortication is the treatment of choice for empyema with a lung that collapses and can't expand due to a thick sheath of inflammation. Decortication is usually used for tuberculous management and post-traumatic trapped lung. This technique aims to restore lung elasticity and free pulmonary parenchyma from the pressure of the inflammatory sheath. In stage III empyema, there is a decrease in pulmonary perfusion of 20-25% on the infected side. Where stage III empyema is equivalent to empyema which has occurred more than 6 weeks. At this stage, Fowler-Delorme's procedures were recommended,

especially for postpneumonic empyema or accompanying trauma.¹²

Decortication can increase FEV1 from 50% to 69% and vital capacity from 62% to 80%. however, the function of the infected lung is still disrupted. Ventilation/lung perfusion improvement depends on multilevel functional lung damage. Patients with posttuberculous with lung collapse and perfusion are minimal, decortication can be done, but the results are unpredictable. This technique is useful for patients with visible clinical symptoms and is not indicated for asymptomatic patients.¹²

3.Pleural Surgery for Pleural Cancers

Pleurectomy/decortication (P/D) are two sequences of procedures. Pleurectomy aims to open the chest and open the pleura around the affected tissue. While decortication to remove visible tumors from the lung surface and chest area.⁶

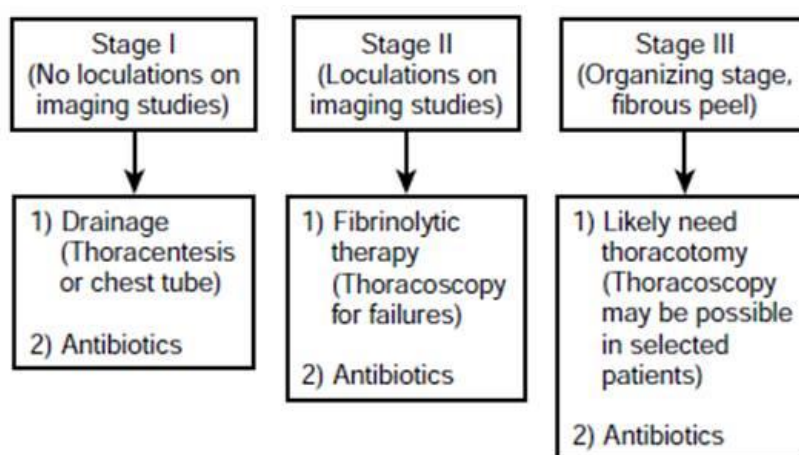


Figure 3. Stage of Empyema (Adopted From Mionar TF)¹²

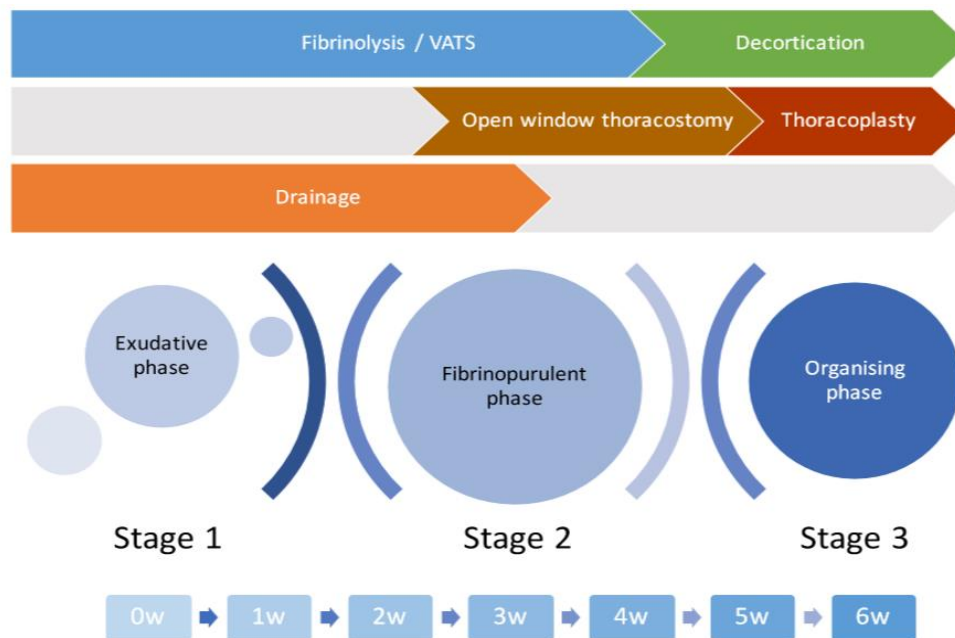


Figure 4. Time Scale for Different Stages of Thoracic Empyema and Treatment
(Adopted From Perikleous P)¹⁴

Previously, pleurectomy was commonly used for the management of pleural mesothelioma to reduce fluid around the lungs and to reduce pain, but since the surgical technique developed, decortication can be done. Generally these two techniques are combined. This technique takes several hours to be completed and the success rate depends on the thoracic surgeon's skills.⁶

To be able to do major surgery in mesothelioma patients, the patient's condition must be stable and the mesothelioma he suffered is still in the initial stage. Pleurectomy/decortication can improve the survival rate and quality of life of patients, especially if combined with

chemotherapy, radiation therapy, and other therapies. VATS (Video-assisted Thoracoscopic Surgery) is one of the treatment options and open surgery was performed if a larger tumor is found.^{1,9,11,17,22}

4. Pleural Surgery for Chylothorax

Chylothorax is a collection of chylous fluid in the thorax cavity. This often occurs because of the leakage of lymphatic vessels in the thoracic duct. other causes are cardiothoracic surgery, penetrating or blunt injury between the neck and upper abdomen, and other diseases such as lymphoma. The choice of therapy can be non operative and operative.^{4,13,18}

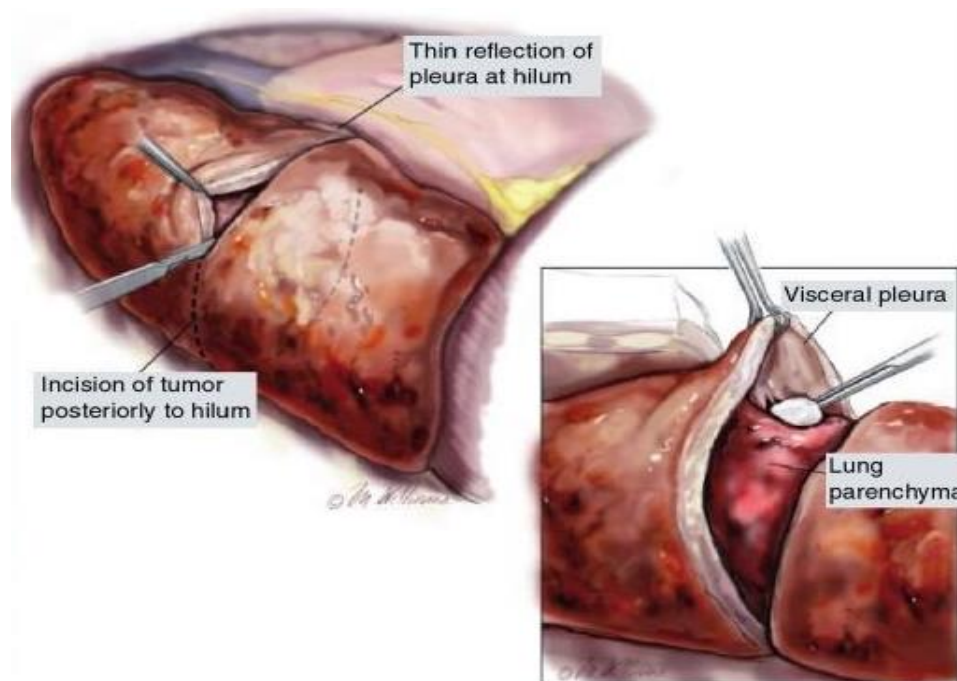


Figure 5. Pleural Surgery for Pleural Cancer (Adopted From Ismail-Khan R)⁶

The most preferred management is ligation of thoracic duct and it has a success rate of 95%. Where this success rate also depends on the procedure performed either on the azygos vein or descending aorta and the structure around the posterior mediastinum. Thoracic duct is a thin structure, has a occasional peristaltic, and tubeshaped. This duct can be dissected or stapled or clipped. If there is sufficient length, this duct can be excised and histopathological examination is performed. Ligation of the supra-diaphragmatic duct has a success rate of 90% but pleurodesis is not indicated in patients with trapped lung and prolonged effusion.¹⁰

there are several surgical options for thoracic duct ligation based on the location of the leakage and its etiology. Consuming milk or cream before surgery or injecting 1% evans blue dye on the thigh can clarify thoracic duct during VATS or open thoracotomy.¹⁶

5. Pleural Surgery for Hematotoraks

Hemothorax can occur due to trauma or non trauma. The most common causes are trauma, but non-traumatic causes such as aortic aneurysm, pulmonary embolism, haemostatic abnormalities or melignant metastatic disease can also occur.⁵ VATS can identify and control bleeding and can clear the pleural cavity from the clots. In addition, chest tube was also needed. Open thoracotomy must be

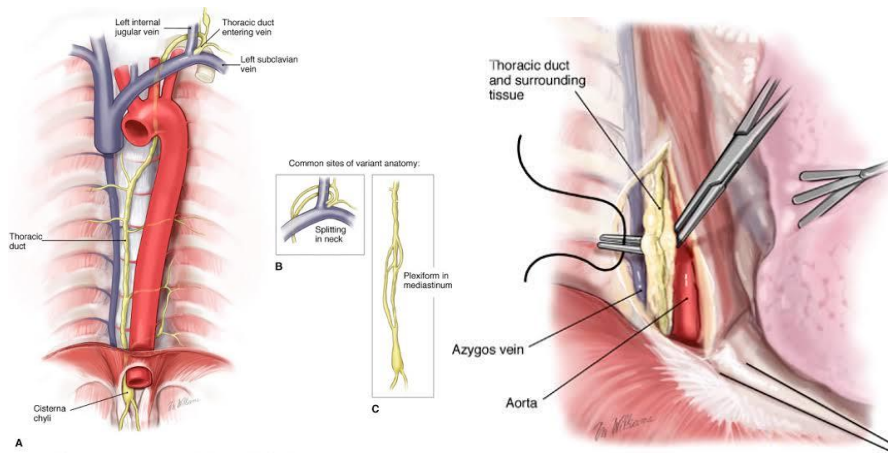


Figure 6. Surgery for Cylothorax (Adopted From Perikleous P)¹

performed in patients with multiple trauma and massive bleeding.¹⁵ The clinical symptoms can be pain that is localized to an area that is inflamed or referred pain according to the nerve pathway Other symptoms can be difficulty breathing, sneezing, coughing, which exacerbates pain. Pain is described as sharp pain and gets worse with movement.⁸

Basically the parietal and visceral pleura have a smooth surface, but can be rough due to inflammation, so that at the physical examination friction rub or rough

scratching sound can be heard during inspiration and expiration.⁸

There are several less invasive techniques for diagnosing and evaluating pleural disease, namely closed pleural biopsy, thoracosynthesis, guided image biopsy (CT or ultrasound), video-assisted Thoracoscopy surgery (VATS), medical thoracoscopy, and open thoracotomy. The main purpose of pleurisy therapy is (1) reducing pleuritic pain with analgesic drugs usually nonsteroidal anti-inflammatory drugs (NSAIDs) and (2) managing underlying diseases.⁸

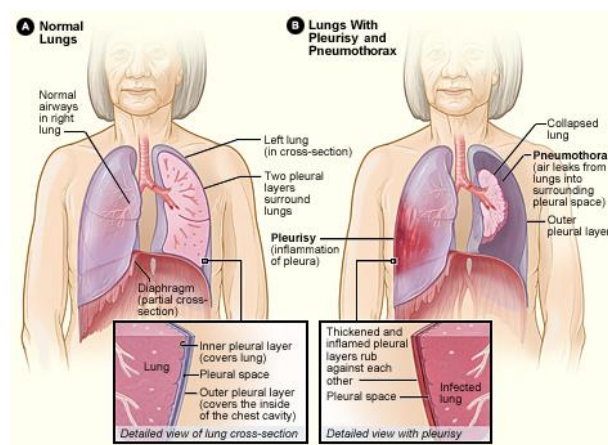


Figure 7. Lung With Pleurisy and Pneumothorax (Adopted From Kass SM)⁸

CASE 1

Surabaya Pleural Surgery Experiences

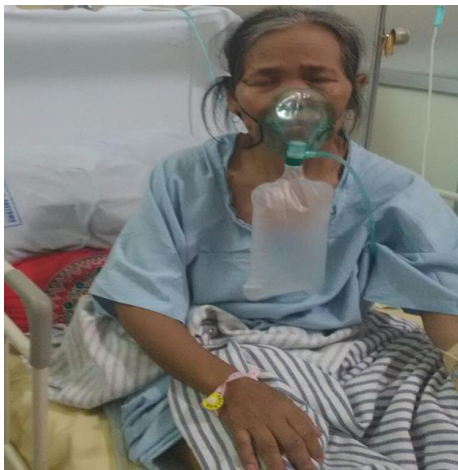

Figure 8. Female, 57 years old with Cylothorax. The patient initially had pneumonia and was treated in the lung room for 1 month. She also had right pleural effusion and drainage was performed. It appears cloudy white liquid like milk out of the drain as much as 1.5 liters. Pleural fluid analysis was done and the results of triglycerides 3 mmol / l (normal <1.24 mmol /l) and cholesterol 18 (normal <5.18 mmol /l).

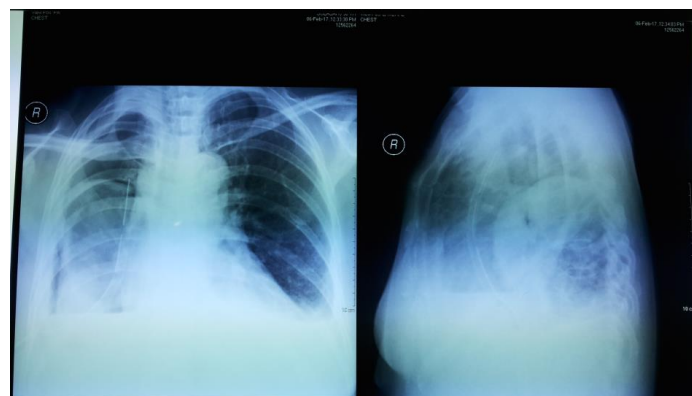


Figure 9. X-Ray Thorax, 6-2-2017

Table 1. Laboratorium Finding in Cylothorax

Feature	Chylothorax	Result of Our Patient's; Pleural Fluid Analysis
Triglycerides	>1.24 mmol/l (110 mg/dl)	TG 3
Cholesterol	>5.18 mmol/l (200 mg/dl)	Cholesterol 18
Cholesterol crystals	Absent	Protein 1.5
Chylomicrons	Present	LDH 5425

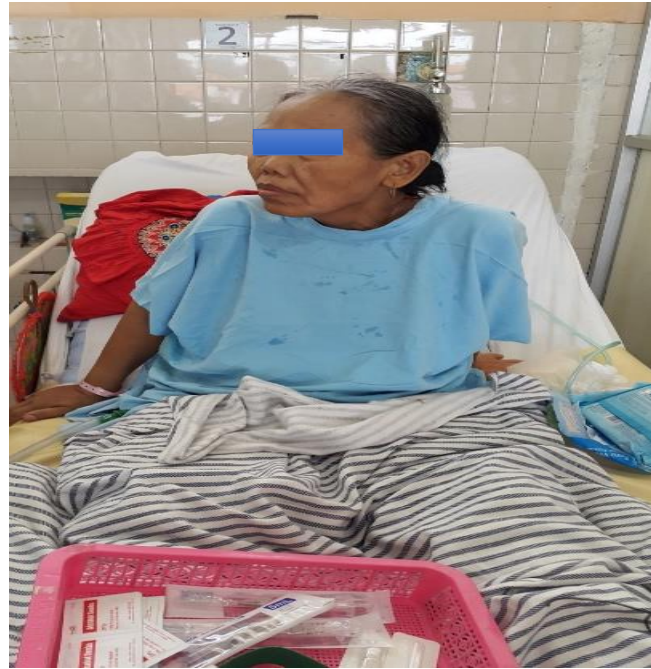

Figure 10. Patient condition after chest tube release

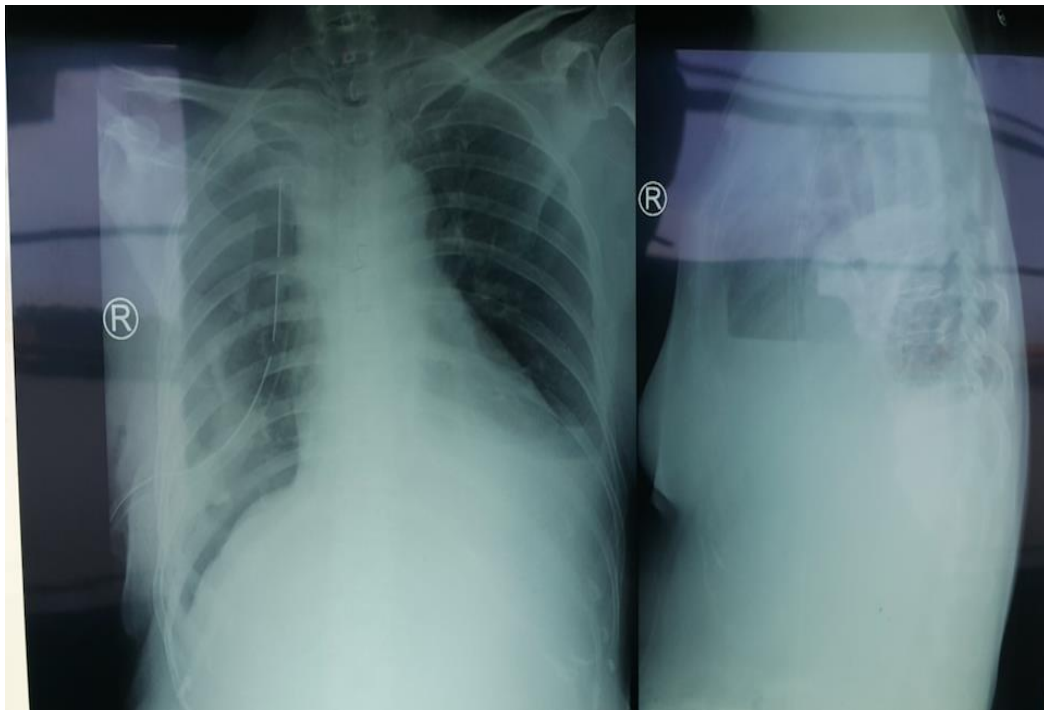
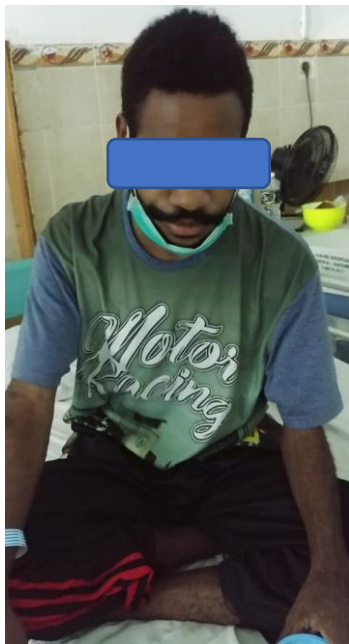
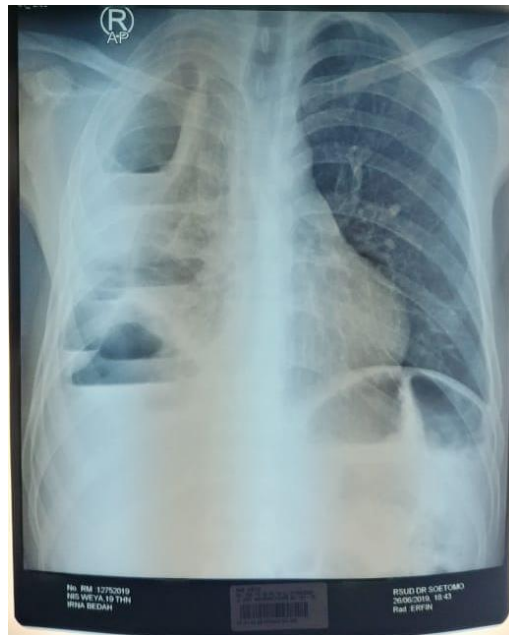
Figure 11. Chest X-Ray one month after release the chest tube

CASE 2




(a)



(b)

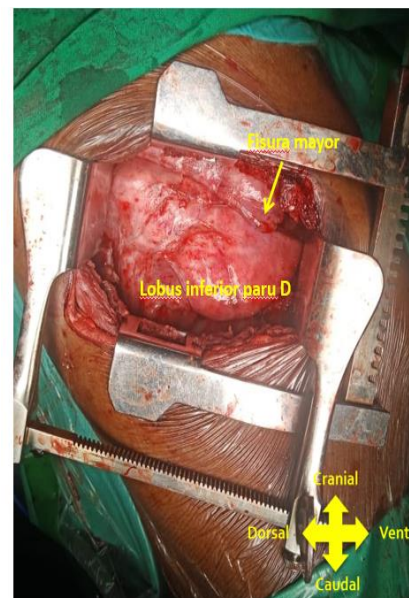
Figure 12. Man, 19 years old with Right Fluidopneumothorax + Pleuritis TB + Pulmonary TB with negative Acid Fast Bacilli (AFB) + Bronkiektasis pro Decortication, (a) Ciliac Figure, (b) Thorax X-Ray with multiple air fluid level, thickening of the parietal and visceral pleura, and right lung collapse



(a)

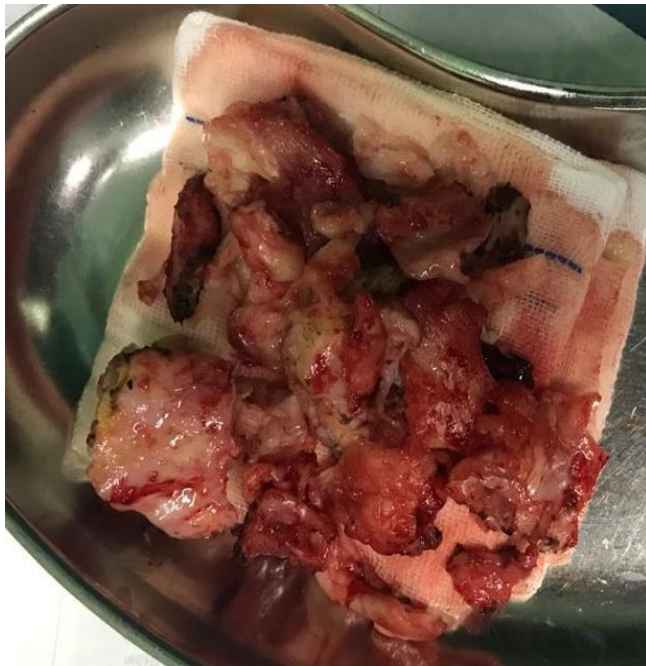

(b)

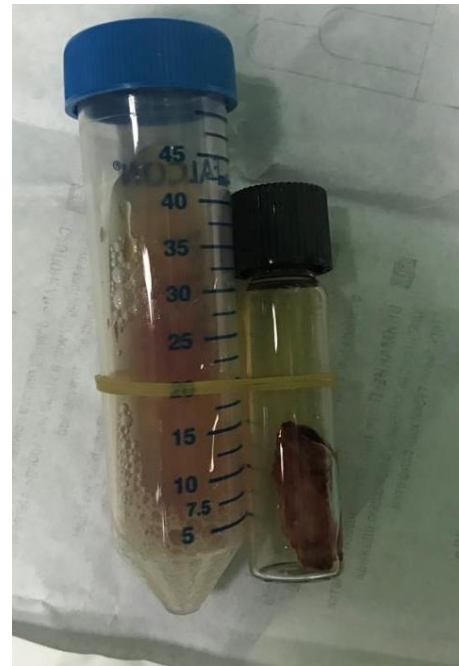

(c)

Figure 13. Operating site (a) & (b) before decortication seem fluid trapped inside the right thorax cavity, thickening of the parietal and visceral pleura, and right lung collapse, (c) after decortication the lung expand \pm 80% and look reddish



(a)



(b)

Figure 14. (a) Parietal and Visceral pleural peel (b) Pleural fluid for microbiology examination

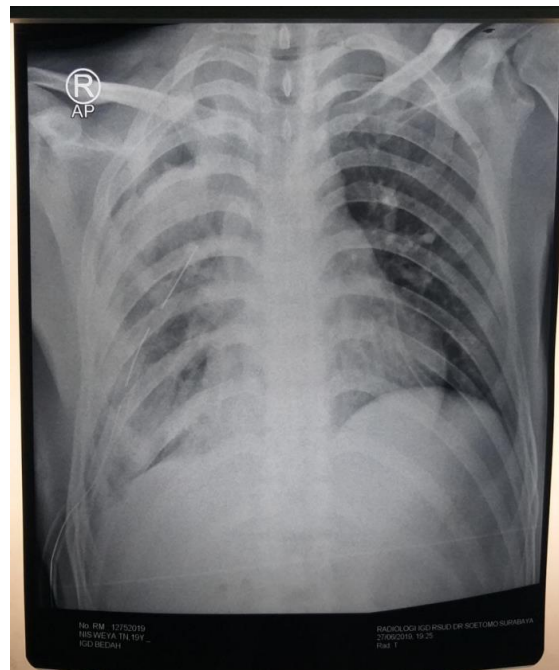


Figure 15. Chest X-Ray one day after Decortication, lung expand \pm 80%

CASE 3

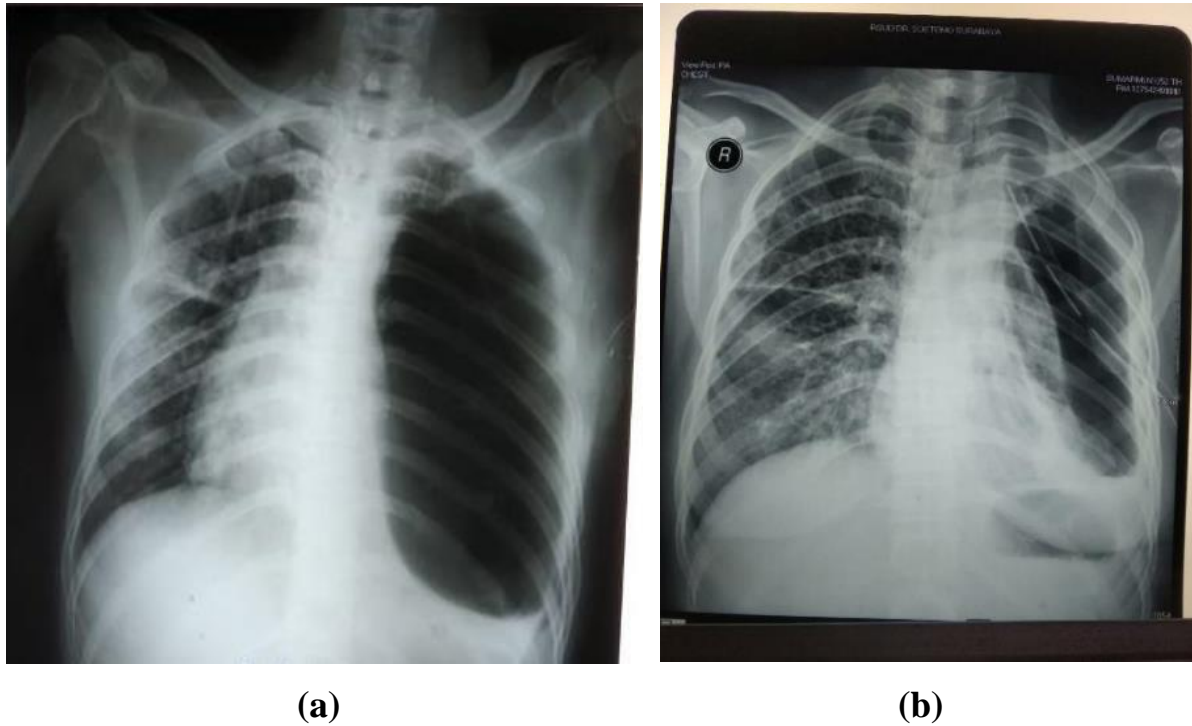


Figure 16. Woman, 50 years old with left fluidopneumothorax and Pulmonary TB, (a) before chest tube insertion seem thickening of parietal pleura, lung totally collapse, and left fluidopneumothorax (b) after chest tube insertion seem lung expand \pm 30% and thickening of parietal and visceral pleura

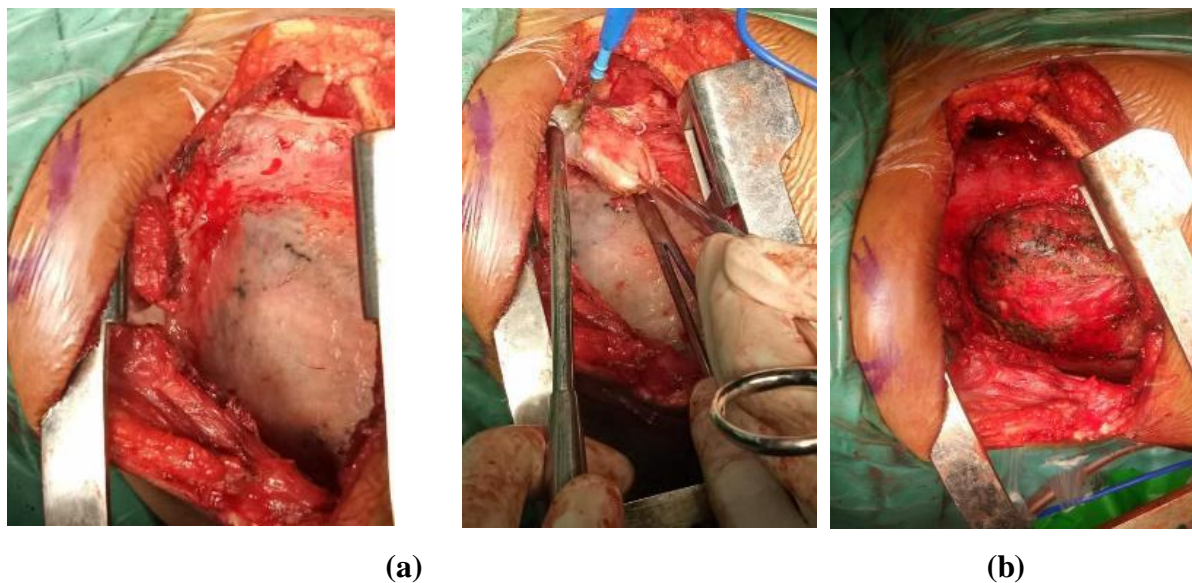


Figure 17. Operating site (a) before operation, lung collapse 30%, (b) after operation lung expand 70-80%

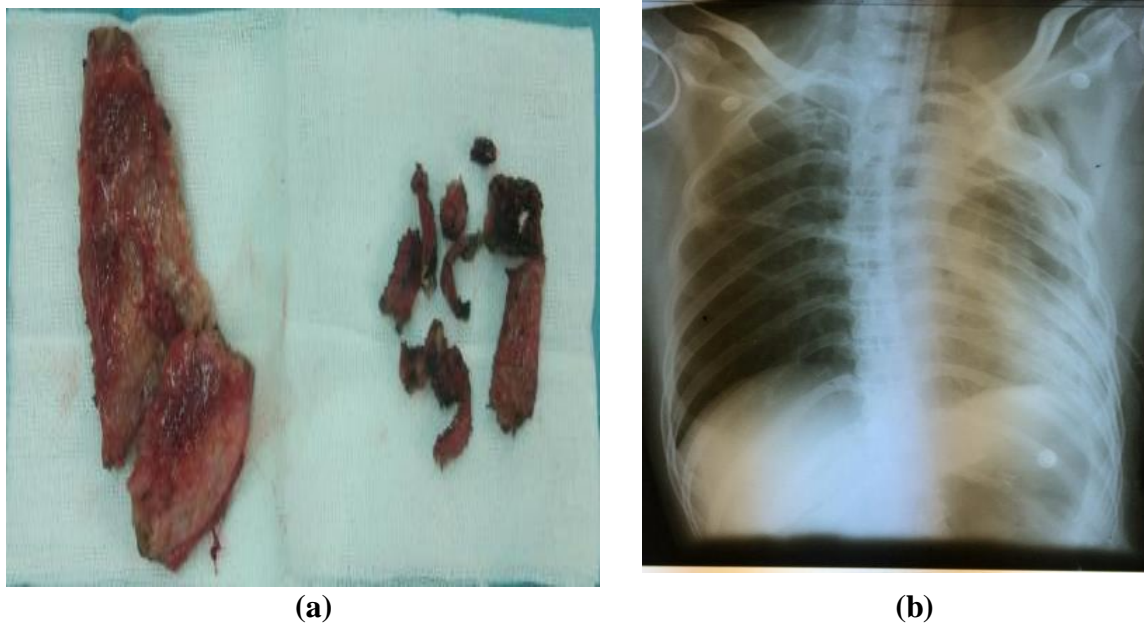


Figure 18. After decortication, (a) parietal and visceral pleura peel, (b) 1 week after decortication, chest tube was released and lung expand 80%

References

1. Cardillo G, Carbone L, Carleo F, et al. Solitary Fibrous Tumors of the Pleura: An Analysis of 110 Patients Treated in a Single Institution. *The Annals of Thoracic Surgery* 2009;88:1632-7.
2. Davies MH. Recent Advances in The Surgery of the Lung And Pleura. *British Journal of Surgery* 1913;1(2):228-58
3. Du Rand I, Maskell N. Introduction and methods: British Thoracic Society pleural disease guideline 2010. *Thorax* 2010;65(Suppl2):ii1-3
4. Fahimi H, Casselman FP, Mariani MA, et al. Current management of postoperative chylothorax. *The Annals of Thoracic Surgery* 2001;71:448-50.
5. Gallardo X, Castañer E, Mata JM. Benign pleural diseases. *Eur J Radiol* 2000;34:87-97.
6. Ismail-Khan R, Robinson LA, Williams CC Jr, Garrett CR, Bepler G, Simon GR. Malignant pleural mesothelioma: a comprehensive review. *Cancer Control*. 2006 Oct. 13(4):255-63.
7. Johna S, Alkoraishi A, Taylor E, Derrick M, Bloch JH. Video-Assisted Thoracic Surgery: Applications and Outcome. *JSLs : Journal of the Society of*

- Laparoendoscopic Surgeons. 1997;1(1):41-44.
8. Kass SM, Williams PM, Reamy BV. Pleurisy. *Am Fam Physician* 2007;75:1357-64.
 9. Kohler M, Clarenbach CF, Kestenholz P, et al. Diagnosis, treatment and long-term outcome of solitary fibrous tumours of the pleura. *European Journal of CardioThoracic Surgery* 2007;32:403-8.
 10. Lee KH, Jung JS, Cho SB, et al. Thoracic Duct Embolization with Lipiodol for Chylothorax due to Thoracic Endovascular Aortic Repair with Debranching Procedure. *The Korean Journal of Thoracic and Cardiovascular Surgery* 2015;48:74-7.
 11. Liu J, Cai C, Wang D, et al. Video-assisted thoracoscopic surgery (VATS) for patients with solitary fibrous tumors of the pleura. *J Thorac Oncol* 2010;5:240-3.
 12. Mionar TF. Current surgical treatment of thoracic empyema in adults. *European Journal of Cardio-Thoracic Surgery* 2007; 32(3): 422–430
 13. O'Callaghan AM, Mead GM. Chylothorax in lymphoma: mechanisms and management. *Ann Oncol* 1995;6:603-7.
 14. Perikleous P, Rathinam S, Waller D.A. VATS and Open Chest Surgery in Diagnosis and Treatment of Benign Pleural Diseases. *Journal of Visualized Surgery* 2017;3:6-10.
 15. Richardson JD, Miller FB, Carrillo EH, et al. Complex thoracic injuries. *Surg Clin North Am* 1996;76:725-48.
 16. Robins E, Walsh D. Minimally Invasive Surgical Treatment of Pediatric Chylothorax. *Society of American Gastrointestinal and Endoscopic Surgeons* 2017: 5.
 17. Robinson LA. Solitary fibrous tumor of the pleura. *Cancer Control* 2006;13:264-9.
 18. Romero S. Nontraumatic chylothorax. *Current Opinion in Pulmonary Medicine* 2000;6:287-91.
 19. Schild HH, Strassburg CP, Welz A, et al. Treatment options in patients with chylothorax. *Dtsch Arztebl Int* 2013;110:819-26
 20. Sensakovic WF, Armato SG, Starkey A, et al. Quantitative measurement of lung reexpansion in malignant pleural mesothelioma patients undergoing pleurectomy/

- decortication. Acad Radiol 2011;18:294-8.
21. Shen RK, Bribriesco A, Crabtree T, et al. Guidelines for The Management of ěEmpyema. The American Association fot Thoracic Surgery Consensus 2017: 5-6
22. Takahama M, Kushibe K, Kawaguchi T, et al. VideoAssisted Thoracoscopic Surgery Is a Promising Treatment for Solitary Fibrous Tumor of the Pleura. Chest 2004;125:1144-7.
23. Vaz MC, Marchi E, Vargas FS. Pleurodesis: technique and indications. J Bras Pneumol.2006;32, (4): 347-356
24. West H. Malignant Pleural Effusions. JAMA Oncol. 2015;1(2):260.