

First Unprovoked Seizure in Indonesian Children

by Prastiya Indra Gunawan

Submission date: 06-Mar-2023 02:11PM (UTC+0800)

Submission ID: 2030015904

File name: First_Unprovoked_Seizure_in_Indonesian_Children.pdf (746.26K)

Word count: 2693

Character count: 15146



Original Article

First Unprovoked Seizure in Indonesian Children

Prastiya Indra Gunawan* , Riza Noviandi , Sunny Mariana Samosir

Department of Child Health, Neurology Division, Faculty of Medicine, Universitas Airlangga, Dr. Soetomo General Academic Hospital, Surabaya, Indonesia

ARTICLE INFO

Article history

Receive: 2022-12-18

Received in revised: 2023-02-10

Accepted: 2023-02-15

Manuscript ID: JMCS-2301-1934

Checked for Plagiarism: Yes

Language Editor:

Dr. Fatimah Ramezani

Editor who approved publication:

Dr. Ali Delpisheh

DOI:10.26655/JMCHMSCI.2023.8.19

KEYWORDS

Children

EEG

First unprovoked seizure

Health

ABSTRACT


Introduction: First unprovoked seizure (FUS) in children is a frightening health problem that often to be taken to emergency room. EEG is absolutely required to determine seizure activity in the brain. It can differentiate seizures from nonepileptic paroxysmal events. This study aims to determine the EEG description of children who experience FUS.

Methods: This study used a retrospective observational method using medical records. All patients in the category of children aged 0 months to 18 years old who came with their FUS and had recorded an EEG, were included. EEG recording is done as soon as possible and a maximum of 2 days after the seizure occurs. Data were analyzed using descriptive statistics and presented in tables and graphs.

Result: The clinical characteristics of FUS show that the majority of boys (61.3%) are older than 5 years old (52.8%). The types of seizures that appear are more generalized seizures and mostly the duration is less than 5 minutes. A few patients have anemia. Abnormal EEG interpretation results reached 53.8% with around 68% of them showing epileptiform discharge. Classification of abnormal EEG indicates more on focal slowing, centrotemporal sharp wave, and BECTS activity.

Conclusion: FUS in Indonesia mostly reported in boys. Generalized seizures were commonly seen. EEG interpretation is mostly abnormal that commonly showing epileptiform discharge. Most of the EEG abnormal classifications that lead to epileptiform activity are focal slowing. This can be a considerable of the possibility of recurrent seizure in later life.

GRAPHICAL ABSTRACT



* Corresponding author: Prastiya Indra Gunawan

✉ E-mail: Email: prastiya-i-g@fk.unair.ac.id

© 2023 by SPC (Sami Publishing Company)

Introduction

Seizures are a neurological clinical complaint that is often found in children so the child has to be taken to the emergency room. The first seizure is a frightening event and creates worry for the patient and family [1]. This is further an emergency event that brings depression to medical personnel. The first unprovoked seizure (FUS) is the first seizure event in the history of life without fever, an infectious process that attacks the brain, the impact of certain drugs, metabolic processes, head trauma, or hypoxia [2]. The incidence of single FUS in the pediatric population ranges from 30-50 per 100,000 persons and some estimate 23-61 per 100,000 person-years [3, 4]. Epidemiological data in Indonesia showed that 17 cases of FUS were found in children in Surabaya in the 2-year research duration [5]. The FUS diagnosis usually needs the confirmation of seizure nature of the event, precisely etiology, seizure type classification, and epileptic syndrome. Seizure recognition is important prognostic information. History of disease and physical examination are not sufficient to prove the seizure activity and further work up with Electroencephalogram (EEG) is valuable because episode that mimic seizures are also common [2, 4].

EEG is a device that can detect seizures. It is a test that measures electrical activity in the brain using electrodes attached to the scalp. Neuron may communicate via electrical impulses that are active even during sleeping. In the case of children with epilepsy, an EEG is absolutely required to determine seizure activity in the brain [6, 7]. EEG can also differentiate seizures from nonepileptic paroxysmal events. Conventional EEG in children is commonly done in about half an hour, given that not all countries have 24-hour EEG monitoring. In emergency cases, there is really no reason to do an EEG, but it can be done as soon as possible after the seizure occurs. EEG in FUS can be used to predict the occurrence of subsequent seizures as well as to localize the source of seizures, thereby facilitating the seizure type and potential epileptic syndrome as well as confirm the diagnosis and treatment [8, 9]. Several studies

stated that EEG that performed after FUS demonstrate high abnormalities of approximately 40-60% [2].

This study aims to determine the EEG description of children who experience FUS. They perform EEG recording as soon as possible following FUS to evaluate the seizure activity in the brain.

Materials and Methods

Patients

This study used a retrospective observational method using medical records from January 2018 to January 2020. All patients in the category of children aged 0 months to 18 years old who came with their first unprovoked seizure, and then had an EEG recorded were included in the inclusion criteria. Patients were excluded if the data in the medical record were incomplete or other conditions were found as a trigger of the seizures, such as fever, intracranial infection, metabolic abnormalities, space-occupying lesions, or metabolic abnormalities. The EEG recording was performed using a Cadwell 32-channel EEG system ARC ESSENTIA machine and interpreted by a pediatric epileptologist who has an international certificate as EEG reader by ILAE. EEG recording is done as soon as possible and a maximum of 2 days after the seizure occurs. EEG recording was done using conventional techniques for 30 minutes with sleep and wakefulness phases. Data taken from medical records included age, sex, type of seizure that occurred, duration of seizure, clinical condition and laboratory results of the patient's blood examination, and EEG interpretation results.

Ethics

This research has been registered and approved to do under the number KEPK-1860/2020-III issued by the Ethics Committee of Dr. Soetomo General Academic Hospital, Indonesia.

Statistics

Research data is processed using IBM SPSS v23. Data were analyzed using descriptive statistics and presented in tables and graphs.

Results and Discussion

The clinical characteristics of FUS show that the majority of boys (61.3%) are older than 5 years old (52.8%). The types of seizures that appear are more generalized seizures and mostly the duration is less than 5 minutes. A few patients

have anemia. Abnormal EEG interpretation results reached 53.8% with around 68% of them showing epileptiform discharge (Table 1). Classification of abnormal EEG indicates more on focal slowing, centrottemporal sharp wave, and BECTS activity (Figure 1).

Table 1. Baseline characteristics of the subjects

Baseline Characteristics	Total (n = 106)
Age	
< 5 years old	50 (47,2%)
≥ 5 years old	56 (52,8%)
Sex	
Boys, n (%)	65 (61,3 %)
Girls, n (%)	41 (38,7%)
Seizures Type	
Generalised seizure	89 (83,9%)
Focal seizure	17 (16,1%)
Seizure duration	
< 5 minute	67 (63,2%)
≥ 5 minute	39 (36,8%)
Neurocutaneous syndrome	
Strudte weber syndrome	1
Tuberosklerosis	1
Laboratory findings	
Anemia	7
Leucosytosis	4
EEG interpretation	
Abnormal	57 (53,8%)
Normal	49 (46,2%)
Type of abnormal wave	
• Epileptiform discharge	38 (66,7%)
• Non-epileptiform discharge	19 (33,3%)

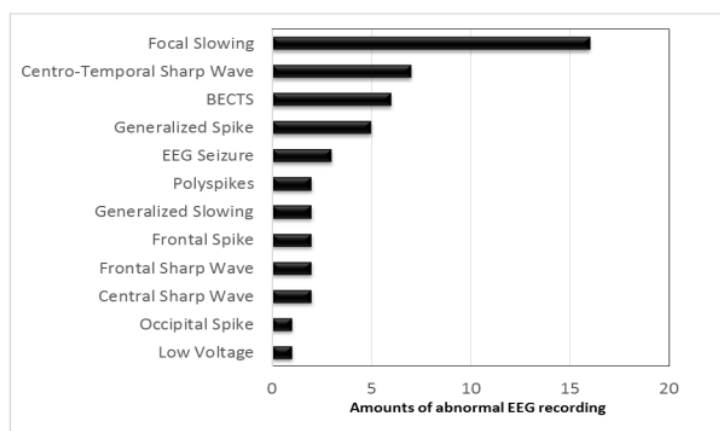


Figure 1: Classification of Abnormal EEG

The first seizure without provocation still holds a lot of mystery. The first seizure without provocation in this study can manifest as brief seizures, recurrent seizures, or long seizures of more than 30 minutes which is referred to as status epilepticus. Recurrent seizures which are still within 1 day are categorized as single seizures. Approximately, 10-12% of patients with FUS experience status epilepticus and the likelihood of status epilepticus is higher in FUS with recurrent seizures [10].

The FUS diagnosis is also enforced by ruling out other conditions that look alike seizures such as syncope, breath-holding spells, tics, migraines, infantile masturbation, and sleep disruption (parasomnias). Therefore, the ability to accurately describe seizures is required so that it can be distinguished whether these are seizures or other events that resembling a seizure. If seizure-like events have been ruled out, other causes of seizures should be traced before diagnosing FUS. In research, the FUS definition has been adapted to ILAE [2, 6].

Electroencephalography is advantageous to identify the type of seizures, help classify seizures, and predict long-term prognosis. EEG examination can be helpful in recognizing encephalopathy, subclinical seizures, and metabolic abnormalities. Performing an EEG examination can reveal focal epilepsy or lateralization abnormalities. If possible, an EEG should be obtained, while the patient is awake and asleep [11]. According to the ILAE, pediatric patients who have their first seizure whose EEG results show epileptiform activity and have remote symptomatic etiology, or structural brain abnormalities can be diagnosed with epilepsy [7]. This study showed 53.8% abnormal EEG results with 66.7% showing epileptiform activity. The study by Dusitanond yielded almost the same results, that is 57.4% abnormal EEG with a lower epileptiform activity around 28.6% [12]. A study from Portugal with a larger number of samples found 38% abnormal EEG data with 31% epileptiform activity in single FUS while in multiple FUS, the abnormality rate was higher [13]. According to Sansevere, the number of EEG

abnormalities in FUS summarized from various studies ranges from 40-60% [2].

Most EEG abnormal classifications that lead to epileptiform activity are focal slowing. Moreover, benign epileptiform centrottemporal spikes (BECTS) and generalized spikes were further found similar to this study where Pereira found that the type of epilepsy which frequently found was localization-related epilepsy with BECTS as the most common epilepsy syndrome. Besides, generalized epilepsy and other several specific epilepsy syndromes are also discovered [13]. In the population in Lebanon who undergo FUS, the abnormal location of EEG dominated by 88.9% of sharp waves was found more in the temporal area [14]. The same thing was found in a study in Vanadia which stated that 55.6% of the EEG abnormal locations were temporal areas [5].

Most children do not experience recurrent seizures after FUS. The risk of seizure recurrence is an important factor to be considered in dealing with children with FUS. Lawn stated that the duration of seizure-free period after FUS is associated with the recurrence risk. Most patients undergo a subsequent seizure episode after 3 months after the first event [15]. Several risk factors for the seizures recurrence in FUS include neurological abnormalities, epileptiform EEG appearance, and previous history of complex febrile seizures [10, 13].

Determining the recurrence risk after FUS is not easy. Sometimes detailed information to determine risk factors is not clear. A neurocutaneous syndrome is one of the clearest predictors of clinical manifestations. In this study, there were 2 neurocutaneous syndromes; namely, Strudge-Weber syndrome and Tuberous sclerosis. Strudge-Weber syndrome manifests as capillary-venous malformation with facial port-wine stain in trigeminal V1-V3 distribution, congenital glaucoma, and seizures that develop into intractable and progressive mental retardation [16]. In tuberculosis, 90% of patients manifest one or more cutaneous lesions such as hypomelanotic macules, facial angiofibromas, or fibrotic plaques. In central nervous system manifestation, seizures and epilepsy are the most common manifestations besides mental

retardation and behavioral problems [17]. In this study, these two syndromes still manifest as FUS with neurocutaneous manifestations.

The weakness of this study is that the EEG device used is not a long-term EEG monitoring model that has high sensitivity because this device is not available in Indonesia. While the strength of this study is that we do an EEG as soon as possible after the seizure occurs. This makes it possible to detect pathological abnormalities that cause seizures in more detail.

Conclusion

FUS in Indonesia mostly reported in boys than girls. Generalized seizures were commonly seen type of seizures. EEG interpretation is mostly abnormal that commonly showing epileptiform discharge. Most EEG abnormal classifications that lead to epileptiform activity are focal slowing. This can be a considerable of the possibility of recurrent seizure in later life.

Acknowledgements

The author would like to thank to pediatric residents of Soetomo Hospital for helping data collection.

Funding

This research did not receive any specific grant from funding agencies in the public, commercial, or not-for-profit sectors.

Author's contribution

All author contributed to conceptualization, data collection, drafting, analysis, manuscript writing, and final review of the manuscript.

Conflict of interest

The author declared no conflict of interest.

Orcid

Prastiya Indra Gunawan

<https://orcid.org/0000-0003-3199-2826>

Riza Noviandi

<https://orcid.org/0000-0002-8266-3099>

Sunny Mariana Samosir

<https://orcid.org/0000-0003-3584-6156>

References

- [1]. Villegas M.J., Garcia L.L., Moog J.C. Update on first unprovoked seizure in children and adults: A narrative review, *Seizure: European Journal of Epilepsy*, 2021, **90**:28 [Crossref], [Publisher]
- [2]. Sansevere A.J., Avalone J., Strauss L.D., Patel A.A., Pinto A., Ramachandran M., Fernandez I.S., Bergin A.M., Kimia A., Pearl P.L., Loddenkemper T., Diagnostic and therapeutic management of a first unprovoked seizure in children and adolescents with a focus on the revised diagnostic criteria for epilepsy, *Journal of child neurology*, 2017, **32**:774 [Crossref], [Google Scholar], [Publisher]
- [3]. Benn E.K.T., Hauser W.A., Shih T., Leary L., Bagiella E., Dayan P., Green R., Andrews H., Thurman D.J., Hesdorffer D.C., Estimating the incidence of first unprovoked seizure and newly diagnosed epilepsy in the low-income urban community of Northern Manhattan, New York City, *Epilepsia*, 2008, **49**:1431 [Crossref], [Google Scholar], [Publisher]
- [4]. Hauser W.A., Beghi E., First seizure definitions and worldwide incidence and mortality, *Epilepsia*, 2008, **49**:8 [Crossref], [Google Scholar], [Publisher]
- [5]. Vanadia A.P.A., Gunawan P.I., Abdurachman A., Utomo M.T., Hidayati H.B., Electroencephalogram in Children who Experienced First Unprovoked Seizure, *Aksona*, 2022, **2**:52 [Crossref], [Publisher]
- [6]. Ghofrani M., Approach to The First Unprovoked Seizure- PART II, *Iran J Child Neurol*, 2013, **7**:1 [Crossref], [Google Scholar], [Publisher]
- [7]. Chen T., Si Y., Chen D., Zhu L., Xu D., Chen S., Zhou D., Liu L., The value of 24-hour video-EEG in evaluating recurrence risk following a first unprovoked seizure: A prospective study, *Seizure*, 2016, **40**:46 [Crossref], [Google Scholar], [Publisher]
- [8]. Suryaningtyas W., Gunawan P.I., Subiyanto H., Turchan A., Parenrengi M.A., Lesson learned from early experience in pediatric epilepsy surgery service in Surabaya, Indonesia, *Neurology Asia*, 2020, **25**:89 [Google Scholar], [Publisher]
- [9]. Gunawan P.I., Widjaya N.A., Lennox Gastaut Syndrome with Bilateral Temporo-Parietal Encephalomalacia Cyst in a Child: The First

- Indonesian Report, *Journal of International Dental and Medical Research*, 2021, **14**:1276 [[Google Scholar](#)], [[Publisher](#)]
- [10]. Melati D., Suwarba I.G.N., Sutriani D., Kari K., First Unprovoked Seizure in Children, *Jurnal Ilmiah Kedokteran*, 2014, **45**:93 [[Publisher](#)]
- [11]. Debicki D.B., Electroencephalography after a single unprovoked seizure. *Seizure*, 2017, **49**:69 [[Crossref](#)], [[Google Scholar](#)], [[Publisher](#)]
- [12]. Dusitanond P. Abnormal electroencephalography in first unprovoked seizure in Rajavithi Hospital, *Journal of the Medical Association of Thailand= Chotmaihet Thangphaet*, 2013, **96**:S42 [[Google Scholar](#)], [[Publisher](#)]
- [13]. Pereira C, Resende C, Fineza I, Robalo C. A 15-year follow-up of first unprovoked seizures: a prospective study of 200 children, *Epileptic Disord*, 2014; **16**:50 [[Crossref](#)], [[Google Scholar](#)], [[Publisher](#)]
- [14]. Bhuyan R., Jahan W., Upadhyaya N., Interictal wave pattern study in EEG of epilepsy patients, *International Journal of Research in Medical Sciences*, 2017, **5**:3378 [[Crossref](#)], [[Google Scholar](#)], [[Publisher](#)]
- [15]. Lawn N., Chan J., Lee J., Dunne J., Is the first seizure epilepsy—and when?, *Epilepsia*, 2015, **56**:1425 [[Crossref](#)], [[Google Scholar](#)], [[Publisher](#)]
- [16]. Mamatha P., Mariappan N., Tanitia K., Shekar D.R., Sturge-weber syndrom: review of literature, *Journal of Evolution of Medical and Dental Sciences*, 2015, **4**:14086 [[Crossref](#)], [[Publisher](#)]
- [17]. Gunawan P.I., Saharso D., Unusual location of fibrous plaque in Indonesian child with tuberous sclerosis complex, *Pan African Medical Journal*, 2017, **28**:92 [[Crossref](#)], [[Google Scholar](#)], [[Publisher](#)]

HOW TO CITE THIS ARTICLE

Prastiya Indra Gunawan, Riza Noviandi, Sunny Mariana Samosir, First Unprovoked Seizure in Indonesian Children. *J. Med. Chem. Sci.*, 2023, 6(8) 1909-1914

DOI: <https://doi.org/10.26655/JMCHMSCI.2023.8.19>

URL: http://www.jmchemsci.com/article_167352.html

First Unprovoked Seizure in Indonesian Children

ORIGINALITY REPORT

11%

SIMILARITY INDEX

8%

INTERNET SOURCES

6%

PUBLICATIONS

0%

STUDENT PAPERS

PRIMARY SOURCES

1	www.bmrat.org Internet Source	1%
2	link.springer.com Internet Source	1%
3	Rafid R. Arraq, Angham G. Hadi, Dina S. Ahmed, Gamal A. El-Hiti et al. "Enhancement of Photostabilization of Poly(Vinyl Chloride) in the Presence of Tin–Cephalexin Complexes", <i>Polymers</i> , 2023 Publication	1%
4	www.researchsquare.com Internet Source	1%
5	ethnobiomed.biomedcentral.com Internet Source	1%
6	mafiadoc.com Internet Source	1%
7	Arnold J. Sansevere, Jennifer Avalone, Lauren Doyle Strauss, Archana A. Patel et al. "Diagnostic and Therapeutic Management of a First Unprovoked Seizure in Children and	1%

Adolescents With a Focus on the Revised Diagnostic Criteria for Epilepsy", Journal of Child Neurology, 2017

Publication

8	Prastiya Indra Gunawan, Claudia Magdalena Felisia Kurube, Riza Noviandi, Sunny Mariana Samosir. "Electroencephalography Patterns in Children with First Unprovoked Seizure", Research Square Platform LLC, 2021 Publication	1 %
9	akjournals.com Internet Source	1 %
10	journal.uwks.ac.id Internet Source	<1 %
11	www.nejm.org Internet Source	<1 %
12	ruj.uj.edu.pl Internet Source	<1 %
13	www.jidmr.com Internet Source	<1 %
14	e-journal.unair.ac.id Internet Source	<1 %
15	www.scribd.com Internet Source	<1 %
16	Derek B. Debicki. "Electroencephalography after a single unprovoked seizure", Seizure,	<1 %

2017

Publication

17

Miral A. Al Momani, Basima Almomani, Salar Bani Hani, Andrew Lux. "Recurrence of First Afebrile Unprovoked Seizure and Parental Consanguinity: A Hospital-Based Study", *Journal of Child Neurology*, 2020

Publication

<1 %

Exclude quotes On

Exclude matches Off

Exclude bibliography On

First Unprovoked Seizure in Indonesian Children

GRADEMARK REPORT

FINAL GRADE

/100

GENERAL COMMENTS

Instructor

PAGE 1

PAGE 2

PAGE 3

PAGE 4

PAGE 5

PAGE 6
