

Pseudomonas Pseudoalcaligenes Caused Otogenic Cerebellar Brain Abscess In Indonesian Child

by Prastiya Indra Gunawan

Submission date: 14-Feb-2023 03:09PM (UTC+0800)

Submission ID: 2013877356

File name: Caused_Otogenic_Cerebellar_Brain_Abscess_In_Indonesian_Child.pdf (865.28K)

Word count: 1480

Character count: 8845

Pseudomonas Pseudoalcaligenes Caused Otogenic Cerebellar Brain Abscess In Indonesian Child

Prastiya Indra Gunawan¹, Achmad Chusnu Romdhoni²

¹Lecturer, Head of Pediatric Neurology Division, Department of Child Health, Universitas Airlangga, College of Medicine, Dr Soetomo General Academic Hospital, Surabaya, Indonesia, ²Lecturer, Department of Ear, Nose and Throat, Universitas Airlangga, College of Medicine, Dr Soetomo General Academic Hospital, Surabaya, Indonesia

Abstract

Otogenic brain abscess is a common intracranial complication from chronic suppurative otitis media. *Pseudomonas pseudoalcaligenes* is a rare cause of brain abscess. Prompt diagnosis and decision making is significant in order to decrease the mortality rate from this type of abscess. We described A 13-year-old boy presented with decreased consciousness, positive meningeal signs, and pathological reflexes. There was a history of chronic suppurative otitis media. A head CT scan revealed multiple left cerebellar abscesses and brain edema. The abscess wall culture revealed *P. pseudoalcaligenes*. After being managed with surgical abscess drainage, mastoidectomy, ear flushing, and antimicrobial therapy for six weeks, his consciousness level improved. Cerebellar neurological impairment was still observed. Physical and neurological rehabilitation was performed in order to improve the patient's condition.

Keywords: cerebellar abscess, *Pseudomonas pseudoalcaligenes*, antimicrobials, drainage

Introduction

Otogenic brain abscess is common intracranial complication of chronic suppurative otitis media. it occurs mostly at temporal lobe or cerebellum, ipsilateral to the infected ear.^{1,2} Among all suppurative otitis media complication, the incident of brain abscess is the second highest (25%) with 10% of abscess located in cerebellum.¹ Factors associated with high mortality are the lack of neuroimaging facilities, infant less than one year of age, multiple abscess, and comatose state. *Streptococci* (both aerobic and anaerobic) are the most common pathogens from the bacterial abscess culture.¹ The presence of *Pseudomonas pseudoalcaligenes* in the brain is uncommon. *P.pseudoalcaligenes* is an aerobic-negative soil organism, motile by polar flagella, taxonomically placed in the P.aeruginosa group by

16S rRNA analysis.³ We present this as the first report of *Pseudomonas pseudoalcaligenes* associated with otogenic cerebellar abscess in Indonesian child.

⁸ Case Report

A 13 year-old boy admitted to Emergency Department with chief complaint decreased of consciousness. There were history of fever, vomiting, severe headache and difficulty of walking few days before. The patient had experienced pain on the left ear, followed by foul-smelling purulent ear discharge on the previous two months. Physical examinations revealed unconscious boy with body temperature of 39⁰C. Positive pathological reflexes and increased of physiological reflexes were present. There was perforation in left eardrum, with purulent liquid of cholesteatoma and edematous mastoid region. The leukocyte count was of 19,400/ μ L, and C-reactive protein of 145 mg/L. Head CT scan showed multiple contrast-enhanced hypodense lesions in left cerebellum and brain edema.

Corresponding Author:

Prastiya Indra Gunawan ⁴

Institution affiliation: Uniersitas Airlangga, College of Medicine, Jl. Prof Dr Moestopo 6-8 Surabaya Indonesia 60286, Email: prastiya_ig@yahoo.co.id
Telephone +628113429476

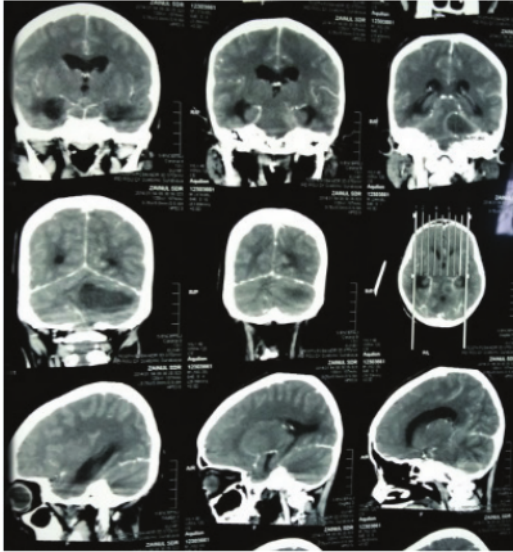


Figure 1. Head CT scan showed multiple contrast-enhanced hypodense lesions in left cerebellum and brain edema.

Mastoidectomy was done and extradural abscess was drained. The isolation of capsule wall culture revealed *Pseudomonas pseudoalcaligenes* and the culture from abscess pus was sterile. Six weeks antimicrobial therapy with ceftriaxone and metronidazole were instituted appropriate with antibiotic sensitivity test along with ofloxacin ear drops and ear toilet with H₂O₂ 3% for the left infected ear. Phenytoin was given for terminating the seizure. Mannitol was administered to reduce brain edema.

After surgery, the patient condition was improved. However, the symptoms of cerebellar dysfunction was still observed. Head CT scan evaluation indicated reducing of cerebellar abscess size formation. The patient was trained for physical rehabilitation in order to improve neurological function.

Discussion

In this case the intracranial abnormality was most likely complication of the infected ear. Chronic suppurative otitis media is a chronic infection of the middle ear cleft that is defined by three elements which are perforation of the tympanic membrane due to acute infection or tympanotomy, discharge from the middle ear (otorrhea), and prolonged duration. It can

be divided into 2 types, benign and malignant type. Fatal complication may occur in malignant type such as intracranial complication. Before the introduction of microbial era, 2.3% of all chronic otitis media developed intracranial complication.⁴

Brain abscess may develop from three sources: First, it may spread from the pericranial contiguous infection focus (25-50% of cases) such as the sinuses, middle ear, or dental infection. Hematogenous spread from a distant focus is the second most common source of infection. Third, in 8-19% of cases, it may come from direct inoculation, such as in head trauma or neurosurgery.⁵ In this case, the origin of cerebellar abscess was considered from the left ear infection. According to a review by Shaw et al, 93% of the cerebellar abscess were secondary to otogenic disease, and less common was complication of tonsils and septicemia.⁶ The possible routes of infection in otogenic cerebellar abscess are considered as direct extension from suppurative labyrinthitis, and as retrograde thrombosis from the lateral, the inferior petrosal, or superior petrosal sinuses.

Pseudomonas pseudoalcaligenes was isolated from the brain abscess wall. It is an aerobic, gram negative bacterium that was relatively uncommon to cause brain infection. Cowlishaw et al reported an alkali-producing pseudomonad which closely resembles *Pseudomonas pseudoalcaligenes* in an 8-month-old female infant with bacterial meningitis.⁷ It was the first case of *Pseudomonas pseudoalcaligenes* that isolated from cerebrospinal fluid and showed its pathogenicity. The patient was treated with gentamycin intravenously and chloramphenicol intravenously and resulted uncomplicated recovery. Pedersen reported the recovery of this organism from many clinical specimens but in none of these instances was it considered to be pathogenic.⁸ Hage et al reported the presence of *Pseudomonas pseudoalcaligenes* in peritoneal dialysis-associated peritonitis.³ Basically, the microbial etiology depends on how the abscess develops and whether the patient is immunocompromised or not. *Streptococci* (both aerobic and anaerobic) are the most common pathogens, comprising about 70% of isolates cultured from bacterial abscess. Sterile microbial culture of abscess pus of the case represents a relatively high rate of sterile cultures, which varied between 10%

and 32% in the literature. This may be explained by prior antibiotic treatment, the difficulty in isolating anaerobic microorganisms or inadequate sampling technique.⁹

Successful management of the disease should include local drainage of the abscess and administration of systemic antibiotic which can cross blood-brain and blood-CSF barriers in adequate concentrations. The empirical antibiotics should include coverage for anaerobic pathogens, such as a third-generation cephalosporin and metronidazole and should be able to cleanse the primary focus of infection.^{1,10} In addition, steroid, anti edema and anti epileptic drugs should be administered. The abscess drained through the radical mastoid cavity following the route of infection using aspiration technique, combining two procedures of draining and cleansing. The candidates for medical treatment to be those with a small abscess (<2.5 cm), in good initial clinical condition (GCS > 12), and for whom the etiology is well-known (microorganism isolated from material other than the abscess pus). In the case of multiple abscesses, candidates are those who after surgery abscesses is >2.5 cm or cause a mass effect, or those at serious risk of operation with bad prognosis.^{5,6,10} A careful examinations should perform in every case of ear infections to prevent further complications.

¹³ **Ethical Clearance:** Informed consent for publishing was taken from patient.

Source of Funding: Self

Conflict of Interest: Nil

References

1. Miranda H., Castellar L., Elzain MA. Brain abscess: current management. *J Neurosci Rural Pract* 2013;4:67-81.
2. Menon S, Bharadwaj R, Chowdhary A, Kaundinya DV, Palande DA. Current epidemiology of intracranial abscesses: a prospective 5 year study. *J Med Microbiol* 2008;57:1259-68.
3. Hage JE, Schoch PE, Cunha BA. Pseudomonas pseudoalcaligenes peritoneal dialysis-associated peritonitis. *Perit Dial Int* 2013;33:223-4.
4. Kangsanarak J., Foonant S., Ruckphaopunt K. Extracranial and intracranial complications of suppurative otitis media. Report of 102 cases. *J Laryngol Otol* 1993;107:999.
5. MathisenGE., Johnson JP. Brain abscess. *Clin Infect Dis* 1997 ;25:763-79.
6. Shaw M., Russell J. Cerebellar abscess: review of 47 cases. *Journal of Neurology, Neurosurgery, and Psychiatry* 1975;38:429-35.
7. Cowlishaw WA, Hughes ME, Simpson HCR. Meningitis caused by an alkali-producing pseudomonad *J Clin Path* 1976;29:1088-90.
8. Pedersen MM, Marso E, Pickett MJ. Nonfermentative bacilli associated with man. III. Pathogenicity and antibiotic susceptibility. *Amer J Clin Path* 1970;54:178-92.
9. Sabatini P, Dietz KC, Noplock AM, Montalbano J. Gram – negative bacilli : nonfermenters. In Engelkirk PG, Engelkirk JLD editors. *Laboratory diagnosis of infectious diseases: Essentials of diagnostic microbiology*. Lippincott Williams & Wilkins; Philadelphia; 2008 p 319-34.
10. Ashoor AA. Otogenic brain abscess management. *Bahrain Medical Bulletin*. 2005; 27(1):30-5.

Pseudomonas Pseudoalcaligenes Caused Otogenic Cerebellar Brain Abscess In Indonesian Child

ORIGINALITY REPORT

15%

SIMILARITY INDEX

9%

INTERNET SOURCES

13%

PUBLICATIONS

0%

STUDENT PAPERS

PRIMARY SOURCES

- 1 Abdul Khairul Rizki Purba, Nina Mariana, Gestina Aliska, Sonny Hadi Wijaya et al. "The burden and costs of sepsis and reimbursement of its treatment in a developing country: An observational study on focal infections in Indonesia", *International Journal of Infectious Diseases*, 2020
Publication 1%
- 2 J.E. Hage, P.E. Schoch, B.A. Cunha. "Pseudomonas Pseudoalcaligenes Peritoneal Dialysis–Associated Peritonitis", *Peritoneal Dialysis International: Journal of the International Society for Peritoneal Dialysis*, 2020
Publication 1%
- 3 Grace Hsu, Jie Zhang, Firat Selvi, Neil Shady, Meredith August. "Do brain abscesses have a higher incidence of odontogenic origin than previously thought?", *Oral Surgery, Oral Medicine, Oral Pathology and Oral Radiology*, 2020 1%

4

Prastiya Indra Gunawan, Darto Saharso. "A case of juvenile dermatomyositis responding to methotrexate and steroid", Bangladesh Journal of Medical Science, 2018

Publication

1 %

5

hdl.handle.net

Internet Source

1 %

6

Sharon E. Mace. "Central Nervous System Infections as a Cause of an Altered Mental Status? What is the Pathogen Growing in Your Central Nervous System?", Emergency Medicine Clinics of North America, 2010

Publication

1 %

7

Agung Dwi Laksono, Ratna Dwi Wulandari. "Relationship between Environment, Smoking Behavior, Education, Poverty, and Prevalence of Stunted Toddler in Indonesia: An Ecological Analysis", Research Square, 2020

Publication

1 %

8

surgicalneurologyint.com

Internet Source

1 %

9

www.yumpu.com

Internet Source

1 %

10

www.mdpi.com

Internet Source

1 %

| | | |
|----|--|------|
| 11 | ijop.net Internet Source | 1 % |
| 12 | pubmed.ncbi.nlm.nih.gov Internet Source | 1 % |
| 13 | www.ijphrd.com Internet Source | 1 % |
| 14 | M D Shaw, J A Russell. "Cerebellar abscess. A review of 47 cases.", <i>Journal of Neurology, Neurosurgery & Psychiatry</i> , 1975 Publication | <1 % |
| 15 | Ronald Alastair McNeill. "The Protective Properties of Fat and Gelfoam as Oval Window Grafts", <i>The Journal of Laryngology & Otology</i> , 2007 Publication | <1 % |

Exclude quotes On

Exclude matches Off

Exclude bibliography On

Pseudomonas Pseudoalcaligenes Caused Otogenic Cerebellar Brain Abscess In Indonesian Child

GRADEMARK REPORT

FINAL GRADE

/100

GENERAL COMMENTS

Instructor

PAGE 1

PAGE 2

PAGE 3
