

# Ovarian Malignant Brenner Tumor

*by* Romi Alfianto

---

**Submission date:** 03-Apr-2023 10:52PM (UTC+0800)

**Submission ID:** 2054665309

**File name:** Ovarian\_Malignant\_Brenner\_Tumor.pdf (490.4K)

**Word count:** 5887

**Character count:** 31264

## CASE REPORT:

### Ovarian Malignant Brenner Tumor

Romi Alfianto<sup>1</sup>, Alphaia Rahniayu<sup>2</sup>, Indra Yulianti<sup>\*1</sup>

<sup>1</sup>Department of Obstetrics and Gynecology, Faculty of Medicine, Universitas Airlangga, Dr Soetomo Hospital, Surabaya, Indonesia. <sup>2</sup>Department of Anatomic Pathology, Faculty of Medicine, Universitas Airlangga, Dr Soetomo Hospital, Surabaya, Indonesia.

#### ABSTRACT

**Objectives:** To report one malignant Brenner tumor (MBT) case in Dr. Soetomo Hospital, Surabaya, Indonesia, that underwent therapy from August 2016 to August 2017.

**Case report:** A woman aged 62 years underwent total abdominal hysterectomy and bilateral salphingo-oophorectomy surgery with histopathologic results of malignant Brenner Tumor. From immunohistochemical examination the expression of p63 was positive. The patient had been treated with Paclitaxel carboplatin chemotherapy for 5-cycles, with the results of the last post-chemotherapy evaluation showing no recidive mass.

**Conclusion:** There was only one case of malignant ovarian Brenner Tumor in Dr Soetomo Hospital, Surabaya, Indonesia, in 2014- 2016. The diagnosis can only be based on anatomic pathology examination. The specific tumor markers for malignant Brenner tumors have so far not been found.

**Keywords:** Malignant Brenner Tumor; epithelial ovarian tumor; p63.

**\*Correspondence:** Indra Yulianti, Departemen of Obstetrics and Gynecology, Faculty of Medicine, Universitas Airlangga, Dr. Soetomo Hospital, Jalan Prof dr Moestopo 6-8, Surabaya 60286, East Java, Indonesia. E-mail: indrayuliatialif@yahoo.com

#### ABSTRAK

**Tujuan:** Melaporkan satu kasus pasien dengan tumor Brenner di RSUD Dr. Soetomo, Surabaya, Indonesia, yang menjalani terapi dari bulan Agustus 2016 hingga Agustus 2017.

**Laporan kasus:** Seorang wanita berusia 62 tahun menjalani histerektomi abdominal total dan operasi salphingo-ooforektomi bilateral dengan hasil histopatologis Tumor Brenner ganas. Dari pemeriksaan imunohistokimia, ekspresi p63 didapatkan positif. Pasien telah dirawat dengan kemoterapi Paclitaxel carboplatin selama 5 siklus, dengan hasil evaluasi post-kemoterapi terakhir tidak menunjukkan massa residif.

**Simpulan:** Hanya terdapat satu kasus Tumor Brenner ovarium ganas di RSUD Dr Soetomo, Surabaya, Indonesia, antara 2014- 2016. Diagnosis hanya dapat didasarkan pada pemeriksaan patologi anatomi. Penanda tumor spesifik untuk tumor Brenner ganas sejauh ini belum ditemukan.

**Kata kunci:** Tumor Brenner ganas; tumor epitel ovarium; p63

## INTRODUCTION

Based on GLOBOCCAN 2012 data, ovarian cancer was ranked as the seventh most common cancer in women in the world with 239,000 cases (3.6%), and the eighth leading cause of cancer deaths among women in the world with 152,000 deaths (4.3%) in 2012. The incidence of ovarian cancer was higher in developing countries, which was about 7.5 per 100,000. The risk of death from ovarian cancer before age 75 was higher in developing countries than in developed countries. Based on GLOBOCCAN 2012 data, in Southeast Asia, there were 19,900 new cases of ovarian cancer and 13,000 deaths from ovarian cancer. Ovarian cancer is the fifth leading cause of death in women in the world.<sup>1</sup> In Indonesia, ovarian cancer ranked third of all cancers in women, with most of the patients (46.3%) were diagnosed in stage III.<sup>2</sup> The most common histologic type of the ovarian cancer was epithelial (89.7%).<sup>3</sup>

18  
Epithelial ovarian cancer is the most common type of ovarian cancer with a variety of cell types. One subclassification of the rarest epithelial ovarian cancer is a transitional epithelial type known as Brenner's tumor. This type was first discovered in 1907 by Fritz Brenner. The Brenner tumor is currently classified into three types: benign, borderline and malignant. Brenner tumor is found in only about 1-2% of all cases of ovarian neoplasms. Of all the reported cases of Brenner tumor, malignant types was found in less than 5% so that until now specific management and appropriate treatment of the chemotherapy is still unclear.<sup>4</sup>

In this case report we found one malignant Brenner tumor (MBT) case in Dr. Soetomo Hospital, Surabaya, Indonesia, who underwent therapy from August 2016 to August 2017. Retrospectively, based on the data from anatomic pathology examination results, from 2014 to 2016 there were only one malignant Brenner tumor (0.2%) of totally 403 cases ovarian epithelial cancer in Dr. Soetomo Hospital, Surabaya.

## CASE REPORT

During the three-year period (2014-2016) in Dr. Soetomo Hospital, there was one case of epithelial ovarian tumor with MBT type. This case was a referral one from Jombang Hospital. The patient Mrs T, aged 62, complained of a stomach discomfort and palpable mass from lower right abdomen for one month (June 2016). The patient came to a general practitioner, who found a possibility of ovarian cyst and recommended the patient to be examined by an obstetrician. On early August 2016, the patient first visited the gynecology outpatient clinic in Jombang Hospital. On gynecological examin-

ation there was palpable adnexal mass on the right side with diameter 10 cm, mobile, and no pain.

26  
Ultrasonography results revealed uterus size of 5.8 x 5.4 x 3.6 cm, hyperechoic mass size 1.5 x 2.4 cm. Right adnexal parameters revealed mass size 10x15 cm, cystic with solid component, positive septa and negative papillae (-). Left adnexal parameters showed no mass. In conclusion, the patient had uterine myoma and dextral ovarian cyst. On 25 August 2016, the surgery was performed by the gynecologist in Jombang Hospital.

Findings during the surgery were as follows: The uterus had normal size, subserous myoma sized 2 cm. Dextral adnexa showed cystic mass sized 10 x 15 cm, adhesion with uterus and sigmoid colon. The adhesion was released, so the cyst was ruptured, revealing yellowish fluid. The sinistral adnexa was within normal limit. The liver was smooth. We decided to perform total abdominal hysterectomy and bilateral salpingo-oophorectomy.

Macroscopic histopathology results on 5 September 2016 was one container with one piece of uterine tissue equipped with both adnexa, total weight 300 grams, sized 9 x 6 x 5 cm, 3 cm cervical diameter. On the incision revealed subserous tumor in 1.5 cm diameter, with clear solid white rubbery border. The right adnexa showed tubal length of 5 cm and 0.5 cm in diameter. The ovarian cysts have been splitted 14 cm in diameter with brownish rough surface. On the slices appear solid tumors with brittle white gray colour. The border clearly penetrate the capsule. Left adnexal showed tubal length of 5 cm, diameter 0.5 cm, and the ovarium size of 2 x 1 x 1 cm.

Microscopic histopathology showed that the cervix had no apparent normality. The endometrium showed endometrial tissue fragments with proliferative phase glands, and solid stroma. On other pieces of visible glands and endometrial stromas in sub serous myometrial tissue. Dextral adnexa showed ovarian cyst wall with malignant tumor growth, consists of the proliferation of anaplastic cells, round cell shape, pleomorphic core, prominent nucleus, separated fibrous connective tissue bins infiltrated with lymphocyte cells. The tube was without apparent abnormalities. Sinistral adnexa showed that the tube was without apparent abnormalities, while the ovary showed corpus albicans. We concluded that the patient had dysgerminoma, and sub-serous uterine leiomyoma. The patients was referred to Dr. Soetomo Hospital for further treatment.

On 13 September 2016, the patient came to Oncology Gynecology Outpatient Clinic, Dr. Soetomo Hospital.

The patient was diagnosed with ovarian cancer (dysgerminoma), post TAH-BSO.

Table 1. Laboratory examination results

Hemoglobin	9.47	Fasting glucose/post prandial	147/195
Leukocytes	9.16	BUN / SK	24/0.6
Thrombocytes	401.000	SGOT/SGPT	12/11
Albumin	4.1	LDH	162
B-HCG	3.16	AFP	3.5

Thoracic X-ray showed no metastasis process, previous lung inflammation, atherosclerosis, and high left hemidiaphragm. Abdominal pelvic CT-Scan showed no residue/residual mass in abdomen and pelvic cavity, and no metastasis process in liver and visualized bone. On 4 October 2016, macroscopic histopathology review results in Dr. Soetomo Hospital lead the patient to receive 8 blocks of paraffin no. Jo. 677/16 I-VIII. The block was repeated and the slides were re-read.

Microscopic results in slide I showed pieces of endocervic tissue coated with columnar epithelium. Fibrous connective tissue stroma contained endocervical glands. Slide II and III showed endometrial tissue with proliferative gland phase, myometrium contains benign growth of benign tumor composed of smooth muscle cell proliferation, rounded nucleus, oval spindle, fine chromatin, sufficient cytoplasm, arranged in the fascicles. There was no sign of malignancy. Slide IV showed the tube with no apparent abnormalities. The ovary was with corpus albicans. All slides V to VIII showed similar features of tissue pieces containing malignant tumor growth consisting of anaplastic transitional epithelial cell proliferation, in oval rounded shape, pleomorphic, hyperchromatic, mitotic, arranged in solid and papillary structures, and grew invasively into the stroma. We could not evaluate whether the tumor penetrated out of the capsule. There were also the tube and corpus albicans. We concluded that the patient had ovarian malignant Brenner Tumor and uterine myoma. Tumor marker results before chemotherapy were as follows: CA-125: 13.6 u/ml, CEA: 1.45 u/ml, and CA 19-9: 9.89 u/ml. Hematoxylin and eosin (HE) staining result is as seen in Figure 1, while the p63 immunohistochemistry result is displayed in Figure 3.

The patient underwent five cycles of paclitaxel carboplatin chemotherapy from 6 cycles that was planned before because of bad compliance of the patient from 17 October 2016 to 30 May 2017. Ultrasono-graphy evaluation after the 3rd chemotherapy revealed no solid/cystic residue mass, no metastatic process in liver and lymph node enlargement in paraaorta, and no apparent abnormalities of the live, gall bladder, pancreas,

right and left kidney, and the bladder. CA-125 evaluation after 3rd chemotherapy: 16.8 u/ml. Abdomen and pelvic CT-scan evaluation after 5th chemotherapy showed no residue mass, and CA-125 evaluation after 5th chemotherapy was found to be 14.2 u/ml.

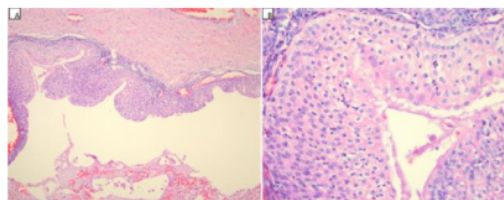


Figure 1. (A). The presence of a benign Brenner tumor component which is a cystic area coated with transitional epithelial cells with no atypical marker with extensive fibromatous stroma (HE, 100x). (B). The benign Brenner component consists of transitional epithelial cells with oval nuclei, fine chromatin, and clear cytoplasm (HE, 400x).

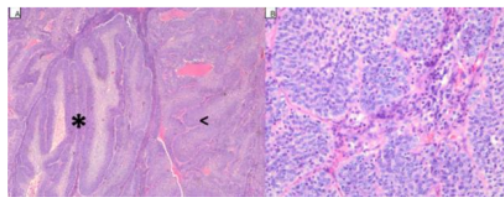


Figure 2. (A) Left side of (\*) appears Brenner borderline tumor adjacent to MBT (mark <). Borderline Brenner tumors were arranged in a dense papillary structure (HE, 100x). (B) MBT, which consists of transitional epithelial cells with anaplasia marks, was arranged in an irregular lair and accompanied by stromal invasion (HE, 400x).

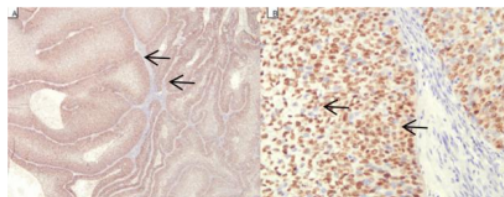


Figure 3. Immunohistochemistry staining with p63 antibody. (A) The tumor cells are positively stained both in borderline and malignant components (HE, 100x) (B). The core of tumor cells was brown stained (HE, 400x).

## DISCUSSION

Based on the data in Gynecological Oncology Division of Dr. Soetomo Hospital, Surabaya, from 2014-2016, ovarian epithelial cancer was the most common type of ovarian cancer histopathology with 89.4%, while non epithelial was only 10.6%. Of the total epithel cancers of the ovaries, the serous papillary type is the most common (34.7%), while the mucinous type was 22.8%, the endometrioid was 18.3%, clear cell carcinoma was 10.4%, Brenner tumor was 0.2% and non-specific ovarian tumor was 13.60%. Although ovarian epithelial tumors was the most common type of ovarian tumor found in Dr. Soetomo Hospital, but MBT histopathology type was the rarest one, since 3 years there were only 1 case (0.2%) of total ovarian epithelial cancer. In the literature it was also said that MBT was the rarest case with only about 1-2% of the total cases of ovarian tumors, usually found benign and very rarely found malignant.<sup>5</sup> Bean et al researched retrospectively to see the epidemiology of MBT based on population data from 1973 to 2012, there were 200 cases of women diagnosed with MBT, of which 164 patients (82%) were found in white race, 21 patients (10.5%) were black race, 3 patients (1.5%) were indian race, and 12 patients (6%) were asian. By age, 30 patients (15%) were diagnosed before the age of 50 years and 170 patients (85%) were diagnosed at the age of more than 50 years. The patient we reported was also 62 years old, according to Bean et al the highest incidence of MBT were at age above 50 years.<sup>6</sup>

### Malignant Brenner tumor diagnosis

It is difficult to diagnose MBT prior to surgery because the tumor has no typical clinical, laboratory and imaging features. Patients with MBT also rarely cause a typical complaint except the palpable mass on the abdomen.<sup>7</sup> These tumor symptoms are similar to other ovarian cancers but are rarely accompanied with ascites or pleural effusions. In the case we reported, the patient complained abdomen enlargement in Jombang Hospital, routine gynecological examination found mass on the right adnexa and on ultrasound images found cystic mass with solid component inside. Due to limitations of local hospitals, no tumor marker evaluation prior to the surgery. In the literature the principle of ovarian tumor management was anamnesis, physical examination, imaging, and laboratory and tumor marker.<sup>8</sup>

### Malignant Brenner tumor symptoms

7  
The most important symptom found in ovarian tumors is the presence of pelvic mass on physical examination. Dense or cystic mass, fixed on the pelvis is very possible is an ovarian tumor. If the mass is enlarged to

the upper abdomen and accompanied by ascites, it is almost certainly an ovarian tumor. In the case we reported the patient complained of a abdominal enlarged within 3 months, pain (-), vaginal bleeding (-). Verma et al also reported a 60-year-old woman with a post-operative diagnosis of MBT, the patient also had the same symptoms as the patient we reported which was abdominal mass that grew 3 months prior to surgery and on a palpable examination there were mass from a pelvic cavity measuring 10x10cm with cystic consistency, no vaginal bleeding, no lymphadenopathy and at laparotomy there were 8x8 cm mass coming from the right ovary, ascites (-), and then performed TAH-BSO-omentectomy and lymph node biopsy.<sup>9</sup> Gescinc et al in his study analyzed 13 MBT patients found from 2004 to 2010, most of the patients had abdominal pain (6 of 13 patients/46.2%), 2 patients (15.4%) complained of abdominal distension, 1 patient ( 7.7%) with post menopausal bleeding, 1 patient (7.7%) with irregular menstruation, and 1 patient (7.7%) had no complaints. Histologic endometrial hyperplasia has been reported in 4-14% of women affected by MBT. Fox and colleagues reported cases with abnormal uterine bleeding in MBT associated with mild to moderate degrees of endometrial hyperplasia.<sup>10</sup>

### Malignant Brenner tumor imaging

23  
It is very difficult to diagnose Brenner tumors by using imaging. Both ultrasound and CT-Scan have limitations in specificity to diagnose because MBT has no specific features. In this case report based on ultrasound data there was a unilateral cystic tumor with solid components and also no has a special feature. Nasioudis et al in his study from a total of 207 patients diagnosed with MBT from 1988 to 2012, 174 patients (84.1%) had unilateral MBT sites, 26 with bilateral sites (12.6%) and 7 patients (3.3%) patients with unknown origin of the tumor.<sup>11</sup>

Dierick et al attempted to look at the characteristics of Brenner ovarian tumors through retrospective studies using data from the International Ovarian Tumor Analysis (IOTA). Based on histopathologic results diagnosed with postoperative Brenner ovarian tumor, 28 patients with 29 Brenner tumors were included in the inclusion criteria. The study found 24 tumors (83%) were benign, 2 tumors (7%) borderline, and 3 tumors (10%) malignant. Of 24 benign Brenner tumors, 17 of them (71%) contained a solid component therein, whereas in Brenner borderline and malignant tumors only (3 of 5 tumors/60%) contained a solid component. On examination with Doppler velocimetry in benign Brenner tumors there was no increase or minimal vascularization, whereas in Brenner borderline and malignant tumors showed increased vascularization.

Calcification was found in 15 of 24 benign Brenner tumors (62.5%), whereas in malignant borderline and tumors calcification was found in 3 of 5 patients (75%). However, the study failed to demonstrate a specific feature of Brenner's tumor and required a prospective study to if imaging features could differentiate Brenner's tumor and other ovarian tumors.<sup>7</sup>

In the case we reported, the MBT was found unilaterally in the right ovary. The imaging before surgery in this case report was found only from an ultrasound report. The cystic mass size in this patient was about 10x15 cm, with a solid component inside, with septa (+), papil (-). The size of the tumor based on a macroscopic examination in anatomic pathology report was about 14 cm, this finding corresponding to the literature that says the MBT size is usually more than 10 cm (15-20 cm).<sup>12</sup>

### Tumor marker in malignant Brenner Tumor

Ovarian tumor should be distinguished from malignant and benign neoplasms or functional cysts. CA-125 serum levels may be used to distinguish benign or malignant pelvic mass. In post menopausal women the normal value of CA-125 is <25 U/ml whereas in pre menopausal women is <35 U/ml. In postmenopausal women with an adnexal mass and a very high level of CA-125 (> 200 U/ml) the positive predictive value for malignancy is 96% whereas in women with pre-menopausal adolescents the specificity of CA-125 is lower, since CA-125 may also increased in some circumstances. Therefore, in pre-menopausal women, further observation is possible if the adnexa mass does not show malignancy feature (mobile, cystic, unilateral, and regular) and the size is less than 8 cm, and may be re-evaluated 2 months later and given combined contraceptive pills to suppress ovulation, if an increase in the size of the mass at the time of evaluation, the surgery must be performed.<sup>8</sup>

Brenner tumor is a rare case, so there is no specific tumor marker specific to this tumor. In this case report, there were no data about tumor marker prior to the surgery. After the surgery, the results of tumor marker was CA-125: 13.6 ug/ml, CEA: 1.45 ul/ml CA 19-9: 9.89 u/ml, of these results showed no increase in tumor markers. After the 5th chemotherapy, evaluation tumor markers are still within normal limit (CA-125: 14.2 u/ml).

Until now specific tumor markers for MBT have not been found, related to the scarcity of the cases. CA-125 increases in some cases of MBT but not all of them, the reported data is only about 30-70% of cases, but not related to the stage or the size of the tumor. Despite low sensitivity (50-62%) and moderate specificity (94-

98.5%), CA-125 remains the most widely used tumor marker in patients with ovarian epithelial cancer in general to monitor recurrence after treatment.<sup>13</sup> Considering MBT is one of the malignant epithelial tumors of the ovary, it remains rational to examine pre-operative CA-125 and use it to monitor recurrence if the tumor marker.<sup>13</sup> Gezginc et al in his case report analyzed 13 MBT patients, where a pre-operative CA-125 level was normal in 7 patients (53.8%) and increased in 6 patients (46.2%).<sup>10</sup> Nasioudis et al in his study found 64 MBT patients with preoperative CA-125 data, 45 patients (70.3%) had increased CA-125 level and 19 patients (29.7%) with normal CA-125 level.<sup>11</sup> Based on the above data although no specific tumor markers were found for MBT but CA-125 was still effective to use as screening or in postoperative monitoring.

### Histopathology feature and immunohistochemistry in malignant Brenner tumor

2  
The diagnosis of MBT histology is principally based on the criteria established by Hull and Campbell, which is benign or borderline Brenner components of MBT, accompanied by a distinct stromal invasion by malignant epithelial components and should be clearly separated from frequent tumor types found simultaneously with MBT (most often mucinous cystadenoma).<sup>14</sup>

The existence of transitional type differentiation is required to diagnose MBT, which is characterized by a grove nucleus that can be seen using immunohistochemistry expressing urothelial markers such as GATA3, uroplakin III, thrombomodulin and p63.<sup>15-17</sup> In the case we reported, a histopathologic examination was performed using routine hematoxylin and eosin (HE) assays. In staining using HE, the islands of transparent anaplastic epithelial cells, pleomorphic nuclei, hyperchromatics, invasive mitosis grew into the connective tissue stroma, but the benign and borderline Brenner component was also still can be found. To confirm the diagnosis, an immunohistochemical examination with p63 antibody was performed. The literature states that p63 is a specific marker of Brenner tumor. In immunohistochemical p63 staining, the results was positive in which transitional cells in Brenner's tumor express a brownish color.

### 16 Differential diagnosis of malignant Brenner tumor

5  
The differential diagnosis of malignant Brenner tumors is transitional cell carcinoma (TCC). Despite the fact that both have transitional cellular features, there is ample evidence that these tumors differ clinically and pathologically. In imaging and gross examination, TCC

show fewer calcifications usually seen in MBT. Another difference is that MBT is commonly found in stage I without spreading outside of ovaries and less aggressive than ovarian TCC. One study reported that TCC was more aggressive than MBT where 69% of TCC was found at an advanced stage whereas only 19% of MBT was found at advanced stage.<sup>18</sup>

14  
Transitional cell carcinoma was first discovered by Austin and Norris in 1987. It has been described as primary ovarian cancer which has a urothelial appearance, this species is never found in benign or borderline forms as found in Brenner tumors, it is clearly differentiating between these two ovarian tumors.<sup>19</sup> Microscopically, TCC does not show any benign tumor component of Brenner marked with nests - a well-differentiated transitional cell, in fact, reveals a malignant image along the cell line.<sup>20</sup>

Immunohistochemistry p63 has the ability to distinguish MBT from TCC in which some studies report that immunohistochemistry has high sensitivity for Brenner tumors but negative in TCC 4. Both MBT or TCC are both expressing CK7, but both are negative against CK20 which is usually expressed by malignant cells in the urinary tract. The immunohistochemistry can be used to see the primary of the tumor. If CK 20 is positive then the malignancy originates from the urinary tract.<sup>21</sup> In this case reports, we perform p63 immunohistochemistry examination to differentiate MBT with TCC, the results was positive marked by brown color that was expresses by the transitional cell.

#### Surgery in malignant Brenner tumor

Surgical therapy on MBT follows another standard ovarian epithelial cancer of primary debulking. Primary debulking with minimal residue followed by platinum-based adjuvant chemotherapy provides longer survival in patients with ovarian cancer, however the use of NAC chemotherapy may be useful in some groups of patients who have tumor mass that are difficult to resect, and high risk patients.<sup>22</sup> Nasioudis et al reported on a retrospective analysis of the population of MBT showing that 98% of MBT patients underwent primary debulking. The selective lymph nodes dissection (pelvic and para-aorta lymph nodes) was a classic procedure performed on ovarian malignancy to assess the stage of cancer.

However, only about 50% of patients who performed tumor removal were followed by lymph node dissection and from that number only 5% of patients proved to be spreading lymphatically. It is also said that lymph node dissection did not significantly affect the survival rate of patient.<sup>11</sup> But TAH-BSO omentectomy and lymph node

dissection in ovarian cancer patients is useful for staging based on FIGO staging.<sup>4</sup> In this case report, the surgery was performed RSUD Jombang hospital, and because of limited facilities the frozen section can not be performed and only TAH – BSO was performed so the stage of the cancer can not be evaluated.

#### Chemotherapy in malignant Brenner tumor

In this case report, the patient received paclitaxel and carboplatin chemotherapy which were planned 6 times, but the patient was absent in the 3rd chemotherapy so she only had 5 course of chemotherapy. The chemotherapy follows the chemotherapy procedure in epithelial ovarian cancer by oncology department of dr. Soetomo Hospital. The role of adjuvant therapy in the treatment of MBT in the literature has not been well explained because this rare ovarian tumor is rarely found in clinical practice. The effects of platinum-based chemotherapy in association with paclitaxel after surgery show some benefit to survival rate. Han et al reported, no recurrence of stage I MBT after surgery followed by chemotherapy.<sup>13</sup> Currently standard chemotherapy for ovarian epithel cancer patients is carboplatin combined with paclitaxel.<sup>23</sup>

#### Radiotherapy in MBT

Radiotherapy has not been studied for the treatment of MBT, but Radiotherapy in the treatment of ovarian epithelial cancer is not done because the tumor is responsive to chemotherapy and to avoid unwanted side effects by whole abdominal radiation therapy (WART). This is the reason why National Comprehensive Cancer Network (NCCN) does not include radiotherapy as a primary treatment recommendation and only as a palliative radiotherapy reference to control local symptoms.<sup>4</sup> However, recent evidence suggests that advances in radiotherapy technology contribute to the success of locally controlling gynecological malignancies and are not associated with high rates of toxicity of the radiation.

15  
Chundury et al stated that 82% of patients with chemotherapy resistant ovarian cancer who received radiotherapy with a median dose of 50.4 Gy were free of local recurrence at 2 years post-radiotherapy, and without high toxicity (acute GI toxicity rate = 6.1%).<sup>24</sup> Given radiotherapy contemporary therapy allows direct therapy directed at tumor sites and is relatively safe for surrounding vital organs, the use of this method may be considered for recurrence in ovarian epithelial tumors. Radiotherapy targets on recurrent tumors will utilize the radiosensitive properties of ovarian epithelial cancer so that it will simultaneously reduce the amount of chemotherapy and possible chemotoxicity.<sup>4</sup>

### Evaluation in malignant Brenner tumor

In this case report the patient was originally planned for 6 course of chemotherap with an evaluation after the 3rd cycle. No residual mass was found at the time of first and second evaluation either on routine gynecological examination or by using ultrasound and abdominal CT scan and no elevation of CA-125 level. Specific tumor markers have not been found for MBT because of the small number of cases, but the combination of CA-125 and imaging is very effective and helps us to evaluate the success of the therapy.

20  
CA-125 levels increase in 80% of patients with ovarian epithelial cancer, especially those with non-mucinous tumors. The levels of these tumor markers often begin undetected after surgical resection and after one or two chemotherapy cycles. CA-125 elevation is only found in 50% epithelial ovarian cancer stage I and 75-90% in advanced stage ovarian epithelial cancer. Prostate, Lung, Colorectal and Ovarian Cancer Screening (PLCO) studies demonstrate the ineffectiveness of CA-125 as a method of early detection of ovarian cancer. In this study of 28,000 women aged 55-74 years who underwent CA-125 and transvaginal sonography (TVS) examinations, only 402 (1.4%) experienced an increase in CA-125. During the study there were only 29 cases of ovarian malignancy, 16 of which were accompanied by an increase CA-125, while 14 cases were in advanced stage without any increase in CA-125. Based on PLCO study also obtained a low predictive value of CA-125 which is 4%.<sup>25</sup>

Radiologic examination is very useful to evaluate whether there is a recurrence, especially to see where the recurrence location. In the CT scan, ascites fluid can be detected immediately, but quite a lot of metastasis in omentum can be missed. Single Positron-emission tomography (PET) examination or in combination with CT scan is helpful in detecting recurrence. MRI may be used as an alternative in patients allergic to contrast medium on CT-scan.<sup>8</sup>

### Prognosis of malignant Brenner tumor

Ryback et al reported mortality from MBT is about 55% and the mean recurrence rate is 1 year.<sup>27</sup> Malignant Brenner tumor confined to ovary (stage I) has an excellent prognosis, with 5 year survival rate reaching 88% as reported by Austin et al. However, when MBT spreads out the ovaries will have the same prognosis as other ovarian epithelial cancer.<sup>8,28</sup>

The stages of the patient's cancer in this case report are not known because the surical staging was not performed but during the surgery the wall of the cyst

was ruptured during adhesion release. Based on first anatomical pathology report, macroscopically the tumor penetrate outside of the tumor capsule but no further microscopic description. The review of histopathology can not confirm whether the tumor penetrate the capsule or not, because the specimen was only in paraffin block.

### CONCLUSION

25  
Malignant Brenner ovarian tumor is a rare epithelial ovarian cancer. During 2014- 2016 in dr. Soetomo Surabaya hospital there were only 1 case. The diagnosis can only be based on anatomic pathology examination. Specific tumor markers for malignant Brenner tumors have so far not been found, the use of CA-125 tumor markers can assist in diagnosis and to monitor treatment success and to assess recurrence. Use of p63 immunohistochemistry is helpful in the anatomical pathology examination to diagnose malignant Brenner tumors. Differential diagnosis of malignant Brenner tumor is ovarian transitional cell carcinoma. Etiology and malignant pathogenesis of Brenner tumor is still a debate, but to date it is suspected the tumor is derived from epithel ovarium surface undergoing metaplasia. Radiologic evaluation in combination with CA-125 tumor marker is very effective to help to see recurrence. The prognosis of malignant Brenner tumors in stage I is very good compared to other ovarian cancers, but if there is spread outside of ovaries then the prognosis is similar to other ovarian cancer.

### REFERENCES

1. Ferlay J, Soerjomataram I, Dikshit R, et al. Cancer incidence and mortality worldwide: sources, methods and major patterns in GLOBOCAN 2012. *International Journal of Cancer*. 2015;1;136(5).
2. Aziz MF. Gynecological cancer in Indonesia. *Journal of Gynecologic Oncology*. 2009;20(1):8-10.
3. Ries LA, Young Jr JL, Keel GE, et al. Cancer survival among adults: US SEER program, 1988–2001. Patient and tumor characteristics SEER Survival Monograph Publication. 2007;07-6215.
4. Lang SM, Mills AM, Cantrell LA. Malignant Brenner tumor of the ovary: Review and case report. *Gynecologic Oncology Reports*. 2017.
5. Hemalatha AL, Konanahalli P. Bilateral malignant Brenner tumor of ovary. *J Obstet Gynecol India*. 2005;55(1):81-2.
6. Bean LM, Anderson KM, Taylor K, et al. Malignant Brenner tumor of the ovary: A population-based study. *Gynecologic Oncology*. 2016;141: 201
7. Dierickx I, Valentin L, Van Holsbeke C, et al. Imaging in gynecological disease (7): clinical and



- ultrasound features of Brenner tumors of the ovary. *Ultrasound in Obstetrics & Gynecology*. 2012;40(6):706-13.
8. Berek and Novak's. *Gynecology*. 15th edn. Lippincott Williams and Wilkins, 2012, p. 1560.
  9. Verma A, Chander B, Verma S, Soni A. Malignant brenner tumor of ovary. *The Journal of Obstetrics and Gynecology of India*. 2014;1:1-2.
  10. Gezginç K, Karataylı R, Yazıcı F, et al. Malignant Brenner tumor of the ovary: Analysis of 13 cases. *International Journal of Clinical Oncology*. 2012; 17(4):324-9.
  11. Nasioudis D, Sisti G, Holcomb K, et al. Malignant Brenner tumors of the ovary; a population-based analysis. *Gynecologic Oncology*. 2016;142(1):44-9.
  12. Organisation mondiale de la santé, Centre international de recherche sur le cancer. WHO classification of tumours of female reproductive organs. IARC press; 2014.
  13. Han JH, Kim DY, Lee SW, et al. Intensive systemic chemotherapy is effective against recurrent malignant Brenner tumor of the ovary: An analysis of 10 cases within a single center. *Taiwanese Journal of Obstetrics and Gynecology*. 2015;54(2):178-82.
  14. Hull MG, Campbell GR. The malignant Brenner tumor. *Obstetrics & Gynecology*. 1973;42(4):527-hyhen.
  15. Cuatrecasas M, Catusus L, Palacios J, Prat J. Transitional cell tumors of the ovary: a comparative clinicopathologic, immunohistochemical, and molecular genetic analysis of Brenner tumors and transitional cell carcinomas. *The American Journal of Surgical Pathology*. 2009;33(4):556-67.
  16. Roma AA, Masand RP. Different staining patterns of ovarian Brenner tumor and the associated mucinous tumor. *Annals of diagnostic pathology*. 2015;19(1):29-32.
  17. Seidman JD, Khedmati F. Exploring the histogenesis of ovarian mucinous and transitional cell (Brenner) neoplasms and their relationship with Walthard cell nests: a study of 120 tumors. *Archives of Pathology & Laboratory Medicine*. 2008;132(11):1753-60.
  18. Austin RM, Norris HJ. Malignant Brenner tumor and transitional cell carcinoma of the ovary: a comparison. *International Journal of Gynecological pathology*. 1987;6(1):29-39.
  19. Tlahuel JL, Heredia RD, Morales JR, Salazar JG. Transitional cell carcinoma of the ovary: A case report and review of the literature. *Journal of Cancerology*. 2014;1:32-5
  20. Ali RH, Seidman JD, Luk M, et al. Transitional cell carcinoma of the ovary is related to high-grade serous carcinoma and is distinct from malignant brenner tumor. *International Journal of Gynecological Pathology*. 2012;31(6):499-506.
  21. Ingin RJ, Andola SK, Zubair AA. Transitional cell carcinoma of the ovary: case series and review of literature. *Journal of Clinical and Diagnostic Research: JCDR*. 2014;8(8):FD07.
  22. Gill SE, McGree ME, Weaver AL, et al. Optimizing the treatment of ovarian cancer: Neoadjuvant chemotherapy and interval debulking versus primary debulking surgery for epithelial ovarian cancers likely to have suboptimal resection. *Gynecologic Oncology*. 2017;144(2):266-73.
  23. Ozols RF, Bundy BN, Greer BE, et al. Phase III trial of carboplatin and paclitaxel compared with cisplatin and paclitaxel in patients with optimally resected stage III ovarian cancer: a Gynecologic Oncology Group study. *Journal of Clinical Oncology*. 2003;21(17):3194-200.
  24. Chundury A, Apicelli A, DeWees T, et al. Intensity modulated radiation therapy for recurrent ovarian cancer refractory to chemotherapy. *Gynecologic Oncology*. 2016;141(1):134-9.
  25. Pepin K, del Carmen M, Brown A, Dizon DS. CA-125 and epithelial ovarian cancer: Role in screening, diagnosis, and surveillance. *American Journal of Hematology/Oncology*. 2014;10(6).
  26. Dail DH, Cagle PT, Marchevsky AM, et al. Metastases to the lung. In: Travis WD, Brambilla E, Muller-Hermelink HK, Harris C, editors. *Tumor of the lung*. Lyon-France: IARC:2004 p. 121-4.
  27. Ryback BJ, Ober WB, Bernacki Jr EG. Malignant Brenner tumor of the ovary. Report of three cases. *Diagnostic Gynecology and Obstetrics*. 1981;3(1): 61-74.
  28. Yamamoto R, Fujita M, Kuwabara M, et al. Malignant Brenner tumors of the ovary and tumor markers. *Japanese Journal of Clinical Oncology*. 1999;29(6):308-13.

# Ovarian Malignant Brenner Tumor

## ORIGINALITY REPORT

13%

SIMILARITY INDEX

10%

INTERNET SOURCES

8%

PUBLICATIONS

1%

STUDENT PAPERS

## PRIMARY SOURCES

1	<a href="http://e-journal.unair.ac.id">e-journal.unair.ac.id</a> Internet Source	1%
2	<a href="http://docksci.com">docksci.com</a> Internet Source	1%
3	<a href="http://mafiadoc.com">mafiadoc.com</a> Internet Source	1%
4	<a href="http://www.ejmanager.com">www.ejmanager.com</a> Internet Source	1%
5	<a href="http://discoveryjournals.org">discoveryjournals.org</a> Internet Source	1%
6	Kazım Gezginç, Rengin Karatayli, Fatma Yazici, Ali Acar, Çetin Çelik, Metin Çapar, Lema Tavli. "Malignant Brenner tumor of the ovary: analysis of 13 cases", International Journal of Clinical Oncology, 2011 Publication	1%
7	<a href="http://doctorlib.info">doctorlib.info</a> Internet Source	1%
8	<a href="http://oamjms.eu">oamjms.eu</a> Internet Source	

1 %

9

Tomoaki Fujita, Aya Takeya, Haruka Miyata, Futa Ninomiya et al. "Thoracic spinal metastasis as recurrence of borderline Brenner tumor without local recurrence: a case report", Gynecologic Oncology Reports, 2022

Publication

<1 %

10

[patentimages.storage.googleapis.com](https://patentimages.storage.googleapis.com)

Internet Source

<1 %

11

I. Dierickx, L. Valentin, C. Van Holsbeke, G. Jacomen, A. A. Lissoni, A. Licameli, A. Testa, T. Bourne, D. Timmerman. "Imaging in gynecological disease (7): clinical and ultrasound features of Brenner tumors of the ovary", Ultrasound in Obstetrics & Gynecology, 2012

Publication

<1 %

12

[www.scribd.com](https://www.scribd.com)

Internet Source

<1 %

13

Sanjay Rao, Daniel A. Smith, Ezgi Guler, Elias G. Kikano et al. "Past, Present, and Future of Serum Tumor Markers in Management of Ovarian Cancer: A Guide for the Radiologist", RadioGraphics, 2021

Publication

<1 %

14 Agarwal, Reena, Shelly Sehgal, Sompal Singh, Leela Pant, Vinita Jaggi Kumar, and Sunita Fotedar. "Transitional Cell Carcinoma of the Ovary: A Case Report", Journal of Gynecologic Surgery, 2012. <1 %  
Publication

---

15 Controversies in the Management of Gynecological Cancers, 2014. <1 %  
Publication

---

16 Guangming Han, Robert A. Soslow. "Nonserous Ovarian Epithelial Tumors", Surgical Pathology Clinics, 2011 <1 %  
Publication

---

17 L.M. Bean, K.M. Anderson, K. Taylor, M.A. Davis, C.C. Saenz, M.T. McHale, S.C. Plaxe. "Malignant Brenner tumor of the ovary: A population-based study", Gynecologic Oncology, 2016 <1 %  
Publication

---

18 [escholarship.mcgill.ca](http://escholarship.mcgill.ca) <1 %  
Internet Source

---

19 [www.medindia.net](http://www.medindia.net) <1 %  
Internet Source

---

20 [epdf.tips](http://epdf.tips) <1 %  
Internet Source

---

21 "GYNECOLOGICAL CANCERS", Cancer Investigation, 2009 <1 %  
Publication

---

22 Ayse Murat. "Bilateral Malignant Brenner Tumor of the Ovary", Journal of Women s Imaging, 09/2005 <1 %  
Publication

---

23 Jing Quan, Lu Jin, Jia Hu, Tao He, Xiang Pan, Yu Ding, Jian Peng, Zhebo Chen, Shangqi Yang, Xiangming Mao, Yongqing Lai. "Brenner tumor of the testis: A case report and review of the literature", Molecular and Clinical Oncology, 2017 <1 %  
Publication

---

24 Seung Eun Jung, Jae Mun Lee, Sung Eun Rha, Jae Young Byun, Jung Im Jung, Seong Tai Hahn. "CT and MR Imaging of Ovarian Tumors with Emphasis on Differential Diagnosis", RadioGraphics, 2002 <1 %  
Publication

---

25 Yingao Zhang, Allison Staley, Katherine Tucker, Leslie H. Clark. "Malignant Brenner tumor of the ovary: Case series and review of treatment strategies", Gynecologic Oncology Reports, 2019 <1 %  
Publication

---

26 new.minerals.net <1 %  
Internet Source

---

27	<a href="http://obgynkey.com">obgynkey.com</a> Internet Source	<1 %
28	<a href="http://planning.cancer.gov">planning.cancer.gov</a> Internet Source	<1 %
29	<a href="http://silo.pub">silo.pub</a> Internet Source	<1 %
30	<a href="http://smj.org.sa">smj.org.sa</a> Internet Source	<1 %
31	Ovarian Neoplasm Imaging, 2013. Publication	<1 %
32	Shi, Shuyuan, Jingkui Yang, and Daqiang Sun. "CT-guided 125I brachytherapy on pulmonary metastases after resection of colorectal cancer: A report of six cases", Oncology Letters, 2014. Publication	<1 %
33	"Blaustein's Pathology of the Female Genital Tract", Springer Science and Business Media LLC, 2019 Publication	<1 %
34	"Oncological Surgical Pathology", Springer Science and Business Media LLC, 2020 Publication	<1 %
35	Ovarian Cancer in Elderly Patients, 2016. Publication	<1 %

---

36

"1-A1: Lung Cancer 1 : Poster Sessions",  
Respirology, 2013.

Publication

<1 %

37

Blaustein's Pathology of the Female Genital  
Tract, 2011.

Publication

<1 %

Exclude quotes On

Exclude matches Off

Exclude bibliography On

# Ovarian Malignant Brenner Tumor

GRADEMARK REPORT

FINAL GRADE

**/100**

GENERAL COMMENTS

**Instructor**

PAGE 1

PAGE 2

PAGE 3

PAGE 4

PAGE 5

PAGE 6

PAGE 7

PAGE 8