

Simultaneous kissing stents in acute left main total occlusion complicated with cardiogenic shock

by Mochamad Yusuf Alsagaff

Submission date: 03-Mar-2023 11:06AM (UTC+0800)

Submission ID: 2027568925

File name: left_main_total_occlusion_complicated_with_cardiogenic_shock.pdf (2.55M)

Word count: 3902

Character count: 20656

Simultaneous kissing stents in acute left main total occlusion complicated with cardiogenic shock

Mochamad Yusuf Alsagaff,¹ Dwi Fachrul Octafian Hidayat,¹ Hiroyuki Daida²

¹Department of Cardiology and Vascular Medicine, Airlangga University, Surabaya, East Java, Indonesia

²Cardiology, Juntendo University School of Medicine, Bunkyo-ku, Tokyo, Japan

Correspondence to
Dr Mochamad Yusuf Alsagaff;
yusuf_505@fk.unair.ac.id

Accepted 2 April 2021

SUMMARY

We present a case of acute left main bifurcation lesion presenting as very high-risk non-ST elevation acute coronary syndrome. Consequently, an immediate invasive strategy for this complex anatomical lesion in an unstable patient requires an emergent bailout strategy to restore the haemodynamic condition. Our case shows the simultaneous kissing stents technique in a patient with a true left main bifurcation lesion (Medina 1-1-1) as a strategy to overcome the compromised haemodynamics. This protocol would be an alternative life-saving strategy in an acute setting.

BACKGROUND

The true left main (LM) bifurcation lesion (Medina 1-1-1) is considered a complex anatomical lesion. Acute total LM primary percutaneous coronary intervention (PCI) represents 0.58% of cardiac intervention data. Approximately 89% of the patients with acute total LM occlusion presented with cardiogenic shock.¹ True LM bifurcation lesions generally require intravascular imaging to guide and select the stent strategy.^{2,3}

We report a case of the simultaneous kissing stents (SKS) technique using a drug-eluting stent (DES) as a bailout strategy in acute left main coronary artery occlusion with a true bifurcation lesion in a clinical presentation of Killip IV very high-risk non-ST elevation acute coronary syndrome (NSTEMI-ACS).

CASE PRESENTATION

A 54-year-old man came to the emergency room reporting about sudden and persistent typical chest pain for 5 hours, loss of vision, lethargy, nausea and vomiting. He had dyslipidaemia and no history of smoking or hypertension. His blood pressure (BP) was 53/37 mm Hg, pulse was 60 beats per min and he had cold extremities. An ECG revealed ST-segment elevation in aVR and V1, ST-segment depression in the inferior and posterior lead (II, III, aVF, V7, V8, V9) with incomplete left bundle branch block and trigeminy premature ventricular contractions (left-sided) (figure 1). He was diagnosed with a very high-risk NSTEMI-ACS. We administered 250 mL normal saline, 0.05 mcg/kg/min norepinephrine, 300 mg aspirin and 600 mg clopidogrel. An immediate invasive strategy was conducted within less than 2 hours.

INVESTIGATIONS

A diagnostic angiography revealed a normal right coronary artery with partial collateral filling (grade 2) to the left anterior descending (LAD) artery

(figure 2A, video 1). The left coronary system had a total occlusion of the left main coronary artery with a true bifurcation lesion (figure 2B, video 1).

TREATMENT

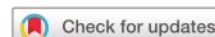An immediate invasive strategy was performed. Hi-torque Whisper MS guide wire (Abbott, USA) placement to the LAD or left circumflex (LCx) was challenging. Balloon support was used to allow a guide wire to cross the LM shaft, then the wire was pushed to the LAD (figure 2C). Hi-torque Versaturn guide wire (Abbott, USA) was intended to be placed in LCx but failed. Accidentally, the thrombus migrated from the LM shaft to the distal LM. The haemodynamic condition was further compromised as BP increased to 74/40 mm Hg and the pulse increased to 110 beats per min, with the support of 0.15 mcg/kg/min norepinephrine.

An eptifibatide loading dose of 180 mcg/kg was administered intravenously, and the procedure was continued with successful thrombus aspiration. Angiography evaluation revealed a true bifurcation lesion Medina 1-1-1 with a wide bifurcation angle (figure 2D–F). Pre-dilatation of LM was performed using a balloon Sapphire II PRO 2.5×15 mm (OrbusNeich, China), dilated at 12 atm in 9 s. The coronary blood flow was improved from thrombolysis in myocardial infarction (TIMI) flow 0 to TIMI flow 2 without haemodynamic restoration (figure 3A, video 2). Considering the complex lesion, unstable haemodynamics with falling BP, and the need for rapid revascularisation, we decided to use the two stents strategy. The SKS technique was chosen as the bailout strategy based on the need for safe and rapid action.

A second Hi-torque Whisper MS guide wire (Abbott, USA) was placed in LCx. Promus Element Plus 3.0×24 mm stents were placed in LAD, and Promus Element Plus 3.0×24 mm stents were placed in LCx (both Boston Scientific, USA). Both stents were pulled to the LM until approximately the same length and formed a Y shape. The proximal lesion covered by both stents then inflated simultaneously 12 atm in 20 s (figure 3B). Then, 300 µg of nitrate was administered intracoronarily. Final angiography resulted in TIMI 3 flow (figure 3C–E), with BP 88/54 mm Hg, pulse 110 beats per min with support of 0.15 mcg/kg/min norepinephrine.

OUTCOME AND FOLLOW-UP

After the procedure, the patient was transferred to intensive care, and echocardiography was performed. The echocardiography showed decreased left ventricular (LV) systolic function



© BMJ Publishing Group Limited 2021. No commercial re-use. See rights and permissions. Published by BMJ.

To cite: Alsagaff MY, Hidayat DFO, Daida H. *BMJ Case Rep* 2021;**14**:e241245. doi:10.1136/bcr-2020-241245

Case report

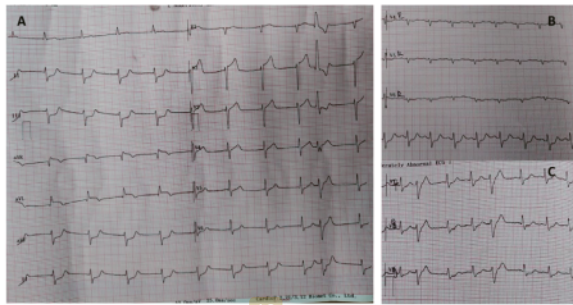


Figure 1 (A) The ECG shows ST-segment elevation leads aVR and V1. ST-segment depression in leads II, III and aVF. (B) The right-sided ECG. (C) The posterior ECG shows ST-segment depression in V7, V8 and V9.

(ejection fraction (EF) 29%), systemic vascular resistance (SVR) 1.613 dynes.sec/cm⁵, cardiac output 2.86 L/min and left ventricular outflow tract velocity time integral (LVOT VTI) was 9.9 cm. LV segmental analysis showed akinesia in anteroseptal, anterior, lateral and anterolateral segments. Other LV segments had hypokinesia.

During observation in intensive care, we administered 5 mcg/kg/min dobutamine due to low LVOT VTI. After 3 days, his condition was improving as the norepinephrine dose was reduced. The second echocardiography revealed improved LV systolic function (EF 43%), apical LV thrombus (2.2 cm × 1.4 cm), SVR 2.058 dynes.sec/cm⁵ and LVOT VTI 10.9 cm with the support of 0.075 mcg/kg/min norepinephrine and 5 mcg/kg/min dobutamine (video 3). An oral anticoagulant was started.

After 7 days in intensive care, the haemodynamics improved without support, and ACE inhibitor and beta-blockers were initiated, but the patient could not tolerate the beta-blockers. The patient was transferred to the ward. He was discharged after

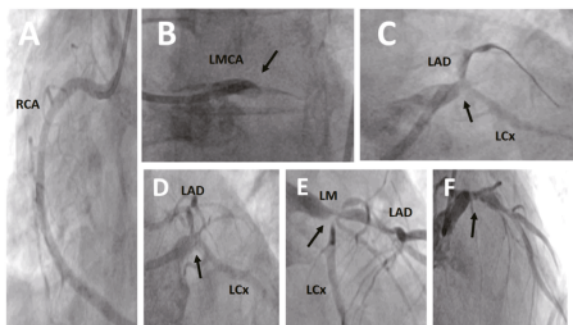
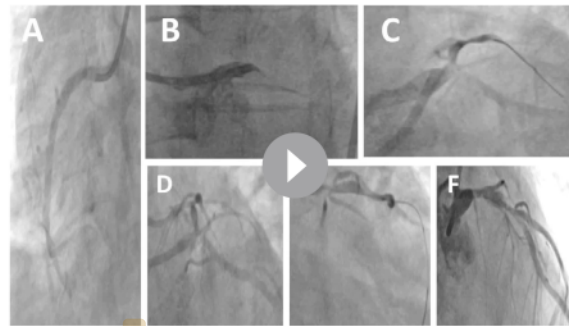


Figure 2 (A) Diagnostic coronary angiography of RCA was normal (LAO cranial view projection) with partial collateral filling (grade 2) from RCA to LAD. (B) Diagnostic coronary angiography of the left coronary artery system. The solid black arrow shows total occlusion at the LM coronary artery. (C) LAD successfully wired. The solid black arrow shows a thrombus at the LM coronary artery. An angiography evaluation after eptifibatide administration and thrombus aspiration revealed a true bifurcation lesion (Medina 1-1-1) with a wide bifurcation angle. The solid black arrow shows true bifurcation lesions. (D) LAO caudal view projection. (E) RAO caudal view projection. (F) RAO cranial view projection. LAD, left anterior descending; LCx, left circumflex; LM, left main; RCA, right coronary artery; LAO, left anterior oblique; RAO, right anterior oblique.



Video 1 (A) Diagnostic coronary angiography of right coronary artery (RCA) was normal (LAO cranial view projection) with partial collateral filling (grade 2) from RCA to left anterior descending (LAD). (B) Diagnostic coronary angiography of the left coronary artery system. The solid black arrow shows total occlusion at the left main (LM) coronary artery. (C) LAD successfully wired. The solid black arrow shows a thrombus at the LM coronary artery. An angiography evaluation after eptifibatide administration and thrombus aspiration revealed a true bifurcation lesion (Medina 1-1-1) with a wide bifurcation angle. The solid black arrow shows true bifurcation lesions. (D) LAO caudal view projection. (E) RAO caudal view projection. (F) RAO cranial view projection. LAO, left anterior oblique; RAO, right anterior oblique.

2 days of observation in the ward. The patient was followed up at the outpatient clinic and remained asymptomatic.

DISCUSSION

According to 2020 European Society of Cardiology (ESC) guidelines, a haemodynamic instability or cardiogenic shock with the presence of ST-segment depression > 1 mm in ≥ 6 leads in addition to ST-segment elevation in aVR and/or V1 are considered very high-risk criteria of NSTEMI-ACS.⁴ Approximately 9% of the

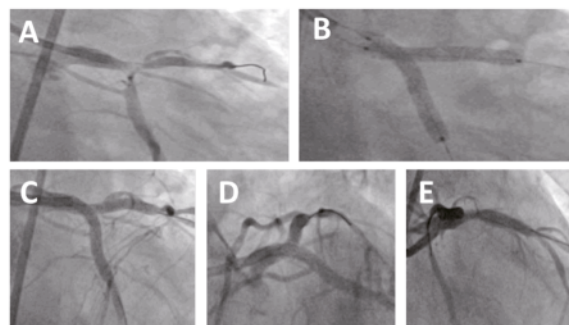
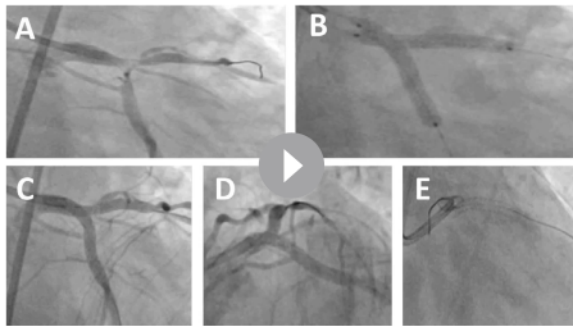


Figure 3 (A) After left circumflex (LCx) was successfully wired, the procedure continued with pre-dilated left main (LM) with balloon Sapphire II PRO 2.5×15 mm (OrbusNeich, China), at 12 atm. This figure shows the angiography evaluation after pre-dilated LM. (B) The simultaneous kissing stents technique used two stents. Promus Element Plus 3.0×24 mm stents placed in LCx, and Promus Element Plus 3.0×24 mm stents placed in left anterior descending (both Boston Scientific, USA). Both stents were pulled to the LM until approximately the same length and formed a Y shape. The proximal lesion covered by both stents was then inflated simultaneously at 12 atm in 20 s. Final angiography results in thrombolysis in myocardial infarction 3 flow. (C) LAO caudal view projection. (D) RAO caudal view projection. (E) RAO cranial projection. LAO, left anterior oblique; RAO, right anterior oblique.

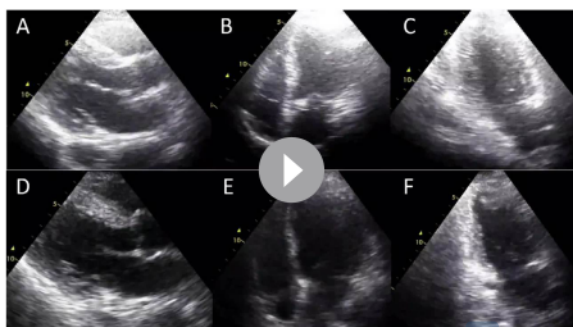


Video 2 (A) After left circumflex (LCx) was successfully wired, the procedure continued with pre-dilated left main (LM) with balloon Sapphire II PRO 2.5×15 mm (OrbusNeich, China), at 12 atm. This video shows the angiography evaluation after the pre-dilated LM. (B) The simultaneous kissing stents technique used two stents. Promus Element Plus 3.0×24 mm stents placed in LCx and Promus Element Plus 3.0×24 mm stents placed in left anterior descending (both Boston Scientific, USA). Both stents were pulled to the LM until approximately the same length and formed a Y shape. The proximal lesion covered by both stents was then inflated simultaneously at 12 atm in 20 s. The final angiography results in thrombolysis in myocardial infarction 3 flow. (C) LAO caudal view projection. (D) RAO caudal view projection. (E) RAO cranial projection. LAO, left anterior oblique; RAO, right anterior oblique.

cases of acute coronary syndrome presented with cardiogenic shock related with LM coronary occlusion.⁵ Almost half of those patients died under hospital care.¹

The LM coronary artery provides 84% of the blood flow to the left ventricle. The pathophysiology of LM disease has been linked to flow haemodynamics. In the case of acute total occlusion of LM, coronary blood flow is significantly reduced. Thus, left ventricle systolic function is impaired, which will develop into cardiogenic shock.⁶

The choice of strategy to treat LM lesion depends on vessel and lesion characteristics (plaque distribution, the branch diameter, the angle between the branches and anatomy of the side branch). According to DEFINITION criteria, a complex LM bifurcation lesion is defined as a major risk factor (side branch diameter stenosis $\geq 70\%$ and length ≥ 10 mm) or any of two minor risk factors (moderate-to-severe calcification, multiple lesions, bifurcation angle $<45^\circ$ or $>70^\circ$, main vessel reference



Video 3 The first echocardiography after the procedure (A) parasternal long-axis view; (B) four-chamber view; (C) two-chamber view. The second echocardiography evaluation (D) parasternal long-axis view; (E) four-chamber view; (F) two-chamber view

vessel diameter <2.5 mm, thrombus-containing lesions and main vessel length ≥ 25 mm).⁷

Complex bifurcation lesions may require a double-stent strategy (T stenting, T and small protrusion (TAP), mini crush, double-kiss crush, culotte, V stenting or SKS stenting). If the bifurcation angle is a T shape, the T-stent, TAP stenting or mini crush is recommended. If the angle is a Y shape, the culotte, double-kiss crush or V stenting is recommended.⁸ The mean procedure of complex stenting requires approximately one and half hours.⁹ Regardless of the strategy that has been chosen, the European Bifurcation Club (EBC) recommends the use of intravascular imaging during LM coronary artery intervention.² Either intravascular ultrasound or optical coherence tomography (OCT) is beneficial during LM coronary artery intervention. OCT has the advantage of providing images of the lumen and the stent-related morphology in complex cases.¹⁰

Sharma *et al* developed the SKS technique in 2004 to treat unprotected LM bifurcation disease. The SKS technique involves using two appropriately sized stents. The main vessel and the side branch are wired, and debulking the vessel is performed as clinically indicated. Two stents are then advanced one by one, initially into the side branch followed by one into the main vessel. The two stents are pulled simultaneously back to the bifurcation and then into the proximal part of the main vessel to configure a Y shape. The two stents completely cover the proximal end of the lesion. One arm of the Y is in the distal main vessel (covering the distal end of the main vessel lesion). The other arm is in the side branch (covering the distal end of the side branch lesions). The position of the stent is confirmed, and proximal stent markers are overlapped. The stents are deployed with simultaneous inflation and deflation at 10–12 atm for 10–20 s. A second dilation is performed at greater pressure to fully expand the stent struts, followed by the third (and final) simultaneous inflation and deflation, at 10–12 atm.¹¹ The SKS technique is an option due to its technical ease and short duration.¹²

Although the SKS technique has its advantages, there are several concerns about the technique. Kim *et al* reported the SKS technique in elective procedures, resulting in a new angiographic structure of carina membrane developed in half of their patients.¹³ Stinis *et al* reported that the SKS technique has a significantly higher target lesion revascularisation (TVR) and major adverse cardiovascular event compared with the crush technique over 3 years of follow-up.¹⁴ Another study by Siotia *et al* reported 150 patients with unprotected LM bifurcation lesions treated with the SKS technique using DES (55% elective, 31% urgent and 14% emergency). The TVR rate was 4.3% at 1 year and 6.2% at 2 years. The 30-day mortality for emergency patients was 14.3%. At the 2-year follow-up, the mortality rate caused by stent thrombosis was 8.6%. Repeat revascularisation was required in 4.3% of patients at 12 months and 6.2% of patients at 24 months.¹⁵ Morris *et al* also reported a computational structural analysis of the stent using the SKS technique for LM bifurcation lesion. In all patients with symptomatic recurrence, the TVR rate was 3.2% at 1 year and 4.2% at 2 years.¹⁶ In addition, the overall rate of restenosis on double-stent techniques of bifurcation lesion ranges from 17% to 26% of patients.¹⁷ A consensus from the EBC does not recommend the elective SKS technique for true bifurcation due to the lack of predictable results regarding stent distortion, vessel wall coverage, and concerns regarding safety with the long, double layer neocarina.³

Another alternative strategy in this clinical patient's setting as a bailout is stenting from the LM to the LAD, followed by medical stabilisation in intensive care. A second coronary intervention

Case report

can be performed once the patient's haemodynamic condition has stabilised. The true LM bifurcation lesion stenting continued with intravascular imaging guidance.² Currently, there are no case reports that clearly explained using SKS as a bailout strategy in a very high-risk NSTEMI-ACS or other acute coronary syndrome case.

Our case shows a very high-risk NSTEMI-ACS within an onset of 5 hours. Hypotension with hypoperfusion signs, presence of ST-segment depression >1 mm in six leads in addition to ST-segment elevation in aVR and V1 were consistent with a very high-risk NSTEMI-ACS. An immediate invasive strategy (<2 hours) is recommended in patients with very high-risk criteria.⁵ During the PCI, the LM coronary artery was totally occluded with a true bifurcation lesion. The SKS technique was chosen to improve the haemodynamics as a bailout strategy. Although this technique can be performed immediately, the same technique still needs further recommendation as alternative procedure in acute settings.

Patient's perspective

I first found my chest so tight when I was at home. I started feeling dizzy and my vision was blurred. A cold sweat broke out, and I felt nauseous. I was lying on the bed, but the feeling persisted.

My family took me to the hospital. At the emergency room, the doctor examined my blood pressure and my heart. An ECG was recorded. I was told that I had a heart attack. The doctor gave me some pills and injections. The doctor explained that I had to undergo cardiac catheterization immediately.

I feel my condition is getting weaker. My family and I agreed to do catheterization. I was sent to the cardiac catheterization room. The doctor put a stent in my coronary arteries. After, I was treated in the intensive room in several days. The chest pain was so much better. After all of the treatment, I did not feel chest pain anymore. My body feels stronger. Then, I was transferred to the ward. I came home after 9 days of hospitalization. Currently, I routinely check my condition every month at the outpatient clinic without any symptoms.

Learning points

- ▶ An immediate invasive strategy is recommended to manage a patient with very high-risk non-ST elevation acute coronary syndrome. A complex anatomical lesion and compromised haemodynamic condition must be considered.
- ▶ The simultaneous kissing stent technique may become a bailout strategy in acute coronary syndrome with true left main bifurcation lesion and rapid haemodynamic deterioration.

Twitter Mochamad Yusuf Alsagaff @cardiology

Contributors Supervised by MYA. The patient was under the care of MYA in the emergency room. An immediate invasive strategy was done by MYA. The patient was under the care of MYA in the intensive cardiac care and ward. The acquisition of data was done by DFOH. The analysis and interpretation of data were done by MYA and DFOH. The report was written by MYA and DFOH. The report was reviewed by HD.

Funding The authors have not declared a specific grant for this research from any funding agency in the public, commercial or not-for-profit sectors.

Competing interests None declared.

Patient consent for publication Obtained.

Provenance and peer review Not commissioned; externally peer reviewed.

REFERENCES

- 1 Gutiérrez-Barrios A, Gheorghe L, Camacho-Freire S, et al. Primary angioplasty in a catastrophic presentation: acute left main coronary total Occlusion—The ATOLMA registry. *J Interv Cardiol* 2020;2020:1–8.
- 2 Mintz GS, Lefèvre T, Lassen JF, et al. Intravascular ultrasound in the evaluation and treatment of left main coronary artery disease: a consensus statement from the European bifurcation Club. *EuroIntervention* 2018;14:e467–74.
- 3 Banning AP, Lassen JF, Burzotta F, et al. Percutaneous coronary intervention for obstructive bifurcation lesions: the 14th consensus document from the European bifurcation Club. *EuroIntervention* 2019;15:90–8.
- 4 Collet J-P, Thiele H, Barbato E. Esc guidelines for the management of acute coronary syndromes in patients presenting without persistent ST-segment elevation. *Eur Heart J* 2020;2020:1–79.
- 5 Thiele H, Akin I, Sandri M, et al. Pci strategies in patients with acute myocardial infarction and cardiogenic shock. *N Engl J Med* 2017;377:2419–32.
- 6 Collet C, Capodanno D, Onuma Y, et al. Left main coronary artery disease: pathophysiology, diagnosis, and treatment. *Nat Rev Cardiol* 2018;15:321–31.
- 7 Wang J, Guan C, Chen J, et al. Validation of bifurcation definition criteria and comparison of stenting strategies in true left main bifurcation lesions. *Sci Rep* 2020;10:10461.
- 8 Liang S, Chen DD. Stenting of left main coronary artery stenosis: data to clinical practice. *J Cardiovasc Dis Diagnosis* 2015;03.
- 9 Behan MW, Holm NR, Curzen NP. Simple or complex stenting for bifurcation coronary lesions. *Circulation* 2011;124:57–64.
- 10 Oosterveer TTM, van der Meer SM, Scherptong RWC, et al. Optical coherence tomography: current applications for the assessment of coronary artery disease and guidance of percutaneous coronary interventions. *Cardiol Ther* 2020;9:307–21.
- 11 Shama SK, Choudhury A, Lee J, et al. Simultaneous kissing stents (sks) technique for treating bifurcation lesions in medium-to-large size coronary arteries. *Am J Cardiol* 2004;94:913–7.
- 12 Ahn J-M, Lee PH, Park S-J. Practical based approach to left main bifurcation stenting. *BMC Cardiovasc Disord* 2016;16:49.
- 13 Kim Y-H, Park D-W, Suh I-W, et al. Long-Term outcome of simultaneous kissing stenting technique with sirolimus-eluting stent for large bifurcation coronary lesions. *Catheter Cardiovasc Interv* 2007;70:840–6.
- 14 Stinis CT, SPC H, Price MJ. Three-Year outcome of drug-eluting stent implantation for coronary artery bifurcation lesions. *Catheter Cardiovasc Interv* 2009;75.
- 15 Siotia A, Morton AC, Malkin CJ, et al. Simultaneous kissing drug-eluting stents to treat unprotected left main stem bifurcation disease: medium term outcome in 150 consecutive patients. *EuroIntervention* 2012;8:691–700.
- 16 Morris PD, Iqbal J, Chiastra C, et al. Simultaneous kissing stents to treat unprotected left main stem coronary artery bifurcation disease; stent expansion, vessel injury, hemodynamics, tissue healing, restenosis, and repeat revascularization. *Catheter Cardiovasc Interv* 2018;92:E381–92.
- 17 Isaz K, Bayle S, Lamaud M, et al. Immediate and long-term results of a modified simultaneous kissing stenting for percutaneous coronary intervention of coronary artery bifurcation lesions. *J Invasive Cardiol* 2013;25:126–31 <http://www.ncbi.nlm.nih.gov/pubmed/23468441>

Copyright 2021 BMJ Publishing Group. All rights reserved. For permission to reuse any of this content visit <https://www.bmj.com/company/products-services/rights-and-licensing/permissions/>
BMJ Case Report Fellows may re-use this article for personal use and teaching without any further permission.

Become a Fellow of BMJ Case Reports today and you can:

- ▶ Submit as many cases as you like
- ▶ Enjoy fast sympathetic peer review and rapid publication of accepted articles
- ▶ Access all the published articles
- ▶ Re-use any of the published material for personal use and teaching without further permission

Customer Service

If you have any further queries about your subscription, please contact our customer services team on +44 (0) 207111 1105 or via email at support@bmj.com.

Visit casereports.bmj.com for more articles like this and to become a Fellow

Simultaneous kissing stents in acute left main total occlusion complicated with cardiogenic shock

ORIGINALITY REPORT

17%

SIMILARITY INDEX

11%

INTERNET SOURCES

13%

PUBLICATIONS

0%

STUDENT PAPERS

PRIMARY SOURCES

- 1 Indulis Kumsars, Niels Ramsing Holm, Matti Niemelä, Andrejs Erglis et al. "Randomised comparison of provisional side branch stenting versus a two-stent strategy for treatment of true coronary bifurcation lesions involving a large side branch: the Nordic-Baltic Bifurcation Study IV", Open Heart, 2020
Publication 1%
- 2 www.imrpress.com
Internet Source 1%
- 3 Gao, Run Lin, Debabrata Dash, Bo Xu, and Thach N. Nguyen. "Left Main", Practical Handbook of Advanced Interventional Cardiology Nguyen/Practical Handbook of Advanced Interventional Cardiology, 2013.
Publication 1%
- 4 Tanveer Rab, Imad Sheiban, Yves Louvard, Fadi J. Sawaya, Jun Jie Zhang, Shao Liang Chen. "Current Interventions for the Left

MainBifurcation", JACC: Cardiovascular Interventions, 2017

Publication

5	Catheter-Based Cardiovascular Interventions, 2013. Publication	1 %
6	PanVascular Medicine, 2015. Publication	1 %
7	pesquisa.bvsalud.org Internet Source	1 %
8	Peyman Izadpanah, Zahra Hooshanginezhad, Mohammad Shojaie. " Monster left circumflex artery fistula closure by vascular plug in a patient with post - - 19 myocardial infarction ", Clinical Case Reports, 2022 Publication	1 %
9	www.frontiersin.org Internet Source	1 %
10	James Baligeh Walter Russell, Theresa Ruba Koroma, Santigie Sesay, Sallieu K Samura et al. "Burden of cardiometabolic risk factors and preclinical target organ damage among adults in Freetown, Sierra Leone: a community-based health-screening survey", Cold Spring Harbor Laboratory, 2023 Publication	1 %

11

Internet Source

<1 %

12

emjreviews.com

Internet Source

<1 %

13

F. Arslan, P. Damman, B. Zwart, Y. Appelman et al. "2020 ESC Guidelines on acute coronary syndrome without ST-segment elevation", *Netherlands Heart Journal*, 2021

Publication

<1 %

14

silo.pub

Internet Source

<1 %

15

Antonio Totaro, Graziapia Casavecchia, Matteo Gravina, Riccardo Ieva et al. "Early recurrence of atrial fibrillation after catheter ablation with left atrial fibrosis identified at cardiac magnetic resonance by late gadolinium enhancement", *Therapeutic Advances in Cardiovascular Disease*, 2016

Publication

<1 %

16

Sarah Marie de Medeiros, Avneet Mangat, Graeme R Polglase, G Zeballos Sarrato, Peter G Davis, Georg M Schmölzer. "Respiratory function monitoring to improve the outcomes following neonatal resuscitation: a systematic review and meta-analysis", *Archives of Disease in Childhood - Fetal and Neonatal Edition*, 2022

Publication

<1 %

17

[oxfordmedicine.com](https://www.oxfordmedicine.com)

Internet Source

<1 %

18

www.scielo.br

Internet Source

<1 %

19

pubmed.ncbi.nlm.nih.gov

Internet Source

<1 %

20

www.em-consulte.com

Internet Source

<1 %

21

Kamohara, K.. "Evaluation of a novel device for left atrial appendage exclusion: The second-generation atrial exclusion device", The Journal of Thoracic and Cardiovascular Surgery, 200608

Publication

<1 %

22

journals.lww.com

Internet Source

<1 %

23

Shanshan Zhai, Hui Wang, Lichao Sun, Bo Zhang, Feng Huo, Shuang Qiu, Xiaoqing Wu, Junyu Ma, Yina Wu, Jun Duan. "Artificial intelligence (AI) versus expert: A comparison of left ventricular outflow tract velocity time integral (LVOT - VTI) assessment between ICU doctors and an AI tool", Journal of Applied Clinical Medical Physics, 2022

Publication

<1 %

24

Internet Source

<1 %

25

eprints.whiterose.ac.uk

Internet Source

<1 %

26

pure.uva.nl

Internet Source

<1 %

27

recintervcardiol.org

Internet Source

<1 %

28

Bernardo Cortese, Jose M. Torre Hernandez, Magdalena Lanocha, Alfonso Ielasi et al. "Optical coherence tomography, intravascular ultrasound or angiography guidance for distal left main coronary stenting. The cohort study", Catheterization and Cardiovascular Interventions, 2021

Publication

<1 %

29

Kuon, E.. "Identification of less-irradiating tube angulations in invasive cardiology", Journal of the American College of Cardiology, 20041006

Publication

<1 %

30

citoday.com

Internet Source

<1 %

31

healthdocbox.com

Internet Source

<1 %

link.springer.com

32

Internet Source

<1 %

33

www.ceemjournal.org

Internet Source

<1 %

34

www.hindawi.com

Internet Source

<1 %

35

W. J Brady. "Electrocardiographic abnormalities encountered in acute myocardial infarction", Emergency Medicine Journal, 2000

Publication

<1 %

36

ia801701.us.archive.org

Internet Source

<1 %

37

invasivecardiology.com

Internet Source

<1 %

38

onlinelibrary.wiley.com

Internet Source

<1 %

39

www.researchgate.net

Internet Source

<1 %

40

www.science.gov

Internet Source

<1 %

41

www.summitmd.com

Internet Source

<1 %

42

"Cardiovascular Interventions in Clinical Practice", Wiley, 2010

<1 %

43

Hyoung-Mo Yang, Seung-Jea Tahk, So-Yeon Choi, Myeong-Ho Yoon et al. "Comparison of 3-year clinical outcomes between classic crush and modified mini-crush technique in coronary bifurcation lesions", *Catheterization and Cardiovascular Interventions*, 2013

Publication

<1 %

44

Kiyuk Chang, Youngkeun Ahn, Sungmin Lim, Jeong Hoon Yang et al. "2021 Korean Society of Myocardial Infarction Expert Consensus Document on Revascularization for Acute Myocardial Infarction", *Korean Circulation Journal*, 2021

Publication

<1 %

Exclude quotes On

Exclude matches Off

Exclude bibliography On

Simultaneous kissing stents in acute left main total occlusion complicated with cardiogenic shock

GRADEMARK REPORT

FINAL GRADE

/100

GENERAL COMMENTS

Instructor

PAGE 1

PAGE 2

PAGE 3

PAGE 4

PAGE 5
