


# Wrapped left anterior descending artery STEMI: time to revisit

Mochamad Yusuf Alsagaff,<sup>1,2</sup> Novia Kusumawardhani <sup>1</sup>

<sup>1</sup>Department of Cardiology and Vascular Medicine, Airlangga University, Surabaya, East Java, Indonesia

<sup>2</sup>Department of Cardiology and Vascular Medicine, Universitas Airlangga Hospital, Surabaya, East Java, Indonesia

## Correspondence to

Dr Mochamad Yusuf Alsagaff; yusuf\_505@fk.unair.ac.id

Accepted 16 December 2020

## SUMMARY

We report three cases of acute myocardial infarction caused by left anterior descending (LAD) artery occlusion presenting as ST elevation in the inferior. Therefore, coronary angiography showed an occlusion of the LAD coronary artery. Our cases show the rare occurrence of left coronary circulation dominance affecting inferior leads. These cases show an unusual and very rare form of left dominance coronary circulation where LAD is wrapped around the apex and continuing as a posterior descending artery. This would make inferior myocardial infarction because of occluded LAD or determine as wrapped LAD.

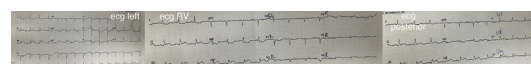
## BACKGROUND

Acute ST-segment elevation myocardial infarction (STEMI) is the major cause of sudden cardiac death, in most cases due to thrombotic occlusion of a coronary artery. The pathophysiology of inflammation and atherosclerosis lead to plaque instability that exists in acute MI.<sup>1</sup> The most comprehensive European STEMI registry is found in Sweden, where the incidence rate of STEMI was 58 per 100.000 per year in 2015.<sup>2</sup>

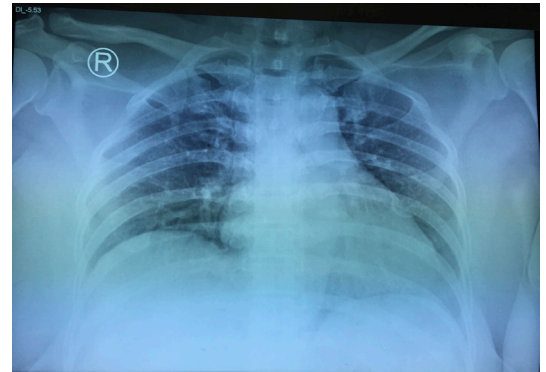
No two coronary anatomic patterns are similar and coronary artery anomalies have an incidence of less than 1.5% across different racial groups.<sup>3</sup> Typically, inferior MI is expected to arise from the culprit vessel of RCA (right coronary artery) or LCx (left circumflex coronary artery).<sup>4</sup> The posteroinferior portion of the muscular interventricular septum is usually supplied by the posterior descending artery (PDA) arising from the right coronary artery (in a dominant or codominant right pattern) or by LCx. Supply of the posteroinferior septum by hyperdominant left anterior descending (LAD) artery that continues as PDA is very rare and only 21 cases reported so far in 19 case reports in the literature (from 1967 to 2020).<sup>3 5-7</sup> We report three cases of acute MI caused by LAD artery occlusion presenting as ST elevation in the inferior. Therefore, through several case reports, the three of which were found within a span of 3 months, intrigued the authors to make a special study for wrapped LAD.

## CASE PRESENTATION

The first case is a 52-year-old woman who was referred to our hospital with typical chest pain along



**Figure 1** ECG shows ST elevation in II, III, aVF, V7–V9.

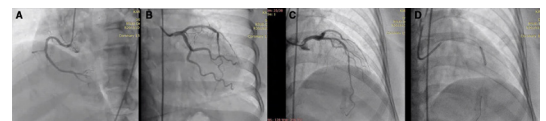

**Figure 2** Chest radiograph (anteroposterior view) shows less inspiration with no significant abnormality.

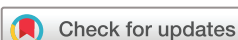with cold sweating 7 hours prior to admission. She has diabetes mellitus, a history of hypertension and stroke. On examination, her pulse was 75/min and blood pressure was 160/100 mm Hg. ECG showed ST elevation in the inferior and posterior lead.

The second case is a 62-year-old man who was referred to our hospital with typical chest pain along with nausea, vomiting and cold sweating 3 hours prior to admission. He has diabetes mellitus and a smoking history, but with no history of hypertension. He was already given a loading dose of aspirin, clopidogrel and nitrate from referring hospital. On examination, his pulse was 73/min and blood pressure was 150/90 mm Hg. ECG showed ST elevation in the anteroseptal and inferior leads.

The third case, a 47-year-old man, was referred to our hospital with typical chest pain along with cold sweating and dyspnoea a day prior to admission. He has diabetes mellitus and a history of smoking. On examination, his pulse was 80/min and blood pressure was 117/56 mm Hg. ECG showed ST elevation at inferior and anterior lead.

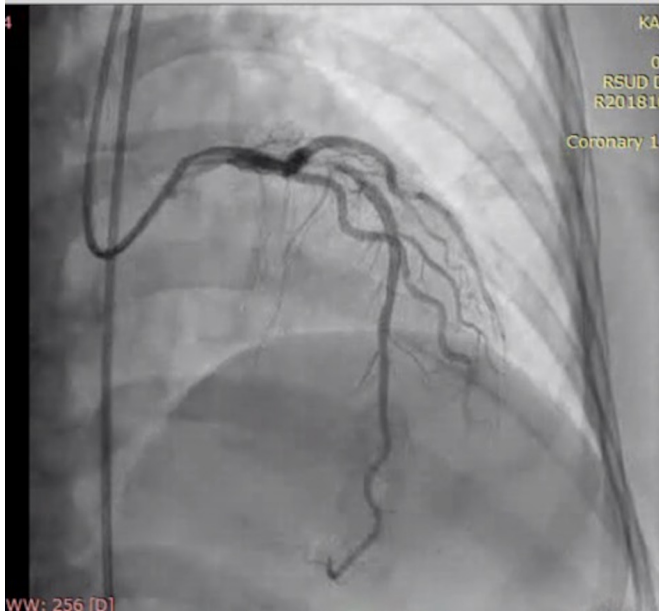


**Figure 3** Coronary angiogram showing (A) normal RCA, (B) normal LCx, (C) significant stenosis 90% at mid and distal LAD, and non-significant stenosis 50% at proximal (D) primary PCI procedure. LAD, left anterior descending; LCx, left circumflex coronary artery; PCI, percutaneous coronary intervention; RCA, right coronary artery.



© BMJ Publishing Group Limited 2021. No commercial re-use. See rights and permissions. Published by BMJ.

**To cite:** Alsagaff MY, Kusumawardhani N. *BMJ Case Rep* 2021;**14**:e237839. doi:10.1136/bcr-2020-237839



**Figure 4** Left anterior descending artery extending into the posterior wraps around the apex and gives rise to an anomalous large posterior descending artery.

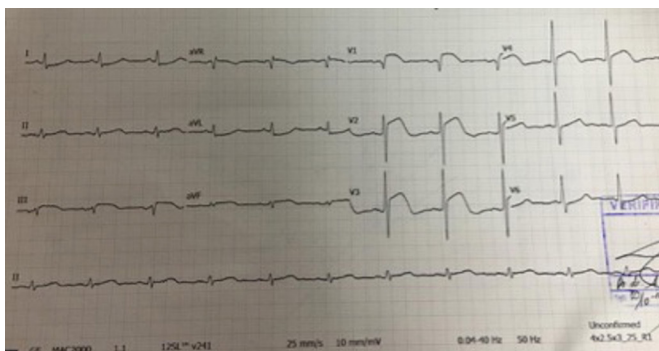
**INVESTIGATIONS**

**Case 1**

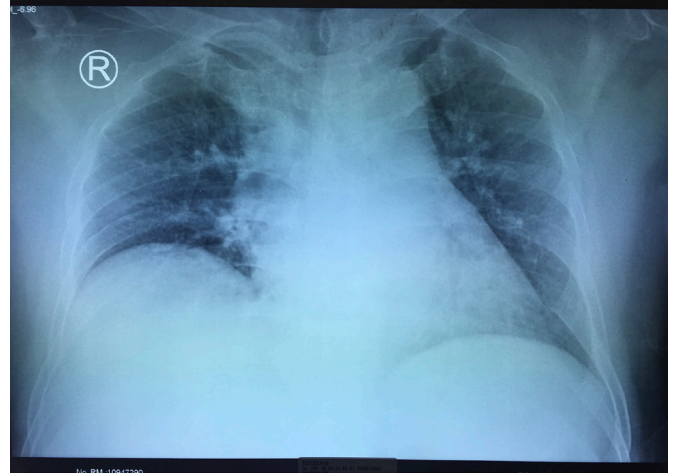
Following the examination, ECG showed ST elevation in the inferior and posterior lead (figure 1). Chest radiograph showed no abnormality (figure 2). Echocardiography revealed normokinetic in all segments with a left ventricle ejection fraction of 63%. Coronary angiography showed normal RCA and LCx. Significant stenosis 90% at mid and distal LAD, and non-significant stenosis 50% at proximal. Primary percutaneous coronary intervention (PCI) had been performed (figure 3D) and showed a PDA arising as the continuation of the LAD (figure 4).

**Case 2**

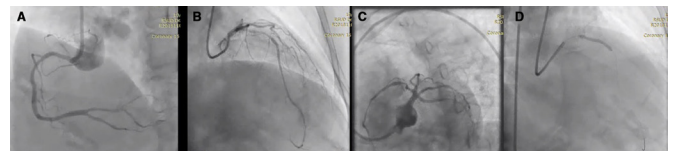
ECG showed ST elevation in the anteroseptal and inferior leads (figure 5). Chest radiograph showed no abnormality (figure 6). Echocardiography revealed hypokinetic at anteroseptal, inferoseptal and septal apical with a left ventricle ejection fraction of 49%. Coronary angiogram showed non-significant stenosis at proximal RCA and LCx but critical stenosis at proximal LAD (figure 7). Primary PCI had been performed (figure 7D) and showed a PDA arising as the continuation of the LAD (figure 8).



**Figure 5** The 12-lead ECG shows elevation of ST segment in III, aVF, V1–V4.



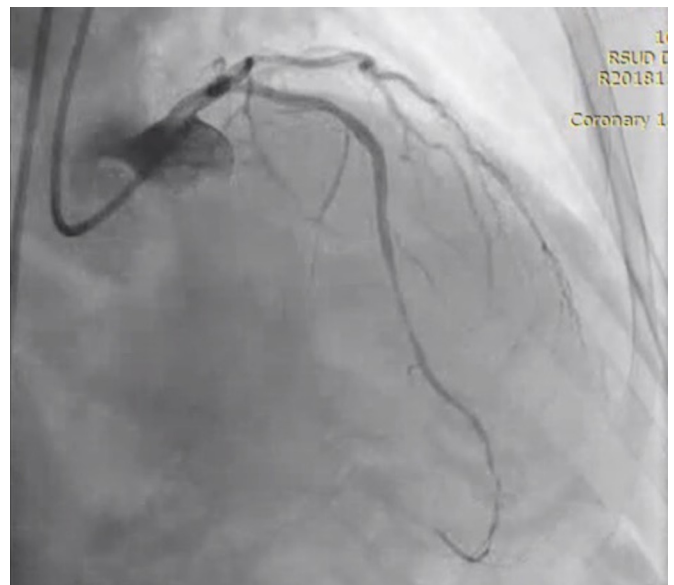
**Figure 6** Chest radiograph (anteroposterior view) shows less inspiration with no significant abnormality.



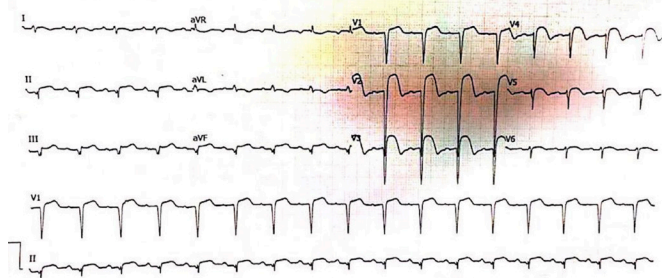
**Figure 7** Coronary angiogram showing (A) non-significant stenosis at proximal RCA, (B) critical stenosis 99% at proximal LAD, (C) non-significant stenosis at LCx and (D) primary PCI procedure at proximal LAD. LAD, left anterior descending; LCx, left circumflex coronary artery; PCI, percutaneous coronary intervention; RCA, right coronary artery.

**Case 3**

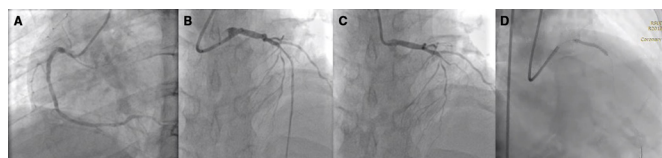
ECG showed ST elevation at inferior and anterior lead (figure 9). Chest radiograph showed normal. From echocardiography findings, we found hypokinetic at anterior, inferoseptal and anteroseptal at basal and apical, and septal apical with ejection fraction 49%. Coronary angiography showed normal RCA and normal LCx. There was critical stenosis 99% at mid



**Figure 8** Posterior descending artery arising as the continuation of the left anterior descending.



**Figure 9** ECG showed ST elevation at lead II, III, aVF, V1–V6.



**Figure 10** Coronary angiogram (A) normal RCA, (B) normal LCx, (C) critical stenosis 99% at mid LAD and (D) primary PCI procedure at mid LAD. LAD, left anterior descending; LCx, left circumflex coronary artery; PCI, percutaneous coronary intervention; RCA, right coronary artery.

LAD and we had performed primary PCI at that time at mid LAD (figure 10A–D). Coronary angiogram in the right anterior oblique (RAO) caudal projection showing LAD artery continuing as PDA (figure 11).

## TREATMENT

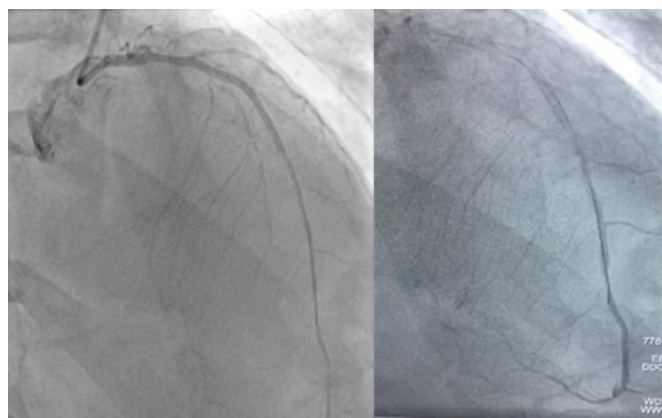
In these three patients the primary PCI procedure was performed and patients were given aspirin therapy, clopidogrel, statins, beta blockers and ACE inhibitors.

## OUTCOME AND FOLLOW-UP

The first month after primary PCI, these patients were able to return doing housework. Every patient was followed up at outpatient care and routinely checked every month, and they still have a good functional capacity.

## DISCUSSION

Atherosclerotic lesions (atheromata) are lesions resulting from asymmetric thickenings of the deepest layer of the artery, the



**Figure 11** Coronary angiogram in the right anterior oblique caudal projection showing left anterior descending artery continuing as posterior descending artery.

## Patient's perspective

### First patient

I first found my chest so tight, deeply pressed, when I was finished housekeeping at home. Cold sweat came out, and I felt my chest like burning. Right after that I lied down and did not feel any better. I got diabetes, hypertension and previous stroke. I swallowed my medicine to relieve these symptoms but I felt increasingly bad. I decided to call my daughter and she asked me to go to hospital. I refused at first, but then I gave up. I asked to pick to hospital. At emergency room, the doctor checked my symptoms and my vital sign and they gave me some pills that I should swallowed. Electrocardiogram was recorded, and they said I got heart attacked. They asked me to do heart catheterization and explained all the risks and benefits.

I said I approved that all and they sent me to the cath lab. They put a ring on my heart and I felt so relieved. I was observed at cardiac care unit and my condition was very good. I discharged after 7 days hospitalization, and now I routinely check my condition every month at outpatient cardiac care.

### Second patient

When I cool down after playing badminton, my chest felt so uncomfortable and I wanted to vomit. Cold sweat broke out and I felt uneasy due to this pain. I vomited twice and my friends took me to the hospital. I am a heavy smoker and I have diabetes. when I arrived at the hospital, the doctor did some checks and gave a number of medicines for me to chew and drink. I was examined for blood, chest x-ray, and heart records. There I was known to have a heart attack. I was surprised why I had a heart attack. Then the doctor explained that I had to do the cardiac intervention immediately and I agreed because I still felt very painful. after the intervention, my chest pain was much reduced and I felt much better. I was then treated in the intensive care unit and 3 days later I went home. I regularly come to outpatient care to check my condition. I have stopped smoking and I am back to my normal activities.

### Third patient

I am a private employee and I often come home late at night. One day I felt a terrible pain in my chest, then I broke out in a cold sweat and felt tight. I found difficulties in breathing and I decided not to come to work temporarily. After an overnight break, my chest pain did not go away. I finally went to the hospital to check my condition. In the emergency room, I was examined and found to have a heart attack. I was shocked, the doctor explained my condition, and I agreed to immediately have cardiac intervention. my condition immediately improved and after 3 days in hospital, I went home. Now my condition is much better and I regularly take my medication. I decided not to work too hard and get enough rest.

intima. They consist of cells, connective-tissue elements, lipids and debris.<sup>4</sup> Overlap between plaque and susceptible thrombogenic blood is important for MI. In addition, myocardium vulnerability, which is largely due to coronary microvascular dysfunction, contributes to extension and severity of ischaemic injury.<sup>8</sup>

Symptomatic coronary occlusion in most cases is due to intraluminal coronary thrombus formation. From the result of post-mortem pathological evaluation in patients with a fatal coronary thrombosis, plaque rupture appears to have occurred in about 66%–75% of cases. Angiograms performed 4 hours after the

## Case report

## Learning points

- ▶ Our cases above show the rare occurrence of left coronary circulation dominance affecting inferior myocardial wall.
- ▶ One of the cases showed the pure inferior elevation that is unusual and very rare form of left dominance coronary circulation where left anterior descending (LAD) is wrapped around the apex and continuing as a posterior descending artery.
- ▶ The other two cases showed LAD involvement associated with inferior and anteroseptal or anterior elevation of ST segment.
- ▶ A preliminary study in the form of a registry, followed by analysis of various parameters of this special anatomical influence on clinical presentation and outcome, is needed. It is no longer the time to use the terms unknown (number and outcome), it is time to revisit.

onset of acute MI symptoms in patients with ST-segment elevation on the ECG have shown total occlusion of the coronary artery in 84% of cases, and the remaining cases showed near total occlusion with some flow to the distal vessel.<sup>9</sup>

ECG interpretation is a basic and crucial diagnostic study to rule out cardiac illness in emergencies. However, differential diagnosis of coronary artery diseases is not easier as thought previously.<sup>5</sup> In a STEMI with ST-segment elevation present in II, III and aVF, the study of the ST elevation and depression in different leads facilitates identification of the occluded artery (RCA or LCx) and even the site of the occlusion and its anatomical characteristics.<sup>10</sup>

STEMI-type MI usually occurs in patients in whom the coronary occlusion is frequently complete or nearly complete, and perfusion of the ventricular segments is severely compromised. After the complete occlusion, the ischaemia occurs first in the subendocardium producing a taller T wave, but the ischaemia soon becomes transmural and homogeneous (ST elevation). With persistent occlusion of an epicardial coronary artery, the ST elevation evolves from an initial concave upward to a convex upward pattern. Finally, this is usually followed by a Q wave of necrosis and an inverted T wave.<sup>10</sup>

Most coronary anomalies cause no signs, symptoms or complications, and are usually found as incidental findings at the time of catheterisation, autopsy or other radiological investigations. According to the literature, the incidence of coronary artery anomalies is less than 1.5%,<sup>3</sup> and the occurrence of isolated inferior MI due to occlusion of LAD is unknown.<sup>11</sup> It is not easy to give information, explanations or differences about wrapped LAD. In addition to the unknown figure, the patient's outcome and prognosis are question marks, including when compared with the classic inferior STEMI at RCA.

Right dominance (in 85% of patients) means that PDA, atrioventricular (AV) nodal artery and the posterolateral branches originate from RCA. Left dominance (in 8% of cases) means that all three vessels (PDA, AV nodal and the posterolateral branches) originate from LCx. Very rarely do they arise from the LAD, there are only 21 cases reported so far in 19 case reports in the literature (from 1967 to 2020).<sup>5-7</sup> Even though the continuation

of the LAD around the apex is commonly seen, usually referred as 'wrap around' LAD or 'wrapped LAD'.<sup>3</sup> A 'wrapped LAD' is defined as a LAD from a post-reperfusion coronary angiogram that perfuses at least one-fourth of the inferior wall of the left ventricle in the RAO projection.<sup>11</sup> Recognition of the various types of these anomalies on angiography may be difficult, and failure to recognise them may lead to prolongation of the angiographic procedure or result in repeated catheterisations.<sup>7</sup>

Our first case shows pure inferior ST elevation that is an unusual variety of wrapped LADs where the entire PDA was formed by a continuation of the distal LAD. The occlusion was distal to all diagonal branches and hence resulted in isolated inferior wall MI without anterior wall changes. The second case presents ST elevation at anteroseptal and inferior, which turns out to be related to occlusion at proximal of LAD; and the third case has the location of the occlusion which is distal to D1, ST segment is elevated in anterior and inferior leads simultaneously.

**Twitter** Mochamad Yusuf Alsagaff @cardiology

**Contributors** MYA and NK took care of the patients together. NK reported the case. MYA made an analysis and interpretation of the data. All authors discussed the results and contributed to the final manuscript.

**Funding** The authors have not declared a specific grant for this research from any funding agency in the public, commercial or not-for-profit sectors.

**Competing interests** None declared.

**Patient consent for publication** Obtained.

**Provenance and peer review** Not commissioned; externally peer reviewed.

**ORCID iD**

Novia Kusumawardhani <http://orcid.org/0000-0002-4067-8487>

**REFERENCES**

- 1 Park D-W, Clare RM, Schulte PJ, *et al.* Extent, location, and clinical significance of non-infarct-related coronary artery disease among patients with ST-elevation myocardial infarction. *JAMA* 2014;312:2019–27.
- 2 Ibanez B, James S, Agewall S, *et al.* 2017 ESC Guidelines for the management of acute myocardial infarction in patients presenting with ST-segment elevation. *Kardiol Pol* 2018;76:229–313.
- 3 Shaikh SSA, Munde K, Patil V, *et al.* "Superdominant" Left Anterior Descending Artery Continuing as Posterior Descending Artery: Extremely Rare Coronary Artery Anomaly. *Cardiol Res* 2018;9:253–7.
- 4 Hannan EL, Samadashvili Z, Walford G, *et al.* Culprit vessel percutaneous coronary intervention versus multivessel and staged percutaneous coronary intervention for ST-segment elevation myocardial infarction patients with multivessel disease. *JACC Cardiovasc Interv* 2010;3:22–31.
- 5 Vora K. Acute inferior wall myocardial infarction with total occlusion of distal left anterior descending coronary artery in a young adult. *J Cardiol Clin Res* 2017;5:1101.
- 6 Jariwala P, Padma Kumar EA. Hyper-dominant left anterior descending coronary artery with continuation as a posterior descending artery-An extended Empire. *J Saudi Heart Assoc* 2018;30:284–9.
- 7 Rawala MS, Munoz A, Naqvi STS, *et al.* Left anterior descending artery hyper dominance giving rise to the posterior descending artery: an extremely rare coronary anomaly and its clinical implications. *J Community Hosp Intern Med Perspect* 2020;10:76–80.
- 8 Montecucco F, Carbone F, Schindler TH. Pathophysiology of ST-segment elevation myocardial infarction: novel mechanisms and treatments. *Eur Heart J* 2016;37:1268–83.
- 9 Ambrose JA, Singh M. Pathophysiology of coronary artery disease leading to acute coronary syndromes. *F1000Prime Rep* 2015;7:08.
- 10 Luna AB, Fiol-Sala M, Antman E. The 12-Lead ECG in ST Elevation Myocardial Infarction. In: *Blackwell futura*. USA: Wiley, 2007: 1–5.
- 11 Sunil Roy TN, Naghani JS, Anil Kumar R. Acute inferior wall myocardial infarction due to occlusion of the wrapped left anterior descending coronary artery. *Case Rep Cardiol* 2013;2013:1–3.

Copyright 2021 BMJ Publishing Group. All rights reserved. For permission to reuse any of this content visit <https://www.bmj.com/company/products-services/rights-and-licensing/permissions/>  
BMJ Case Report Fellows may re-use this article for personal use and teaching without any further permission.

Become a Fellow of BMJ Case Reports today and you can:

- ▶ Submit as many cases as you like
- ▶ Enjoy fast sympathetic peer review and rapid publication of accepted articles
- ▶ Access all the published articles
- ▶ Re-use any of the published material for personal use and teaching without further permission

#### **Customer Service**

If you have any further queries about your subscription, please contact our customer services team on +44 (0) 207111 1105 or via email at [support@bmj.com](mailto:support@bmj.com).

Visit [casereports.bmj.com](http://casereports.bmj.com) for more articles like this and to become a Fellow