

Hemodynamic Stroke in Simultaneous Cardio Cerebral Infarction: A New Term for Cardiologist

by Moch Yusuf

Submission date: 31-Mar-2023 09:30PM (UTC+0800)

Submission ID: 2052035406

File name: 21HEMO_1.PDF (762.08K)

Word count: 3006

Character count: 17425



Hemodynamic Stroke in Simultaneous Cardio Cerebral Infarction: A New Term for Cardiologist

Mochamad Yusuf^{1*}, Ivan Satria Pratama¹, Ruth Gunadi¹, Achmad Firdaus Sani²

¹Department of Cardiology and Vascular Medicine, Universitas Airlangga, Dr. Soetomo Hospital, Surabaya, East Java, Indonesia; ²Department of Neurology, Universitas Airlangga, Dr. Soetomo Hospital, Surabaya, East Java, Indonesia

Abstract

Edited by: Igor Spiroski
Citation: Yusuf M, Pratama IS, Gunadi R, Sani AF. Hemodynamic Stroke in Simultaneous Cardio Cerebral Infarction: A New Term for Cardiologist. Open Access Maced J Med Sci. 2021 Aug 05; 9(C):114-117. <https://doi.org/10.3889/oamjms.2021.6388>
Keywords: Cardio cerebral infarction; Myocardial Infarction; STEMI; Hemodynamic stroke
Correspondence: Mochamad Yusuf Alsagoff, Department of Cardiology and Vascular Medicine, Universitas Airlangga, Dr. Soetomo Hospital, Surabaya, East Java, Indonesia. E-mail: yusuf_505@fk.unair.ac.id
Received: 03-May-2021
Revised: 17-Jun-2021
Accepted: 26-Jul-2021
Copyright: © 2021 Mochamad Yusuf, Ivan Satria Pratama, Ruth Gunadi, Achmad Firdaus Sani
Funding: This research did not receive any financial support
Competing Interests: The authors have declared that no competing interests exist
Open Access: This is an open-access article distributed under the terms of the Creative Commons Attribution-NonCommercial 4.0 International License (CC BY-NC 4.0)

BACKGROUND: Incidence of cardio cerebral infarction is exceptionally rare, with an incidence rate as low as 0.009%. Hemodynamic compromise in patients with acute myocardial infarction may result in the cerebral blood flow reduction to water-shed areas of the brain that cause hemodynamic stroke.

CASE REPORT: We report an uncommon case of simultaneous cardio-cerebral infarction, due to Inferior right ventricle ST Segment Elevation Myocardial Infarction (STEMI) with acute ischemic stroke. Due to the rarity of this condition, there were no recommended therapeutics strategy. Mechanical reperfusion with PCI procedure may be a superior choice in the settings of acute cardio-cerebral infarction for restoring hemodynamic stability.

CONCLUSION: Therefore, PCI should be reasonable approach in treating patients with simultaneous cardio cerebral infarction.

Introduction

Cardiovascular events persist to be the leading cause of death worldwide and continue to grow in number. Mortality is predisposed by numerous factors such as advanced age, Killip class, left ventricular ejection fraction (LVEF), and complications following myocardial infarction (MI), for example, acute stroke [1], [2]. Recent studies have revealed that ischemic stroke after an acute MI is coupled with poorer outcomes compared to patients without cerebrovascular complications. The coinciding presentation of these conditions is acknowledged as cardio-cerebral infarction, which is known to be remarkably uncommon but precedes a life-threatening state. Decisive and precise diagnosis followed by immediate management should be achieved to minimize morbidity and mortality risks [3], [4].

Case Report

A 56-year-old male, with a history of type 2 diabetes and hypertension, presented to emergency ward

with severe chest pain, on-going for 2 h before admission. After evaluation, the patient was diagnosed with inferior and right ventricle ST-segment elevation MI (STEMI) and total atrioventricular (AV) block. Since he presented himself to a non-percutaneous coronary intervention (PCI) capable hospital, he was prearranged for a thrombolytic procedure. However, before the procedure, he suddenly experienced hemiparesis, dysarthria, and gradual loss of consciousness. Thrombolytics procedure was postponed and a non-contrast brain computed tomography (CT) scan was performed, which revealed signs of acute ischemic stroke. Due to the risk of hemorrhagic stroke transformation, coronary reperfusion via thrombolytics was finally canceled. Hence, he was then referred to tertiary hospital for PCI.

Upon arrival, the patient was soporous with a Glasgow Coma Scale of 8 (E2 V1 M5) with his National Institutes of Health Stroke Scale (NIHSS) was 17. His blood pressure was 140/100 mm Hg, his pulse was 55 bpm. Electrocardiogram (ECG) revealed a high degree AV block with a 2:1 conduction ratio and ST-segment elevation in the inferior and posterior lead, with increased Troponin I level (1.910 ng/ml) and HbA1C (10,3 mg/dL). Echocardiography showed a reduction of LVEF and hypokinetic segments in inferior, inferoseptal, and posterior left ventricle (LV) segments without sign

of intracardiac thrombus. A second Brain CT scan was performed and revealed no signs of hemorrhage, but there was cerebral infarction in the left centrum semiovale, left corona radiata, lacunar cerebral infarction in the right genu internal capsule (Figure 1). Afterward, the patient was immediately transferred to the cardiac catheterization lab for primary PCI.

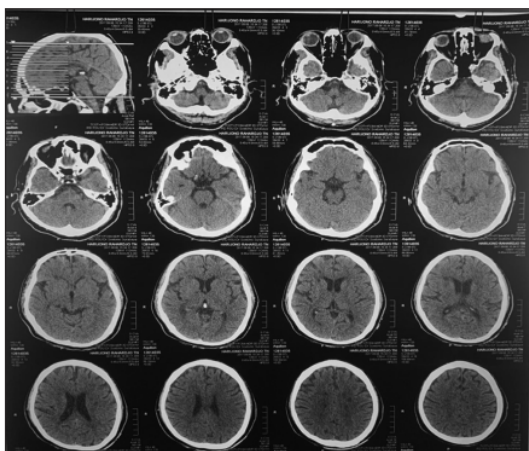


Figure 1: Computed tomography brain imaging showing infarction in the border zone area

Diagnostic coronary angiography revealed triple vessel disease, with critical stenosis at the ostial and total occlusion at mid-right coronary artery (RCA) (Figure 2).

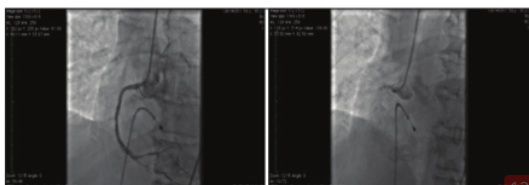


Figure 2: Pre percutaneous coronary intervention procedure on the right coronary artery (upper) and after the procedure (bottom)

Grade 2 collateral was existent from the left circumflex which was also diffusely diseased. There was a long significant 80% stenosis at proximal left anterior descending (Figure 3).

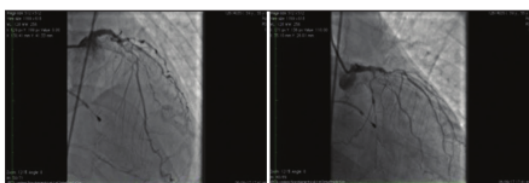


Figure 3: Diffuse disease in left anterior descending and left circumflex

The first procedure in the catheterization lab was temporary transvenous pacemaker insertion, with an initial setting of 70 ppm, 2 V output, and 5 mV sense. Loading dose of antiplatelets (Clopidogrel 600 mg and Aspirin 300 mg) were given through nasogastric tube and Heparin 5000 IU was given intravenously.

The lesion was crossed using guidewire run-through hypercoat, and pre-dilation was carried out with a 2.0 × 20 mm balloon (6 atm) at proximal RCA, 1.5 mm × 15 mm balloon (16 atm) at proximal to mid-RCA, and 2.75 mm × 20 mm balloon (8 atm) at proximal to mid-RCA. Thrombus aspiration was performed, revealing a red thrombus. This was followed by the placement of two sirolimus-eluting stents in RCA, 3.5 mm × 20 mm and 3.5 mm × 28 mm, overlapped, inflated to 12 atm, and further post dilated with a non-compliant balloon at 18 atm. Post-PCI angiography showed Thrombolysis in MI 3 flow in the RCA.

Post-PCI procedure, his rhythm subsequently converted to a 1st degree AV Block, henceforth his temporary pacemaker was later removed. The patient regained consciousness in <24 h post-procedure, but still had left hemiparesis, which gradually improved over time. At 1-year follow-up, he had no residual paresis and no symptoms of angina and dyspnea.

Discussion

Acute MI and acute ischemic stroke are medical emergencies that require timely diagnosis and management. It has been shown that acute MI increases the risk of acute ischemic stroke and vice versa. Coinciding presentation of these conditions has seldom been reported and is also acknowledged as acute cardio-cerebral infarction, with an incidence estimated to be as low as 0.009% [1]. Cardio-cerebral infarction can further be divided into two classifications, first is "synchronous cardio-cerebral infarction" which is a simultaneous infarction in the cerebral and coronary vascular territories, and "metachronous cardio cerebral infarction" which is one event preceding the other [1], [2]. The reported prevalence and incidence have mostly been for the metachronous presentation of cardio-cerebral infarction. The incidence of simultaneous cardio cerebral infarction is currently unknown due to the rarity of this co-occurrence [3]. Simultaneous cardio cerebral infarction can be diagnosed by the presence of simultaneous acute onset of a focal neurological deficit - indicating acute stroke, and chest pain or evidence of MI such as changes of the ECG and elevation of cardiac enzymes.

The pathophysiology leading to simultaneous cardio-cerebral infarction can be multi-factorial, with proposed mechanism as follows: (i) conditions resulting in concurrent cerebral coronary infarction, (ii) cardiac diseases leading to cerebral infarction, and (iii) brain-heart axis dysregulation [4], [5]. Other conditions that may contribute include: Atrial fibrillation, aortic dissection, and pre-existing cardiac thrombus [6].

Epidemiologic studies have proven that patients who have an acute MI have an increased risk

of ischemic stroke. A large MI predisposes the formation of a LV mural thrombus, and befits a potential source of embolic events [7]. Another mechanism that may cause acute ischemic stroke is brain hypoperfusion resulting from acute MI. The occurrence of a sudden hemodynamic compromise in patients presenting with acute MI may result in the reduction of cerebral blood flow to water-shed areas of the brain, especially if there is a failure of blood pressure autoregulatory mechanisms. Stroke in this condition is also known as a hemodynamic stroke [8].

The term hemodynamic stroke has traditionally been used for ischemic stroke caused by hypoperfusion and not by emboli or by local vasculopathy, where hypoperfusion can result from either regional or systemic origin. The feature that distinguishes hemodynamic stroke from other subtypes of stroke is that blood flow toward the brain is exceedingly low and results in ischemia in an area of the brain [8].

Diagnosis of a hemodynamic stroke may be difficult and is often made only after excluding a possible embolic source. Hemodynamic stroke has a distinctive pattern in brain imaging, the so-called "rosary like" pattern in the watershed area or also known as border zone (or watershed) infarct [9], [10]. Cerebral watershed infarct (WI), involves the junction of the distal fields of non-anastomosing arterial systems. There are two types of WI: cortical WI, occurring at the junction between cortical territories of the anterior, middle, and posterior cerebral arteries; and internal WI, occurring in the white matter between the deep and superficial perfusion systems of the middle cerebral artery. Pathogenesis of WI remains unthoroughly understood, and diagnosis can be challenging. In an acute phase setting, diffusion-weighted brain magnetic resonance imaging allows a clearer diagnosis than CT scan [11].

Simultaneous cardio-cerebral infarction requires early diagnosis and treatment since the myocardial cells and neurons undergo immediate necrosis. The main therapeutic strategy for this condition is to reduce infarct size by providing prompt reperfusion to the occluded artery [4]. However, due to the rarity of concurrent cardio-cerebral infarction, the recommendation for optimal reperfusion strategy in this scenario is not well established. Furthermore, a consensus among cardiologists and neurologists has not been perceived, producing challenges and dilemmas for both parties. A delayed intervention of one infarcted territory for the other may result in permanent irreversible morbidity or disability and even death. In addition to the dilemma of the sequence of management, the agents of management for each territory may complicate the extent of the other infarcted territory [3].

Intravenous thrombolytic therapy with tissue plasminogen activator (tPA) is a standard treatment for acute ischemic stroke for patients who arrived within 4.5h after onset unless contraindicated and

thrombolytic therapy within 12 h after onset, is an alternative treatment for STEMI in the setting of the non-PCI capable hospital [12], [13]. Although fibrinolytic therapy using intravenous tPA can be used in both acute ischemic stroke and acute STEMI, different dose requirements and timing of the fibrinolytic therapy after onset hinder the use of tPA as a definitive treatment for both conditions. Moreover, the higher dose and longer infusion time of tPA treatment for STEMI when compared with a standard dose for acute ischemic stroke may increase the risk of hemorrhagic transformation among patients with simultaneous acute ischemic stroke and MI [2]. A few cases of treatment success have been reported previously, using administered intravenous tPA for stroke treatment dose (0.9 mg/kg over 60 min), although there is an improvement in neurological status, the cardiac result is unknown [4].

The American Heart Association and American Stroke Association in 2018 recommended that in the setting of hyper-acute simultaneous cardio-cerebral infarction, treatment with intravenous alteplase at the dose used for cerebral ischemia followed by PCI is reasonable [1]. However, different dose requirements and timing of fibrinolytic treatment often hinder the use of alteplase as a definitive treatment for both conditions. Furthermore, suspending reperfusion therapy can lead to both hemodynamic instability and cardiac complications.

There are several anecdotal reports of simultaneous cardio-cerebral infarction with varying approaches to management. Omar Obaid et al. reported a 48-year-old patient presenting with inferior-posterior and right ventricular transmural acute myocardial infarction and a massive cerebral infarction immediately after admission. The patient was treated conservatively with antiplatelet and anticoagulants but deceased the second day [2]. Another case of simultaneous cardio cerebral infarction, reported a 44-year-old male presenting with acute ischemic stroke and an NIHSS score of 11, and was found to have an inferior acute myocardial infarction with a 2:1 atrioventricular block. The patient was treated with an intravenous tissue plasminogen activator (0.9 mg/kg over 1 hour, with a total dose of 80 mg). The patient, however, had recurrent episodes of malignant refractory arrhythmias including ventricular fibrillation requiring multiple resuscitation efforts [3].

These case reports highlighted the need to individualize treatment in patients presenting with simultaneous cardio-cerebral infarction. The ideal management of simultaneous cardio-cerebral infarction is a treatment strategy that benefits both vascular territories. An important deciding factor in the approach to management is the presentation of STEMI. According to the European Society of Cardiology guidelines for STEMI, PCI is recommended/indicated for STEMI patients within 12 after onset, or more if there were hemodynamic instability, arrhythmia, or ongoing chest

pain [12], [14]. We would like to emphasize PCI as an alternative and precedence treatment for this condition, as presented in our case where PCI showed satisfactory results in both cardiac and neurological status.

Due to the paucity of cardio-cerebral infarction, recommendations for ideal reperfusion strategy in this scenario are still deficient. In case of suspected cardio-cerebral infarction, after an initial evaluation, non-contrast CT brain, CT angiogram, and ECG should be done to confirm diagnosis. Reperfusion strategy using tPA may be selected in stable hemodynamic patients. Whereas, emergency PCI is required for patients who have unstable hemodynamic status or STEMI [2]. A reasonable approach to the acute management of simultaneous cardio-cerebral infarction is a combined treatment of both vascular territories with the administration of intravenous tPA at 0.9 mg/kg infused for 60 min, with 10% of the total dose administered as an initial intravenous bolus for 1 min, followed by PCI [2], [3].

Conclusion

The concurrent presentation of acute MI and acute ischemic stroke (also referred as cardio-cerebral infarction) is uncommon but proves to be challenging and devastating for both physician and patient. Stroke in this situation can also be described as hemodynamic stroke, where sudden hemodynamic compromise in patients with acute MI may result in the cerebral blood flow reduction to water-shed areas of the brain. Considering the insufficient clinical trials and studies, treatment options should be individualized per case. Mutual therapeutic strategies and efficient team-work among neurologists and cardiologists are required for ideal management for such exceptional cases. We believe that invasive treatment using PCI should be reasonable. Further study is needed to determine the ideal treatment for this condition.

References

1. Dutta M, Das P, Steinhubl R. Incidence and prevention of ischemic stroke following myocardial infarction : Review of current literature. *Cerebrovasc Dis*. 2006;22(5-6):331-9. <https://doi.org/10.1159/000094847>
PMid:16888371
2. Obaid O, Brancheau D. Simultaneous acute anterior ST-elevation myocardial infarction and acute ischemic stroke of left middle cerebral artery : A case report. *Am J Case Rep*. 2019;20:776-9. <https://doi.org/10.12659/ajcr.916114>

- PMid:31154453
3. Kijpaisalratana N, Chutinet A, Suwanwela NC. Hyperacute simultaneous cardiocerebral infarction: Rescuing the brain or the heart first? *Front Neurol*. 2017;8:1-7. <https://doi.org/10.3389/fneur.2017.00664>
PMid:29270151
 4. Akinseye OA, Shahreyar M, Heckle MR, Khouzam RN. Simultaneous acute cardio-cerebral infarction: Is there a consensus for management? *Ann Transl Med*. 2018;6(1):7. <https://doi.org/10.21037/atm.2017.11.06>
PMid:29404353
 5. Gungoren F, Besli F, Tanriverdi Z, Kocaturk O. Optimal treatment modality for coexisting acute myocardial infarction and ischemic stroke. *Am J Emerg Med*. 2019;37(4):795.e1-4. <https://doi.org/10.1016/j.ajem.2018.12.060>
PMid:30612780
 6. Witt BJ, Ballman KV, Brown RD, Meverden RA, Jacobsen SJ, Roger VL. The incidence of stroke after myocardial infarction : A meta-analysis. *Am J Med*. 2006;119(4):354.e1-9.
PMid:16564779
 7. Hornung M, Franke J, Gafoor S, Sievert H. Cardioembolic stroke and post myocardial infarction stroke. *Cardiol Clin*. 2016;34(2):207-14. <https://doi.org/10.1016/j.ccl.2015.12.003>
PMid:27150168
 8. Klijn CJ, Kappelle LJ. Hemodynamic stroke : Clinical features, prognosis, and management. *Lancet Neurol*. 2010;9(10):1008-17. [https://doi.org/10.1016/s1474-4422\(10\)70185-x](https://doi.org/10.1016/s1474-4422(10)70185-x)
PMid:20864053
 9. Bladin CF, Chambers BR. Frequency and pathogenesis of hemodynamic stroke. *Stroke*. 1994;25(11):2179-82. <https://doi.org/10.1161/01.str.25.11.2179>
PMid:7974542
 10. Shi J, Meng R, Konakondla S, Ding Y, Duan Y, Wang B, et al. Cerebral watershed infarcts may be induced by hemodynamic changes in blood flow. *Neurol Res*. 2017;39(6):538-44. <https://doi.org/10.1080/01616412.2017.1315499>
PMid:28393628
 11. Juergenson I, Mazzucco S. A typical example of cerebral watershed infarct. *Clin Pract*. 2011;1(4):1-2. <https://doi.org/10.4081/cp.2011.e114>
PMid:24765355
 12. Jauch EC, Saver JL, Adams HP, Bruno A, Connors JJ, Demaerschalk BM, et al. Guidelines for the early management of patients with acute ischemic stroke: A guideline for healthcare professionals from the American heart association/American stroke association. *Stroke*. 2013;44(3):870-947. <https://doi.org/10.1161/str.0b013e318284056a>
PMid:29367334
 13. Ibanez B, James S, Agewall S, Antunes MJ, Bucciarelli-Ducci C, Bueno H, et al. 2017 ESC Guidelines for the management of acute myocardial infarction in patients presenting with ST-segment elevation: The task force for the management of acute myocardial infarction in patients presenting with ST-segment elevation of the European society of cardiology (ESC). *Eur Heart J*. 2018;39(2):119-77. <https://doi.org/10.5603/kp.2018.0041>
PMid:28886621
 14. Lanzer P, Widimsky P. Ischaemic stroke and ST-segment elevation myocardial infarction : Fast-track single-stop approach. *Eur Heart J*. 2015;36(35):2348-55. <https://doi.org/10.1093/eurheartj/ehv217>
PMid:26038589

Hemodynamic Stroke in Simultaneous Cardio Cerebral Infarction: A New Term for Cardiologist

ORIGINALITY REPORT

19%

SIMILARITY INDEX

14%

INTERNET SOURCES

16%

PUBLICATIONS

6%

STUDENT PAPERS

PRIMARY SOURCES

1	eprints.ugd.edu.mk Internet Source	2%
2	oatext.com Internet Source	1%
3	surgicalneurologyint.com Internet Source	1%
4	Victor Mione, Hermann Yao, Gabriel Laurent, Marianne Zeller, Laurent Fauchier, Yves Cottin. "Simultaneous cardiocerebral embolization in patients with atrial fibrillation", Archives of Cardiovascular Diseases, 2020 Publication	1%
5	Edward Kurnia Setiawan Limijadi, Noegroho Harbani, Nani Widorini, Imam Budiwijono. "Left Hemiparesis in Acute Myeloblastic Leukemia with High Mortality", Open Access Macedonian Journal of Medical Sciences, 2020 Publication	1%

6	Submitted to iGroup Student Paper	1 %
7	Matías Casanova, Emiliano Cornú, Rubén Darío Mesa. "Hyperacute Cardio-cerebral Infarction: a Therapeutic Challenge", SN Comprehensive Clinical Medicine, 2021 Publication	1 %
8	Submitted to Universitas Airlangga Student Paper	1 %
9	Fahrul Abdul Azis, Tutik Hardjianti, Andi Fachruddin Benyamin, Sahyuddin Saleh, Rahmawati Minhajat, Dimas Bayu. "Acquired Hemophilia A in a Female: A Case Report", Open Access Macedonian Journal of Medical Sciences, 2022 Publication	1 %
10	faculty.uobasrah.edu.iq Internet Source	1 %
11	www.scitechnol.com Internet Source	1 %
12	Biplab Das, Anshu Mahajan, Gaurav Goel, Arun Garg. "Tenecteplase-induced nonaneurysmal subarachnoid hemorrhage in a patient with acute ischemic stroke: A case report and literature review", Asian Journal of Neurosurgery, 2022 Publication	1 %

13	"Full Issue PDF", Journal of the American College of Cardiology, 2019	1 %
Publication		
14	Cohen, J. E., M. Gomori, G. Rajz, S. Moscovici, R. R. Leker, S. Rosenberg, and E. Itshayek. "Emergent stent-assisted angioplasty of extracranial internal carotid artery and intracranial stent-based thrombectomy in acute tandem occlusive disease: technical considerations", Journal of NeuroInterventional Surgery, 2012.	1 %
Publication		
15	Mochamad Yusuf Alsagaff, Kandita Arjani, Yudi Oktaviono, Sondang Sitorus. "Primary Percutaneous Coronary Intervention in the Left Main ST-Elevation Myocardial Infarction and Cardiogenic Shock on Octogenarian Patient with Single Remaining Vessel", Open Access Macedonian Journal of Medical Sciences, 2021	1 %
Publication		
16	I. Hashmi, F. Shahzadi. "Watershed infarcts in a patient after carotid endarterectomy", Case Reports, 2012	<1 %
Publication		
17	f1000research.com	<1 %
Internet Source		

18

www.pubfacts.com

Internet Source

<1 %

19

D. Villasboas-Rosciolesi, M. Simó-Perdigó, J. Castell-Conesa, S. Aguadé-Bruix. "Recurrent superinfection in a patient with transjugular intrahepatic portosystemic shunt (endotipsitis), findings on 18F-FDG PET/CT", Revista Española de Medicina Nuclear e Imagen Molecular (English Edition), 2021

Publication

<1 %

20

Salvatore Chianese, Valentina Capone, Andrea Salzano, Eduardo Bossone, Rosangela Cocchia. "652 SUCCESSFUL SURGICAL REPAIR OF LEFT VENTRICULAR PSEUDOANEURYSM IN A PATIENT WITH SUBACUTE ST-ELEVATION MYOCARDIAL INFARCTION", European Heart Journal Supplements, 2022

Publication

<1 %

21

Vu Tuan Anh, D'Esposito Fabrizio, Le Thi Thanh Xuan, Pham Trong Van Van, Tran Thi Hoang Nga. "Survey of Refractive Errors in Secondary School and Refractive Errors Based- School Screening in Vietnam", Open Access Macedonian Journal of Medical Sciences, 2022

Publication

<1 %

22

austinpublishinggroup.com

Internet Source

<1 %

23	hdl.handle.net Internet Source	<1 %
24	japer.in Internet Source	<1 %
25	pdfs.semanticscholar.org Internet Source	<1 %
26	www.mdpi.com Internet Source	<1 %
27	jag.journalagent.com Internet Source	<1 %
28	Andi Susilawaty, Fajrin Noviyanto, Iis Afrianty, Armia Syahputra et al. "Attitude, Risk Perception and Public Acceptance against Coronavirus Disease 2019 Vaccination in Indonesia", Open Access Macedonian Journal of Medical Sciences, 2021 Publication	<1 %
29	Wenxian Sun, Luyang Zhang, Weishi Liu, Mengke Tian et al. "Stroke and Myocardial Infarction: A Bidirectional Mendelian Randomization Study", International Journal of General Medicine, 2021 Publication	<1 %
30	T P Ng, C Wong, E L E Leong, B Y Tan, M Y -Y Chan, L L Yeo, T -C Yeo, R C Wong, A S Leow, J S -Y Ho, C -H Sia. "Simultaneous cardio-	<1 %

cerebral infarction: a meta-analysis", QJM: An International Journal of Medicine, 2021

Publication

Exclude quotes Off

Exclude matches Off

Exclude bibliography On

Hemodynamic Stroke in Simultaneous Cardio Cerebral Infarction: A New Term for Cardiologist

GRADEMARK REPORT

FINAL GRADE

/100

GENERAL COMMENTS

Instructor

PAGE 1

PAGE 2

PAGE 3

PAGE 4
