

Relationship Histopathology Grading of Meningioma with the Use of Medroxyprogesterone Acetate (MPA) as A Hormonal Contraceptive

Shafhan Dustur¹, Joni Wahyuhadi^{1,*}, Budi Utomo², Muhammad Arifin Parenrengi¹, Abdul Hafid Bajamal¹, Sri Ratna Dwiningsih³

Shafhan Dustur¹, Joni Wahyuhadi^{1,*}, Budi Utomo², Muhammad Arifin Parenrengi¹, Abdul Hafid Bajamal¹, Sri Ratna Dwiningsih³

¹Department of Neurosurgery, Universitas Airlangga – Dr. Soetomo General Academic Hospital, Surabaya, East Java, INDONESIA.

²Department of Public Health and Community Medicine, Universitas Airlangga – Dr. Soetomo General Academic Hospital, Surabaya, East Java, INDONESIA.

³Department of Obstetrics and Gynaecology, Universitas Airlangga – Dr. Soetomo General Academic Hospital, Surabaya, East Java, INDONESIA.

Correspondence

Joni Wahyuhadi

Department of Neurosurgery, Universitas Airlangga – Dr. Soetomo General Academic Hospital, Surabaya, East Java, INDONESIA.

E-mail: joniwahyuhadi@fk.unair.ac.id

History

- Submission Date: 02-10-2022;
- Review completed: 25-11-2022;
- Accepted Date: 12-12-2022.

DOI : 10.5530/pj.2022.14.193

Article Available online

<http://www.phcogj.com/v14/6>

Copyright

© 2022 Phcogj.Com. This is an open-access article distributed under the terms of the Creative Commons Attribution 4.0 International license.

ABSTRACT

Introduction: Meningioma is a common brain tumor with an incidence of more than 30% of all primary brain tumors in adults. The incidence of meningiomas increases with increasing age, women suffer more from meningiomas with a ratio of 3:1. Meningiomas are known to have steroid receptors in the form of progesterone (88%), estrogen (40%), and androgen (40%). Therefore, the use of hormonal therapy is suspected to affect the incidence and histopathological degree of meningioma. One of the widely used hormonal therapy is medroxyprogesterone acetate (MPA). However, there is not enough literature to explain the relationship between MPA and the incidence of meningioma. **Objective:** To identify the relationship between the duration of the use of *Medroxyprogesterone acetate* (MPA) hormonal contraceptives and the histopathological degree of meningioma. **Methods:** This study is an analytic observational with a retrospective design of meningiomas patients based on the duration of use of MPA-type hormonal contraception who performed surgery at Dr. Soetomo General Academic Hospital during the period January 2015 to December 2019. We determined the inclusion criteria for meningioma patients: a history of using MPA hormonal contraceptives or 3-month injectable contraceptives; and the control group: meningioma patients without a history of hormonal contraception. **Results:** There were 452 cases of meningioma and 101 patients met the inclusion criteria. Based on the results of statistical analysis, it was found that there was no difference relationship between the grade of meningioma and meningioma patients either using MPA or without using MPA. There was no difference in duration of use between the group using MPA <10 years or more than 10 years with the non-hormonal control group on meningioma grading ($p = 0.772$). There was also no difference relationship between the group that did not use hormonal contraception and the MPA group on the age of the patient ($p = 0.217$), both using contraception for <10 years and more than 10 years. **Conclusion:** There was no relationship found between histopathological degree of meningioma with the patients who use MPA contraceptives, both duration of use <10 years and ≥ 10 years compared with meningioma patients who do not use MPA contraception.

Key words: Meningioma, *Medroxyprogesterone acetate*, MPA, Hormonal contraceptive, Contraception, Progesterone, Grading, Neoplasm.

INTRODUCTION

Meningiomas are the most common primary brain tumor in adults, representing about one-third of all intracranial tumors.¹ Meningiomas account for approximately 37.6% of all primary CNS tumors and 53.3% of all benign CNS tumors based on histopathological findings.² They are classically found to be most common in women and older patients with peak ages in the fourth and sixth decades.^{3,4}

Sex hormones are crucial in the development of meningiomas. This is believed to be the result of research showing an increase in meningiomas, which are more common in women and have 100% SSTR2, 88% progesterone receptors, 40% estrogen receptors, and 40% androgen receptors.² Additionally, *in vivo* and *in vitro* research shows that antiprogesterone medications can control meningioma growth (mifepristone).⁵ Meningiomas are believed to occur less frequently and exhibit more severe histopathology when progestin hormone medications (which are also present in hormonal contraceptives) are taken in high doses for an extended period of time.⁶

The use of hormonal contraception is believed to be a factor underlying the relationship between exogenous hormones and the incidence of meningiomas. This is because meningiomas have progesterone and estrogen receptors, which, when activated by the appropriate hormones, trigger meningioma cells to multiply.⁷ The use of progestin hormone drugs (which are also found in hormonal contraceptives) in high doses for an extended period of time is believed to affect the occurrence of meningiomas and increase the degree of meningiomas histopathologically.⁶ This study aims to identify the relationship between the duration of the use of *Medroxyprogesterone acetate* (MPA) hormonal contraceptives and the histopathological degree of meningioma.

MATERIALS AND METHODS

This study uses a retrospective analytical observational design to analyze meningioma patients who had tumors surgically removed at Dr. Soetomo General Academic Hospital between 2015 and 2019. From these data, the researchers determined the inclusion criteria for meningioma patients: a history of using MPA hormonal contraceptives or 3-month injectable contraceptives; and the control group: meningioma

Cite this article: Dustur S, Wahyuhadi J, Utomo B, Parenrengi MA, Bajamal AH, Dwiningsih SR. Relationship Histopathology Grading of Meningioma with the Use of Medroxyprogesterone Acetate (MPA) as A Hormonal Contraceptive. *Pharmacogn J.* 2022;14(6)Suppl: 938-941.

patients without a history of hormonal contraception. Patients with meningioma who had previously used MPA or were currently taking it for a condition other than contraception were excluded from the study.

The history of MPA use was divided into two categories: groups with a duration of less than 10 years and groups with a duration of more than 10 years. The histopathological grade of the meningioma was also divided into 2 groups: the benign group included those with grade 1; the non-benign group included those with grades 2 and 3. The age of exposure of meningioma patients was also evaluated in this study based on the age groups of 18 to 45 years and over 45 years.

Data analysis was carried out using a statistical computer with SPSS IBM 25 software. The Chi-square test was used to analyze the data on the variables related to the histopathological degree and the length of MPA contraceptive use. If the data does not meet the requirements for Chi-square, then it is continued with Spearman analysis, with a value of significance of $p < 0.05$. The data obtained from the research variables will be tabulated and presented in the form of tables, graphs, and diagrams.

RESULTS

Data was gathered from the medical records of Dr. Soetomo General Academic Hospital between January 2015 and December 2019. There were 452 cases of meningioma who underwent surgery at Dr. Soetomo General Academic Hospital. Based on the inclusion criteria, 101 cases of meningioma cases were then analyzed. The distribution and characteristics of meningioma patients are described in the following paragraph.

The demographic distribution and clinical characteristics of meningioma patients are shown in Table 1 above. The sample consisted of ages ranging from 20 to 75 years with a mean of 55.5 years. Meningioma cases were most prevalent (68.3%) in people aged 45 to 75. A total of 97% of meningioma patients have a history of contraception

Table 1: Demographic distribution and characteristics of meningiomas patients.

Variable	Total	%
Age		
20-44 year	32	31.7
≥ 45 year	69	68.3
History of Contraception		
MPA	84	83.17
Non-hormonal IUD	14	13.86
Not using contraception	3	2.97
Duration		
< 10 years	60	59.41
≥ 10 years	24	23.76
Histopathology		
Benign	90	89.10
Non-benign	11	10.90

Table 2: Results of the analysis of the relationship between the duration of MPA use and the histopathological degree of meningioma.

Variable	Not using hormonal Contraception	Using MPA		p
		MPA < 10 years	MPA ≥ 10 years	
Histopathology				
Benign	14	55	21	0.772
Non-benign	3	5	3	
Age				
20-44 year	4	23	5	0.217
≥ 45 year	13	37	19	

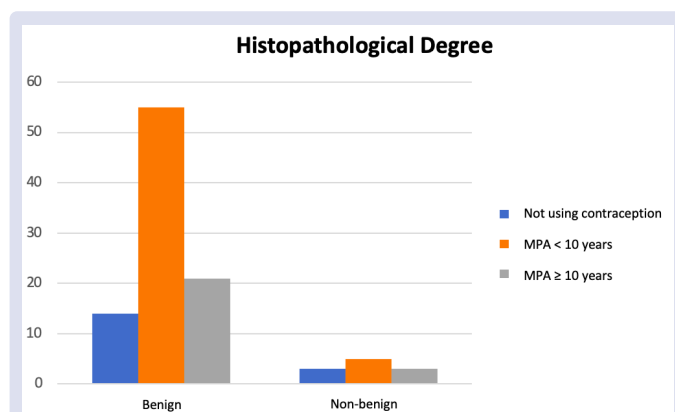


Figure 1: Distribution of duration of use of MPA hormonal contraception based on the histopathological degree of meningioma.

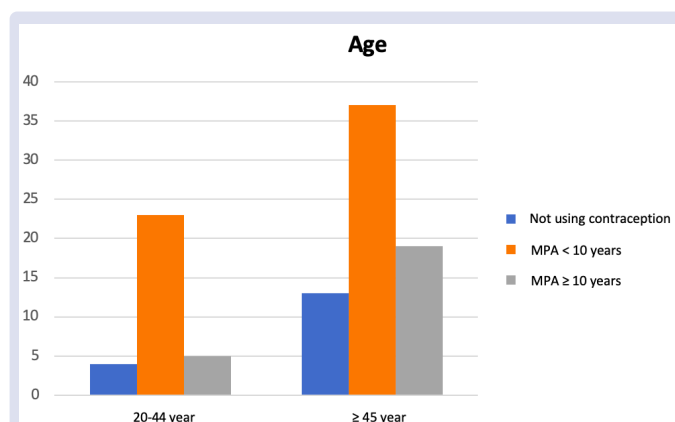


Figure 2: Distribution of duration of use of MPA hormonal contraception based on the age of meningioma patients.

in the past, both hormonal and non-hormonal. In this study, those who used hormonal contraception in the form of MPA contraception accounted for 83.17% of users; those who used IUD contraceptives made up 13.86% of users; and those who did not use contraception made up 2.97% of meningioma patients.

Based on the duration of MPA contraception use in this study, 59.41% of meningioma patients used it for less than 10 years and 23.76% for more than 10 years, while 16.83% of the control group did not use any. According to the histopathological classification, 89.10% of meningioma patients had histopathological distributions that were WHO grade 1 or benign. Following that, up to 9.90% had WHO Grade 2 and 1% had Grade 3, for a cumulative total of 10.9% non-benign groups (Figure 1).

Statistical tests showed that there was no significant relationship between the degree of meningioma and meningioma patients, either using MPA or without using MPA ($p = 0.772$) (Table 2). There was no significant relationship between patients who use MPA contraceptives, both in the duration <10 years and ≥10 years' groups compared to meningioma patients who do not use hormonal contraception on the histopathological degree of meningioma. However, quantitatively, it was found that there was an increase in the number of patients using MPA contraception in cases of meningioma with a benign histopathological degree (89.1%).

Additionally, statistical analyses revealed that there was no statistically significant difference between MPA contraception and the control group on the age of patients, both using contraception for <10 years and ≥10 years ($p = 0.217$). However, there was a quantitative increase in the number of meningioma patients aged >45 years with a history of using MPA contraception (Figure 2).

DISCUSSION

The findings indicated that patients with meningiomas were more prevalent in the older age group (>45 years). This is consistent with studies showing that the prevalence of meningiomas rises gradually with age (4)(8). Studies conducted in America also support this finding, which states that as people age, meningitis cases increase in frequency. According to this study, the incidence is 5.57 per 100,000 children under the age of 19 and rises to 28.58 per 100,000 people over the age of 20.⁹

In this study, 97% of meningioma patients had a history of using some form of birth control, with details of hormonal contraception specifically being MPA type hormonal injection contraception or injectable contraceptives every 3 months by 83.17% and non-hormonal contraception by 13.86%. A study by Wahyuhadi in 2017 also showed that 95.04% of meningioma patients had a history of contraceptive use. Similar results were also obtained in in this study, where 98.95% of meningioma patients used hormonal contraception. These conclusions are supported by the findings of another study, which found that 98.95% of meningioma patients used hormonal contraception.¹⁰

Meningioma cases quantitatively increased with age in our study, despite statistical tests yielding insignificant results. These findings are consistent with research by Wiemels *et al.* (2010), which demonstrated that patients who have used contraceptives for a period of time longer than 10 years will have a meningioma incidence risk that is 18.216 times higher. The number has decreased to 5.86 after being in use for less than ten years.⁴ The results of the study by Wigertz, *et al* in 2006 also showed similar results where the risk of meningiomas with a history of contraceptive only progesterone increased with the duration of use 5-10 years and continued to increase at the duration of use >10 years.^{11,12}

The only current study explaining the relationship between the use of MPA hormonal contraceptives and the risk of meningioma was conducted by Dewata *et al* (2017), which stated that hormonal contraception significantly increased the risk of meningioma (OR 2.19 (95% CI: 1.32–3.62)), in where the risk of meningioma was highest in patients with a history of using MPA type hormonal contraception (OR 3.13 (95% CI: 2.03–4.85)). In addition, the duration of the use of hormonal contraception will also increase the risk of meningioma with a history of using MPA for 10-15 years (OR 2.33 (95% CI; 1.31–4.15)) and for >15 years (OR 4.45 (95% CI: 2.35–8.35)).¹³

The histopathological distribution of meningioma patients in this study are as follow. Those who suffered from WHO Grade 1 meningioma at 89.1% (benign group), followed by WHO Grade 2 at 9.9%, and WHO Grade 3 at 1% (non-benign group). The population study in Germany for meningiomas cases supports the results in this study. The majority of patients who suffer from meningioma Grade 1, Grade 2, and Grade 3 was 70%, 28%, and 3%, respectively.¹⁴

The statistical test results of this study also revealed no statistically significant correlation between the duration of MPA contraceptive use and the degree of histopathology ($p = 0.214$). This finding contrasts with those of a prior study by Supartoto *et al.* published in 2019, which demonstrated a relationship between the length of hormonal contraception use and meningioma grading, where the longer exposure to exogenous hormonal contraceptives, such as progesterone, was associated with lower expression of progesterone receptors and neurofibromatosis type 2 (NF2) mRNA in serum. Low PR and NF2 expression are associated with a higher risk of developing meningiomas.¹⁵⁻¹⁷

Wahyuhadi *et al.* (2022) conducted a similar research into the correlation between hormonal contraception and the histopathological severity of meningioma, but with a larger sample size. The study involved all meningioma patients who had undergone surgery and had a history of

using any hormonal form of birth control, including injections, pills, or implants. The results of the study showed that there was no significant difference between the history of using hormonal contraception and the grading of meningioma ($p = 0.392$).¹⁷

The sample of this study only examined the group of meningioma patients who had a history of using MPA-type hormonal contraceptives, whereas previous studies combined all groups of hormonal contraceptives, either progesterone alone, estrogen alone, or a combination with various types of administration (injection, oral, or implant), possibly led to the present result. Another limitation of the study is the lack of information regarding the specifications for the type of hormonal contraception used and the duration of use which is not made clear. For instance, patients with a history of using MPA but who have also regularly used oral contraceptives or injectable contraceptives are an example of this limitation. The distribution of meningioma patients in the study with WHO Grade 3 histopathology was also very small, which had an impact on the significance of statistical tests.

CONCLUSIONS

In comparison to histopathological degree of meningioma, there is no statistically significant difference between meningioma patients who use MPA contraceptives, both duration of use <10 years and ≥10 years compared with meningioma patients who do not use MPA contraceptives. Regarding the age of patients who used contraception for less than 10 years and more than 10 years, there was no statistically significant difference between the meningioma group using MPA contraception and the meningioma group without MPA, but there was a quantitative increase in patients who were older than 45 years old and had previously used MPA contraception. A larger sample size and additional research variables, such as the expression of the progesterone receptor (PR), estrogen receptor (ER), and type 2 neurofibromatosis mRNA, may be required for future study.

CONFLICTS OF INTEREST

We have no conflicts of interest.

SOURCE OF FUNDING

No funding was granted in this study.

ACKNOWLEDGMENTS

None to declare.

REFERENCES

1. Utomo SA, Bajamal AH, Wadjib YYP, Haq IBI, Varidha VU, Fauziah D. The role of apparent diffusion coefficient in differentiating typical from atypical meningioma. *Bali Med J.* 2022;11(1):455-9.
2. Utomo SA, Bajamal AH, Yueniwati PWY, Haq IBI, Fauziah D, Fajarini ES. Advanced MRI prediction of meningioma histopathological classification: a literature review and case presentations. *Bali Med J.* 2022;11(1):23-7.
3. Hafizhan H, Bakhtiar Y, Prihatningias R. Visual function recovery post decompression surgery in meningioma: a case report. *Bali Med J.* 2021;10(1):429-32.
4. Wiemels J, Wrensch M, Claus EB. Epidemiology and etiology of meningioma. *J Neurooncol.* 2010;99(3):307-14.
5. Telugu R, Chowhan A, Rukmangadha N, Patnayak R, Phaneendra B, Prasad BM, *et al.* Estrogen and progesterone receptor in meningiomas: An immunohistochemical analysis YR - 2020/10/1. *J Cancer Res Ther.* 2020;16(6):1482-7.
6. Peyre M, Gaillard S, de Marcellus C, Giry M, Bielle F, Villa C, *et al.* Progesterin-associated shift of meningioma mutational landscape. *Ann Oncol.* 2018;29(3):681-6.

7. Supartoto A, Sasongko MB, Respatika D, Mahayana IT. Relationships Between Neurofibromatosis-2, Progesterone Receptor Expression, the Use of Exogenous Progesterone, and Risk of Orbitocranial Meningioma in Females. *Front Oncol.* 2019;8(1):1-7.
8. DeMonte F, McDermott MW, Al-Mefty O. *Al-Mefty's Meningiomas.* 2nd ed. New York: Thieme; 2011.
9. Ostrom QT, Cioffi G, Gittleman H, Patil N, Waite K, Kruchko C, et al. CBTRUS Statistical Report: Primary Brain and Other Central Nervous System Tumors Diagnosed in the United States in 2012-2016. *Neuro Oncol.* 2019;21(5):V1-100.
10. Wahyuhadi J, Heryani D, Basuki H. Risk of meningioma associated with exposure of hormonal contraception. A case control study. *Maj Obstet Ginekol.* 2018;26(1):36.
11. Wigertz A, Lönn S, Mathiesen T, Ahlbom A, Hall P, Feychting M. Risk of brain tumors associated with exposure to exogenous female sex hormones. *Am J Epidemiol.* 2006;164(7):629-36.
12. Malueka RG, Hartanto RA, Setyawan NH, Noor D, Fauzi F, Damarjati KR, et al. Association of Hormonal Contraception with Meningioma Location in Indonesian Patients. *Asian pacific J cancer Prev.* 2022;23(3):1047-51.
13. Dewata L, Prasetyo B, Yuliati A, Wahyuhadi J. Hormonal Contraceptive Exposure and Risk Factors for Meningioma in Soetomo Hospital 2012-2016. *Adv Sci Lett.* 2017;23(1):3291-4.
14. Holleczeck B, Zampella D, Urbschat S, Sahm F, von Deimling A, Oertel J, et al. Incidence, mortality and outcome of meningiomas: A population-based study from Germany. *Cancer Epidemiol.* 2019;62:101562.
15. Maiuri F, Mariniello G, Divitiis O De, Esposito F, Guadagno E, Teodonna G, et al. Progesterone Receptor Expression in Meningiomas: Pathological and Prognostic Implications. *Front Oncol.* 2021;11(2):611218.
16. Lassie N, Supartoto A. Progesterone Receptor Expression in Histopathological Subtypes of Beningn Orbitocranial Meningiomas. *Ophthalmol Ina.* 2016;42(1):91-6.
17. Wahyuhadi J, Rusdi FP. Association Between Hormonal Contraception With Histopathology Grading Of Meningioma. *Nat Volatiles Essent Oils.* 2022;9(1):1583-92.

GRAPHICAL ABSTRACT

**Relationship Histopathology
Grading of Meningioma with the
Use of Medroxyprogesterone
acetate (MPA)**



As A Hormonal Contraceptive

ABOUT AUTHORS



DrDr. Joni Wahyuhadi, Sp.BS (K) is a lecturer at the Department of Neurosurgery, Universitas Airlangga and Director of Dr. Soetomo General Academic Hospital, Surabaya, East Java, Indonesia.

Cite this article: Dustur S, Wahyuhadi J, Utomo B, Parenrengi MA, Bajamal AH, Dwiningsih SR. Relationship Histopathology Grading of Meningioma with the Use of Medroxyprogesterone Acetate (MPA) as A Hormonal Contraceptive. *Pharmacogn J.* 2022;14(6)Suppl: 938-941.