

A CBCT based cross sectional study on the prevalence and anatomical feature of C shaped molar among Jordanian

by Dian Agustin Wahjuningrum

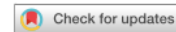Submission date: 20-Oct-2022 10:21AM (UTC+0800)

Submission ID: 1930174541

File name: s41598-022-20921-1.pdf (1,016.43K)

Word count: 4947

Character count: 26254



OPEN A CBCT based cross sectional study on the prevalence and anatomical feature of C shaped molar among Jordanian

Taher Al Omari¹, Mustafa AlKhader², Ayfer Atav Ateş³, Dian Agustin Wahjuningrum⁴✉, Alaa Dkmak¹, Waheeb Khaled¹ & Hazem Alzenate¹

The prevalence and anatomical features of C-Shaped Mandibular Second Molars (MSMs) are rarely studied in Jordanian sub-population. This study then took a part to evaluate the prevalence of C-shaped in MSMs using cone-beam computed tomography (CBCT) in the Jordanian sub-population. It used a cross-sectional design and three thousand scans collected over eight years between 2011 and 2019. The data were then reviewed for whether they were fully formed of MSMs. A total of 2037 cases that had 2845 MSMs were evaluated to identify C-shaped canals at coronal, middle, and apical sites. An oblique slicing module perpendicular to the long axis of MSMs was used to evaluate the teeth. The type and frequency of C-shaped canals, as well as the correlations between sex and side (right/left) and between sex and groove direction (buccal/lingual) were measured using the chi-square test on SPSS software at the significance level of 95%. A total of 342 teeth of 243 patients were C-shaped molars, which comprised 12% of the patient's teeth and 99 of them as a bilateral C-shaped canal with mean age of 40 years and sex ratio of 2:1 between female and male. With the limitations of this study, the lingual groove and type 3 were the most common properties of MSM. Besides, the Jordanian population mostly had C-shaped canals.

Anatomical variation in teeth is a natural phenomenon in human teeth. The failure of Hertwig's epithelial root sheath fusion in lower molars may cause an uncommon anatomical variation, a thin ribbon-shaped canal¹. Cooke and Cox were the first researchers who reported the C-shaped configuration in endodontic literature². The occurrence of this variation differs among different populations; it can be lower than 5% in certain populations^{3,4} and as high as 40% in the Chinese population⁵.

This anatomical variations in human teeth between different populations are worth investigating; however, detecting the variations on a conventional radiograph requires advanced-imaging studies. Moreover, the presence of radiographic-fused roots on the conventional x-rays and panoramic reconstruction increases the prevalence of C-shaped molars by a factor of 17.2 times⁶. Many methods have been used to study the root canal morphology, such as the clearing technique, vulcanite casts duplicated, tooth sectioning, and microscopic evaluation, as well as radiographic micro-computed tomographic imaging and cone-beam computed tomography (CBCT)⁷⁻⁹. Many of the morphological studies are conducted using non-invasive methods such as CT and CBCT⁵⁻⁸. CBCT has its own advantages and disadvantages. Some of its advantages are that it is widely used and available to modify the visual field, the high-resolution images and the high confidence level¹⁰. Despite the advantages, most studies using the CBCT method have relatively a small sample size. To date, the prevalence of C-shaped lower molars in the Jordanian subpopulation was reported to be 10%¹¹.

None of literature evaluates the prevalence of the C-Shaped mandibular second molars (MSM) in the Jordanian sub-population using the CBCT method. Therefore, this cross-sectional study aimed to verify the prevalence and anatomical features of C-shaped mandibular second molars in this population using CBCT imaging technology.

¹Department of Conservative Dentistry, Faculty of Dentistry, Jordan University of Science and Technology, Irbid, Jordan. ²Department of Oral Medicine and Oral Surgery, Faculty of Dentistry, Jordan University of Science and Technology, Irbid, Jordan. ³Department of Endodontics, Faculty of Dentistry, Istinye University, Istanbul, Turkey. ⁴Department of Conservative Dentistry, Faculty of Dental Medicine, Universitas Airlangga, Surabaya, Indonesia. ✉email: dian-agustin-w@fkg.unair.ac.id

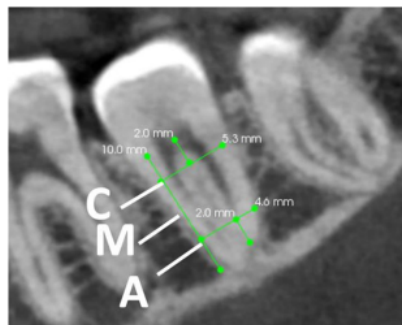


Figure 1. Representative sagittal CBCT view of a mandibular second molar generated by oblique slicing module. Exemplifying the three axial levels i.e., coronal (C), middle (M), and apical (A) at which the evaluation was performed.

Methods

Study design. In this cross-sectional retrospective study, a pool of 3,000 CBCT images collected from north and middle territories of Jordan were initially evaluated for whether they were fully formed of mandibular second molars (MSMs). The images were collected over 8 years (2011–2019) at the Dental Teaching Hospital of Jordan University of Science and Technology and CBCT 3D Dental Imaging Center/Amman. This work has been reported in line with previous research using STROBE guidelines¹² and investigating preferred reporting items for epidemiologic cross-sectional studies on root and root canal anatomy using cone-beam computed tomographic technology.¹³ The study procedures started from preparing, data analysis, and writing of this study. As the present study did not interfere with the psychological or physical of patient. This study was approved, and the informed consent is waived by Ethical Clearance Commission of the Institutional Review Board of Jordan University of Science and Technology (6/140/2021).

Study population. Patients aged between 18 and 65 years were included in the analysis. Images were taken for various reasons not limited to endodontic purpose. Teeth with artefacts, root canal treatment, posts and core, crowns, pathologies affecting the root and impossibility to determine the tooth numbering were omitted from the study. KODAK 8100 and 9500 Cone Beam 3D System (Carestream, Rochester, NY) machines with a flat panel detector were used. CBCT scanning parameters for the 8100 CBCT machine were 0.15-mm as the voxel size, 81 kV as a tube voltage, 6.3 mA as the tube current and 15 s as the exposure time, representing two third of the sample size. Parameters for the 9500 CBCT machine were 0.2-mm as the voxel size, 90 kV as the tube voltage, 10 mA as the tube current and 10.8 s as the exposure time. Patients were asked to stop swallowing and to keep their teeth in maximum intercuspation. The occlusal plane was parallel to the floor, and the field of view was 5 × 5 cm and 15 × 9 cm, respectively.

Measurements and CBCT-based 3D examination on Kodak Dental Imaging Software. The CBCT sample images were collected over eight years from 2011 until 2019. After one-hour training conducted by a maxilla-facial radiologist with 12 years of experience, three graduate dentists, internally calibrated, were responsible for generating and simultaneously evaluating three cross-sectional CBCT slices perpendicular to the long axis for all MSMs. Their primary task was to evaluate the presence of C-shaped mandibular second molars. After the first selection of teeth, to remove any source of bias, the experienced radiologist and calibrated endodontist evaluated all cases in a darkened room. Kappa test was used for intrarater reliability. The interobserver reliability was high for all evaluated teeth related to C-shaped canals identification (Cohen's Kappa of >0.91) and classification (100% of agreement).

The observers evaluated C-shaped canal scans following the examples from Alfawaz et al.¹⁴. The generated slices were coronal, middle and apical; coronal sections were taken 2 mm beneath the pulpal floor, where the middle floor was calculated by dividing the full length of the root by 2, and apical was measured 2 mm above the radiographic apex (Fig. 1).

To generate the cross-sectional slices, the oblique slicing module of the CS 3D imaging viewer version 3.10.4.0. was used. The sagittal oblique image views were created by moving the green bar at MSM over the horizontal section, and then the yellow bar was moved up to 90 degrees to the long axis of each MSM and vertically to the three previously determined sections (Fig. 1).

Shemesh et al.³ mentioned some following classifications, modified from Fan et al.¹⁵ to evaluate the CBCT images. Within the same framework, this current study classified C-shaped canals as three cross-sectional slices.

- 1) Type 1: continuous C with no separation or division (Fig. 2a)
- 2) Type 2: kidney-shaped semi-column (Fig. 2b)
- 3) Type 3: separate canals either two or three (Fig. 2c)

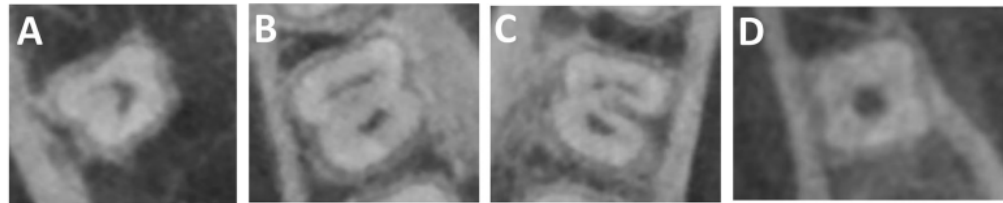


Figure 2. Example of oblique slicing module perpendicular to the long axis of a mandibular second molar. (A) Type 1—Continuous C with no separation or division, (B) Type 2—kidney-shaped semi-column, (C) Type 3—separate canals either two or three, (D) Type 4—one funnel-shaped large canal. (B buccal, L Lingual).

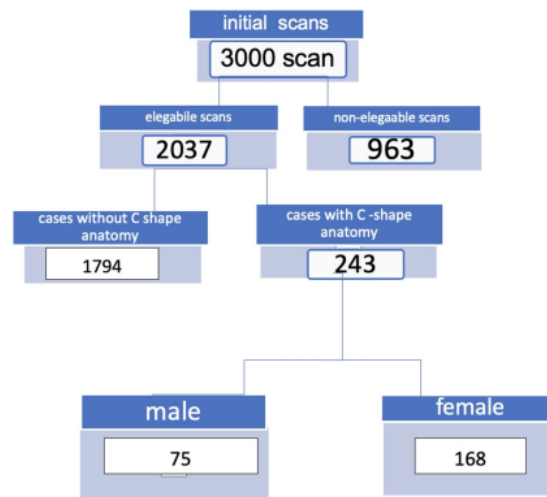


Figure 3. Flow diagram for the eligible cases.

4) Type 4: one funnel-shaped large canal (Fig. 2d).

The groove (developmental depression in root surface) for each C-shaped root was also classified as buccal or lingual.

An LCD monitor with the installed dedicated CS 3D imaging viewer was set along with the screen settings adjusted to optimize the images for evaluation.

The chi-square test was used to measure the frequency and types of the C-shaped canals, the correlations between sex and side (right or left) and between sex and groove direction (buccal or lingual). IBM SPSS Statistics software (version 20.0; IBM Corp., Armonk, NY, USA) was used to proceed the data analysis with a significance level of 0.05.

Ethics declaration. This present study was approved by the Institutional Ethics Committee of Jordan University of Science and Technology and was conducted according to the Guidelines of the Declaration of Helsinki.

Results

Patients' characteristics. Out of 3000 patients, a total of 2037 patients had fully formed MSMs, and 243 patients had C-shaped molars. The selected patients consisted of 75 males and 168 females with a mean age of 40 years. The total number of C-shaped molars was 342 teeth out of 2845 screened teeth. The flow diagram shown in Fig. 3. The prevalence of C-shaped canals in MSMs was 12.0%, while 99 patients had bilateral C-shaped canals.

No statistically significant differences were detected for sex ($p > 0.05$) and side of occurrence (left vs right side) ($p > 0.05$) on the formulation of C-shaped canals; however, statistically significant differences were detected between sex and groove direction ($p < 0.05$). Table 1 shows the analysis of the gender, side, and groove distribution of C-shaped canals in the population. Table 2 shows the analysis of the relationship between gender, side, and groove. Additionally, Table 3 indicates the classifications of C-shaped mandibular second molars modified from Fan's classifications.

	Number of included cases	C-shaped canal (%)
Gender		
Female	342	237 (69.3%)
Male	342	105 (30.7%)
Side		
Right	342	183 (53.5%)
Left	342	159 (46.5%)
Groove		
Buccal	342	72 (21.1%)
Lingual	342	270 (78.9%)

Table 1. Distribution analysis of gender, side, and groove distribution of C-shaped canals in mandibular molars of the Jordanian population.

	Female (%)	Male (%)	Total (%)
Side			
Right	126 (36.8%)	57 (16.7%)	183 (53.5%)
Left	111 (32.5%)	48 (14%)	159 (46.5%)
Groove			
Buccal	59 (17%)	13 (4%)	72 (21%)
Lingual	178 (52%)	92 (27%)	270 (79%)
Total	237	105	342

Table 2. Analysis of the relationship between gender, side, and groove.

	Type 1 (%)	Type 2 (%)	Type 3 (%)	Type 4 (%)	Total
Coronal third	100 (29.2%)	56 (16.4%)	121 (35.4%)	65 (19.0%)	342
Middle third	84 (24.6%)	58 (17.0)	138 (40.4%)	62 (18.1%)	342
Apical third	43 (12.6%)	23 (6.7%)	104 (30.4%)	172 (50.3%)	342

Table 3. Classifications of C-shaped mandibular second molars based on the modified Far's classifications.

Discussion

In this current study, the prevalence and configuration of C-shaped canals in MSMs were evaluated in different parts (coronal, middle, apical) of the teeth. The results of this study showed that the percentage of C-shaped canals in MSMs was 12% in the Jordanian subpopulation.

The canal configuration may vary according to the ethnic population (Table 4). Previous studies showed that the percentage of C-shaped canals in the second mandibular molar teeth ranged from 2.7% in the American population² to 44.5% in the Korean population¹⁶. The pooled proportion of C-shaped mandibular second molars in East Asian countries (39.6%; 36.0–43.1%) was significantly higher than in other regions¹³. The prevalence of C-shaped canals in the Brazilian population was 15.3%, but it did not differ by gender or age. There was a significant prevalence of C-shaped canals in the mandibular second molars of the population studied¹⁷. Wide variations in the root and canal morphology of mandibular second molars were found in Emirates population with a relatively high prevalence of C-shaped canal configuration (17.9%)¹⁸. A more recent study showed the prevalence of C-shaped canal configuration in Iraqi sub-population was 17.4% which is similar to Emirates population and more than Jordanian sub-population. While the female/male ratio was similar to the current study. In Iraqi sub-population, a higher prevalence was found in women than men (10.4%)¹⁹. In both studies, women exhibited more C-shaped mandibular molars than men. This result is similar to a global study conducted by von Zuben et al.²⁰.

The results of this study showed that the value of the Jordanian population is 12% which is between these percentages. This result is consistent with a study conducted by Al-Qudah and Awawdeh¹¹ discovering a similar prevalence (10%) in the same sub-population and less prevalence than a study by Ladeira et al.¹⁸ where 15.3% were found in Brazilian population²¹.

Table 4 shows the prevalence of C-shaped molars in different countries.

Wang et al.¹⁷ showed that the identification with radiographic examination showed 34.64% of C-shaped canal systems in mandibular second molars, and that using clinical examination showed 39.18%. The amount of C-shaped root canals diagnosed by radiographic method was statistically different from that by clinical examination and the combined examination²¹. However, it is challenging to obtain enough knowledge about the

Investigators	Race	Overall prevalence of C-shaped canals in mandibular first molar (%)	Overall prevalence of C-shaped canals in mandibular second molar (%)
Shemesh et al. ³	Israel	0.16	4.6
Silva et al. ⁴	Brazilian	1.7	3.5
Zheng et al. ⁵	Chinese		39
Nejaim et al. ⁶	Brazilian	2.39	14.32
Pan et al. ⁹	Malaysian		48.7
Jin et al. ¹³	Korean	–	44.5
Wang et al. ¹⁴	Chinese	–	41.27
Ladeira et al. ¹⁵	Brazilian	–	15.3
Khawaja et al. ¹⁶	Emirati		17.9
Zhang et al. ³¹	Chinese	29	29
Pawar et al. ³²	Indian	–	13.2
Alfawaz et al. ³⁸	Saudi	0.19	9.1
Abdallahman et al	Iraqi	–	17.4

Table 4. Incidence of C-shaped root canal configuration mentioned by *in vivo* studies.

cross-sectional morphology and the canal systems with two-dimensional radiographs³. While CBCT images had more superior accuracy when compared to periapical radiographs that involve anatomical difficulties such as second mesiobuccal canals in maxillary molars and C-shaped canals in mandibular molars^{22–24}. CBCT imaging is a good way to understand the full anatomy of teeth and plan root canal treatment.

Previous studies^{25–27} showed that changing the tomographic slice angulation or inclination could affect the visibility of anatomical structures, for example in the mandibular canals. The visibility of the canals was better when the slice inclination was perpendicular to the canal. Some new software (e-Vol DX, CDT Software, Bauru, Brazil) has been developed to visualize the teeth anatomy using slice inclination perpendicular to the canal^{28–31}. Bueno et al.²⁴ used this technique in an observational study on the anatomy of various teeth (maxillary central, mandibular molars and premolar).

Similarly, we generated perpendicular CBCT sections to the canals of MSMs by using the oblique slicing module, which enhanced the detection of different anatomy. Using this method in this current study likely resulted in the slightly higher prevalence of C-shaped canals than other studies conducted to the same ethnic group¹¹. The C-shaped canal in endodontics has not clearly been defined yet, and different classifications of the canals have been used in previous studies^{3,15,32}. In this current study, the CBCT images were evaluated according to modification criteria used by Shemesh et al.³. Since we performed our study with CBCT method, to avoid the low image quality in the apical part (2 mm), we followed Shemesh et al. to exclude category 5 of the Fan et al.¹⁵ classifications³.

According to this current study, type 1 (29.2%) and 3 (35.4%) were the most common in the coronal part. In addition, type 3 (40.4%) was the most common in the middle third of the canal, and type 4 was the most noticeable in the apical part (50.3%). The results related to the coronal part are partially relevant to what Shemesh et al.³ and Fan et al.¹⁵ found. They reported that type 1 was the most frequent. On the other hand, a study by Seo and Park³³ showed that the frequency of type 2 was higher than other types. In Iraqi sub-population, type 2 was the most common in contrary to Jordanian sub-population where type 3 was the most common¹⁹. This inconsistency of certain images between the studies is likely influenced by the ethnicity of the study population and the use of various study designs. However, it may be an advantage for Jordanian clinicians because shaping and cleaning the type 3 root canal system is easier than type 1 and 2⁵.

In this current study, both right and left mandibular second molars were examined. Ninety-nine of the 243 patients or 40.7% of the patients had bilateral C-shaped second mandibular molars; therefore, we should be aware of C-shaped canals when treating the lower second molars. According to our research results, gender did not influence the side occurrence of C-shaped canals. This finding is in accordance with the studies conducted by Zhang et al.³⁴ and Pawar et al.³⁵. However, this current study found gender did affect the groove direction. These anatomical features are important both in endodontics and periodontology. These grooves are difficult to clean, cause plaque to accumulate, and are periodontally important anatomical formations on the root surface³⁶. From the perspective of endodontics, the groove is considered a danger zone due to their low dentin thickness which tends to perforate³⁷. Clinicians should be mindful about the direction of this groove while performing root canal treatment. In our study, the lingual groove was frequently seen, and previous research by Fan et al.¹⁵ showed similar result. However, this finding is in contrast to research by Ladeira et al.¹⁸.

The use of CBCT instead of micro-computed tomography (μ CT) is one of the limitations of this study. Although μ CT gives more information about the details of the morphology, this technology is used for extracted teeth^{38,39}. While extracted teeth that are generally pathological cannot simulate the anatomical features of second molars in Jordanian population. Despite this limitation, this study holds more contribution to research compared to previous research which used a clearing method with extracted teeth¹¹ of the Jordanian population. Thus, our study gives novel information about the same population.

The strength of this study is that it used a large sample size using CBCT images and conducted evaluation by both the endodontist and radiologist. These advantages allow more accurate assessment of C-shaped canals;

however, this study has other limitations related to data standardization which are the use of CBCT images acquired for different purposes other than endodontics and the collection of samples from two regions of Jordan. Future prospective research could be designed to accurately evaluate the C-shaped molars by sampling CBCT images collected for endodontic purpose from different geographical areas with specific parameters for the Jordanian population. Comparing the assessment method used for this study to new assessment tools (e-Vol DX, CDT Software, Bauru, Brazil) is worth to investigate in future research.

Conclusion

In conclusion, the Jordanian population mostly had the lingual groove and type 3 properties of MSM with C-shaped canals. The prevalence of this morphology was 12%. Therefore, the clinicians should take these features into account and should combine CBCT and periapical radiography before starting endodontic treatment to reduce complications. With the thoughtful considerations on the features, a successful endodontic treatment may be achieved. Finally, it should be noted that the use of the oblique slicing module enhances the visibility of different anatomical features related to the detected C-shaped canals.

Data availability

The data used in this article are shared upon request to the corresponding author.

Received: 16 April 2022; Accepted: 20 September 2022

Published online: 13 October 2022

References

1. Fernandes, M., De Ataide, I. & Wagle, R. C-shaped root canal configuration: A review of literature. *J. Conserv. Dent.* **17**, 312–319 (2014).
2. Cooke, H. G. & Cox, F. L. C-shaped canal configurations in mandibular molars. *J. Am. Dent. Assoc.* **99**, 836–839 (1979).
3. Shemesh, A. *et al.* C-shaped canals-prevalence and root canal configuration by cone beam computed tomography evaluation in first and second mandibular molars—a cross-sectional study. *Clin. Oral Investig.* **21**, 2039–2044 (2017).
4. Silva, E. J., Nejaim, Y., Silva, A. V., Haiter-Neto, F. & Cohenca, N. Evaluation of root canal configuration of mandibular molars in a Brazilian population by using cone-beam computed tomography: An in vivo study. *J. Endod.* **39**, 849–852 (2013).
5. Zheng, Q. *et al.* C-shaped root canal system in mandibular second molars in a Chinese population evaluated by cone-beam computed tomography. *Int. Endod. J.* **44**, 857–862 (2011).
6. Nejaim, Y. *et al.* C-shaped canals in mandibular molars of a Brazilian subpopulation: Prevalence and root canal configuration using cone-beam computed tomography. *Clin. Oral Investig.* **24**, 3299–3305 (2020).
7. Martins, J. N. R. *et al.* Worldwide prevalence of a lingual canal in mandibular premolars: A multicenter cross-sectional study with meta-analysis. *J. Endod.* **47**, 1253–1264 (2021).
8. Fan, B., Cheung, G. S., Fan, M., Gutmann, J. L. & Fan, W. C-shaped canal system in mandibular second molars: Part II—radiographic features. *J. Endod.* **30**, 904–908 (2004).
9. Pan, J. Y. Y. *et al.* Root canal morphology of permanent teeth in a Malaysian subpopulation using cone-beam computed tomography. *BMC Oral Health* **19**, 14 (2019).
10. Viana Wanzeler, A. M. *et al.* Can cone-beam computed tomography change endodontists' level of confidence in diagnosis and treatment planning? A before and after study. *J. Endod.* **46**, 283–288 (2020).
11. Al-Qudah, A. A. & Awawdeh, L. A. Root and canal morphology of mandibular first and second molar teeth in a Jordanian population. *Int. Endod. J.* **42**, 775–784 (2009).
12. von Elm, E. *et al.* The strengthening of reporting of observational studies in epidemiology (STROBE) statement: Guidelines for reporting observational studies. *Int. J. Surg.* **12**, 1495–1499 (2014).
13. Martins, J. N. R. *et al.* Prevalence of C-shaped canal morphology using cone beam computed tomography: A systematic review with meta-analysis. *Int. Endod. J.* **52**, 1556–1572 (2019).
14. Alfawaz, H. *et al.* Prevalence of C-shaped canal system in mandibular first and second molars in a Saudi population assessed via cone beam computed tomography: A retrospective study. *Clin. Oral Investig.* **23**, 107–112 (2019).
15. Fan, B., Cheung, G. S., Fan, M., Gutmann, J. L. & Bian, Z. C-shaped canal system in mandibular second molars: Part I—anatomical features. *J. Endod.* **30**, 899–903 (2004).
16. Jin, G. C., Lee, S. J. & Roh, B. D. Anatomical study of C-shaped canals in mandibular second molars by analysis of computed tomography. *J. Endod.* **32**, 10–13 (2006).
17. Wang, Y., Guo, J., Yang, H. B., Han, X. & Yu, Y. Incidence of C-shaped root canal systems in mandibular second molars in the native Chinese population by analysis of clinical methods. *Int. J. Oral Sci.* **4**, 161–165 (2012).
18. Ladeira, D. B., Cruz, A. D., Freitas, D. Q. & Almeida, S. M. Prevalence of C-shaped root canal in a Brazilian subpopulation: A cone-beam computed tomography analysis. *Braz. Oral Res.* **28**, 39–45 (2014).
19. Abdalrahman, K., Talabani, R., Kazzaz, S. & Babarasil, D. Assessment of C-shaped canal morphology in mandibular and maxillary second molars in an Iraqi subpopulation using cone-beam computed tomography. *Scanning* **2022**, 1–10 (2022).
20. Von Zuben, M. *et al.* Worldwide prevalence of mandibular second molar C-shaped morphologies evaluated by cone-beam computed tomography. *J. Endod.* **43**(9), 1442–1447 (2017).
21. Khawaja, S. *et al.* The C-shaped root canal systems in mandibular second molars in an Emirati population. *Sci. Rep.* **11**, 23863 (2021).
22. Vizzotto, M. B. *et al.* CBCT for the assessment of second mesiobuccal (MB2) canals in maxillary molar teeth: Effect of voxel size and presence of root filling. *Int. Endod. J.* **46**, 870–876 (2013).
23. Mirmohammadi, H. *et al.* Accuracy of cone-beam computed tomography in the detection of a second mesiobuccal root canal in endodontically treated teeth: An ex vivo study. *J. Endod.* **41**, 1678–1681 (2015).
24. Fan, W., Fan, B., Gutmann, J. L. & Fan, M. Identification of a C-shaped canal system in mandibular second molars. Part III. Anatomical features revealed by digital subtraction radiography. *J. Endod.* **34**, 1187–1190 (2008).
25. Naitoh, M. *et al.* The role of objective plane angulation on the mandibular image using cross-sectional tomography. *J. Oral Implantol.* **32**, 117–121 (2006).
26. Neves, F. S. *et al.* Oblique or orthoradial CBCT slices for preoperative implant planning: Which one is more accurate?. *Braz. J. Oral Sci.* **13**, 104–108 (2014).
27. Alkhader, M., Hudieb, M., Jarab, F. & Shawees, A. The visibility of mandibular canal on orthoradial and oblique CBCT slices at molar implant sites. *Biotechnol. Biotechnol. Equip.* **30**, 770–776 (2016).

28. Estrela, C. *et al.* Apical foramen position in relation to proximal root surfaces of human permanent teeth determined by using a new cone-beam computed tomographic software. *J. Endod.* **44**, 1741–1748 (2018).
29. Bueno, M. R., Estrela, C., Azevedo, B. C. & Diogenes, A. Development of a new cone-beam computed tomography software for endodontic diagnosis. *Braz. Dent. J.* **29**, 517–529 (2018).
30. Bueno, M. R., Estrela, C., Azevedo, B. C. & Cintra Junqueira, J. L. Root canal shape of human permanent teeth determined by new cone-beam computed tomographic software. *J. Endod.* **46**, 1662–1674 (2020).
31. Porto, O. C. L. *et al.* CBCT assessment of bone thickness in maxillary and mandibular teeth: An anatomic study. *J. Appl. Oral Sci.* **28**, e20190148 (2020).
32. Melton, D. C., Krell, K. V. & Fuller, M. W. Anatomical and histological features of C-shaped canals in mandibular second molars. *J. Endod.* **17**, 384–388 (1991).
33. Seo, M. S. & Park, D. S. C-shaped root canals of mandibular second molars in a Korean population: Clinical observation and in vitro analysis. *Int. Endod. J.* **37**, 139–144 (2004).
34. Zhang, R. *et al.* Use of cone-beam computed tomography to evaluate root and canal morphology of mandibular molars in Chinese individuals. *Int. Endod. J.* **44**, 990–999 (2011).
35. Pawar, A. M. *et al.* Root canal morphology and variations in mandibular second molar teeth of an Indian population: An in vivo cone-beam computed tomography analysis. *Clin. Oral Investig.* **21**, 2801–2809 (2017).
36. Kato, A. *et al.* Evaluation of root morphology of maxillary and mandibular second molars lost due to periodontitis. *J. Periodontol. Res.* **55**, 753–761 (2020).
37. Solomonov, M., Paqué, F., Fan, B., Eilat, Y. & Berman, L. H. The challenge of C-shaped canal systems: A comparative study of the self-adjusting file and ProTaper. *J. Endod.* **38**, 209–214 (2012).
38. Keleş, A. & Keskin, C. Apical root canal morphology of mesial roots of mandibular first molar teeth with vertucci type II configuration by means of micro-computed tomography. *J. Endod.* **43**, 481–485 (2017).
39. Amoroso-Silva, P. *et al.* Analysis of mandibular second molars with fused roots and shallow radicular grooves by using micro-computed tomography. *J. Conserv. Dent.* **21**, 169–174 (2018).

Author contributions

T.A.O. managed the research conceptualization, design, data acquisition, analysis, and interpretation, writing draft, and critical revision of the manuscript; M.A. was responsible for the research conceptualization, design, data analysis and interpretation, writing draft, and critical revision of the manuscript; A.A.A. and D.A.W. drafted and critically revised the manuscript; A.D., W.K. and H.A. performed data analysis and interpretation, and revision of the manuscript; H.A. managed the data, including the data quality control. All authors contributed substantially to the revision of this manuscript.

Competing interests

The authors declare no competing interests.

Additional information

Correspondence and requests for materials should be addressed to D.A.W.

Reprints and permissions information is available at www.nature.com/reprints.

Publisher's note Springer Nature remains neutral with regard to jurisdictional claims in published maps and institutional affiliations.



Open Access This article is licensed under a Creative Commons Attribution 4.0 International License, which permits use, sharing, adaptation, distribution and reproduction in any medium or format, as long as you give appropriate credit to the original author(s) and the source, provide a link to the Creative Commons licence, and indicate if changes were made. The images or other third party material in this article are included in the article's Creative Commons licence, unless indicated otherwise in a credit line to the material. If material is not included in the article's Creative Commons licence and your intended use is not permitted by statutory regulation or exceeds the permitted use, you will need to obtain permission directly from the copyright holder. To view a copy of this licence, visit <http://creativecommons.org/licenses/by/4.0/>.

© The Author(s) 2022

A CBCT based cross sectional study on the prevalence and anatomical feature of C shaped molar among Jordanian

ORIGINALITY REPORT

14%

SIMILARITY INDEX

11%

INTERNET SOURCES

11%

PUBLICATIONS

0%

STUDENT PAPERS

PRIMARY SOURCES

1	www.ncbi.nlm.nih.gov Internet Source	1%
2	www.scielo.br Internet Source	1%
3	jcd.org.in Internet Source	1%
4	www.jidmr.com Internet Source	1%
5	scholarsmine.mst.edu Internet Source	1%
6	Hany Mohamed Aly Ahmed. "A critical analysis of laboratory and clinical research methods to study root and canal anatomy", International Endodontic Journal, 2022 Publication	1%
7	www.science.gov Internet Source	1%
8	www.pubfacts.com Internet Source	

1 %

9

Mohammed Mashyakhy, Hemant Ramesh Chourasia, Ahmad Jabali, Abdulmajeed Almutairi, Gianluca Gambarini. "Analysis of Fused Rooted Maxillary First and Second Molars with Merged and C-shaped Canal Configurations: Prevalence, Characteristics, and Correlations in a Saudi Arabian Population", Journal of Endodontics, 2019
Publication

1 %

10

onlinelibrary.wiley.com
Internet Source

1 %

11

www.jcdr.net
Internet Source

1 %

12

Cimilli, H. "Spiral computed tomographic demonstration of C-shaped canals in mandibular second molars", Dentomaxillofacial Radiology, 2005.
Publication

1 %

13

www.njcponline.com
Internet Source

<1 %

14

ricinus2.mf.uni-lj.si
Internet Source

<1 %

15

Thomas Alexander Fenelon, Peter Parashos. "Prevalence and morphology of C - shaped

<1 %

and - shaped root canal systems in mandibular second molars ", Australian Dental Journal, 2022

Publication

16

Elif Aslan, A. Canberk Ulusoy, B. Güniz Baksı, Ali Mert, B.Hakan Şen. "Cone Beam-CT Evaluation of C-Shaped Canal Morphology In Mandibular Premolar Teeth", Research Square Platform LLC, 2022

Publication

<1 %

17

[bmcoralhealth.biomedcentral.com](https://www.bmcoralhealth.biomedcentral.com)

Internet Source

<1 %

18

pdfs.semanticscholar.org

Internet Source

<1 %

19

www.researchsquare.com

Internet Source

<1 %

20

Min, Y.. "C-shaped Canal System in Mandibular Second Molars Part III: The Morphology of the Pulp Chamber Floor", Journal of Endodontics, 200612

Publication

<1 %

21

Rahimi, Saeed, Shahriar Shahi, Mehرداد Lotfi, Vahid Zand, Majid Abdolrahimi, and Reza Es'haghi. "Root canal configuration and the prevalence of C-shaped canals in mandibular second molars in an Iranian population", Journal of Oral Science, 2008.

Publication

<1 %

22

www.koreascience.or.kr

Internet Source

<1 %

Exclude quotes Off

Exclude matches < 10 words

Exclude bibliography On

A CBCT based cross sectional study on the prevalence and anatomical feature of C shaped molar among Jordanian

GRADEMARK REPORT

FINAL GRADE

/0

GENERAL COMMENTS

Instructor

PAGE 1

PAGE 2

PAGE 3

PAGE 4

PAGE 5

PAGE 6

PAGE 7
