

# Comparison between lung ultrasonography and chest x- ray in the diagnosis of respiratory distress syndrome in preterm neonates in Dr Soetomo General Hospital Surabaya, Indonesia

*by* Muhammad Reza

---

**Submission date:** 11-Jun-2021 10:29AM (UTC+0800)

**Submission ID:** 1604421149

**File name:** neonates\_in\_Dr\_Soetomo\_General\_Hospital\_Surabaya,\_Indonesia.pdf (548.01K)

**Word count:** 2845

**Character count:** 15259

## Comparison between lung ultrasonography and chest x-ray in the diagnosis of respiratory distress syndrome in preterm neonates in Dr. Soetomo General Hospital Surabaya, Indonesia.

Muhammad Reza, Martono Tri Utomo\*, Talitha Yuliaputri Aden

Department of Child Health, Airlangga University, Surabaya, Indonesia

### Abstract

**Background:** Respiratory Distress Syndrome (RDS) is one of the most common cause of respiratory emergency and death in preterm neonates, due to lung immaturity. Chest X-rays take time to implement and interpret. Pulmonary ultrasonography has been developed as a diagnostic modality for neonatal respiratory distress syndrome. The objective of this study is to analyze the comparison of chest X-ray examination and lung ultrasound in the diagnosis of respiratory distress syndrome in preterm neonates.

**Study design:** This study was conducted from July until September 2019. Lung ultrasound was performed on 33 preterm neonates with gestational age  $\leq 34$  weeks. The x-ray instrument used was the Sirius star mobile x-ray unit, and the ultrasound device used was the GE V-Scan dual probe. Statistical analysis test was carried out using the McNemar and Kappa test.

**Results:** Subjects with mean gestation age of 29.64 weeks and birth weight of 1,230 grams. The A-line abnormality was seen in 4 samples. Accompanied by a double lung point image and alveolar-interstitial syndrome. There was no lung pulse or pleura effusion in all samples. The Mc Nemar statistical test value stated that there was no significant difference between the two instruments, with a significant Kappa result of  $p < 0.05$  and a value of 0.633.

**Conclusion:** Lung ultrasound can be used as a more rational approach to diagnosing and treating Respiratory Distress Syndrome (RDS).

**Keywords:** Lung ultrasonography, Chest x-ray, Respiratory Distress Syndrome (RDS), Preterm neonates.

Accepted on April 15<sup>th</sup>, 2021

### Introduction

The infant mortality rate is one of the main health indicators for a country and the world, including the neonate group (aged 0-28 days). Globally, based on WHO data, the neonatal mortality rate is estimated at 32 deaths per 1000 live births in 2015 [1]. The health demographic survey in Indonesia based on data from the health ministry shows that during 2016 there was an average neonatal mortality rate of 25.5 deaths per 1000 live births. The average preterm birth rate in developed countries is about 5%-7% but it is estimated to have a much larger number in developing countries. Indonesia is rank ninth in the world among countries with an average rate of premature births per 100 live births (15.5%) [2]. Respiratory distress syndrome is one of the most common problems in preterm neonates, especially during the first day of life. This is due to surfactant deficiency that gives rise to lung immaturity, both structural and physiological. Decreased pulmonary compliance causes the lung to collapse and atelectasis occurs, indicated by hypoventilation, hypoxemia, and respiratory acidosis. The overall incidence rate of respiratory distress reaches 6.7% [3] and increasing in preterm neonates. The most common cause of respiratory distress in preterm neonates is Respiratory Distress Syndrome (RDS) at 24-27 weeks' gestation; 92% experienced RDS, 88% at 28-31 weeks' gestation, and 76% at 32-34 weeks' gestation.

With the advances in science, the use of antenatal steroid therapy and the introduction of exogenous surfactants as prevention in respiratory distress syndrome therapy have improved the clinical picture and decreased disease morbidity and mortality of the disease. Surfactants are usually found in mature lungs. The function of surfactants is to keep the alveoli sacs open and filled with air. Preterm neonates don't have a sufficient amount of surfactant, they have difficulty in expanding the lung. Surfactant therapy has provided a dramatic improvement in the outcome of respiratory distress syndrome patients. Surfactant therapy must be given as soon as possible so that an accurate early diagnosis with minimal side effects is needed for its future effects [4].

To determine the diagnosis of RDS, it is necessary to have supporting investigations besides physical examination. Chest X-rays take time to implement and interpret. The radiation can develop an impact on the development of the child in the future. Pulmonary ultrasonography has been developed as a diagnostic modality for neonatal respiratory distress syndrome. Apart from being fast and non-invasive, ultrasound can be performed repeatedly without radiation effects. The use of ultrasound is a practical alternative in an emergency, allowing patients to be examined while receiving other treatments without having to be transferred to the radiology room [5]. Many other studies have investigated the use of lung ultrasound in neonatal respiratory distress syndrome. Pulmonary

ultrasound has a very high sensitivity [6] and reliable [7] to detect the etiology of RDS and distinguish it from Transient Tachypnoea of the Newborn (TTN), pneumonia, and meconal aspiration syndrome [8]. Other studies have stated that the accuracy is not good enough to replace chest X-rays as the gold standard in diagnosing RDS [9]. However, it is quite useful and efficient in differentiating neonatal respiratory distress syndrome [10]. Based on these problems, it is necessary to conduct a study to compare the accuracy of lung ultrasound with chest X-ray in premature neonates in determining the diagnosis of respiratory distress syndrome, so that fast and precise management can be carried out. We present a study of diagnosing RDS in Preterm Neonates using lung ultrasonography in July 2019 aiming to prove its accuracy compared to chest x-ray and increase safety in our complex paediatric population.

## Materials and Methods

This study began in July 2019, until a minimum of 31 samples were met. The research subjects were preterm neonates, born and treated in the NICU room of Dr. Soetomo, Surabaya. The inclusion criteria were neonates aged less than 24 hours at the time of receiving treatment and a chest X-ray was carried out before the age of 24 hours. Patients who met the inclusion criteria were recorded in gender, weight, gestational age, mode of delivery, history of prenatal lung maturation, breathing aid therapy during lung ultrasound (NIV or invasive ventilation). Chest X-ray was performed in an anteroposterior position and transthoracic lung ultrasound in supine and lateral decubitus position. The exclusion criteria were clinical signs of congenital malformations, maternal infection history during pregnancy, rupture of membranes for greater than 18 hours, meconium-stained amniotic fluid, a pulmonary ultrasound that was not performed immediately after chest X-ray, infants who had been given surfactant therapy, and parents disagreeing to be included in the research. The x-ray instrument used was the Sirius Star Mobile X-Ray Unit, and the ultrasound device used was the GE V-Scan Dual Probe. Statistical analysis test was carried out using the McNemar and Kappa test to obtain significance and agreement between lung ultrasound and chest X-ray as the gold standard diagnosis. Ethical clearance was given, number 1302/KEPK/VII/2019 dated July 16, 2019.

## Results

This study was conducted from July 2019 until the sample was fulfilled in September 2019. After going through the exclusion process, 33 patients were obtained as the study sample with a mean gestation age of 29.64 weeks and a birth weight of 1,230 grams. Born through caesarean section were 18 (54.5%) with the most common cause: pre-eclampsia, hypertension, and premature rupture of membranes. Eleven (33.3%) samples were born with asphyxia and had undergone resuscitation at birth. A total of 21 samples were male (63.6%) and 12 samples (36.4%) female. The entire study sample was divided into three groups according to gestational age with the largest number of samples being 28-31 weeks of gestation, namely 21 (63.6%)

samples, then 32-34 weeks, namely 9 (27.3%) samples and <28 weeks 3 (9.1%) sample. Very low birth weight (1,000-1,499 grams) is the largest sample size in this study. In preterm neonates who experienced clinical signs of RDS, only 4 (12.1%) samples had received complete lung maturation therapy; 3 samples from the 32-34 week group, and 1 sample from the 28-31 week group. Twenty-three (69.7%) samples had received lung maturation therapy but were not complete according to the proper protocol, and the remaining samples did not receive lung maturation therapy at all (Table 1). Of the total 33 samples, a total of 29 samples were diagnosed with RDS, based on lung ultrasound or chest X-ray, and the other two samples were diagnosed with TTN (Table 2).

Variable	N, (33)	%
Mode of delivery		
Sectio Caesarea	18	54,5
Spontaneous labor	15	45,4
Gender		
Boy	21	63,6
Girl	12	36,4
Gestational age		
<28 weeks	3	9,1
28-31 weeks	21	63,6
32-34 weeks	9	27,3
Birth weight		
<1000 gram	8	24,2
1000-1499 gram	16	48,5
≥ 1500 gram	9	27,3
Lung maturation history		
Not given	6	18,2
Not completed	23	69,7
Completed	4	12,1
Asfixia	11	33,3
Breathing support		
NIV	29	87,8
Invasive Ventilation	4	12,2

**Table 1.** Subjects characteristics.

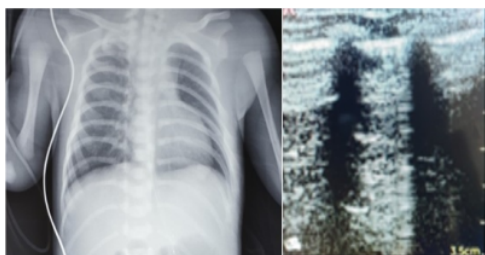
Lung consolidation with subpleural air bronchogram was found in 29 samples of the 2nd-degree respiratory distress syndrome group (Figure 1) based on chest X-ray and looked a little faint at grade 1 (Figure 2). In contrast to the sample group with grade 3 and 4 respiratory distress syndrome, consolidation and air bronchogram images are more visible. Although sometimes obscured by the alveolar-interstitial syndrome image found in the lung posterior region. White-lung appearance was found in 14 samples diagnosed with grade 3

1  
**Comparison between lung ultrasonography and chest x-ray in the diagnosis of respiratory distress syndrome in preterm neonates in Dr. Soetomo General Hospital Surabaya, Indonesia.**

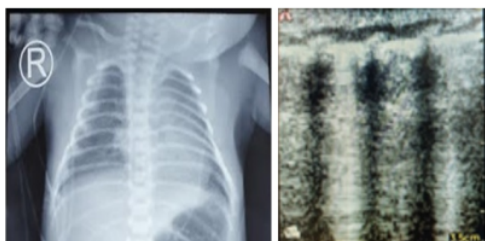(Figure 3) and grade 4 (Figure 4) RDS. The remaining sample group was diagnosed with grade 1 and 2 RDS, 15 samples showed Alveolar-Interstitial Syndrome (AIS). From the lung ultrasonography, the A-line abnormality was seen in 4 samples with the TTN (Figure 5). Accompanied by a double lung point image and AIS. There was no lung pulse or pleura effusion in all samples. The Mc Nemar statistical test value stated that there was no significant difference between the two instruments, with a significant Kappa result of  $p < 0.05$  and a value of 0.633 indicating the agreement value between the two instruments used (Table 3).

Methods		Chest X-ray	Total	
Lung Ultrasonound		RDS	Not RDS	
	RDS	29	1	30
	Not RDS	1	2	3
Total		30	3	33

2  
**Table 2.** Diagnosis result between lung ultrasound and chest X-ray in the diagnosis of RDS.



**Figure 1.** First-grade of RDS.



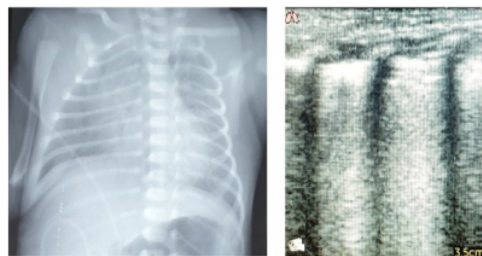
**Figure 2.** Second-grade of RDS.

Variable	Value
Mc Nemar Test	1.000
Kappa Significancy	P 0.000
Kappa Value	0.633

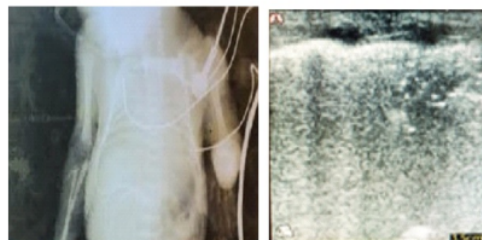2  
**Table 3.** Comparison between lung ultrasound and chest X-ray in the diagnosis of RDS.

**Discussion**

This study was conducted to find significant results, agreement value, and whether there was a difference between lung ultrasound examination and chest X-ray in diagnosing neonatal respiratory distress syndrome. The gestational age range with the incidence of RDS in preterm neonates in this study was less than 34 weeks. The most incidence was found in the 28-31 weeks gestation group, namely 63.6% of the total sample. These results are consistent with other studies that show the incidence of RDS increases with lower gestational age [11]. This study also shows that the largest group was babies born with very low weight. As in previous studies, gestational age is an absolute value in determining the degree of lung immaturity, where a low gestational age indicates immature alveoli cells. The incidence of perinatal asphyxia was 33.3% in this study. Previous studies have revealed a linkage of the incidence of asphyxia to the incidence of respiratory distress syndrome. APGAR scores less than 6 at the tenth minute are thought to cause cardiovascular shock and associated with pulmonary hypertension. Pulmonary vasoconstriction causes endothelial cell damage resulting in alveolar cell epithelial damage. Further disrupts surfactant activity then decreased pulmonary compliance, resulting in respiratory distress syndrome. The common cause of maternal complications in this study was pre-eclampsia and gestational hypertension. Previous studies of infants born to pre-eclamptic mothers had a 1.5 greater risk of developing respiratory distress syndrome. Another study also said that gestational hypertension has a close relationship with the incidence of respiratory distress syndrome and the most maternal indications for caesarean section are pre-eclampsia and gestational hypertension [12].

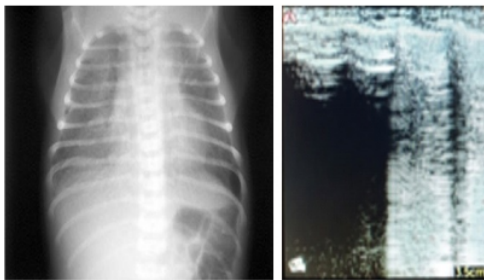


**Figure 3.** Third-grade of RDS.



**Figure 4.** Fourth-grade of RDS.

Pleural line abnormalities evaluation on respiratory distress syndrome is very specific and useful for diagnosis, but it is difficult to do with the transabdominal method [13]. We use the transthoracic method for its superiority over transabdominal, as stated in previous studies that the technique reduced false-positive diagnoses, additional investigations, and unnecessary interventions. Ecographic picture of the Alveolar-Interstitial Syndrome (AIS) when accompanied by a pleural line abnormality, has 100% sensitivity and specificity in diagnosing respiratory distress syndrome [14]. The appearance of lung ultrasound in respiratory distress syndrome is similar to that of Acute Lung Injury (ALI) and Acute Respiratory Distress Syndrome (ARDS) in adults, where abnormalities of the pleural lines and AIS are involved. In this study, it was proven that there was a picture of AIS in all existing research subjects, including the involvement of abnormalities from pleural lines [15]. In the acute phase of RDS, the clinical picture can change significantly over time, built on by the natural severity of the disease and the impact of the care given especially resuscitation and breathing support. This increases the risk of bias due to the likelihood of changes occurring due to increased disease severity or, conversely, the response to treatment. Therefore, to reduce bias, we performed a lung ultrasound immediately after the chest X-ray. The statistical calculation obtained using the Kappa test with  $p < 0.05$  and a Kappa value of 0.633 stated that the agreement value between the lung ultrasound and chest X-ray was 63.3%. While the McNemar test value of 1,000 stated that there was no significant difference between the two instruments.



**Figure 5.** Imaging of TTN that can also be found in RDS.

### Conclusion

Based on this research, accurate results are obtained and are related to the suitability of the results given. We concluded that lung ultrasound can be used as a more rational approach to diagnosing and treating RDS.

### Acknowledgments

The author thank Dr. Evita Bermanshah Ifran for the expert advice and support throughout this research. We thank Dr. Risa Etika, Dr. Dina Angelika and Dr. Kartika Dharma Handayani for valuable discussion and useful suggestions.

### References

1. [https://www.who.int/pmnch/media/news/2012/preterm\\_birth\\_report/en/](https://www.who.int/pmnch/media/news/2012/preterm_birth_report/en/)
2. <https://pusdatin.kemkes.go.id/resources/download/pusdatin/profil-kesehatan-indonesia/Profil-Kesehatan-indonesia-2019.pdf>
3. Kumar A, Vishnu Bhat B. Epidemiology of respiratory distress of newborns. *Indian J Pediatr* 1996; 63: 93-8.
4. Miller JD, Carlo WA. Pulmonary complications of mechanical ventilation in neonates. *Clin Perinatol* 2018; 35: 273-81.
5. Liu J, Cao H, Liu Y. Lung ultrasonography for the diagnosis of neonatal respiratory distress syndrome: A pilot study. *Zhonghua Er Ke Zhi Chin J Pediatr* 2013; 51: 205-10.
6. Hiles M, Culpam AM, Watts C, et al. Neonatal respiratory distress syndrome: Chest X-ray or lung ultrasound? A systematic review. *Ultrasound* 2012; 25: 80-91.
7. Liu J, Cao HY, Wang HW, et al. The role of lung ultrasound in diagnosis of respiratory distress syndrome in newborn infants. *Iran J Pediatr* 2015; 25: e323.
8. Copetti R, Cattarossi L, Macagno F, et al. Lung ultrasound in respiratory distress syndrome: a useful tool for early diagnosis. *Neonatology* 2016; 94: 52.
9. Abdelsadek A, Khair MDA, Naga OA. Lung ultrasound as early diagnostic tool in neonatal respiratory distress syndrome (RDS). *Egypt J of Chest Dis and Tuber* 2015; 1: 1-6.
10. Rachuri H, Oleti TAPI, Murki S, et al. Diagnostic Performance of point of care ultrasound in identifying the etiology of respiratory distress in neonates. *Indian J Pediatr* 2017; 84: 267-70.
11. Bohn D, Dargaville P, Davis P, et al. Acute neonatal respiratory failure. *Pediatric Neonat Mech Ventil* 2014; 1185-1265.
12. Asztalos EV, Murphy KE, Willan AR, et al. MACS-5 Collaborative Group. Multiple courses of antenatal corticosteroids for preterm birth study: outcomes in children at 5 years of age (MACS-5). *JAMA Pediatr* 2013; 167: 1102-10.
13. Liu J, Chi JH, Ren XL, et al. Lung ultrasonography to diagnose pneumothorax of the newborn. *Am J Emerg Med* 2017; 35: 1298-1302.
14. Lichtenstein D, Mauriat P. Lung ultrasound in the critically ill Neonate. *Curr Pediatr Rev* 2012; 8: 217-23.
15. Copetti R, Soldati G, Copetti P. Chest sonography: A useful tool to differentiate acute cardiogenic pulmonary edema from acute respiratory distress syndrome. *J Cardiovasc Ultrasound* 2008; 6.

1  
*Comparison between lung ultrasonography and chest x-ray in the diagnosis of respiratory distress syndrome in preterm neonates in Dr. Soetomo General Hospital Surabaya, Indonesia.*

**\*Correspondence to:**

Martono Tri Utomo  
Department of Child Health,  
Dr. Soetomo General Hospital,  
Jl. Mayjen Prof. Dr. Moestopo No. 6-8,  
Surabaya, Indonesia  
Tel: +6281703667063  
E-mail: [mmartono73@gmail.com](mailto:mmartono73@gmail.com)

# Comparison between lung ultrasonography and chest x-ray in the diagnosis of respiratory distress syndrome in preterm neonates in Dr Soetomo General Hospital Surabaya, Indonesia

## ORIGINALITY REPORT

13%

SIMILARITY INDEX

7%

INTERNET SOURCES

12%

PUBLICATIONS

0%

STUDENT PAPERS

## PRIMARY SOURCES

1	"ESPR 2018", <i>Pediatric Radiology</i> , 2018 Publication	2%
2	Qiang Fei, Yu Lin, Tian-Ming Yuan. "Lung Ultrasound, a Better Choice for Neonatal Pneumothorax: A Systematic Review and Meta-analysis", <i>Ultrasound in Medicine &amp; Biology</i> , 2021 Publication	1%
3	<a href="http://medultrason.ro">medultrason.ro</a> Internet Source	1%
4	"Neonatal Lung Ultrasonography", Springer Science and Business Media LLC, 2018 Publication	1%
5	<a href="http://journals.sagepub.com">journals.sagepub.com</a> Internet Source	1%
6	<a href="http://pesquisa.bvsalud.org">pesquisa.bvsalud.org</a> Internet Source	1%

7

Rosy Setiawati, Ika Ruriana, Priyambodo, Giuseppe Guglielmi. "Anthropometry Study Using Adult Pelvic 3D CT for Determining Sexes at Dr. Soetomo General Hospital, Indonesia", Research Square Platform LLC, 2021

Publication

1 %

8

D Kurepa, N Zaghloul, L Watkins, J Liu. "Neonatal lung ultrasound exam guidelines", Journal of Perinatology, 2017

Publication

1 %

9

Matthew Hiles, Anne-Marie Culpan, Catriona Watts, Theresa Munyombwe, Stephen Wolstenhulme. "Neonatal respiratory distress syndrome: Chest X-ray or lung ultrasound? A systematic review", Ultrasound, 2017

Publication

1 %

10

[www.kfafh.org](http://www.kfafh.org)

Internet Source

1 %

11

Happy K. Sawires, Eman A. Abdel Ghany, Nouran F. Hussein, Hadeel M. Seif. "Use of Lung Ultrasound in Detection of Complications of Respiratory Distress Syndrome", Ultrasound in Medicine & Biology, 2015

Publication

<1 %



12 Chung-Sing Li, Shih-Ming Chu, Reyin Lien, Tze-Yee Mok, Kai-Hsiang Hsu, Shen-Hao Lai. "Prospective investigation of serial ultrasound for transient tachypnea of the newborn", *Pediatrics & Neonatology*, 2020  
Publication

---

13 [link.springer.com](http://link.springer.com)  
Internet Source

---

14 Neda Razaz, Amanda Skoll, John Fahey, Victoria M. Allen, K. S. Joseph. "Trends in Optimal, Suboptimal, and Questionably Appropriate Receipt of Antenatal Corticosteroid Prophylaxis", *Obstetrics & Gynecology*, 2015  
Publication

---

15 [embryology.med.unsw.edu.au](http://embryology.med.unsw.edu.au)  
Internet Source

---

16 [emedicine.medscape.com](http://emedicine.medscape.com)  
Internet Source

---

17 Alessandro Perri, Riccardo Riccardi, Rossella Iannotta, Domenico V. Di Molfetta, Roberta Arena, Giovanni Vento, Enrico Zecca. "Lung ultrasonography score versus chest X-ray score to predict surfactant administration in newborns with respiratory distress syndrome", *Pediatric Pulmonology*, 2018  
Publication

---

18 Hong Cui, Yingxue Ding, Yang Yu, Lijun Yang. "Changes of amplitude integration electroencephalogram (aEEG) in different maturity preterm infant", Child's Nervous System, 2013  
Publication <1 %

---

19 Jing Liu, Hai-Ying Cao, Wei Fu. "Lung ultrasonography to diagnose meconium aspiration syndrome of the newborn", Journal of International Medical Research, 2016  
Publication <1 %

---

20 [systematicreviewsjournal.biomedcentral.com](http://systematicreviewsjournal.biomedcentral.com)  
Internet Source <1 %

---

21 [worldwidescience.org](http://worldwidescience.org)  
Internet Source <1 %

---

22 C. J. D. McKinlay, S. R. Dalziel, J. E. Harding. "Antenatal glucocorticoids: where are we after forty years?", Journal of Developmental Origins of Health and Disease, 2014  
Publication <1 %

---

23 Arrabella King, Douglas Blank, Risha Bhatia, Faezeh Marzbanrad, Atul Malhotra. "Tools to assess lung aeration in neonates with respiratory distress syndrome", Acta Paediatrica, 2019  
Publication <1 %

---

---

Exclude quotes      On

Exclude matches      Off

Exclude bibliography      On

# Comparison between lung ultrasonography and chest x-ray in the diagnosis of respiratory distress syndrome in preterm neonates in Dr Soetomo General Hospital Surabaya, Indonesia

---

## GRADEMARK REPORT

---

FINAL GRADE

**/100**

GENERAL COMMENTS

**Instructor**

---

PAGE 1

---

PAGE 2

---

PAGE 3

---

PAGE 4

---

PAGE 5

---