

Massive cystic hygroma of the neck with respiratory distress in newborn

by Martono Tri Utomo

Submission date: 22-Jul-2021 12:58PM (UTC+0800)

Submission ID: 1622611287

File name: tic_hygroma_of_the_neck_with_respiratory_distress_in_newborn.pdf (3.26M)

Word count: 2343

Character count: 12992



Massive cystic hygroma of the neck with respiratory distress in newborn

Martono Tri Utomo, Aminuddin Harahap^{*}, Risa Etika

⁵
Department of Child Health, Faculty of Medicine, Universitas Airlangga, Dr. Soetomo General Hospital, Jalan Mayjen Prof. Dr. Moestopo No. 6-8, Surabaya, 60286, Indonesia

ARTICLE INFO

Keywords:
Congenital tumor
Cystic hygroma
Respiratory distress

ABSTRACT

Cystic hygroma is one of the congenital benign tumors of the lymphatic system, which commonly occurs on the neck and axial area. Despite its benign nature, cystic hygroma of the neck is potentially a life-threatening condition. The massive mass on the neck may block the neonatal airway. Here we report a newborn baby presented with cystic hygroma on the neck, which impairs the neonatal airway and breathing. Complete excision was carried out. The patient had an uneventful postoperative recovery.

1. Introduction

Cystic hygroma (CH) manifests as mono- or multiloculated mass due to abnormal fluid accumulation inside the lymphatic vessels. It is predominantly occurs in the cervicofacial regions (80%), particularly at the posterior cervical triangle in infants which accompanied by enlargement of jugular lymphatic sacs concomitantly [1,2]. The other sites are axilla (20%), mediastinum extension (10%), and only 1% confined to the chest [1,3]. The CH of the neck results from maldevelopment between the lymphatic and venous systems [4]. They mostly occur in the infant and children population, and rarely seen in adults [1,5]. The overall incidence varies between 1:286 to 1:1000 in different studies [2]. In this case, we reported the giant cystic hygroma on the neck that cause respiratory distress on newborn.

2. Case report

2.1. Case presentation

A 2700 g male newborn was referred to our tertiary referred hospital due to respiratory distress syndrome and a giant mass on his neck (Fig. 1). The baby was delivered by cesarean section (CS) in secondary hospital from a 34-year-old mother with gravida 4, para 3, at 34 weeks of gestation, with breech presentation, oligohydramnios, and history of CS. The patient has trouble breathing in which the previous hospital had oxygen administration using CPAP PEEP 6 FiO₂ 30%. From delivery history, the patient was not crying vigorously after born with a final APGAR score of 6–7.

On the present physical examination, the respiratory rate was 52

breaths per minute, the temperature was 36.6°Celsius, pulse was 154 beats per minute, and the SaO₂ was 94%. The large, mobile, spherical mass on the patient's right neck size was approximately 7 × 4 × 5 cm. The chest x-ray and abdominal x-ray were foreseeable (Fig. 2). The patient was transferred to the neonatal intensive care unit (NICU) with Continuous Positive Airway Pressure (CPAP) support for further monitoring and treatment. We administer D10% infusion 250 cc/24 hours, calcium gluconate injection five cc/24 hours, and oxygen administration using oxygen bubble CPAP PEEP 6 with a flow of 6 L per minute.

The patient underwent neck USG on the fourth day of hospitalization. On USG, the thyroid was within normal limits, and no lymph node enlargement was found. The mass appears as a non-enhancing hypo-dense cystic mass, septated, multiloculated, and has a well-defined border that was extending from the right side to the posterior side of the neck (Fig. 3). The Color Doppler revealed no intralesional or perilesional vascularization. We were suspected of cystic hygroma. Fetal echocardiography was performed on the same day that revealed mild tricuspid regurgitation.

On the fifth day of hospitalization, the patient shows improvement by breathing spontaneously with room air. The respiratory rate was 45 breaths per minute, the temperature was 37.5°Celsius, pulse was 150 beats per minute, and SaO₂ was 96%. Later on, the patient was prepared for surgical planning to complete excision of the mass.

2.2. Treatment

The patient was placed in a supine position. 10% povidone-iodine was used to disinfect the operating area. A transverse incision was made over the supratoral and continued down to expose the mass wall. The cyst was then freed from the surrounding tissue (Fig. 4A). The

12

^{*} Corresponding author.
E-mail address: aharahap71@yahoo.co.id (A. Harahap).

<https://doi.org/10.1016/j.epsc.2021.101945>

Received 27 May 2021; Accepted 5 June 2021

Available online 7 June 2021

2213-5766/© 2021 The Authors.

Published by Elsevier Inc.

This is an open access article under the CC BY-NC-ND license

<http://creativecommons.org/licenses/by-nc-nd/4.0/>

Abbreviations

CH	Cystic hygroma
CT scan	Computed Tomography scan
CPAP	Continous positive airway pressure
NICU	Neonatal intensive care unit
SaO ₂	Saturation oxygen
USG	Ultrasonography

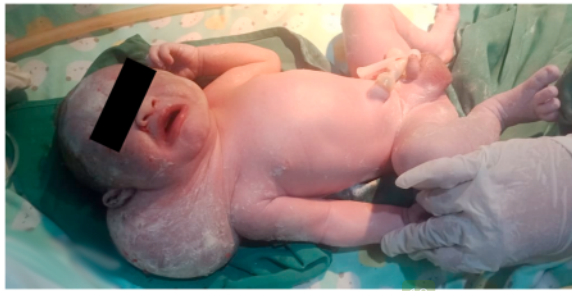

Fig. 1. Clinical presentation of the mass. Large mass on the right side of the neck extending to posterior, soft, and freely mobile.

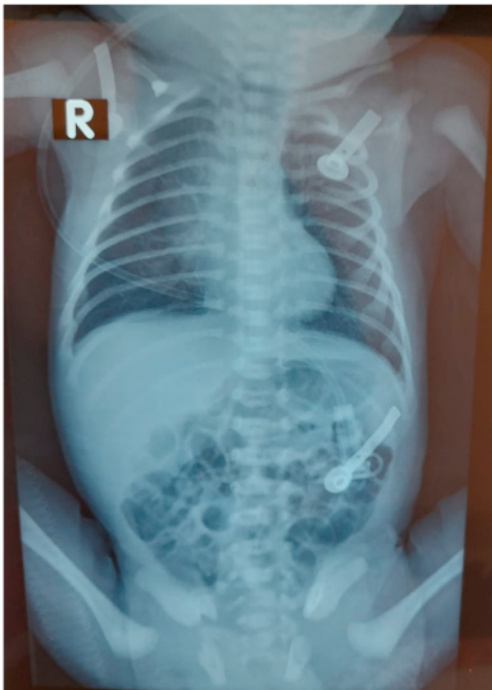

Fig. 2. The chest and abdominal x-ray were within normal limits.

jugular vein and the sternocleidomastoid muscle were preserved. A drain was placed, and the surgical wound was sutured (Fig. 4B). The postoperative course was uneventful.

The mass was sent for histopathological examination. Externally, the mass size 6.5 × 6.4 × 1 cm with a rough as well as smooth surface

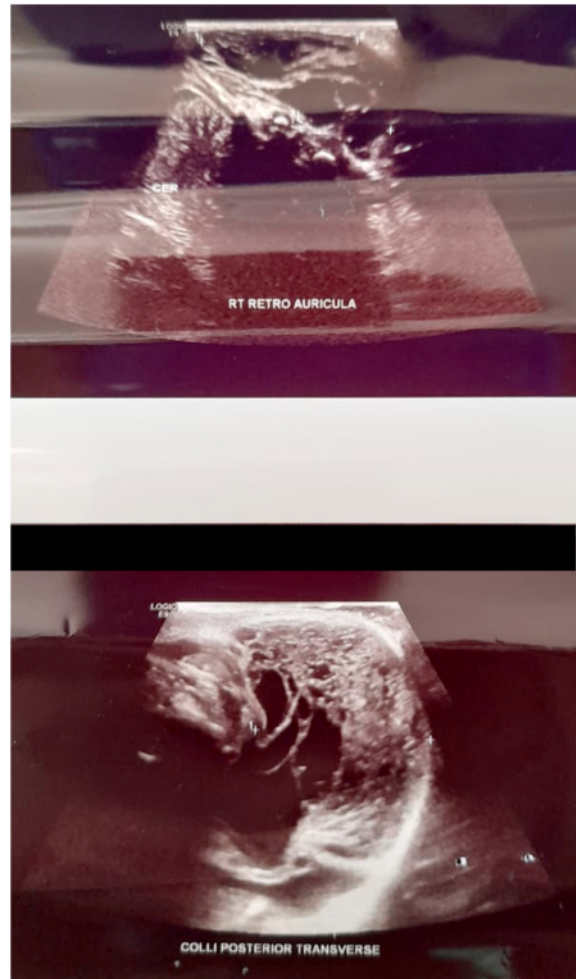


Fig. 3. Neck USG shows non-enhancing hypodense cystic mass, septated, multiloculated, with well-defined border.

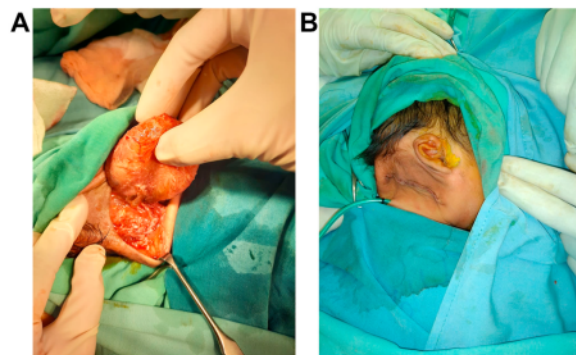


Fig. 4. 4A. Complete excision of the cyst. 4B. Postoperation, the mass has been removed.

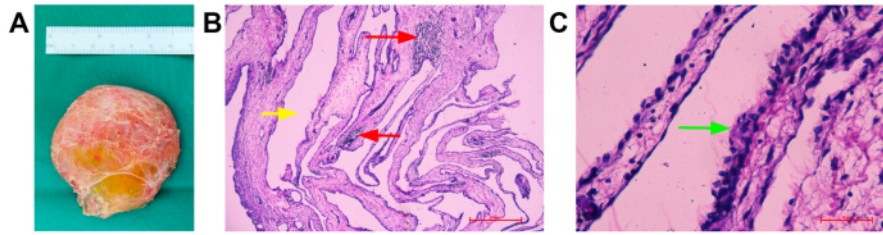


Fig. 5. 5A. Gross appearance of cystic hygroma. 5B. Proliferation and dilatation of lymphatic vessels (yellow arrow) with lymphoid aggregates (red arrow) (x40). 5C. Swelling of the stroma with mononuclear cell infiltration (green arrow) (x400).

(Fig. 5A). After cutting open, the cystic masses revealed multiple small cysts containing yellowish-green jelly-like substance and yellow fluid. Histopathological examination showed large, proliferated, and dilated lymphatic vessels with lymphoid aggregates (Fig. 5B). The stroma was swollen with mononuclear cell infiltration (Fig. 5C). There was no evidence of a specific process or malignancy. The conclusion was cystic hygroma.

3. Discussion

CH is a benign congenital tumor of lymphatic system that develops at the end of the sixth week of gestation [6]. It occurs during embryonic development caused by failure of the lymphatic tissue to communicate with the central lymphatic system and venous system. Afterward, the dilatation of the isolated lymphatic tissues happen which gives the cystic morphology of CH [7]. It manifests as large single or multiple loculated cysts filled with serous secretions [3]. It often appears at birth (60%), and up to 90% become overt before the age of two [3]. It is associated with other congenital anomalies such as Down and Turners syndromes and also heart defects [4]. In our patient, after suspected as cystic hygroma in neck USG, we performed echocardiography immediately then found a mild tricuspid regurgitation.

The head and necks are the most common sites of origin (80%), but it also can extend into the floor of the mouth, the pharyngeal wall, and the mediastinum [1,3]. The patient with cervical CH may present with dyspnea/respiratory compromise/respiratory distress due to airway obstruction or feeding problem/dysphagia [1,3,7]. Cervical CH on newborn was at high risk of respiratory distress. Therefore, airway management is essential during delivery process [4,6]. In our patient, respiratory distress was occurs and the patient required oxygen support using CPAP.

These lesions appear soft, compressible, non-tender, transluminal, and without any bruit on clinical manifestation [3,7,8]. Chest x-ray is important for all cases to identify the intra-thoracic extension. Tumors located in the mediastinum may require further diagnostic examination such as angiography, CT scan, and fluoroscopy [4].

This anomaly is usually noticed via USG in the first trimester or at the beginning of the second trimester [9]. The prenatal diagnosis using ultrasonography (USG) may shown a septated or non-septated bilateral thin-walled cystic lesion in the fetal occipitocervical region in both the sagittal and axial plane [2,3]. Sometimes, CH may have mixed echo images due to the combination of cystic and solid components inside the mass. No blood flow is detected on color doppler USG [3]. On CT scan, the mass appear as multicystic, homogenous, and low attenuation mass [3].

Evidence of fetal anasarca/hydrops fetalis may be present. The presence of septations may indicate a poorer outcome, while greater volumes (>75 mm³) are thought to correlate with increased karyotypic abnormality and also poorer outcomes. Abnormal karyotypes occur in 86.6% of cases. Karyotyping analysis of amniotic fluid may be carried out to rule out the associated congenital syndromes and aneuploidies [6]. Fetal echo is recommended for detecting cardiac anomalies which

can bother viability [10]. The incidence of major cardiac pathologies in CH is 4.3% [6]. Antenatal diagnosis of fetal cystic hygroma is essential not only for prognostication but also for planning the mode of delivery and postnatal management [6]. Teamwork consists of obstetrician, pediatrician, pediatric surgeon, anesthesiologist, and radiologist are required.

Although CH has benign characteristic, the behavior is unpredictable. Most of them progressively grow bigger in size, while some cases may experience spontaneous regression. Respiratory distress, recurrent infection, dysphagia, bleeding, sudden enlargement of mass, lymph discharging sinus, or cosmetic reason are the main indications of the treatment. Complete surgical excision is still the definitive treatment for CH [3].

However, the surgery itself is also a complex task. The high mortality rate of the neonate with large cervical CH was noticed due to increased incidence of postoperative complications include respiratory obstruction secondary to edema of the airway, airway collapse, tongue edema, rapid expansion of residual cyst due to bleeding; inflammation complications include injury to the hypoglossal nerve, facial nerve, carotid vessels, thoracic duct, and pleura and internal jugular vein; further postoperative complication include wound infection, bleeding, hypertrophied scar, and lymphatic discharge. Incomplete excision may cause infiltration to the adjacent structure. However, the recurrency may occurs even after complete excision surgery (20% of the cases) [4]. Patient follow-up is needed to detect the possibility of recurrence.

Another treatment modality is intralesional sclerotherapy with OK432. OK432 is a sclerosing agent which irritating endothelial lining that leads to inflammation, fibrosis, and involution [10]. It has been accepted as a safe and effective alternative treatment. It may be used as a primary treatment or after recurrent cystic hygroma or partial surgery treatment. However, it works better in simple cysts [9]. Sclerotherapy was reserved for macro cystic lesions, whereas surgical excision was required for microcystic lesions or airway compromise or sclerotherapy failure [10].

In the first trimester, cystic hygroma can be associated with major congenital anomalies, aneuploidy, pregnancy loss, and developmental disorders [2]. This lesions also can get infected at any time. The primary infection site was from respiratory tract infection. During infection, the lesions appear more swollen, warm, red, and tender. Fever may be present. Sometimes the cystic hygroma turns into an abscess which needs drainage. Another complication was spontaneous bleeding in the cyst, which needs urgent surgery and respiratory difficulties and dysphagia [3].

The outcome of cystic hygroma is associated with the timing of onset. The first-trimester onset tends to have the worst outcome than detected later in pregnancy [2,6]. First-trimester cystic hygroma has a strong association with aneuploidy. It is often associated with the prevalence of Turner syndrome and trisomy 21 (50–80%) [1–3]. Most fetuses with cystic hygromas have a poor prognosis, especially if associated with abnormal karyotype and other congenital anomalies [10]. Several cases may regress in utero on their own. Spontaneous remission does not necessarily exclude an abnormal karyotype [1].

4. Conclusion

Cystic hygroma is a rare tumor in the pediatric population. Complete excision still becomes a therapeutic option. Despite its benign nature, recurrency may occur in 20% of cases. Patients diagnosed with CH in antenatal period require follow-up to detect other anomalies and monitoring the fetal hydrops. The cyst size and structure, location, and infiltration signs are important prognostic factors.

Patient consent

Patient's family gives permission for patient information to be published in scientific journal anonymously.

Funding

No funding or grant support

Authorship

All authors attest that they meet the current ICMJE criteria for Authorship.

Declaration of competing interest

The following authors have no financial disclosures: AH, MTU, RE.

References

- [1] Cystic hygroma | radiology reference article. Radiopaedia.org n.d. <https://radiopaedia.org/articles/cystic-hygroma-1>. [Accessed 13 May 2021].
- [2] Schreurs L, Lannoo L, de Catte L, van Schoubroeck D, Devriendt K, Richter J. First trimester cystic hygroma colli: retrospective analysis in a tertiary center. *Eur J Obstet Gynecol Reprod Biol* 2018;231:60–4. <https://doi.org/10.1016/j.ejogrb.2018.10.019>.
- [3] Mirza B, Ijaz L, Saleem M, Sharif M, Sheikh A. Cystic hygroma: an overview. *J Cutan Aesthetic Surg* 2010;3:139. <https://doi.org/10.4103/0974-2077.74488>.
- [4] Rao K, Shenoy T. Anesthetic management of a large cystic hygroma in a newborn. *Anesth Essays Res* 2015;9:270. <https://doi.org/10.4103/0259-1162.156364>.
- [5] Bhatia V, Taksande R, Sondankar D. Cystic hygroma in an adult male: a diagnostic challenge. *Iranian Journal of Pathology* 2015;10:310–3.
- [6] Noia G, Pellegrino M, Masini L, Visconti D, Manzoni C, Chiaradia G, et al. Fetal cystic hygroma: the importance of natural history. *Eur J Obstet Gynecol Reprod Biol* 2013;170:407–13. <https://doi.org/10.1016/j.ejogrb.2013.07.043>.
- [7] Guruprasad Y, Chauhan DS. Cervical cystic hygroma. *Journal of Maxillofacial and Oral Surgery* 2012;11:333–6. <https://doi.org/10.1007/s12663-010-0149-x>.
- [8] Cystic hygroma - StatPearls - NCBI bookshelf n.d. <https://www.ncbi.nlm.nih.gov/books/NBK560672/>. [Accessed 26 May 2021].
- [9] Temizkan O, Abike F, Ayvaci H, Demirag E, Görücü Y, Isik E. Fetal axillary cystic hygroma: a case report and review. *Rare Tumors* 2011;3:122–5. <https://doi.org/10.4081/rt.2011.e39>.
- [10] Behera S, Bawa M, kanojia RP, Saha PK, Singh T, Samujh R. Outcome of antenatally diagnosed cystic hygroma - lessons learnt. *Int J Pediatr Otorhinolaryngol* 2020;138. <https://doi.org/10.1016/j.ijporl.2020.110227>.

Massive cystic hygroma of the neck with respiratory distress in newborn

ORIGINALITY REPORT

17%

SIMILARITY INDEX

9%

INTERNET SOURCES

15%

PUBLICATIONS

0%

STUDENT PAPERS

PRIMARY SOURCES

- 1 Saswati Behera, Monika Bawa, Ravi P. kanojia, Pradip Kumar Saha, Tulika Singh, Ram Samujh. "Outcome of antenatally diagnosed cystic hygroma - Lessons learnt", International Journal of Pediatric Otorhinolaryngology, 2020
Publication 3%
- 2 Khalid Shreef, Yahia Alsagr, Mohammed Beaiti, Hmad Hader. "An unusual abdominal mass: A left ureteric cyst", Journal of Pediatric Surgery Case Reports, 2020
Publication 2%
- 3 Osman Temizkan, Faruk Abike, Habibe Ayvaci, Ersan Demirag, Yasin Görücü, Ecmel Isik. "Fetal axillary cystic hygroma: a case report and review", Rare Tumors, 2017
Publication 2%
- 4 jultika.oulu.fi
Internet Source 1%
- 5 www.inabj.org
Internet Source 1%

6	pericles.pericles-prod.literatumonline.com Internet Source	1 %
7	Mitra Mehrad, Douglas R. Gnepp. "Cysts of the Neck, Unknown Primary Tumor, and Neck Dissection", Elsevier BV, 2021 Publication	1 %
8	helda.helsinki.fi Internet Source	1 %
9	Anoop M, Rajeev Kumar Nishad, Shobhit Gupta, Yogendra Yadav. "Role of Bleomycin Sclerotherapy as a Non-surgical Method for the Treatment of Cystic Hygroma of Head and Neck Region-an Institutional Study", Indian Journal of Otolaryngology and Head & Neck Surgery, 2020 Publication	1 %
10	ijp.iranpath.org Internet Source	1 %
11	digitalcommons.wustl.edu Internet Source	1 %
12	pureportal.coventry.ac.uk Internet Source	1 %
13	Alper Gezdirici, Ali Ekiz, Elif Yılmaz Güleç, Başak Kaya, Salim Sezer, Alev Atış Aydın. "How necessary is to analyze gene in fetuses with first trimester cystic hygroma and	1 %

normal karyotype? ", The Journal of Maternal-Fetal & Neonatal Medicine, 2016

Publication

14

G. Noia, M. Pellegrino, L. Masini, D. Visconti, C. Manzoni, G. Chiaradia, A. Caruso. "Fetal cystic hygroma: the importance of natural history", European Journal of Obstetrics & Gynecology and Reproductive Biology, 2013

Publication

1 %

15

Jerry Tsung-Kai Lin, Johnny Chuieng-Yi Lu, Yenlin Huang, Tommy Nai-Jen Chang, David Chwei-Chin Chuang. "Lymphangiomatous Tumors of the Neck", Annals of Plastic Surgery, 2018

Publication

1 %

16

bmcpregnancychildbirth.biomedcentral.com

Internet Source

<1 %

17

www.thefreelibrary.com

Internet Source

<1 %

18

Jessica Scholl, Stephen T. Chasen. "First trimester cystic hygroma: does early detection matter?", Prenatal Diagnosis, 2016

Publication

<1 %

Exclude quotes On

Exclude matches Off

Exclude bibliography On

Massive cystic hygroma of the neck with respiratory distress in newborn

GRADEMARK REPORT

FINAL GRADE

/100

GENERAL COMMENTS

Instructor

PAGE 1

PAGE 2

PAGE 3

PAGE 4
