

Kutu Kepala pada pasien Geriatri dengan Komplikasi Sepsis dan anemia Laporan Kasus

by Rahmadewi Rahmadewi

Submission date: 25-Apr-2023 12:34AM (UTC+0800)

Submission ID: 2074162826

File name: n_Geriatri_dengan_Komplikasi_Sepsis_dan_anemia_Laporan_Kasus.pdf (639.16K)

Word count: 3844

Character count: 20666

Kutu Kepala pada Pasien Geriatri dengan Komplikasi Sepsis dan Anemia: Laporan Kasus

(Pediculosis Capitis with Complication Sepsis and Anemia In Elderly Patient: A Case Report)

Rahmadewi, Riyana Noor Oktaviyanti

Departemen/SMF Ilmu Kesehatan Kulit dan Kelamin

Fakultas Kedokteran Universitas Airlangga/Rumah Sakit Umum Daerah Dr. Soetomo Surabaya

ABSTRACT

Background: Pediculosis is an ectoparasitic infestation of human scalp. Infestation is characterized by intense itching, secondary infection, and anemia in cases of severe infestation, and inadequate diet. Treatment of head lice includes physical methods, topical pediculicides, and oral agents. **Purpose:** To report a case of pediculosis capitis with complication of sepsis and anemia in elderly patient **Case:** A women, 80 year-old, body weight 45 kilograms, came to Emergency Room of Dr. Soetomo General Hospital with complaint about malaise, low appetite, and sometimes fever since 1 week ago. Patient also complained about itchy sensation on her scalp appeared since 3 months ago. There were many lice on her scalp. Itchy sensation was felt all day. Patient took a bath only once daily, and spent her time on bed because patient had a hemiparese since 6 months ago. History of the same disease in the family, her grandson also had the same complaint (lice on scalp). No history of bleeding or gastrointestinal bleeding. Patient had a low appetite. There were so many lice on her scalp, with erosion and crustae. Patient was treated with systemic antibiotic ceftriaxone injection 2 times 1 gram daily, metronidazole drip 3 times 500 mg, Packed Red Cell (PRC) transfusion 2 kolf /day until Hb more than 10 g/dl, permethrin 1 % (Peditox). The treatments gave a good result. **Discussion:** Head-to-head contact is by far the most common route of lice transmission. We assumed that the infestation could stem directly from hair in hair contact, or indirectly, e.g. towels, which may have been already used by infected people. The source of contagious in this case could be from her grandson who also had the same complaint (lice on scalp). Treatment of pediculosis is permethrin 1%, other options if these treatments don't work include malathion, benzyl alcohol, spinosad, and topical ivermectin. **Conclusion:** This patient was successfully treated with permethrin 1 % (Peditox) and repeated treatment after 7 days gave good results and in this case there were no side effects. Patient education is the key in preventing pediculosis capitis and also reminding patients that they can help to prevent the spread of these parasites.

Key words: head lice, pediculosis capitis, permethrin 1%.

ABSTRAK

Latar Belakang: Pedikulosis adalah infestasi ektoparasit pada kulit kepala manusia. Infestasi yang banyak dari kutu ditandai dengan gatal yang sangat kuat, infeksi sekunder, dan anemia dijumpai pada kasus yang parah dan pada keadaan diet yg kurang. Pengobatan kutu meliputi metode fisik, topikal, dan agen oral. **Tujuan:** Melaporkan suatu kasus kutu kepala pada pasien geriatri dengan komplikasi sepsis dan anemia. **Kasus:** Seorang wanita, 80 tahun, berat badan 45 kilogram, datang ke Instalasi Gawat Darurat Rumah Sakit Umum Dr. Soetomo dengan keluhan lemas, kurang nafsu makan, dan terkadang demam. Keluhan dirasakan sejak 1 minggu yang lalu. Pasien mengeluh tentang gatal pada kulit kepalanya muncul sejak 3 bulan yang lalu. Terdapat banyak kutu di kulit kepalanya. Sensasi gatal terasa sepanjang hari. Pasien hanya mandi satu kali sehari, dan menghabiskan waktunya di tempat tidur karena pasien mengalami hemiparese sejak 6 bulan yang lalu. Ada riwayat penyakit yang sama dalam keluarga, cucunya juga memiliki keluhan yang sama (kutu pada kulit kepala). Tidak ada riwayat perdarahan atau perdarahan pencernaan, nafsu makan berkurang. Pemeriksaan fisik terdapat banyak kutu di kulit kepala, dengan luka dan sisik. Pasien diterapi dengan antibiotik sistemik injeksi seftriakson 2x1 gram, metronidazol 3x500 mg, transfusi packed red cell (PRC) 2 kolf/hari sampai Hb lebih dari 10 g/dl, permetrin 1% (peditox). Terapi memberikan hasil yang baik dan tidak didapatkan efek samping pada pasien. **Pembahasan:** Kontak secara langsung adalah jalur transmisi kutu yang paling umum. Diduga infestasi dapat berasal langsung dari kontak dengan rambut, atau secara tidak langsung seperti handuk, yang mungkin sudah pernah digunakan oleh orang yang terinfeksi. Sumber penularan kasus ini dari cucunya yang juga memiliki keluhan yang sama (kutu pada kulit kepala). Terapi pedikulosis adalah permetrin 1%. Pilihan lain jika perawatan ini tidak berhasil meliputi malation, benzil alkohol, spinosad, dan ivermektin topikal. **Simpulan:** Pasien ini berhasil diobati dengan permetrin 1% (Peditox) dengan pengulangan dalam 7 hari memberikan hasil yang baik dan tidak ada efek samping. Pendidikan pasien adalah kunci dalam mencegah pedikulosis kapitis dan mengingatkan pasien bahwa mereka dapat membantu mencegah penyebaran parasit ini.

Kata kunci: kutu kepala, pedikulosis kapitis, permetrin 1%.

Alamat korespondensi: Rahmadewi, Departemen Ilmu Kesehatan Kulit dan Kelamin, Fakultas Kedokteran Universitas Airlangga, Rumah Sakit Umum Daerah Dr. Soetomo, Jl. Mayjen Prof Dr. Moestopo No. 6-8 Surabaya 60131, Indonesia. Telepon: +62315501609, e-mail: dewimbo@yahoo.co.id

INTRODUCTION

Pediculosis is an ectoparasitic infestation of human scalp. The causative lice *Pediculus humanus var. capitis* (Anoplura: Pediculidae), feed on the human blood. An infestation is commonly encountered in pediatric population in the age group of 6 - 12 years. In rural areas, prevalence rate ranges from in the age group of 3 - 13 years, ranges varies from 13.3% to 49%. Girls are 2 to 4 times more frequently infested than boys, especially in rural and developing areas owing to their hair length. Although pediculosis is not a major health problem (no vector-borne disease reported), it can be cause of social embarrassment, isolation, parental anxiety, peer-criticism, unnecessary absenteeism from academics and difficult issue for school authorities to handle.¹

Its diagnosis is based on the detection of adults, nymphs and/or viable eggs in the human head, which represents an active infestation and requires an appropriate treatment for its control.² The characteristic itch that is classic of head lice infestations is caused by irritation from saliva injected by the feeding louse. This might take 2 to 6 weeks to develop with the first infestation, and subsequent infestations might take hours for symptoms to start.³

Transmission occurs mainly by direct person-to-person contact or by instruments such as shared combs, pillows, and hats. Climate, geography, ethnicity, and hygienic conditions play a role in spreading lice. Head lice are blood-sucking insects that can cause pruritus, excoriation, conjunctivitis, secondary bacterial infection, local post-therapeutic dermatitis, posterior neck adenopathy, unspecific generalized dermatitis, anemia, and allergic reactions resulting in nasal obstruction and rhinorrhea.^{4,5}

Infestation is characterized by intense itching, secondary infection, and anemia in cases of severe infestation and inadequate diet. Severe infestations are associated with low socioeconomic status, hair characteristics, parasite resistance to insecticides, genetic factors, and cultural habits.³ Treatment of head lice includes physical methods, topical pediculicides, and oral agents. Choice of treatment is determined by age, louse resistance patterns particular to the local area, and potential toxicity. The physical removal of eggs has become an important part of treatment of louse infestations. Topical pediculicides require 2 applications 7 to 10 days apart, as no pediculicide is completely ovicidal and in order to reduce the development of resistance. These agents quickly

immobilize and kill lice.³

These lice survive from a blood meal from their host. Although the amount of blood ingested during a single feed is extremely small, a heavily infested individual over an extended period of time might be expected to be susceptible to iron deficiency anemia. This might particularly be the case in an individual with poor nutrition or additional risk factors for iron deficiency anemia such as slow gastrointestinal bleeding. Considering the animal reports of iron deficiency anemia consequent to heavy louse infestation, it is not unexpected that blood sucking *P. humanus capitis* and corporis could have a similar effect in humans. Complication of pediculosis capitis are secondary infection, sepsis, anemia, and serival, occipital lymphadenopathy. Sepsis is a life-threatening condition in which the body is fighting a severe infection that has spread via bloodstream. Anemia is a medical condition in which the red blood cell count or hemoglobin is less than normal.⁶⁻⁸

We report a case of pediculosis capitis in elderly patient with complication sepsis and anemia but fortunately give good result either clinical and laboratory at the end of treatment period, and no contagious person was reported.

Case

A woman, 80 year old, body weight 45 kilograms, came to Emergency Room of Dr. Soetomo General Hospital with main complaint itchy sensation and there are some lice on her scalp, malaise, decrease appetite and sometimes fever. Patient come to Emergency Room with complaint about malaise, low appetite, and sometime fever since 1 week ago. Patient also complaint about itchy sensation on her scalp appeared since 3 months ago. There are many lice on her scalp. Itchy sensation felt all day long. Patient just take a bath once daily, and spent her time on bed because patient had a hemiparesis since 6 months ago. There are history of the same disease in the family, her grandson also has the same complaint (lice on scalp). No history of bleeding or gastrointestinal bleeding. Patient has a low appetite. History of Diabetes Melitus was denied but this patient had history of hypertension. She never had different sexual partner and never had genital complaint before, no history of transfusion before. On general examination, patient look not well, compositis. The Blood pressure 100/60, heart rate 82 times per minute, respiration rate 20 times per minute, body temperature 36,7 degree celcius. No

icteric or cyanosis, there were anemic in his eyes. There were enlargement of retroauricular lymphonodes. No abnormality in thorax and abdomen examination. The dermatological examination on regio capital of his scalp there were macule erythematous,

unsharplymarginated with multiple papules. There were so many lice on her scalp, with erosion and crustae. No lice on regio eyebrows, eyelashes, and pubis (Figure 1).

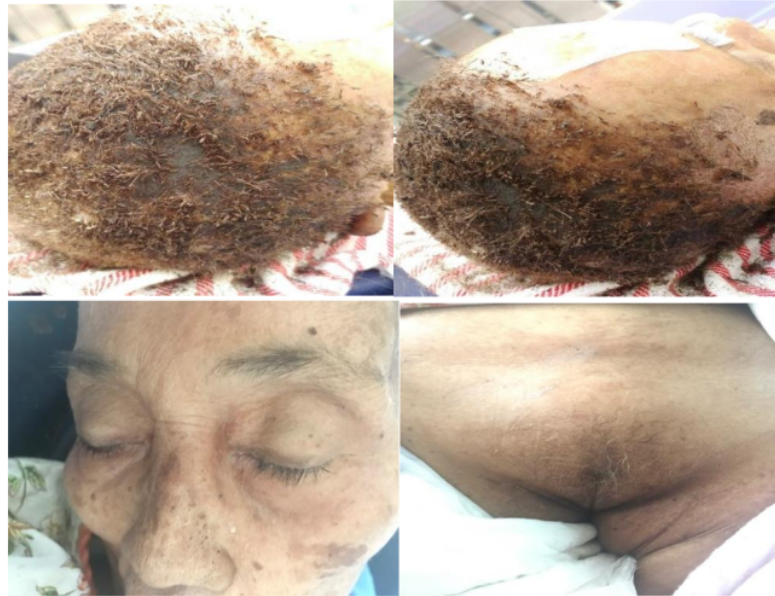


Figure 1. So many lice on scalp, no lice on eyebrow, eyelash, and pubis.

From the blood examination, there was low level of haemoglobin (7,1 g/dl), increase on leucocyte number (15.450/mm³), HIV Rapid Test non reaktif. Urinary test, electrolyte, liver and renal function test

when she admitted were within normal limit. Result from blood smear with anemia hypochromic microcytic. The scapping examination there were lice (Figure 2).

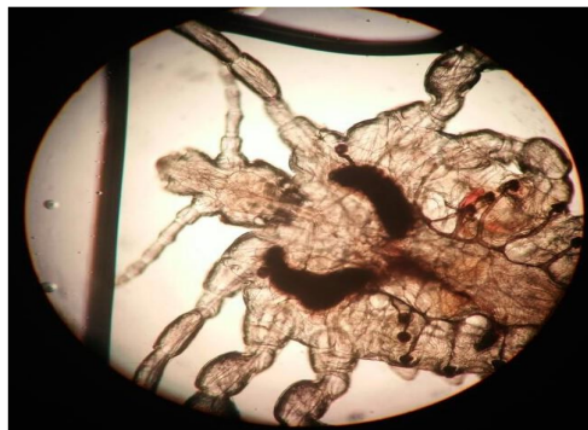

Figure 2. The scrapping examination showing scabiei mite, 100 times magnification.

Diagnose was made from anamnesis, physical examination, laboratory examination, and scrapping

examination. The diagnosis in this patient was pediculosis capitis with complication sepsis and

anemia.

This patient treated with systemic antibiotic ceftriaxone injection 1 gr 2 times daily, metronidazole drip 500 mg 3 times daily, PRC transfusion 2 kolf/day until HB more than 10g/dl permethrin 1 % (Peditox) apply to all over the scalp and hair, but secondary infection area not involved and after that cover it with bath

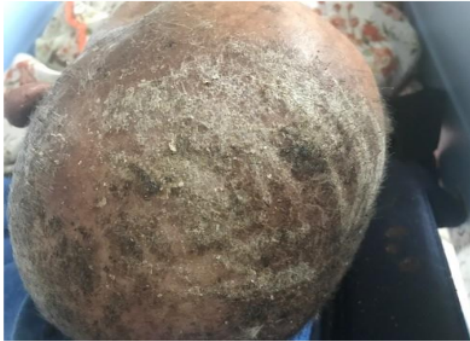

Figure 3. After 2 days treatment, lice on scalp were decreased and erosions still present.

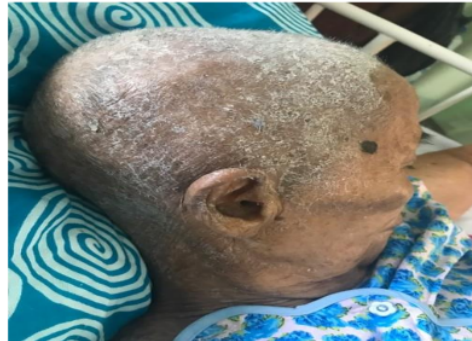

Figure 4. After 7 days treatment, no head lice and erosion got improvement.

DISCUSSION

Pediculosis infestation by *Pediculus Capitis* (head lice), has worldwide distribution, and is observed in all age groups, though particularly among children. It is considered one of several ectoparasites neglected by the scientific community and healthcare authorities. Its diagnosis is based on the detection of adults, nymphs and or viable eggs in the human head, which represents an active infestation and requires an appropriate treatment for its control. Head lice are considered to be a public health problem of both developed as well as developing countries. For example in Australia 13% of the children were infested by head lice. In Brazil, the prevalence of head louse infestations was as high as 43% in urban areas and 28% in rural areas. Similarly, in China, the prevalence of pediculosis has been on average 14%. In England, it is 2%. Interestingly, in developed countries such as Canada and the United States, Caucasians are more frequently infested as compared with black individuals. Similar reports have shown that pediculosis is more prevalent in low income groups. In general, girls are infested more frequently than boys, between the ages of 3–11 yr. From 1% to 3%, and the incidence rate has been estimated to be 800 and 2400 new cases per 10.000 children per year.^{9,10}

This is a case of pediculosis capitis in elderly, 80 years old, with anemia and sepsis. Close personal contact and sharing of headgear is the chief mode of transmission among susceptible contacts. Head to head

contact is by far the most common route of lice transmission. Head louse cannot fly as they lack wings, and they do not possess powerful legs for jumping. They move from one infested hair to another with the help of claw on their legs.¹ In this case a number of lice more than 200 adults and nits of *Phthirus* present on her head. Suggested a primary infection more than a month. The origin of this extraordinary infestation in this geriatric patient can only be hypothetical. An indirect contamination, e.g. towel, could also not be neglected. For this case, considering to her age and her normal mental state, the sexual transmission hypothesis was rejected due to the absence of louse in her pubis hair. We therefore suppose that the infestation could stem directly from hair to hair contact, or indirectly, e.g. towels, which may have been already used by infected people. The source of contagious of this case could be from her grandson also has the same complain (lice on scalp).¹¹

Infestation is characterized by intense itching, secondary infection, and anemia in cases of severe infestation and inadequate diet. Bites of the mites may produce 2 mm erythematous macules or papules, but usually an examiner only excoriations, erythema, and scaling. The most common symptom seen in the patients is itching on the scalp, appearing approximately 7-10 days after sensitivity to the parasite's saliva or excrement antigens. After successful landing on scalp skin, head louse takes a blood meal (hematophagia) usually 4 to 5 times per

day. A single study conducted by Speare and associates attempted to quantitate the amount of blood a single head louse ingests during a single feed. The value ranged from 0.0000387 mL to 0.0000657 mL in female and male lice, respectively.¹ While taking a blood meal, lice injects its saliva through the scalp skin to prevent clotting of blood, thereby maintaining the fluidity for an easy sucking. Although any part of the scalp may be colonized, lice favour the nape of the neck and the area behind the ears, where the eggs are usually laid. During its lifespan of 4 weeks, a female louse can lay 50–150 Eggs.¹² Severe infestations are associated with low socioeconomic status, hair characteristics, parasite resistance to insecticides, genetic factors, and cultural habits. Chronic and heavy lice infestation can rarely lead to secondary bacterial infection and sepsis (criteria $t > 38^{\circ}\text{C}$, leucocyte > 12.000 U/l, RR > 20 x/minute, HR > 90 x/minute and suspected infection), anemia, especially in rural females who are already suffering from iron deficiency anemia. Severe pyoderma of the scalp can rarely lead irregular patches of cicatricial alopecia and cervical and occipital lymphadenopathy.^{1,7,8}

In this case patient with clinical presentation pruritus, macule erythematosus, excoriations and crustation. In Internal Department patient diagnose with sepsis and cervical lymphadenopathy cause complication from chronic and heavy lice. Considering the animal reports of iron deficiency anemia consequent to heavy louse infestation, it is not unexpected that bloodsucking *P. humanus capitis* and *corporis* could have a similar effect in humans.⁶

The diagnosis of pediculosis requires the presence of live lice on the scalp, not only the presence of nits (hatched empty eggshells). The human head louse (*Pediculus humanus capitis*) is a parasite with 6 legs that cannot fly or jump, thus lice are transmitted by head to head contact. As obligate human blood feeders, lice do not survive away from a human host for more than 3 days. The role and extent of fomite transmission (eg, hats, hair accessories, bedding) remains controversial.² An adult louse deposits eggs close to the scalp and the eggs hatch within 6 to 9 days. Within 9 to 15 days these nymphs mature to adults and begin laying eggs. The life span of a louse is generally 3 to 4 weeks and it can lay 50 to 150 eggs in this time frame.¹² Eggs are laid by an adult fertile female and are cemented at the base of the hair shaft nearest the scalp. To attach each egg, the adult female secretes glue-like substance from her reproductive organ. This glue quickly hardens into a “nit sheath” that covers the hair shaft and the entire egg except for the operculum, a cap through which the embryo respire. They are hard to see and are often confused for dandruff or hair spray

droplets. The term nit refers to either a louse egg or a louse nymph. These nits cannot be moved along the hair shaft in contrast to pseudonits. They are of size 0.8 mm by 0.3 mm, oval and usually yellow to white. Nits take about 1 week to hatch (range 6 to 9 days). Viable eggs are usually located within 6 mm of the scalp as morphogenesis is enhanced at human body temperature. A single fertile female can lay about 150–250 eggs during its 30-day life cycle.¹

Head lice can be treated with pyrethroids, pediculicide shampoos containing pyrethrin or permethrin. Pyrethrins and pyrethroids (eg, 1% permethrin) are the most common pediculicides. These agents quickly immobilize and kill lice. When released, pyrethrin and pyrethroid treatments were 88% to 99% successful in eradicating infestations; however, after their widespread use, studies in the past 10 years demonstrated efficacy of only 10% to 75%. The marked reduction in effectiveness reflects the development of resistance in *Pediculus humanus capitis*, which is documented worldwide and which has grown rapidly with susceptibility patterns varying substantially even between schools. The common side effect of topical treatments is local irritation with scalp burning and itching. Those allergic to ragweed, chrysanthemums, or related plants should avoid pyrethrins, as they might develop dyspnea and wheeze.^{1-3,5}

All pediculicidal agents should be rinsed after prescribed time limit with cool water over a sink. Rinsing with warm water can increase systemic absorption due to vasodilation of scalp vasculature. The physical removal of eggs has become an important part of treatment of louse infestations. Head lice can be treated with pyrethroids, pediculicide shampoos containing pyrethrin or permethrin. Pyrethrins and pyrethroids (eg, 1% permethrin) are the most common pediculicides. These agents quickly immobilize and kill lice. When released, pyrethrin and pyrethroid treatments were 88% to 99% successful in eradicating infestations; however, after their widespread use, studies in the past 10 years demonstrated efficacy of only 10% to 75%. The marked reduction in effectiveness reflects the development of resistance in *Pediculus humanus capitis*, which is documented worldwide and which has grown rapidly with susceptibility patterns varying substantially even between schools. The common side effect of topical treatments is local irritation with scalp burning and itching. Those allergic to ragweed, chrysanthemums, or related plants should avoid pyrethrins, as they might develop dyspnea and wheeze.¹³ Any suspected bacterial infection should be treated with anti staphylococcal antibiotic, preferably first generation

cephalosporin (cephalexin: Adult dose- 0.25-1 mg 6-8 hourly) and further antibiotic therapy should be tailored as per microbiological studies.¹ For choice of treatment is determined by age, louse resistance patterns particular to the local area, and potential toxicity. Treatment also includes decontamination of clothing, bedding, towels, stuffed animals, and all personal items by washing them in hot, soapy water that's at least 130°F (54°C) or drying on high heat for a minimum of 20 minutes.^{1-3,5}

This patient successful treated with permethrin 1 % (Peditox) and repeat in 7 days give good results on the kill lice and in this case there were no side effects. Patient also get systemic therapy ceftriaxone injection 1 gr 2 times daily, metronidazole drip 500 mg 3 times daily, and PRC transfusion 2 kolf/day until HB>10 U/l. Patient education is key in preventing pediculosis capitis and remind patients that they can take measures to help prevent the spread of these parasites.

REFERENCES

1. Madke M, Khopkar U. Pediculosis capitis: An update. *Indian J Dermatol Venereol Leprol* 2012;78(4):429-39.
2. Gallardo A, Toloza A, Vassena C, Picollo MI, Cueto GM. Comparative efficacy of commercial combs in removing head lice (*Pediculus humanus capitis*) (Phthiraptera: Pediculidae). *Parasitol Res* 2013;112:1363–6.
3. Christine H. Smith MB BS Ran D. Goldman MD FRCP. An incurable itch. *Canadian Family Physician* 2012;58:839-41.
4. Gulgun M, Balci E, Karaoglu A, Babacan O, Türker T. Pediculosis capitis: prevalence and its associated factors in primary school children living in rural and urban areas in kayseri, turkey. *Cent Eur J Public Health* 2013;21(2):104–8.
5. Barbosa CS, Moroni BR, Mendes J, Justiniano CSB, Moroni FT. Head lice in hair samples from youths, adults and the elderly in manaus, amazonas state, brazil. *Rev. Inst. Med. Trop. Sao paulo* 2015;57(3):239-44.
6. Guss DA, Koenig M, Castillo EM. Severe iron deficiency anemia and lice infestation. *J Emerg Med* 2011;41(4):362-5.
7. Singer M, Deutschman CS, Seymour CW, Shankar-Hari M et al. Third International Consensus Definitions for Sepsis and Septic Shock (Sepsis-3) *JAMA* 2016; 315: 801-10.
8. Angus DC, Poll TVD. Severe Sepsis and Septic Shock. *N Engl J Med* 2013;369: 840-51.
9. Tagka A, Lambrou GI, Braoudaki M, Panagiotopoulos, Papanikolaou E, Laggas D. Socioeconomical Factors Associated With Pediculosis (Phthiraptera: Pediculidae) in Athens, Greece. *Journal of Medical Entomology* 2015:1–4.
10. Take Z, Tekin Z, Karadağ AS. A Pediculid Case: Autosensitization dermatitis caused by pediculosis capitis. *Türkiye Parazitol Derg* 2012; 36:185-7.
11. Akhouni M, Cannel A, Arab MK, Marty P, Delaunay P. An old lady with pediculosis pubis on the head hair. *JEADV* 2016;30: 852–909
12. Insaurralde IO, Toloza AC, Picollo MI, Vassena C. Influence of the formulations in removing eggs of *Pediculus humanus capitis* (Phthiraptera: Pediculidae). *Parasitol Res* 2014; 113:3439–44.
13. Mary SM, Messikh R, Jeudy A. Assessment of the efficacy and safety of a new treatment for Head Lice. *ISRN Dermatol* 2012; 1-6.

Kutu Kepala pada pasien Geriatri dengan Komplikasi Sepsis dan anemia Laporan Kasus

ORIGINALITY REPORT

13%

SIMILARITY INDEX

11%

INTERNET SOURCES

8%

PUBLICATIONS

2%

STUDENT PAPERS

PRIMARY SOURCES

| | | |
|---|--|----|
| 1 | static.uc.ac.id Internet Source | 1% |
| 2 | repository.unair.ac.id Internet Source | 1% |
| 3 | ppjpi.unair.ac.id Internet Source | 1% |
| 4 | go.gale.com Internet Source | 1% |
| 5 | parazitoloji.dergisi.org Internet Source | 1% |
| 6 | Akina Nara, Hisashi Nagai, Rutsuko Yamaguchi, Yohsuke Makino, Fumiko Chiba, Ken-ichi Yoshida, Daisuke Yajima, Hirotarō Iwase. "An unusual autopsy case of lethal hypothermia exacerbated by body lice-induced severe anemia", International Journal of Legal Medicine, 2015 Publication | 1% |

| | | |
|----|---|------|
| 7 | Internet Source | 1 % |
| 8 | jamanetwork.com Internet Source | 1 % |
| 9 | Ahmad, Hesham M., Eman S. Abdel-Azim, and Rasha T. Abdel-Aziz. "Assessment of topical versus oral ivermectin as a treatment for head lice : Topical versus oral ivermectin for head lice", <i>Dermatologic Therapy</i> , 2014. Publication | 1 % |
| 10 | pdfcookie.com Internet Source | 1 % |
| 11 | www.emedicinehealth.com Internet Source | 1 % |
| 12 | www.scribd.com Internet Source | 1 % |
| 13 | oak.go.kr Internet Source | <1 % |
| 14 | van der Wouden, Johannes C, Tim Klootwijk, Laurence Le Cleach, Giao Do, Robert Vander Stichele, Arie Knuistingh Neven, Just AH Eekhof, and Johannes C van der Wouden. "Interventions for treating head lice", <i>Cochrane Database of Systematic Reviews Protocols</i> , 2011. Publication | <1 % |

| | | |
|----|---|------|
| 15 | ijpbs.net Internet Source | <1 % |
| 16 | Elham Rezaee, Fatemeh Heidari, Mohammad Nowrouzi. "Investigation of the prevalence of Head Lice and Factors Affecting Them in Infected People Referring to Gerash County Health Center", International Journal of Epidemiologic Research, 2020 Publication | <1 % |
| 17 | www.jtraumainj.org Internet Source | <1 % |
| 18 | isainsmedis.id Internet Source | <1 % |
| 19 | pediatrics.aappublications.org Internet Source | <1 % |
| 20 | studentsrepo.um.edu.my Internet Source | <1 % |

Exclude quotes On
Exclude bibliography On

Exclude matches Off

Kutu Kepala pada pasien Geriatri dengan Komplikasi Sepsis dan anemia Laporan Kasus

GRADEMARK REPORT

FINAL GRADE

/100

GENERAL COMMENTS

Instructor

PAGE 1

PAGE 2

PAGE 3

PAGE 4

PAGE 5

PAGE 6
