

# Psoriasis Vulgaris in Human Immunodeficiency Virus Infected Patient: A Case Report

*by Rahmadewi Rahmadewi*

---

**Submission date:** 25-Apr-2023 12:35AM (UTC+0800)

**Submission ID:** 2074163719

**File name:** human\_immunodeficiency\_virus\_infected\_patient\_a\_case\_report.pdf (432.72K)

**Word count:** 2962

**Character count:** 16586

# *Psoriasis Vulgaris in Human Immunodeficiency Virus Infected Patient: A Case Report*

**Rahmadewi, Maya Wardiana**

*Department of Dermatology and Venereology Faculty of Medicine Universitas Airlangga  
Dr. Soetomo General Academic Hospital Surabaya-Indonesia*

## **ABSTRACT** <sup>16</sup>

**Background:** Psoriasis vulgaris (PV) is a chronic inflammatory skin disease characterized by erythematous thick scaly plaques. PV in human immunodeficiency virus (HIV) infected patient can give severe clinical features and challenging to treat since the treatment are immunosuppressive drugs. **Purpose:** To report a case of psoriasis vulgaris in HIV infected patient. **Case:** A 39 year-old man complained about scaly redness patches on his back and elbow that spread accompanied by burning sensation. From physical examination, on almost all over his body there were erythematous plaques sharply marginated with thick scales. Histopathologic examination from skin biopsy revealed parakeratosis, acanthosis, with psoriasiform hyperplasia and Munro's microabscesses consistent to PV. The patient was treated with methotrexate tablets. After 8 days hospitalization, white plaque appeared on his tongue. Potassium hydroxide examination (KOH) 10% and 3 methods HIV test was done with positive result. Because of HIV positive methotrexate was stopped. Antiretroviral therapy (ART) was given and its combination with desoximetasone 0.25% cream after 10 days gave a good result for the PV. **Discussion:** The pathophysiology of PV in HIV infected patient seems to be conflicting due to the involvement of T cell lymphocyte in both diseases. Treatment for PV in HIV infected patient should consider the probability of the immunosuppressive effect of the drugs that can worsen the HIV infection. ART is recommended as the treatment for PV. **Conclusion:** Psoriatic lesion in this patient responded well to ART and desoximetasone 0.25% cream. PV in HIV infected patient requires certain management considering immunological status and immunosuppressive treatment. Early diagnosis of these comorbid condition help to determine appropriate management.

**Key words:** Psoriasis vulgaris, human immunodeficiency virus, antiretroviral therapy.

## **ABSTRAK**

**Latar Belakang:** Psoriasis vulgaris (PV) adalah penyakit kulit inflamasi kronis dengan ciri khas plak eritematus berskuama tebal. PV pada pasien yang terinfeksi *human immunodeficiency virus* (HIV) dapat memberikan gambaran klinis yang lebih parah dan penanganan yang lebih menantang karena terapi yang biasa digunakan adalah obat-obatan imunosupresif. **Tujuan:** Melaporkan suatu kasus psoriasis vulgaris pada pasien terinfeksi HIV. **Kasus:** Seorang laki-laki berusia 39 tahun mengeluhkan bercak merah bersisik yang awalnya muncul pada punggung dan siku kemudian menyebar disertai rasa terbakar. Dari pemeriksaan fisik, di hampir seluruh tubuh terdapat plak eritematus simetris berbatas tegas dengan skuama tebal. Pemeriksaan histopatologis dari biopsi kulit menunjukkan parakeratosis, akantosis dengan hiperplasia psoriasiformis dan mikroabses Munro sesuai dengan PV. Pasien diterapi dengan tablet metotreksat. Setelah 8 hari rawat inap, plak putih muncul pada lidah pasien. Pemeriksaan KOH 10% dan tes HIV 3 metode dilakukan dan hasilnya positif. Oleh karena HIV positif maka pemberian metotreksat tablet dihentikan. *Antiretroviral therapy* (ART) diberikan, kombinasi ART dengan krim desoksimeson 0,25% memberikan hasil yang baik untuk PV. **Pembahasan:** Patofisiologi PV pada pasien terinfeksi HIV nampak bertentangan karena keterlibatan sel limfosit T pada kedua penyakit. Terapi untuk PV pada pasien terinfeksi HIV harus mempertimbangkan kemungkinan efek imunosupresif dari obat yang dapat memperburuk infeksi HIV. ART direkomendasikan sebagai terapi untuk PV. **Simpulan:** Lesi psoriasis pada pasien ini memberikan respons yang baik dengan pemberian ART dan desoksimeson krim 0.25%. PV pada pasien terinfeksi HIV memerlukan manajemen khusus mengingat status imunologis dan terapi yang bersifat imunosupresif. Diagnosis dini kedua kondisi komorbid ini akan membantu penanganan yang lebih tepat.

**Kata kunci:** Psoriasis vulgaris, *human immunodeficiency virus*, *antiretroviral therapy*.

Alamat korespondensi: Rahmadewi, Departemen/Staf Medik Fungsional Ilmu Kesehatan Kulit dan Kelamin, Fakultas Kedokteran Universitas Airlangga/Rumah Sakit Umum Daerah Dr. Soetomo, Jl. Mayjen Prof Dr. Moestopo No. 6-8 Surabaya 60131, Indonesia. Telepon: +62315501609, e-mail: dewimbo@yahoo.co.id

## **INTRODUCTION** <sup>1</sup>

Psoriasis vulgaris (PV) is a chronic inflammatory skin disease, with a strong genetic basis,

characterized by complex alterations in epidermal growth, differentiation with multiple biochemical, immunologic, vascular abnormalities, and a poorly

understood relationship to nervous system function. It has polygenic predisposition with triggering environmental factors such as trauma, infection, or medication. It is characterized by erythematous scaly papules and plaques. The most common sites of involvement are scalp, elbows, knees, hands, feet, trunk, and nails. Joints may also be involved with the form of psoriatic arthritis.<sup>1</sup> Depending on the region, the prevalence of PV varied from 0.09% in the United Republic of Tanzania to 11.4% in Norway. PV is considered equally prevalent in both sexes. However, some studies indicated that psoriasis is more common in men.<sup>2</sup> Prevalence of psoriasis and psoriatic arthritis seems to be higher in human immunodeficiency virus (HIV) infected people than in the general population.<sup>3</sup>

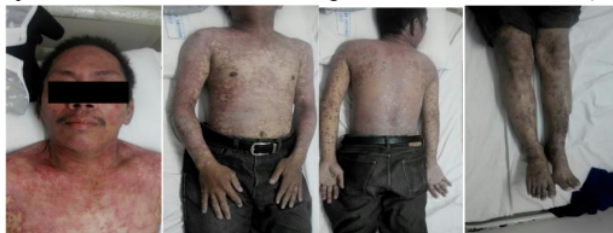The classic lesion of psoriasis is a well demarcated, raised, red plaque with a white scaly surface. Below the scale, the skin has a glossy homogeneous erythema, and bleeding points appear when the scale is removed, traumatizing the dilated capillaries below (the Auspitz sign). PV tends to be a symmetric eruption. Koebner phenomenon is the traumatic induction of psoriasis on nonlesional skin; it occurs more frequently during flares of disease and is an all or none phenomenon (if psoriasis occurs at one site of injury it will occur at all sites of injury). The histopathologic findings of PV show acanthosis and psoriasiform hyperplasia, and accumulation of neutrophils in the stratum corneum (Munro's microabscesses).<sup>1</sup>

PV can be observed in every stage of the HIV infection patient, but its onset seems to be related to low CD4<sup>+</sup> T-cell count. PV in HIV infected patient shows a progressive course and it is resistant to conventional PV treatments. The conventional treatments for PV consist of: immunosuppressive drugs, such as cyclosporine A and methotrexate, which are not easily viable in HIV infected patients.<sup>3,4</sup>

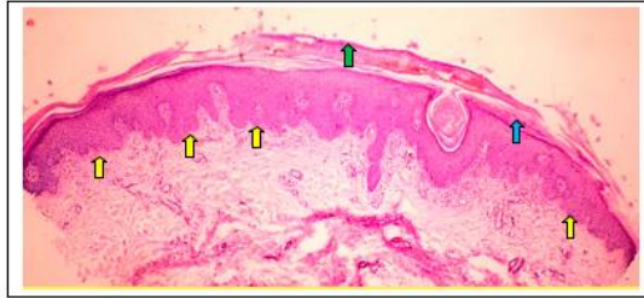
#### CASE

A 39-year-old man came with chief complaint scaly redness patches those first appeared on his back and elbow, and then spread out to almost all over his

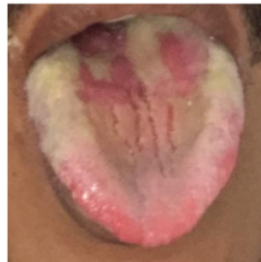
body in the last 1 year with burning sensation. He treated by general practitioner with desoximetasone 0.25% cream with minimal improvement. He admitted that he stressed out because of family's problem in these past 4 months. No joint pain, either without fever, sore throat or cough, toothache, ear's discharge. Physical examination found lesions spread on elbows, knees, face, trunk, superior, and inferior extremities as erythematous plaques sharply margined with thick scales symmetrically (Figure 1). Auspitz sign and koebner phenomenon were positive. The patient was suspected to have PV. A skin biopsy was performed and the histologic examination revealed: parakeratosis, acanthosis with psoriasiform hyperplasia, and Munro's microabscesses specified to PV (Figure 2). The patient was treated with methotrexate tablets 2.5 mg, 3 times for every 12 hours, folic acid 1 mg 2 times daily separately when methotrexate wasn't taken, apply desoximetasone 0.25% cream, and Vaseline album topically. The progression of the lesions were good. But during the day 8<sup>th</sup> hospitalization, white plaque appeared on almost all over his tongue (Figure 3). Potassium hydroxide 10% examination and 3 methods HIV tests were done since oral candidiasis is the one of mucocutaneous manifestations of HIV infection. While waiting for the laboratory result, the patient got another cycle of methotrexate treatment. The result of potassium hydroxide 10% examination pseudohyphae was found. The result of all three methods HIV tests were all reactive. The patient was diagnosed as HIV infection associated with PV. CD4<sup>+</sup> count examination was performed. The result of CD4<sup>+</sup> absolute was 172/mm<sup>3</sup> and CD4<sup>+</sup>% was 13.16%. The conclusion was CD4 counts are greatly decreased. Methotrexate was stopped. Nystatin oral drop was given for the oral candidiasis. Duviral 2 times daily and Neviral once daily was given as antiretroviral therapy (ART). Desoximetasone 0.25% cream as topical treatment for psoriasis lesions. After 10 days combination treatment with ART and and desoximetasone 0.25% cream, there were showed good result of the PV lesions (Figure 4).



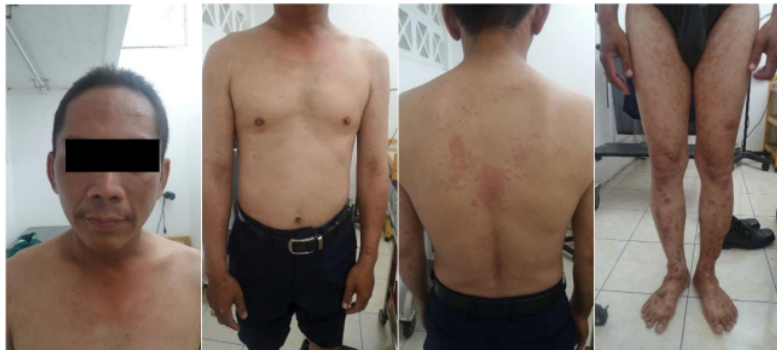**Figure 1.** There were erythematous plaques sharply margined with thick scales on the elbows, knees, face, trunk, superior and inferior extremities symmetrically and erythematous macule sharply margined with white thin scale on the scalp.



**Figure 2.** Parakeratosis (green arrow), acanthosis with psoriasiform hyperplasia (yellow arrows) and Munro's microabscesses (blue arrow). (Hematoxylin & Eosin staining, 40x objective magnification)



**Figure 3.** White plaque on almost all over his tongue suggesting there were oral candidiasis.



**Figure 4.** Ten days after antiretroviral therapy (ART) and desoximetasonone 0.25% cream were given, psoriasis vulgaris lesion showed improvement.

## DISCUSSION

PV is a chronic papulosquamous skin disease that is known to be a T cell mediated autoimmune disorder of keratinocyte proliferation. HIV-associated PV is common condition. PV can be the initial clinical manifestation of HIV infection or as the initial appearance in advanced HIV infection frequently. The clinical manifestation of PV associated with HIV infection case tends to has more severe condition, refractory to the tretatment, and more frequent relapses. The pathophysiology of PV in HIV infected patients is still poorly understood. PV is known to be T cell mediated autoimmune disorder, while HIV infection leads to a decreased of CD4<sup>+</sup> T lymphocytes.

It seems to be paradoxical. Treatment of PV in HIV infected patient also offer a challenge for the clinician, because of the impaired immunological status of the patient, while the conventional treatment for PV is based on using the immunosuppressive drugs.<sup>4,5,6,7</sup>

In our case, a man who was firstly diagnosed as PV. During the hospitalization, oral candidiasis appeared and the 3 methods HIV test results were reactive, and suggesting as PV in HIV infected patient. To understand the pathogenesis of PV in HIV infected patients, it should be noted that T cells can be divided to many categories, such as CD4<sup>+</sup> versus CD8<sup>+</sup>. CD8<sup>+</sup> T cells are predominantly located in the epidermis, whereas CD4<sup>+</sup> T cells are predominantly

located in the upper dermis. In recent years, it is known that CD8<sup>+</sup> lymphocyte has more prominent role in the pathogenesis of PV. Histological evidence reveals that the accumulation of CD8<sup>+</sup> memory lymphocytes in the epidermis is linked to both the onset and exacerbation of PV. Multiple studies of psoriatic patients have shown that CD8<sup>+</sup> T cell concentrations are increased in the epidermis and papillary dermis of lesional skin compared to uninvolved skin. HIV infection leads to the decrease of the CD4<sup>+</sup> T cell count and CD4/CD8 T cell ratio. The HIV virus also affects the naive and memory cell subpopulations differently depending on the T cell type (CD4<sup>+</sup> versus CD8<sup>+</sup>). Studies show that the virus preferentially infects and replicates in CD45RO<sup>+</sup> (memory) CD4<sup>+</sup> T cells; whereas in CD8<sup>+</sup> T cells, it tends to infects the CD45RA<sup>+</sup> (naive) subtype. This contribute to a further depiction that the increase of CD8<sup>+</sup> T lymphocyte is due to the expansion of a specific subpopulation with memory phenotype, implicated in the pathogenesis of psoriasis. Simultaneously, there is a marked decrease in the naive subpopulation of CD8<sup>+</sup> T lymphocytes. These two factors together imply, in patient with HIV infection, 80% of circulating CD8<sup>+</sup> T lymphocytes express a memory phenotype (in contrast to 50% in individuals without HIV infection), thus altering the balance of the immune state favorable to psoriatic disease. In other words, the increased of the CD8<sup>+</sup> T cell memory subset is largely responsible for the exacerbation of PV in immunocompromised condition of HIV infected patient.<sup>4,6,8</sup>

The type of cytokines also plays as the pathogenesis role in HIV and PV case. In general, type 1 cytokines will negatively regulate the production of type 2 cytokines, and vice versa. In HIV infected patient, type 2 cytokines (IL-4, IL-6, IL-10) increases throughout the natural history of this infection. As type 2 cytokines increased, type 1 cytokines (TNF $\alpha$ , IFN $\gamma$ , IL-2) appeared to decrease. In other words, type 2 cytokines predominant throughout the course of the infection. This finding made the exacerbation of PV in HIV infected patients seem paradoxical because the cytokines implicated in PV belong to type 1. Later it is known that despite an increase in type 2 cytokines, there is concomitantly an increase in production of type 1 cytokines to the periphery by some subpopulations of lymphocytes, which is CD8<sup>+</sup> with memory phenotype.<sup>4,6,9</sup>

The treatment of PV in HIV infected patients can be challenging. HIV infection causes immunological status impairment of patients. While the conventional treatment of PV which are immunosuppression drugs. Besides, PV in HIV infected patients is more

refractory to treatment and has more frequent relapses.<sup>3,4</sup> Topical treatment with corticosteroids and vitamin D3 analogues are indicated as the first-line therapy in mild-to-moderate PV as monotherapy or combined with other modalities in severe PV. ART is indicated as the first-line therapy in patients with moderate to severe PV, especially in those with CD4<sup>+</sup> cell count <350 cells/mm<sup>3</sup>, and in some cases monotherapy may be considered. ART not only control the progression of HIV infection, but also effectively control PV. A retrospective study also shows that PV was prevalent among patients without ART.<sup>10,11</sup>

Phototherapy can be added in cases where topical treatment and ART are not sufficient to control PV.<sup>12</sup> When the combination of topical agents, ART, and phototherapy is ineffective in controlling disease activity, or in cases where this combination is not possible, oral retinoids, such as acitretin, can be added to the therapeutic regimen.<sup>4,13,14</sup> The use of oral immunosuppressants is limited to highly selected patients with particularly recalcitrant disease, due to the actual risks of severe immunosuppression HIV infected patients.<sup>4,15</sup> Based on a systematic review, with adequate combination of ART and monitoring for signs and symptoms of infection, the likelihood of serious infection can be minimized.<sup>14</sup> Methotrexate is the most frequent immunosuppressant used in PV. In early cases of PV in HIV infected patient, methotrexate administration was reported to be related to higher incidence of opportunistic infection and progression of HIV infection.<sup>3</sup> The use of methotrexate in HIV infected patient should be considered after risk benefit assessment. Low doses of methotrexate can be given with combination of prophylaxis for opportunistic infection and ART.<sup>3,4</sup> In this case, at first the PV patient with HIV infection that was not established yet methotrexate was given as the treatment and it led to the development of oral candidiasis after 8 days treatment. After the diagnosis of HIV infection was done, methotrexate was stopped and ART was given and combined with desoximetasone 0.25% cream, and showed good improvement after 10 treatment.

Psoriatic lesion in this patient respond well to ART and desoximetasone 0.25% cream. PV in HIV infected patient require certain management considering immunological status and immunosuppressive therapy. Early diagnosis of these comorbid condition help to determine appropriate management.

## REFERENCE

1. Gudjonsson JE, Elder JT. Psoriasis. In: Goldsmith L, Katz S, Gilchrist B, Paller A, Leffell D, Wolff K, editors. Fitzpatrick's Dermatology in General Medicine. New York: McGraw-Hill Medical; 2012. p. 197-231.
2. World Health Organization. Global report on Psoriasis. Geneva: WHO Library Cataloguing-in Publication Data; 2016. p. 5-6.
3. Ceccarelli AM, Rullo EV, Vaccaro M, Facciola A, Aleo FD, Paolucci IA, et al. HIV associated psoriasis: epidemiology, pathogenesis and management. *Dermatol Ther* 2018; e12806:1-21.
4. Alpalhao M, Borges-Costa J, Filipe P. Psoriasis in HIV infection: an update. *Int J STD & AIDS* 2019; 30(6):596-604.
5. Morar N, Willis-owen SA, Maurer T, Bunker CB. HIV associated psoriasis: pathogenesis, clinical features, and management. *Lancet Infect Dis* 2010; 10(7):470-8.
6. Fife DJ, Waller JM, Jeffes EW, Koo JY. Unraveling the paradoxes of HIV-associated psoriasis: a review of T-cell subsets and cytokine profiles. *Dermatol Online J* 2007; 13(2):4.
7. Yen Y-F, Jen I-A, Chen M, Lan Y-C, Lee C-Y, Chuang P-H, et al. HIV infection increases the risk of incident psoriasis: a nationwide population-based cohort study in Taiwan. *J Acquir Immune Defic Syndr* 2017; 75(5):493-9.
8. McBreen S, Imlach S, Shirafuji T, Scott GR, Leen C, Bell JE, et al. Infection of the CD45RA<sup>+</sup> (Naive) subset of peripheral CD8<sup>+</sup> lymphocytes by human immunodeficiency virus Type 1 in vivo. *J Virol* 2001; 75(9):4091-102.
9. Klein SA, Dobbmeyer JM, Dobbmeyer TS, Pape M, Ottmann OG, Helm EB, et al. Demonstration of the Th1 to Th2 cytokine shift during the course of HIV-1 infection using cytoplasmic cytokine detection on single cell level by flow cytometry. *AIDS* 1997; 11(9):1111-8.
10. Tan J, Pina A, Borges-Costa J. Skin diseases in the era of highly active antiretroviral therapy: a retrospective study of 534 patients. *J Int Assoc Provid AIDS Care* 2018; 17(1):1-5.
11. Chiricozzi A, Saraceno R, Cannizzaro MV, Nisticò SP, Chimenti S, Giunta A. complete resolution of erythrodermic psoriasis in an HIV and HCV patient unresponsive to antipsoriatic treatments after highly active antiretroviral therapy (Ritonavir, Atazanavir, Emtricitabine, Tenofovir). *Dermatology* 2012; 225(4):333-7.
12. Fotiades J, Urn HW, Jiang SB, Soter NA, Sanchez M, Moy J. Efficacy of ultraviolet B phototherapy for psoriasis in patients infected with human immunodeficiency virus. *Photodermatol Photoimmunol Photomed* 1995; 11(3):107-11.
13. Van Zander J, Orlow SJ. Efficacy and safety of oral retinoids in psoriasis. *Expert Opin Drug Saf* 2005; 4(1):129-38.
14. Nakamura M, Abrouk M, Farahnik B, Zhu TH, Bhutani Ti. Psoriasis treatment in HIV positive patients: a systematic review of systemic immunosuppressive therapies. *Cutis* 2018; 101(1):38-43.
15. Menon K, Voorhees AS Van, Bebo BF, Gladman DD. Psoriasis in patients with HIV infection: from the medical board of the national psoriasis foundation. *J Am Dermatology* 2009; 62(2):291-9.

# Psoriasis Vulgaris in Human Immunodeficiency Virus Infected Patient: A Case Report

## ORIGINALITY REPORT

16%

SIMILARITY INDEX

11%

INTERNET SOURCES

14%

PUBLICATIONS

0%

STUDENT PAPERS

## PRIMARY SOURCES

1	<a href="http://www.rsu.lv">www.rsu.lv</a> Internet Source	1%
2	<a href="http://www.researchgate.net">www.researchgate.net</a> Internet Source	1%
3	Ali TÜRKAY, Yuliia PAVLIVNA KARVATSKA, Olha IVANIVNA DENYSENKO. "Acute Onset of Generalize Pustular Psoriasis in a Patient with Previously Unknown HIV Infection", <i>Turkiye Klinikleri Journal of Dermatology</i> , 2019 Publication	1%
4	Nilesh Morar, Saffron A Willis-Owen, Toby Maurer, Christopher B Bunker. "HIV-associated psoriasis: pathogenesis, clinical features, and management", <i>The Lancet Infectious Diseases</i> , 2010 Publication	1%
5	<a href="http://docobook.com">docobook.com</a> Internet Source	1%
6	<a href="http://jpad.com.pk">jpad.com.pk</a> Internet Source	1%

---

7	Meda Sandra Orasan, Iulia Ioana Roman, Andrei Coneac. "Chapter 2 Evaluation of Psoriasis Patients", IntechOpen, 2019 Publication	1 %
8	dokumen.pub Internet Source	1 %
9	"Dermatology in Public Health Environments", Springer Nature, 2018 Publication	1 %
10	National Psoriasis Foundation. "Psoriasis in patients with HIV infection: From the Medical Board of the National Psoriasis Foundation", Journal of the American Academy of Dermatology, 201002 Publication	1 %
11	www.childandadolescentpsychiatry.ro Internet Source	1 %
12	Nitin Saksena. "HIV reservoirs in vivo and new strategies for possible eradication of HIV from the reservoir sites", HIV/AIDS - Research and Palliative Care, 2010 Publication	<1 %
13	docserv.uni-duesseldorf.de Internet Source	<1 %
14	synapse.koreamed.org Internet Source	<1 %

---



15

[www.scitepress.org](http://www.scitepress.org)

Internet Source

&lt;1 %

16

[www.spandidos-publications.com](http://www.spandidos-publications.com)

Internet Source

&lt;1 %

17

Gatot Soegiarto, Dewajani Purnomosari, Laksmi Wulandari, Bagus Aulia Mahdi et al. "Incidence of SARS-CoV-2 infection in hospital workers before and after vaccination programme in East Java, Indonesia - A retrospective cohort study", *The Lancet Regional Health - Southeast Asia*, 2022

Publication

&lt;1 %

18

Ya. O. Yemchenko, V. I. Shynkevych, K. Ye Ishcheikin, I. P. Kaidashev. "PPAR-Gamma Agonist Pioglitazone Reduced CD68+ but Not CD163+ Macrophage Dermal Infiltration in Obese Psoriatic Patients", *PPAR Research*, 2020

Publication

&lt;1 %

19

Claudia Günther, Nicole Carballido-Perrig, Susanne Kaesler, José M. Carballido, Tilo Biedermann. "CXCL16 and CXCR6 Are Upregulated in Psoriasis and Mediate Cutaneous Recruitment of Human CD8+ T Cells", *Journal of Investigative Dermatology*, 2012

Publication

&lt;1 %

20	<a href="http://etd.repository.ugm.ac.id">etd.repository.ugm.ac.id</a> Internet Source	<1 %
21	<a href="http://scholar.sun.ac.za">scholar.sun.ac.za</a> Internet Source	<1 %
22	<a href="http://www.dovepress.com">www.dovepress.com</a> Internet Source	<1 %
23	Michelle Duff, Olga Demidova, Stephanie Blackburn, Jay Shubrook. "Cutaneous Manifestations of Diabetes Mellitus", <i>Clinical Diabetes</i> , 2015 Publication	<1 %
24	<a href="http://ejournal.unsrat.ac.id">ejournal.unsrat.ac.id</a> Internet Source	<1 %
25	<a href="http://fr.scribd.com">fr.scribd.com</a> Internet Source	<1 %
26	<a href="http://worldwidescience.org">worldwidescience.org</a> Internet Source	<1 %
27	<a href="http://www.mdpi.com">www.mdpi.com</a> Internet Source	<1 %
28	Ann Sophie Lønnberg, Lone Skov. "Co-morbidity in psoriasis: mechanisms and implications for treatment", <i>Expert Review of Clinical Immunology</i> , 2016 Publication	<1 %

29

MATTHEW L. DESCHOOLMEESTER, KATHRYN J. ELSE. "CYTOKINE AND CHEMOKINE RESPONSES UNDERLYING ACUTE AND CHRONIC TRICHURIS MURIS INFECTION", *International Reviews of Immunology*, 2009

Publication

<1 %

30

Kaku So-Armah, Matthew S. Freiberg. "HIV and Cardiovascular Disease: Update on Clinical Events, Special Populations, and Novel Biomarkers", *Current HIV/AIDS Reports*, 2018

Publication

<1 %

31

Mario Clerici, Apurva Sarin, Pierre A Henkart, Gene M Shearer. "Apoptotic cell death and cytokine dysregulation in human immunodeficiency virus infection: pivotal factors in disease progression", *Cell Death & Differentiation*, 1999

Publication

<1 %

32

Paolo Romita, Caterina Foti, Gianluca Calianno, Andrea Chiricozzi. " Successful treatment with secukinumab in an - positive psoriatic patient after failure of apremilast ", *Dermatologic Therapy*, 2022

Publication

<1 %

Exclude bibliography On

# Psoriasis Vulgaris in Human Immunodeficiency Virus Infected Patient: A Case Report

---

## GRADEMARK REPORT

---

FINAL GRADE

**/100**

GENERAL COMMENTS

**Instructor**

---

PAGE 1

---

PAGE 2

---

PAGE 3

---

PAGE 4

---

PAGE 5

---