

# Trichoscopy of tinea capitis infection in children by Microsporum sp.: A case series

*by Evy Ervianti*

---

**Submission date:** 25-Apr-2023 03:48PM (UTC+0800)

**Submission ID:** 2074919606

**File name:** capitis\_infection\_in\_children\_by\_Microsporum\_sp\_A\_Case\_aeris.pdf (611.78K)

**Word count:** 1714

**Character count:** 9776

## Trichoscopy of tinea capitis infection in children by *Microsporum* sp.: A case series

Evy Ervianti, Linda Astari, Yuri Widia, Sylvia Anggraeni

Department of Dermatology and Venereology, Airlangga University, Dr. Soetomo General Hospital, Surabaya, Indonesia.

**Abstract** The main trichoscopic findings were: mouse hair, zigzag hair, broken hair, perifollicular scaling, and diffuse scaling. Subsequent mycological cultures confirmed *Microsporum* sp. growth. The primary therapy was oral griseofulvin and ketoconazole 2% shampoo for a minimum of six weeks.

**Key words**

Trichoscopy, tinea capitis, *Microsporum*.

### Introduction

Tinea capitis (TC) is a common childhood infection worldwide. Its clinical manifestations range from mild scaling with little hair loss to inflamed lesions with extensive alopecia.<sup>1</sup> Mycology culture is the golden standard for TC, but its process requires around four weeks, risking delayed treatment and secondary infections.<sup>2</sup> Dermoscopy of scalp and hair (trichoscopy) is a rapid, non-invasive tool that offers information at a submacroscopic level, which boosts the screening and diagnostic accuracy in the field of some hair disorders, especially TC.<sup>3</sup>

### Case history

All data were collected from the Mycology Division Clinic of Dermatology and Venereology Outpatient Unit in Dr. Soetomo General Hospital, Surabaya, Indonesia. In all

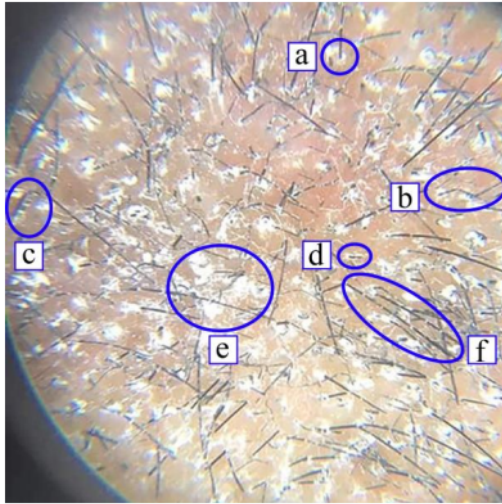
four cases, Wood's light tests yielded yellow-green fluorescence, potassium hydroxide (KOH) microscopic examinations showed ectothrix arthroconidia with the presence of hyphae, and all cultures confirmed the growth of *Microsporum* sp. Trichoscopic findings vary respectively. Every patient was treated with oral griseofulvin 20mg/kg/day twice a day and ketoconazole 2% shampoo every three days for at least six weeks. Each patient's progress was followed up for a minimum of four weeks. Follow-ups showed that complaints, lesions, and trichoscopic findings have greatly improved.

### 4 Case 1

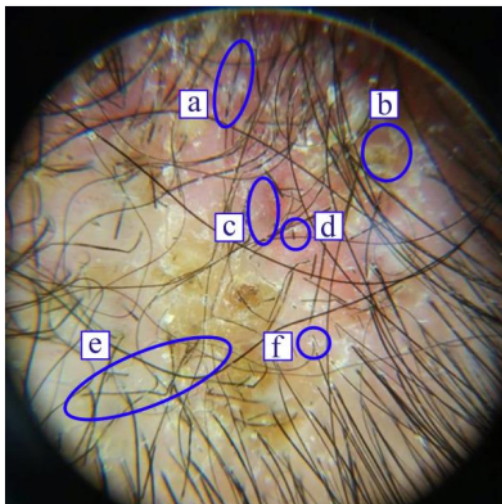
A 12-year-old boy presented with scalp baldness, itch and broken hair for three weeks. Scalp examination showed alopecia with a diameter of 4 cm, erythematous macule, thin scales, broken hair, and grayish hair. Trichoscopy revealed mouse hair, zigzag hair, bent hair, broken hair, perifollicular scaling, and diffuse scaling (**Figure 1**). Lactophenol cotton blue (LPCB) stain on mycology culture showed terminal chlamydoconidia and pectinate (comb-like) hyphae, indicating *Microsporum audouinii* growth. He was diagnosed with tinea capitis gray patch type.

### Address for correspondence

Dr. Evy Ervianti  
Department of Dermatology & Venereology,  
Airlangga University, Dr Soetomo General Hospital,  
Mayjen Prof. Dr. Moestopo No.6-8, Surabaya,  
East Java, Indonesia, 60286  
Ph: (+6231) 5501078  
Email: publikasimikologi01@gmail.com



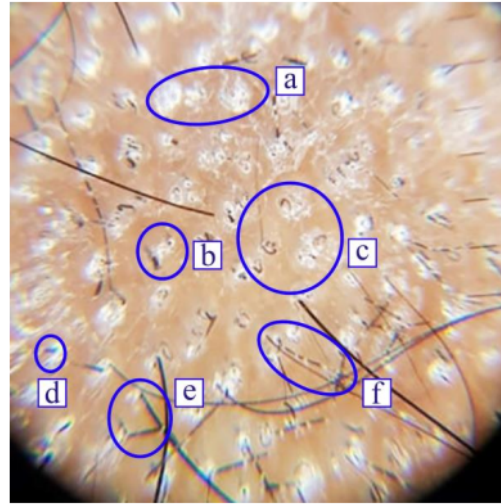
**Figure 1** Trichoscopy of a *Microsporium audouinii* infected scalp of a 12-year-old boy. (a) perfollicular scaling, (b) zigzag hair, (c) bent hair, (d) broken hair, (e) diffuse scaling, (f) morse hair



**Figure 2** Trichoscopy of a *Microsporium canis* infected scalp of a 7-year-old girl. (a) morse hair, (b) yellow crusts, (c) erythema, (d) broken hair, (e) zigzag hair, (f) perfollicular scaling.

4  
**Case 2**

A 7-year-old girl presented with itchy, scalp baldness with yellow crusts for three weeks. Scalp examination showed alopecia with a diameter of 5 cm, an erythematous macule,

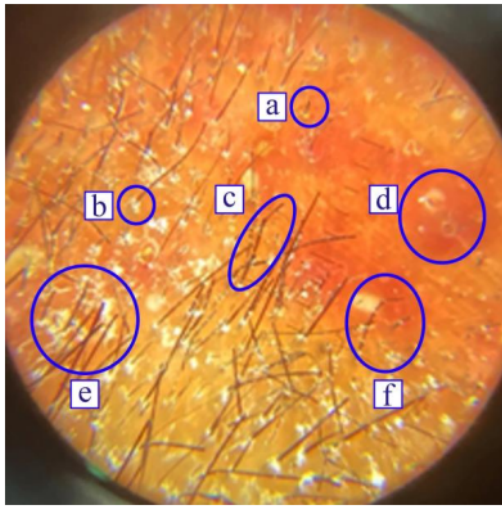


**Figure 3** Trichoscopy of a *Microsporium canis* infected scalp of a 13-year-old boy. (a) diffuse scaling, (b) perfollicular scaling, (c) comma hair, (d) broken hair, (e) zigzag hair, (f) morse hair.

yellow crusts, and grayish hair. Trichoscopy revealed erythema, yellow crusts, morse hair, zigzag hair, broken hair, and perfollicular scaling (**Figure 2**). The LPCB stain showed thick walled and echinulate spindle shaped macroconidia with terminal knobs, indicating *Microsporium canis* growth. She was diagnosed with tinea capitis gray patch type and secondary infection. In addition to griseofulvin, she received oral amoxicillin 50mg/kg/day three times a day.

**Case 3**

A 13-year-old boy presented with scalp baldness, itch, hair loss, and broken hair for one week. Scalp examination showed an alopecia with a diameter of 6 cm, erythematous macule, thin scales, broken hair, and grayish hair. Trichoscopy revealed morse hair, zigzag hair, comma hair, broken hair, perfollicular scaling, and diffuse scaling (**Figure 3**). Mycology culture confirmed *M. canis* growth. He was diagnosed with tinea capitis gray patch type.



**Figure 4** Trichoscopy of a *Microsporum canis* infected scalp of an 8-year-old boy. (a) broken hair, (b) perifollicular scaling, (c) zigzag hair, (d) erythema, (e) diffuse scaling, (f) morse hair.

#### Case 4

3  
An 8-year-old boy presented with multiple bald spots on his scalp accompanied with itch and hair loss for one month. Scalp examination showed multiple erythematous, scaly plaques with partial alopecia and grayish hair.

Trichoscopy showed erythema, morse hair, zigzag hair, broken hair, perifollicular scaling, and diffuse scaling (**Figure 4**). Mycology culture indicated *M. canis* growth. He was diagnosed with tinea capitis gray patch type.

#### 6 Discussion

Tinea capitis is an infection of the scalp skin and hair caused by dermatophyte fungi, namely *Microsporum* and *Tricophyton* species.<sup>8</sup> Its clinical manifestations range from broken hairs with little scaling to a severe inflammatory mass called kerion.<sup>4</sup> Lately, trichoscopy has been utilized to observe visual features that may be distinctive for different TC causative species.<sup>1</sup> However, trichoscopy is not disease specific, because some of the features such as black dots, perifollicular scaling and broken hairs may be observed in other scalp diseases such as alopecia areata, psoriasis, seborrheic dermatitis, and many more.<sup>5</sup>

Based on our trichoscopic images, we suspected *Microsporum* sp. to be the causative agent.

**Table 1** A summary of diagnostic findings in four cases.

	Case one	Case two	Case three	Case four
Wood's lamp				
Yellow green fluorescence	✓	✓	✓	✓
Trichoscopy finding				
Morse hair	✓	✓	✓	✓
Zigzag hair	✓	✓	✓	✓
Bent hair	✓	-	-	-
Broken hair	✓	✓	✓	✓
Comma hair	-	-	✓	-
Black dot	-	-	-	-
Corkscrew hair	-	-	-	-
Perifollicular scaling	✓	✓	✓	✓
Diffuse scaling	✓	-	✓	✓
Erythema	-	✓	-	✓
Yellow crust	-	✓	-	-
KOH				
Ectothrix	✓	✓	✓	✓
Mycology culture				
<i>M. audouinii</i>	✓	-	-	-
<i>M. canis</i>	-	✓	✓	✓

A study of 24 patients stated morse hair and zigzag hair were seen primarily in *Microsporum* sp. induced TC due to its ectothrix infection mechanism,<sup>6</sup> just as how morse hair and zigzag hair were observed in all of our cases. A review study of 37<sup>5</sup> literatures showed morse hair, zigzag hair, bent hairs, and diffuse scaling were more commonly observed in *Microsporum* sp. induced TC, while corkscrew hair was more in *Trichophyton* sp. induced TC. The study also showed that there was no significant difference in occurrence for both species in terms of comma hair, black dot, broken hair, and perifollicular scaling.<sup>5</sup> Similarly, our findings were in line with the aforementioned study, as we also did not find any corkscrew hair. Corkscrew hair is probably caused by *Trichophyton* sp. mediated endothrix hair damage that resulted in hair degradation and external resistance.<sup>7</sup> Meanwhile, in ectothrix infection (particularly *Microsporum* sp.), the fungal hyphae perforate the hair cuticle to produce conidia on the hair surface, resulting in transverse fractures appearing as white bands across the hair shaft forming a Morse code-like appearance. Several transverse fractures may occur further from the follicular ostia along the hair shafts, causing zigzag hair formation. Broken hairs occur when the fractures are complete. Bent hair was reported in very few studies, occurring only in ectothrix TC.<sup>6,8</sup> When subsequent diagnostic examinations were performed on all patients, *Microsporum* sp. infection was confirmed. This meant our trichoscopic observations had a good correlation with other diagnostic findings, suggesting its potential role in identifying the causative fungus, allowing a quick and targeted selection of therapy. After comparing our findings with other literatures, we propose that the presence of morse hair and zigzag hair as well as the absence of corkscrew hair are valuable predictive trichoscopic findings in *Microsporum* sp. mediated TC infections.

Systemic antifungal agents are essential in treating TC because topical agents are not able to penetrate the hair shafts. There are several agents that have shown effectiveness such as griseofulvin, terbinafine, itraconazole, and fluconazole.<sup>4</sup> We prescribed griseofulvin because it is more effective in treating *Microsporum* sp. infections than *Trichophyton* sp. infections. Additional topical agents such as ketoconazole, selenium sulfide, or ciclopirox shampoo are advised to reduce transmission by decreasing the carriage rate of infected species.<sup>6,9</sup> We prescribed ketoconazole 2% shampoo, and when combined with oral griseofulvin yielded excellent results during patient control sessions, as shown clinically and by the significant decrease in specific trichoscopic findings such as all types of dystrophic hair and scaling. This showed that trichoscopy also had a role in monitoring the treatment efficacy of TC.<sup>5</sup>

## Conclusion

11  
Trichoscopy offers an inexpensive, non-invasive technique that allows magnified visualization of the scalp skin and hair. It is fast, readily available, and can be performed anytime at the bedside.<sup>10</sup> Its use in TC cases improves diagnostic accuracy and allows a more prompt, targeted therapy. This method needs wider validation but may provide a rapid provisional diagnosis, sufficient to initiate treatment.

## References

1. Hay RJ. Tinea Capitis: Current Status. *Mycopathologia*.2017;**182(1-2)**:87-93.
2. Aqil N, Baybay H, Moustaid K, Douhi Z, Elloudi S, Mernissi FZ. A prospective study of tinea capitis in children: Making the diagnosis easier with a dermoscope. *J Med Case Rep*.2018;**12(1)**:383.
3. Errichetti E, Stinco G. Dermoscopy in General Dermatology: A Practical Overview. *Dermatol Ther (Heidelb)*.2016;**6(4)**:471–507.

4. Ely JW, Rosenfeld S, Stone MS. Diagnosis and Management of Tinea Infections. *Am Fam Physician*.2014;**90(10)**:702–10.
5. Wałkiel-Burnat A, Rakowska A, Sikora M, Ciechanowicz P, Olszewska M, Rudnicka L. Trichoscopy of Tinea Capitis: A Systematic Review. *Dermatol Ther (Heidelb)*.2020; **10(1)**:43–52.
6. Bourezane Y, Bourezane Y. Analysis of trichoscopic signs observed in 24 patients presenting tinea capitis: Hypotheses based on physiopathology and proposed new classification. *Ann Dermatol Venereol*.2017; **144(8-9)**:490–6.
7. Tirado-Sánchez A, Bonifaz A. Tinea Capitis: Current Review of the Literature. *Curr Fungal Infect Rep*.2018;**12(3)**:120–6.
8. Lin YT, Li YC. The dermoscopic comma, zigzag, and bar code-like hairs: Markers of fungal infection of the hair follicles. *Dermatologica Sin*.2014;**32(3)**:160–3.
9. Gupta AK, Mays RR, Versteeg SG, Piraccini BM, Shear NH, Piguat V, *et al*. Tinea capitis in children: a systematic review of management. *J Eur Acad Dermatology Venereol*.2018;**32(12)**:2264-74.
10. Elghblawi E. Tinea capitis in children and trichoscopic criteria. *Int J Trichology*.2017; **9(2)**:47–9.

# Trichoscopy of tinea capitis infection in children by *Microsporum* sp.: A case aeries

## ORIGINALITY REPORT

**11** %  
SIMILARITY INDEX

**4** %  
INTERNET SOURCES

**10** %  
PUBLICATIONS

**0** %  
STUDENT PAPERS

## PRIMARY SOURCES

- 1** Zeinab Aryanian, Kamran Balighi, Parvaneh Hatami, Zeinab Mohseni Afshar, Nessa Aghazadeh Mohandesi. " The role of - 2 infection and its vaccines in various types of hair loss ", *Dermatologic Therapy*, 2022  
Publication **2** %
- 2** Yu-Ting Lin, Yu-Chuan Li. "The dermoscopic comma, zigzag, and bar code-like hairs: Markers of fungal infection of the hair follicles", *Dermatologica Sinica*, 2014  
Publication **1** %
- 3** "Rook's Textbook of Dermatology", Wiley, 2010  
Publication **1** %
- 4** "Hospital-Based Dermatopathology", Springer Science and Business Media LLC, 2020  
Publication **1** %
- 5** Anna Waśkiel-Burnat, Adriana Rakowska, Mariusz Sikora, Piotr Ciechanowicz, Małgorzata Olszewska, Lidia Rudnicka. **1** %

# "Trichoscopy of Tinea Capitis: A Systematic Review", Dermatology and Therapy, 2020

Publication

---

6	Cara Palusak, Kaitlyn Blacha, Suchita Sampath, Shannon C. Trotter. "Chapter 21 40-Year-Old Female with a Scaly, Gray Patch of Hair Loss on the Left Parietal Scalp", Springer Science and Business Media LLC, 2022 Publication	1 %
7	erepo.unud.ac.id Internet Source	1 %
8	Nkechi Anne Enechukwu, Esther Ngozi Umeadi, Ogochukwu Ifeanyi Ezejiofor, Adebola Olufunmilayo Ogunbiyi. "Chapter 2 A 14-Year-Old Boy with Hair Loss and Scaling on the Scalp", Springer Science and Business Media LLC, 2022 Publication	1 %
9	brain.unboundmedicine.com Internet Source	1 %
10	e-journal.unair.ac.id Internet Source	1 %
11	www.dovepress.com Internet Source	1 %
12	"Dermatophytes and Dermatophytoses", Springer Science and Business Media LLC, 2021	<1 %



13

Ashish Dalal, Suraj Chawla, Prakriti Vohra, Jyoti Sangwan, Janshruti. "Clinico-mycological profile and trichoscopic findings among pediatric tinea capitis patients: A cross-sectional study from northern India (Haryana)", Asian Journal of Medical Sciences, 2022

<1 %

Publication

---

Exclude quotes      On

Exclude matches      Off

Exclude bibliography      On

# Trichoscopy of tinea capitis infection in children by Microsporum sp.: A case aeries

---

GRADEMARK REPORT

---

FINAL GRADE

**/100**

GENERAL COMMENTS

**Instructor**

---

PAGE 1

---

PAGE 2

---

PAGE 3

---

PAGE 4

---

PAGE 5

---