

### A Case Report of Tinea Capitis in Children: Utility of Trichoscopy

Citra Dwi Harningtyas, Evy Ervianti, Linda Astari, Sylvia Anggraeni, Yuri Widia

Departement of Dermatology and Venereology Faculty of Medicine Universitas Airlangga, Dr. Soetomo General Academic Hospital, Surabaya, Indonesia

#### ABSTRACT

**Background:** Tinea capitis (TC) is the most prevalent pediatric superficial dermatophyte infection. Scalp dermoscopy or “trichoscopy” represents a valuable, noninvasive technique for the evaluation of patients with hair loss due to TC. **Purpose:** To characterize trichoscopic findings in children with clinical findings suggestive of TC. **Case:** A 13-year-old boy was presented with a scaled plaque on his scalp that had appeared 1 month earlier. A physical examination revealed a scaly, nonerythematous, rounded lesion in the parietal area of the head. Wood’s lamp yielded a blue fluorescence. Microscopic morphology from fungal culture found the typical spindle-shaped macroconidia of *Microsporum canis*. Trichoscopy showed mainly comma hair, corkscrew hair, morse code hair, bent hair, and zig zag hair. The patient was started on oral griseofulvin 20 mg/kg/day and antifungal shampoo for 8 weeks. The patient was cured after two months of treatment and trichoscopy returned to normal. **Discussion:** Fungal culture remains the gold standard in TC diagnosis, but it needs time. Trichoscopy can be an additional tool to help evaluate the diagnosis, aetiology, and follow up of this disorder. The presence of characteristic trichoscopic features (comma hairs, corkscrew hairs, Morse code-like hairs, zigzag hairs, bent hairs, block hairs, and i-hairs) is predictive of TC. The present analysis confirmed that trichoscopy is a useful method in differentiating between *Microsporum* and *Trichophyton* TC, which is important from the perspective of a different therapeutic approach. **Conclusion:** Trichoscopy is not only of value in the diagnosis of TC but also for the etiologic agent and follow-up after treatment in this case.

**Keywords:** tinea capitis, trichoscopy, tropical disease, infectious disease.

Correspondence: Evy Ervianti, Departement of Dermatology and Venereology Faculty of Medicine Universitas Airlangga/Dr. Soetomo General Academic Hospital. Jl. Mayjend Prof. Dr. Moestopo No. 6-8 Surabaya 0131, Indonesia. Phone number: +62315501609, e-mail: evy-e@fk.unair.ac.id

---

#### BACKGROUND

Tinea capitis (TC) describes a dermatophyte infection of the hair and scalp typically caused by *Trichophyton* and *Microsporum* species, with the exception of *Trichophyton concentricum*.<sup>1</sup> Etiological agents differ according to the geographical distribution. During the last few decades, an increased prevalence of the disease with a remarkable change in the pattern of the causative dermatophytes among different countries has been observed, probably due to immigration, emigration, traveling, and changes in the level of surveillance.<sup>2</sup> The incidence of TC among children is greater in developing countries. This has been attributed to inadequacies in improved social, economic, healthcare, and hygiene practices; this includes poor living conditions, children’s interaction patterns, poor sanitation, housing congestion, limited water supply, and poor health-seeking behavior. There is also a higher susceptibility among children who have pets, wet skin conditions, skin injuries or abrasions, and those who use public showers, who are barefoot, and share hairbrushes or unwashed clothing with other people. The prevalence of TC is equally high among

pre-pubertal children.<sup>2,3</sup>

Dermatophytes are commonly found in tropical and subtropical regions, which is the climate in Indonesia.<sup>3</sup> There were 42 new TC cases out of 1.757 new cases in Mycology Division Outpatient Unit Dr. Soetomo General Academic Hospital Surabaya in 2014-2016. The disease is most commonly observed in children between 3 and 7 years of age. Adults (especially elderly individuals) may be occasionally affected.<sup>3,4</sup> Clinically, TC is characterized by the presence of hair loss areas with coexistent scaling, inflammation, or pustules.<sup>3</sup> The scalp can be dry, which accounts for the majority of the cases (90%) or the acute inflammatory oozing form. TC has diverse causative agents and can exhibit one or multiple foci of alopecia.<sup>5</sup>

Mycological examination is considered the gold standard diagnostic method in TC.<sup>6</sup> Diagnosis can be conducted easily by direct 10%–20% potassium hydroxide examination of plucked hair, or by isolation of the dermatophyte in Sabouraud agar, which would take weeks to reveal and delay diagnosis and proper treatment.<sup>5</sup> However, trichoscopy may be useful in

making a correct diagnosis before culture results are available.<sup>6</sup> It has been reported that trichoscopy, an easy-to-perform, non-invasive method, is characterized by a higher sensitivity compared with direct examination (94% vs 49.1%) in the diagnosis of TC. Moreover, a high specificity of trichoscopy in TC has been described (83%).<sup>7</sup> Trichoscopy is a useful method for the diagnosis of TC. The presence of characteristic trichoscopic features (comma hairs, corkscrew hairs, Morse code-like hairs, zigzag hairs, bent hairs, block hairs, and i-hairs) is predictive of TC. Broken hairs, black dots, perifollicular, and diffuse scaling are commonly observed in TC. However, they may also be detected in other hair and scalp diseases such as alopecia areata, trichotillomania, lichen planopilaris, discoid lupus erythematosus, seborrheic dermatitis, or psoriasis, so they cannot be considered as disease-specific.<sup>8</sup> Trichoscopy may be a helpful method in the differentiation between *Microsporum* and *Trichophyton* TC, and consequently, the selection of the appropriate therapy. Finally, it can be applied to the monitoring of treatment efficacy.<sup>2</sup>

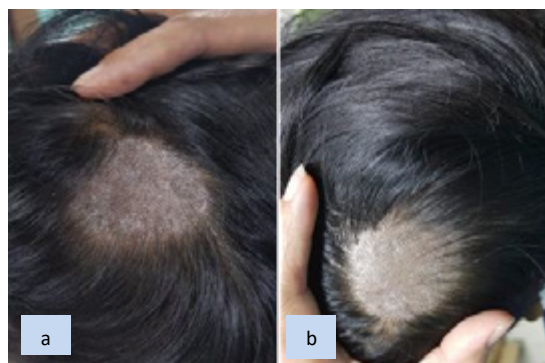
Here, we report a case of Tinea Capitis that was identified as being caused by a *Microsporum canis* infection through mycological examination and correlate it with the features of trichoscopy.

## CASE REPORTS

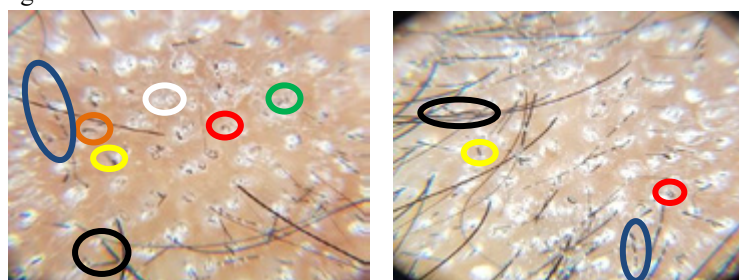
A 13-year-old boy came to the clinic, presenting with an intense itchy, painless scaly patch of hair loss

in the occipitoparietal region of the scalp since 1 month. Complaints of scratchy or scaly plaques on the hands, feet, or other body parts were absent. He often played around the house with stray cats. There were no similar complaints from the family. He never did any gardening or exchanged clothes with other people. On physical examination, there was the existence of wide patchy alopecia in occipitoparietal region of the scalp with massive dry scaling, dull gray hair, and minimal inflammation (Figure 1). There were no palpable lymph nodes in the lateral cervical chains.

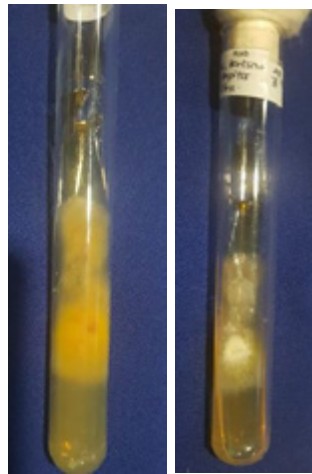
Potassium hydroxide 20% examination of the hair showed numerous ectoarthroconidia. The Wood's lamp examination yielded a characteristic fluorescence of yellowish green. Portable trichoscopy examination at 10x magnification was employed with alcohol and the most characteristic findings observed were multiple broken hairs, perifollicular scaling, and hairs with the characteristics of comma hair, corkscrew hair, morse code hair, bent hair, and zigzag hair (Figure 2). The hair and scale cultures produce very slow-growing, white to light yellow, coarsely hairy, with closely spaced radial grooves within 10 days. There was yellow to orange reverse pigment visible on the reverse side of the colonies (Figure 3). Microscopic morphology showed the typical spindle-shaped macroconidia of *Microsporum canis*. Few microconidia are observed as club-shaped, smooth-walled, and forming along the hyphae. Other structures may include chlamydoconidia, which characterizes the dysgonic type (Figure 4).



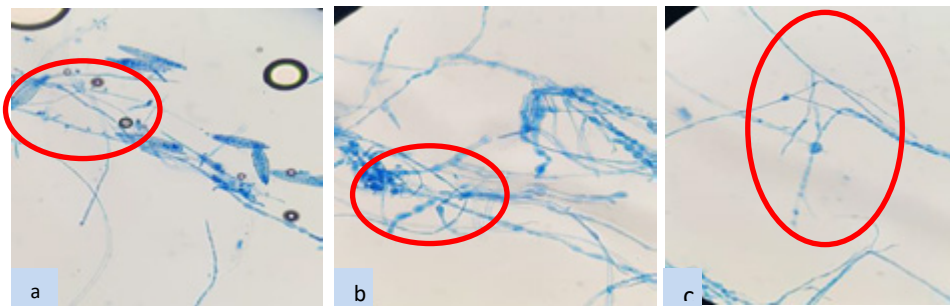
**Figure 1.** Clinical appearance revealed: wide patchy alopecia (a) prior of being cleaned with an alcohol swab; (b) after of being cleaned with an alcohol swab.



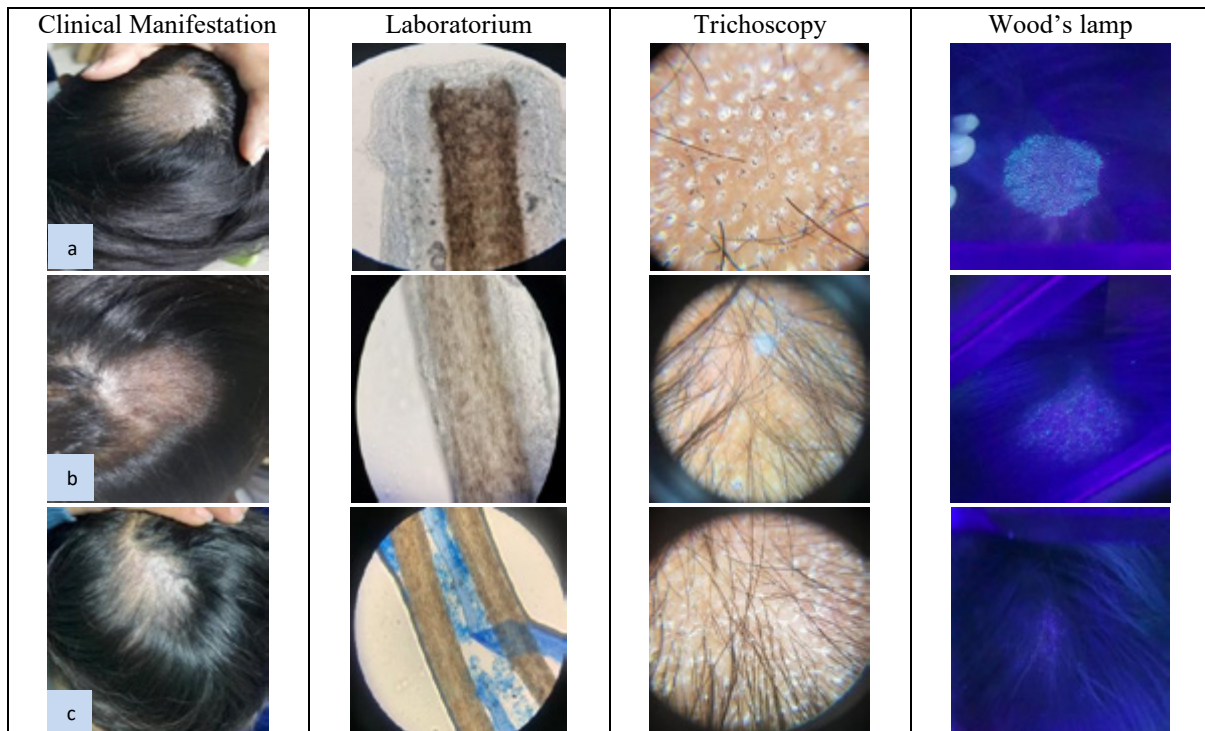
**Figure 2.** Trichoscopy results: comma hair (red circles), corkscrew hair (green circle), Morse code hair (blue circles), bent hair (orange circle), zigzag hair (black circles), perifollicular scaling (white circles), broken hairs (yellow circles).



**Figure 3.** Cultures produced very slowly growing within 10 days, white to light yellow, coarsely hairy, with closely spaced radial grooves. There was yellow to orange reverse pigment visible on the reverse side of the colonies.



**Figure 4.** Microscopic morphology. (a) Septate hyphae containing numerous thick-walled, and echinulate spindle-shaped macroconidia with terminal knobs and more than 6 cells. Few microconidia are observed as club-shaped, smooth-walled and forming along the hyphae. Chlamydoconidia (b,c) characterizes the dysgonic type.



**Figure 5.** Progress of the patient. (a) Before treatment. (b) 1 month after treatment. (c) 2 months after treatment.

When this diagnosis was confirmed, the patients were treated orally with 20 mg/kg body weight of griseofulvin twice a day for 6-12 weeks. Ketoconazole shampoo 2% was administered locally. Trichoscopy and potassium hydroxide preparations of hair, scrapings made every 4 weeks. The result of a potassium hydroxide 20% examination 2 months after therapy remained negative and sterile, respectively. At the 8<sup>th</sup> week follow up visit, trichoscopy showed the disappearance of dystrophic hairs (comma hair, corkscrew hair, morse code hair, bent hair, and zigzag hair), with the presence of perifollicular scaling and diffuse desquamation.

## DISCUSSION

Tinea capitis (TC) is a frequent scalp infection in children and is caused by various dermatophyte species of the genera *Trichophyton* and *Microsporum*, with a prevalence of roughly 1% in developed countries.<sup>9</sup> The condition should be suspected in patients with solitary or numerous plaques of hair loss associated with cut hairs and scales. Mycological examination is considered the gold standard diagnostic method in TC. Diagnosis can be conducted easily by direct 10%–20% potassium hydroxide examination of plucked hair. The expected diagnostic finding is the presence of fungal hyphae and spores within the hair shaft (endothrix) or around the hair shaft (ectothrix).<sup>5,6,10</sup> The etiologic agent could be revealed by isolation of the dermatophyte in Sabouraud agar, which would take weeks to reveal and delay diagnosis and initiation of proper treatment.<sup>5</sup> Wood's lamp is helpful for diagnosis as it is known that *Microsporum* species fluoresces blue-green and *Trichophyton schoenleinii* fluoresces dull blue. A fungal infection due to other organisms does not fluoresce.<sup>9</sup> A case of TC non-

inflammatory type (grey patch) was reported. Potassium hydroxide 20% examination of the hair showed numerous ectothrix arthroconidia. Hyphae and arthroconidia were also found in the preparations containing the scales. The Wood's lamp examination yielded a characteristic fluorescence of yellowish green. The hair and scale cultures produced yellow to orange reverse pigment, visible on the reverse side of the colonies. Microscopic morphology showed the typical spindle-shaped macroconidia of *Microsporum canis*.

Trichoscopy can be useful in the diagnosis of TC. The presence of characteristic trichoscopic features (comma hairs, corkscrew hairs, Morse code-like hairs, zigzag hairs, bent hairs, block hairs, and i-hairs) is predictive of TC. The frequency, sensitivity, specificity, and positive and negative predictive values of the most characteristic trichoscopic findings for TC are presented in Table 1.<sup>2</sup> According to these observations, trichoscopy may be useful to establish the primary diagnosis of TC and start the therapy before culture results are available. Moreover, it may be helpful to perform screening in high-risk populations. Broken hairs, black dots, perifollicular and diffuse scaling, are commonly observed in TC. However, they may also be detected in other hair and scalp diseases such as alopecia areata, trichotillomania, lichen planopilaris, discoid lupus erythematosus, seborrheic dermatitis, or psoriasis, so they cannot be considered as disease-specific.<sup>8</sup> The appearance of trichoscopy in our patient was multiple broken hairs, perifollicular scaling, and hairs with the characteristics of comma hair, corkscrew hair, morse code hair, bent hair, and zigzag hair. The features had good positive predictive value for TC.

**Table 1.** Trichoscopic features of tinea capitis<sup>2</sup>

Trichoscopic feature	Reported prevalence in % (mean value)	Sensitivity (%)	Specificity (%)	Positive predictive value (%)	Negative predictive value (%)
Comma hairs	13-100 (51)	50	99	94	82
Corkscrew hairs	14-100 (32)	32	100	98	77
Morse code-like hairs	12-56 (22)	13	100	100	73
Zigzag hairs	5-49 (21)	17	99	83	73
Bent hairs	4-71 (27)	7	100	100	72
Block hairs	4-50 (10)	2	100	83	70
i-Hairs	4-33 (10)	6	100	97	71

Comma hairs are short, C-shaped hairs, that are homogeneous in pigmentation and thickness. They were first described by Slowinska et al. in 2008.<sup>11</sup> Comma hairs are formed due to subsequent cracking and bending of a hair shaft filled with hyphae.<sup>11</sup> The

frequency of comma hairs varied between 13% and 100% (mean value: 51%) of patients with TC.<sup>2</sup> They were also occasionally detected in patients with alopecia areata and trichotillomania.<sup>14</sup> Corkscrew hairs are multiple twisted and coiled hairs with a corkscrew-

like structure. They were first described by Hughes et al. in 2011 as a specific form of comma hairs in black-skinned patients (with African hair types) or a specific trichoscopic finding of TC caused by *Trichophyton soudanense*.<sup>11,13</sup> They were observed in endothrix TC caused by *Trichophyton tonsurans* and *Trichophyton violaceum*. Moreover, corkscrew hairs were detected in ectothrix-type fungal infection caused by *Trichophyton verrucosum*, *Microsporum canis*, and *Microsporum audouinii*. The incidence of corkscrew hairs varied between 14% and 100% (mean value: 32%) of patients with TC.<sup>2</sup> Corkscrew hairs were described as a specific trichoscopic feature of TC. However, they may also be observed in ectodermal dysplasias.<sup>14,15</sup> Morse code-like hairs, also known as bar code-like hairs, represent hairs with multiple thin white bands across the hair shaft. The term was introduced in 2011 by Rudnicka et al.<sup>11,14</sup> Morse code-like hairs are formed due to the accumulation of spores around the hair shaft that cause a transverse perforation of the hair shaft. They were only described in patients with ectothrix-type fungal infection with an incidence rate of between 12% and 56% (mean value: 22%).<sup>2</sup> Zigzag hairs, first described by Rudnicka et al., are bent hairs with multiple sharp angles. Their formation results from incomplete, transverse fractures along the hair shaft.<sup>14,16</sup> Zigzag hairs were only described in patients with ectothrix-type fungal infection with an incidence rate between 5% and 49% (mean value: 21%). They were also reported in patients with alopecia areata.<sup>17</sup> Bent hairs are characterized by bending of the hair shaft with homogeneous thickness and pigmentation. In contrast to comma hairs, no hair shaft shortening is observed.<sup>18</sup> Very few studies reported bent hairs in TC, with an incidence rate between 4% and 71% (mean value: 27%). They were only observed in patients with ectothrix-type fungal infection.<sup>2</sup> Block hairs are very short hairs with a transverse horizontal distal end. I-Hairs are block hairs with an accented dark distal end. The terms were introduced by Rudnicka et al.<sup>8,11</sup> There were very few studies reporting block hairs and i-hairs in TC, with an incidence rate of 4–50% (mean value: 10%) and 4–33% (mean value: 10%), respectively.<sup>2</sup>

Trichoscopy may also be helpful in differentiating TC from other hair disorders. Alopecia areata is characterized by an exclamation mark, broken, clustered short vellus hairs. Coiled hairs are characteristic of trichotillomania.<sup>15</sup> In congenital triangular alopecia, trichoscopy would reveal vellus hairs surrounded by normal terminal hairs. It is also necessary to bear in mind that on the normal scalp of

children can be found artefacts reminiscent of trichoscopic findings that can be washed away by shampooing.<sup>19</sup>

The present analysis confirmed that trichoscopy is a useful method in differentiating between *Microsporum* and *Trichophyton* TC (Table 2), which is important from the perspective of a different therapeutic approach. Terbinafine is considered to be the first-line therapy for *Trichophyton* TC, while for *Microsporum* TC griseofulvin is recommended by many experts.<sup>20</sup> In the present analysis, Morse code-like hairs, zigzag hairs, bent hairs and diffuse scaling were only present in *Microsporum* TC. Conversely, corkscrew hairs were more commonly observed in *Trichophyton* compared to *Microsporum* TC.<sup>2</sup> Isa et al., in a prospective study, reported corkscrew hairs in three patients with *T. tonsurans* infection, in two patients with *M. canis* infection, and in one patient with *M. audouinii* infection; all patients with corkscrew hairs had Fitzpatrick skin types IV to IV. Based on these results, they conclude that corkscrew hairs are not specific to *T. soudanense*, they can be found in other species of *Trichophyton* and *Microsporum*, and probably are a variation of comma-shaped hairs in black populations.<sup>20</sup> No significant difference was found in the frequency of comma hairs, black dots, broken hairs, perifollicular scaling, block hairs, and i-hairs between *Microsporum* and *Trichophyton* TC.<sup>2</sup> The Bourezane and Bourezane studies of 24 patients with TC distinguished three major groups of trichoscopic signs, determined by the endothrix, ectothrix, or joint ectothrix-endothrix nature of the fungal infection. Group 1, trichoscopic signs showing deformation of the hair shaft associated with loss of intrapilar stiffness seen primarily in endothrix infections: comma hair (CH); corkscrew hair (CSH); broken hair (BH); black dots (BD). The pigmentation of the hair continues to be normal since the spores are inside the hair shaft. The main forms of tinea involve *Trichophyton soudanense* and *T. tonsurans*. Group 2, signs seen primarily in ectothrix infections resulting in lightening of hair colour due to spores surrounding the hair shaft (especially *Microsporum canis* and *M. audouinii*): bar code-like hair (BCH), zigzag hair (ZZH), broken hair (BH), black dots (BD). Group 3, mixed signs seen in joint ectothrix-endothrix infections combining the signs in the first two groups (e.g., tinea caused by *Trichophyton verrucosum*).<sup>16</sup> In this case, from trichoscopy, were found Morse code-like hairs, zigzag hairs, and bent hairs. This feature was only present in *Microsporum* TC.

**Table 2.** Trichoscopic differences between *Microsporum* and *Trichophyton* TC <sup>2</sup>

Trichoscopic feature	<i>Microsporum</i> capitis Number of patients (%)	tinea <i>Trichophyton</i> capitis Number of patients (%)	Statistical significance ( <i>p</i> value)
Comma hairs	21/29 (72)	24/38 (63)	0,42
Corckscrew hairs	3/29 (10)	21/38 (55)	<0.001
Morse code-like hairs	8/29 (28)	0/38 (0)	<0.001
Zigzag hairs	6/29 (21)	0/38 (0)	<0.01
Bent hairs	4/29 (14)	0/38 (0)	<0.05
Block hairs	0/29 (0)	0/38 (0)	-
i-Hairs	0/29 (0)	0/38 (0)	-
Broken hairs	13/29 (45)	17/38 (45)	0.99
Black dots	3/29 (10)	3/38 (8)	0.73
Perifollicular scaling	3/29 (10)	2/38 (5)	0.43
Diffuse scaling	4/29 (14)	0/38 (0)	<0.05

The treatment of tinea capitis requires systemic antifungal therapy because topical antifungal agents cannot penetrate the hair shaft sufficiently to eradicate infection. Griseofulvin, the former gold-standard agent, has been associated with treatment failure; a retrospective review of patients' medical records revealed a failure rate of 39.3%. Consequently, the recommended dose has been increased from 10–15 mg/kg to 20–25 mg/kg, creating an additional challenge and dramatically increasing the cost. The only available liquid form of griseofulvin comes at a concentration of 125 mg/5 mL, requiring a large amount of medicine to achieve the therapeutic dose and resulting in increased cost. For instance, the required dose to treat a 20-kg child, an average 5-year-old in the US, is 16–20 mL daily for 8 weeks.<sup>23</sup> According to a recent systematic review, griseofulvin maintains a high complete cure rate of 72%. Terbinafine was the only agent to have a higher complete cure rate of 92%. However, griseofulvin was superior in treating infections caused by *Microsporum* species. Hence, longer courses of griseofulvin are sometimes required to cure infections caused by *M. canis*. The observed advantage in treating *M. canis* has not been explained by any clinical studies but is speculated to be due to griseofulvin's ability to concentrate in sweat, unlike terbinafine, which is a lipophilic agent.<sup>24</sup> In this case, the patients were treated orally with griseofulvin 330mg (20 mg/kg body weight) twice a day for 6-12 weeks. The result of the potassium hydroxide 20% examination 2 months after therapy remained negative and sterile, respectively.

The role of trichoscopy in monitoring TC therapy has also been described. The trichoscopic marker of treatment efficacy is the disappearance of dystrophic hairs (comma hairs, corkscrew hairs, zigzag hairs, Morse code-like hairs, broken hair, and black dots), 4–12 weeks after therapy initiation.<sup>2</sup> In a study conducted

by Campos et al. on the 12<sup>th</sup> week follow-up visit after starting the treatment, dystrophic hairs were not present; however, perifollicular scaling and diffuse scaling were detected.<sup>21</sup> Perifollicular and diffuse scaling tend to resolve more slowly compared to hair shaft abnormalities, it cannot be considered to be a marker of therapy failure.<sup>2</sup> Moreover, previous data suggested that trichoscopy may be more reliable than repeated potassium hydroxide examinations in the monitoring of treatment efficacy in TC.<sup>22</sup> The trichoscopic features of this patient also showed the disappearance of dystrophic hairs (comma hair, corkscrew hair, morse code hair, bent hair, and zigzag hair), with the presence of perifollicular scaling and diffuse desquamation on the 8th week follow-up visit.

While fungal culture remains the gold standard in TC diagnosis, we still consider trichoscopy as a valuable additional tool that is fast, efficient, and could lead to establishing the diagnosis. Further investigations are needed to validate the role of trichoscopy as a diagnostic tool per se for TC because the level of evidence is still low from available studies and has made it inconclusive. It can be an additional tool to help the dermatologist in the diagnosis of this disorder, but always with the combination of clinical performance and mycological examination to enable a definitive diagnosis.

## REFERENCES

1. Craddock LN, Schieke SM. Superficial fungal infection. In: Kang S, Amagai M, Bruckner AL, Enk AH, Margolis DJ, McMichael AJ, et al., editors. Fitzpatrick's Dermatology Ninth Edition. New York: McGraw-Hill Education; 2019. p. 2925–52.
2. Burnat AW, Ciechanowicz P, Rakowska A, Sikora M, Rudnicka L. Trichoscopy of tinea capitis: a systematic review. *Dermatol Ther*

- (Heidelb) 2020; 10(1): 1-10.
3. Adesiji YO, Omolade FB, Aderibigbe IA, Ogungbe O, Adefioye OA, Adedokun SA, et al. Prevalence of tinea capitis among children in Osogbo, Nigeria, and the associated risk factors. *Diseases* 2019; 7(13): 1-13.
  4. Michaels BD, Del Rosso JQ. Tinea capitis in infants: recognition, evaluation, and management suggestions. *J Clin Aesthet Dermatol* 2012; 5(1): 49–59.
  5. Hay RJ. Tinea capitis: current status. *Mycopathologia* 2017;182(1–2): 87–93.
  6. Aqil N, BayBay H, Moustaid K, Douhi K, Elloudi S, Mernissi FZ. A prospective study of tinea capitis in children: making the diagnosis easier with a dermoscope. *J Med Case Rep* 2018;1(2): 383.
  7. Dhaille F, Dillies AS, Dessirier F, Reygagne P, Diouf M, Baltazard T, et al. A single typical trichoscopic feature is predictive of tinea capitis — a prospective multicenter study. *Br J Dermatol* 2019; 2(1): 1-6.
  8. Rudnicka L, Olszewska M, Rakowska A. Atlas of trichoscopy: dermoscopy in hair and scalp disease. London: Springer; 2012: p.361-71.
  9. Elghblawi E. Tricoscopy findings in tinea capitis. A rapid method of diagnosis. *Eur J Pediat Dermatol* 2016; 2(6): 71-4.
  10. Leecharoen W, Leeyaphan C, Bunyaratavej S. Tinea capitis incognito in adult: a case report. *Thai J Dermatol* 2018; 34(3): 225-30.
  11. Rudnicka L, Rakowska A, Kerzeja M, Olszewska M. Hair shafts in trichoscopy: clues for diagnosis of hair and scalp diseases. *Dermatol Clin* 2013;3(1): 695–708.
  12. Park J, Kim J, Kim H, Yun S, Kim S. Trichoscopic findings of hair loss in Koreans. *Ann Dermatol* 2015; 27(5): 539–50.
  13. Hughes R, Chiaverini C, Bahadoran P, Lacour JP. Corkscrew hair: a new dermoscopic sign for diagnosis of tinea capitis in black children. *Arch Dermatol* 2011; 14(7): 355–6.
  14. Rudnicka L, Olszewska M, Rakowska A, Slowinska M. Trichoscopy update 2011. *J Dermatol Case Rep* 2011; 5(1): 82–8.
  15. Rudnicka L, Olszewska M, Waskiel A, Rakowska A. Trichoscopy in hair shaft disorders. *Dermatol Clin* 2018; 3(6): 421–30.
  16. Bourezane Y, Bourezane Y. Analysis of trichoscopic signs observed in 24 patients presenting tinea capitis: hypotheses based on physiopathology and proposed new classification. *Ann Dermatol Venereol* 2017; 144(8–9): 490–6.
  17. Khunkhet S, Vachiramon V, Suchonwanit P. Trichoscopic clues for diagnosis of alopecia areata and trichotillomania in Asians. *Int J Dermatol* 2017; 5(6): 161–5.
  18. Shim W, Jwa S, Song M, Kim H, Ko H, Kim B, et al. Dermoscopic approach to a small round to oval hairless patch on the scalp. *Ann Dermatol* 2014; 26(2): 214–20.
  19. Lacarrubba F, Tosti A. Scalp dermoscopy or trichoscopy. *Curr Probl Dermatol* 2015; 4(7): 21–32.
  20. Isa RI, Amaya BY, Pimentel MI, Arenas R, Tosti A, Cruz AC. Dermoscopy in tinea capitis: a prospective study on 43 patients. *Med Cutan Ibero Lat Am* 2014; 42: 18–22.
  21. Campos S, Brasileiro A, Galhardas C, Apetato M, Cabete J, Serrão V, et al. Follow-up of tinea capitis with trichoscopy: a prospective clinical study. *J Eur Acad Dermatol Venereol* 2017; 31(11): 478–80.
  22. Richarz NA, Barboza L, Monson M, Gonzalez MA, Vicente A. trichoscopy helps to predict the time point of clinical cure of tinea capitis. *Australas J Dermatol* 2018; 1(1): 1–2.
  23. Alkeswani A, Cantrell W, Elewski B. Treatment of tinea capitis. *Skin Appendage Disord* 2019; 1(1): 1–10.
  24. Gupta AK, Mays RR, Versteeg SG, Piraccini BM, Shear NH, Piguet V, et al. Tinea capitis in children: a systematic review of management. *J Eur Acad Dermatol Venereol* 2018; 32(12): 2264–74.