

Immune Thrombocytopenic Purpura Secondary to Peritoneal Tuberculosis Patient with Anti-Tuberculosis Drug- Induced Liver Injury. A Case Report

by Muhammad Vitanata Arfijanto

Submission date: 08-May-2023 10:12AM (UTC+0800)

Submission ID: 2086993444

File name: h_Anti-Tuberculosis_Drug-Induced_Liver_Injury._A_Case_Report.pdf (393.46K)

Word count: 4394

Character count: 24632

Immune Thrombocytopenic Purpura Secondary to Peritoneal Tuberculosis Patient with Anti-Tuberculosis Drug-Induced Liver Injury. A Case Report

Púrpura trombocitopénica inmune secundaria a tuberculosis peritoneal en paciente con daño hepático inducido por drogas antituberculosas.

Reporte de un caso

Fitria Yulistiawati¹, Muhammad Vitanata Arfijanto^{2*}

SUMMARY

Introduction: Various haematological abnormalities commonly occur in active tuberculosis (TB) but immune thrombocytopenic purpura (ITP) secondary to extrapulmonary TB is exceedingly rare.

Case presentation: We reported an 18-year-old male patient who presented with fever, abdominal pain, and thrombocytopenia. From the physical examination, there was found slight abdominal distention and diffuse tenderness. Peripheral blood smear and Immature Platelet Fraction (IPF) investigations were suggestive of ITP. His abdominal Ultrasound (US) and contrast computerized tomographic (CT) suggested peritoneal

tuberculosis. He was treated with methylprednisolone orally for his ITP which showed a good response and was treated with isoniazid, pyrazinamide, and ethambutol for his peritoneal tuberculosis. He experienced Drug Induced Liver Injury (DILI) after Anti-Tuberculosis Therapy (ATT) was given. The initial ATT regimen was stopped and initiated again with a different ATT regimen (streptomycin, isoniazid, ethambutol) when there was a lowering of ALT and AST in 2 weeks. His steroid treatment was tapered off and his new regimen of ATT was continued for 10 months. In his follow-up visits, the patient reported improvement in abdominal symptoms and contrast abdominal CT evaluation.

Conclusion: ITP is a rare but potentially treatable presenting manifestation of extrapulmonary tuberculosis infection. A combination of ATT and steroids showed good results in this patient. The occurrence of DILI in this patient brought a new challenge in his peritoneal tuberculosis treatment but was resolved by switching initial ATT to a new ATT regimen.

Keywords: Secondary immune thrombocytopenic purpura, peritoneal tuberculosis, drug induced liver injury

²⁶
DOI: <https://doi.org/10.47307/GMC.2023.131.s2.19>

ORCID: 0000-0003-2275-4068¹
ORCID: 0000-0003-4510-755X²

¹³
¹MD, Department of Internal Medicine, Airlangga University, Surabaya, 60131, East Java, Indonesia. E-mail: littlefitri@yahoo.com Phone: +62 838-1319-9674

Corresponding author: Muhammad Vitanata Arfijanto, MD, Department of Internal Medicine, Tropical and Infectious Disease Division, Airlangga University, Surabaya, 60131, East Java, Indonesia.

E-mail: muhammad-v-a@fk.unair.ac.id Phone: +62 812-3029-9371.

Recibido: 23 de febrero 2023
Aceptado: 6 de marzo 2023

RESUMEN

Introducción: Varias anomalías hematológicas ocurren comúnmente en la tuberculosis (TB) activa,

pero la púrpura trombocitopénica inmune (PTI) secundaria a la TB extrapulmonar es extremadamente rara.

Presentación del caso: Reportamos un paciente masculino de 18 años que presentó fiebre, dolor abdominal y trombocitopenia. Al examen físico se encontró ligera distensión abdominal y dolor difuso a la palpación. Las investigaciones de frotis de sangre periférica y fracción de plaquetas inmaduras (IPF) sugirieron PTI. Su ultrasonido abdominal (US) y tomografía computarizada (TC) de contraste sugirieron tuberculosis peritoneal. Recibió tratamiento con metilprednisolona por vía oral para su PTI que mostró una buena respuesta y fue tratado con isoniazida, pirazinamida y etambutol para su tuberculosis peritoneal. Experimentó lesión hepática inducida por fármacos (DILI) después de que se le administró la terapia antituberculosa (ATT). El régimen inicial de ATT se suspendió y se inició de nuevo con un régimen de ATT diferente (estreptomina, isoniazida, etambutol) cuando hubo una disminución de ALT y AST en 2 semanas). Su tratamiento con esteroides se redujo gradualmente y su nuevo régimen de ATT continuó durante 10 meses. En sus visitas de seguimiento, el paciente refirió mejoría de los síntomas abdominales y evaluación por TC abdominal con contraste.

Conclusión: La PTI es una manifestación de presentación rara pero potencialmente tratable de la infección tuberculosa extrapulmonar. Una combinación de ATT y esteroides mostró buenos resultados en este paciente. La aparición de DILI en este paciente supuso un nuevo reto en su tratamiento de la tuberculosis peritoneal, pero se resolvió cambiando el ATT inicial por un nuevo régimen de ATT.

Palabras clave: Púrpura trombocitopénica inmune secundaria, tuberculosis peritoneal, lesión hepática inducida por fármacos.

INTRODUCTION

Tuberculosis is a multi-system disease, 90 % of which is located primarily in the lung. Extrapulmonary tuberculosis accounts for 5 of all cases of tuberculosis. The low incidence of extrapulmonary tuberculosis in national registers may be caused by poor identification and atypical symptoms. Abdominal tuberculosis is one of the common presentations of extrapulmonary tuberculosis and affects the gastrointestinal tract, peritoneum, mesentery, abdominal lymph nodes, liver, pancreas, and spleen (1).

Extrapulmonary tuberculosis can present with a wide variety of haematological

manifestations such as anaemia, leukopenia, pancytopenia, thrombocytopenia, myelofibrosis, and hemophagocytic syndrome. Severe isolated thrombocytopenia in extrapulmonary tuberculosis is relatively uncommon (2). In one study, it was found around 1 % of TB patients had symptomatic ITP related to TB. And all those cases constituted around 7 % of all cases of ITP diagnosed over the same period. In endemic regions, TB should be considered an underlying cause of ITP (3).

Pulmonary TB represented the most common clinical presentation having occurred in 33 % of cases, followed equally at 19 % by disseminated TB and lymphadenitis. Tuberculosis-induced immune thrombocytopenic purpura (ITP) is rare, with few cases reported in the literature and only one case reported in the context of intestinal tuberculosis (4,5). Eighty-one and 35 % of patients presented with a platelet count under $20 \times 10^9/L$ and $5 \times 10^9/L$, respectively. Lastly, one of the characteristics that are shared with most reports of TB-related ITP was an initial failure to identify TB as a putative cause of thrombocytopenia (4).

CASE PRESENTATION

An 18-year-old male was admitted with a high fever that was started 6 days prior he came to the hospital. The patient reported weight loss, loss of appetite, and night sweats for the last 6 months. He also presented with generalized abdominal pain, nausea, and vomiting. The abdominal pain was reported as non-localized and vague. Diarrhea and constipation were not reported. The patient did not report any respiratory symptoms or bleeding. There was no history of any haematological, hepatic, or other chronic illness. There was no history of contact with a known case of tuberculosis or any routine medication intake in the recent past.

The physical examination revealed a blood pressure of 103/73 mmHg, a pulse of 102/min and regular, a temperature of 37.6° Celsius, and his oxygen saturation was 98 % while the patient was breathing ambient air. The patient appeared undernourishment. His body mass index (BMI) was 15.6 kg/m² (underweight). On physical examination, the abdomen was slightly distended with diffuse tenderness. Bowel sound

IMMUNE THROMBOCYTOPENIC PURPURA

was normal. There was no lymphadenopathy or hepatosplenomegaly. The remainder of the physical examination was unremarkable.

The initial complete blood count revealed a white blood cell count of $4\,270/\mu\text{L}$ with 82.7 % granulocytes, 8.8 % lymphocytes, 8.3 % monocytes, 0.0 % eosinophils, and 0.2 % basophils, haemoglobin 10.9 g/L with an MCV of 75.0 and an MCH of 24.1, and platelet count $11\,000/\mu\text{L}$. A peripheral smear demonstrated

microcytic normochromic red blood cells, markedly decreased platelets with giant platelets, and no atypical cells. Immature Platelet Fraction (IPF) was 13.8 % (normal 1-8.99 %). The erythrocyte sedimentation rate was 15 mm/h (normal: 0 - 10 mm/h). Serum albumin was 2.7 g/dL (normal: 3.4 - 5.0 g/dL). The following laboratory studies were normal or negative: PT/PTT, ANA test, C3 and C4, anti-HIV, HbsAg, IgM, and IgG Dengue. Serum electrolytes and liver and kidney function tests were normal.

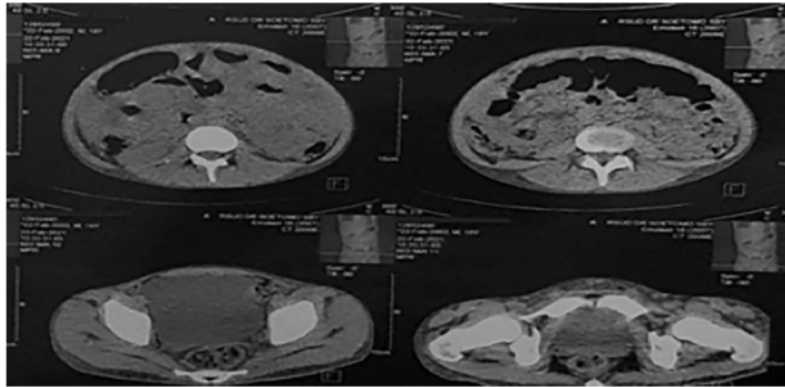


Figure 1. Axial contrast-enhanced CT: Mild ascites; thickening of the peritoneum, omentum, and small bowel's wall; adhesion of small bowel, mesenteric, and omentum.

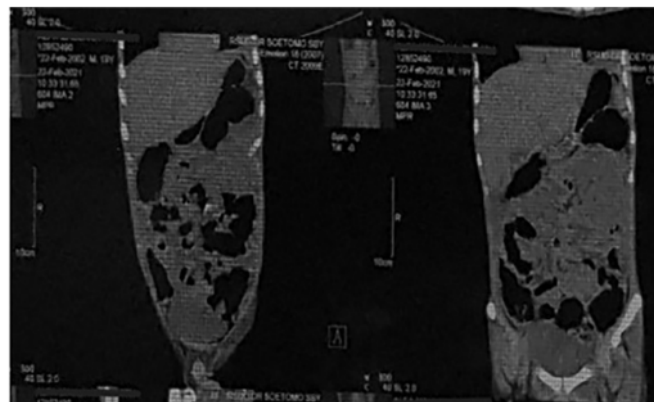


Figure 2. CT of the abdomen (coronal view) demonstrating densely-loculated ascites.

A chest X-ray demonstrated bilateral pleural effusions without fibro infiltrates (Figure 1). A CT scan of the abdomen showed ascitic fluid

has high attenuation values of 27 HU (normal: 20-45 HU) (Figure 2). The peritoneum was thickened. There was adhesion of the small

bowel, mesenteric, and omentum. The small bowel's wall was thickened, and the small bowel seemed dilated. There were proofs of mesenteric and omental involvement with characteristic multiple, fine, mobile septations. CT scan of the abdomen also demonstrated enlarged aortocaval lymph nodes. Abdomen ultrasound reveals free, loculated ascites, and thickening of the peritoneum and omentum. We diagnosed the patient with TB peritoneum.

³² Peritoneal biopsy and subsequent pathological or microbiologic confirmation were ideally performed to diagnose peritoneal tuberculosis as it is the gold standard for definitive peritoneal tuberculosis. We diagnosed the patient with peritoneal tuberculosis only based on imaging examinations. Colonoscopy was planned, but eventually, we did not perform a biopsy to obtain tissue for histological examination. The decision was made because the patient's condition greatly improved since we introduced steroids and ATT into the patient's treatment. This fact proved our diagnosis of peritoneal tuberculosis.

During hospitalization, thrombocytopenia worsened despite repeated platelet transfusions. There was no increase in platelets (8 000/ μ L) despite the transfusion of 10 units of platelets for two days. Administration of methylprednisolone 16 mg every 8 h orally was started. After the indication of tuberculosis infection, Anti-Tuberculosis Therapy (ATT) was started. He was given Isoniazid 300 mg once daily, Pyrazinamide 1 000 mg per 24 jam, and Ethambutol 500 mg once daily. Five days after methylprednisolone was given, the platelet count had increased to 33 000/ μ L. Methylprednisolone 16 mg every 8 h orally was continued.

¹⁷ The patient was diagnosed with ITP after the exclusion of other causes of thrombocytopenia. Abdomen ultrasound findings that indicated tuberculosis infection, thrombocytopenia worsening after platelet transfusion, and increase of platelet count (PC) after administration of steroids and ATT supported the diagnosis of ITP secondary to TB infection.

On 3rd day of anti-tuberculosis therapy, there was an increase in serum alanine aminotransferase (ALT) or aspartate aminotransferase (AST) levels greater than 2.5 times the normal upper limit (ULN). ALT increased from 20 mg/dL to 283

mg/dL and AST increased from 48 mg/dL to 239 mg/dL. Anti-tuberculosis therapy was stopped. On the 8th day after the steroid was given, the platelet continues to increase to 52.000/ μ L. He has discharged with methylprednisolone 16 mg every 8 hours orally. On 1st follow-up visit, the platelet count continued to increase to 106.000/ μ L. And on 2nd follow-up visit, ALT had decreased to 59 mg/dL and AST had decreased to 94 mg/dL. Because the ALT level had decreased to lower than 2 times the normal upper limit, ATT was started again with a new regimen that was less hepatotoxic. The new regimen consisted of Streptomycin 1 000 mg once a day was given intramuscularly, Isoniazid 300 mg once a day orally, and Ethambutol 750 mg once a day orally. He planned to take this ATT regimen for 2 months. Because the level of AST and ALT increases as he received ATT for 3 days and then decreased as ATT was stopped, we concluded that the patient had experienced ATT-induced liver injury. His steroid therapy started to taper off.

On a follow-up visit 3 months later, he went through an abdominal CT scan with contrast re-evaluation. It showed multiple mesenteric nodules and gave an impression of improvement in his TB peritoneum compared to the previous CT scan. His laboratory evaluation also showed platelet count within normal limit and liver function test that return to normal. He reported no gastrointestinal or systemic symptoms. He also reported gaining more weight in the last 3 months. He didn't consume any more steroids to maintain a normal platelet count. Because these facts and other causes of thrombocytopenia had been excluded, we diagnosed the patient with immune thrombocytopenic purpura secondary to tuberculosis. He continues to take ATT with a regiment of Isoniazid 300 mg once a day orally and Ethambutol 750 mg once a day orally for 10 months.

DISCUSSION

ITP can be defined as a platelet count less than 100.000/ μ L with other causes of thrombocytopenia excluded (5,6). ITP is an autoimmune disease characterized by thrombocytopenia as the only haematological manifestation. The two main diagnostic criteria for ITP are thrombocytopenia

in the context of a normal blood count, a normal smear, and the exclusion of primary conditions capable of causing thrombocytopenia (7). ITP is further differentiated into primary ITP or secondary ITP (6). Common secondary causes of ITP include autoimmune diseases like SLE, infections (HIV/hepatitis C), drugs (rifampicin), and lymphoproliferative disorders but tuberculosis per se is a very rare condition (8).

In the study conducted by Salib et al. (9), there was improved agreement about the diagnosis when 2 criteria were met: (1) the patient had a very low platelet nadir ($<20\,000/\mu\text{L}$), and (2) the platelet count increased following treatment with intravenous immunoglobulin (IVIG), corticosteroids, or treatment of the underlying cause of secondary ITP. In our patient, the diagnosis of secondary ITP is based on very low platelet ($11.000/\mu\text{L}$) and also an increase in platelet counts following corticosteroid treatment. Besides those facts, history taking, physical examination, and laboratory investigation also supported the diagnosis of secondary ITP (2).

Reticulated platelets (RPs) and the immature platelet fraction (IPF) have been suggested as the platelet equivalent of red cell reticulocytes. In disorders in which thrombocytopenia is caused by platelet underproduction, the RP percentage and IPF are often low, whereas, in disorders of increased platelet turnover, the RP percentage and IPF are often elevated (6). In our patient, IPF was found to increase as a sign of platelet turnover.

The ITP in extrapulmonary tuberculosis can be either due to the production of platelet antigen-specific antibodies or platelet surface membrane immunoglobulin G, which is generated by proliferating lymphocytes as a part of the immune response to infection (2). Toxic thrombocytopenia might be related to the direct effect of the infecting organism, the acid-fast bacilli, or of immune complexes on the platelets during the most toxic period of infection (10). Previously suggested mechanisms included the production of antiplatelet antibodies and molecular mimicry during the regular immune response to TB (3).

Peritoneal TB can be a challenge to diagnose if it is not suspected. The clinical features include abdominal distension, abdominal pain, features of intestinal obstruction, and systemic

symptoms like fever, weight loss, anorexia, and occasionally abdominal lump (11). Abdominal pain is a common presenting symptom and is frequently accompanied by abdominal distension. It is usually non-localized and vague (12). From the patient's physical examination, there were abdominal symptoms like abdominal pain and abdominal distention and systemic symptoms like fever and weight loss. Those supported peritoneal TB diagnosis.

Ascites is said to be the most common finding with 73 % of TB peritoneum patients having ascites. While ascites formation is a common phenomenon in patients with tubercular peritoneal involvement, the condition can also occur without ascites and may be characterized by thickening and nodularity of the omentum, mesentery, peritoneum, and clumping of bowel loops (11).

Ultrasonography (US) is a useful modality, and it can detect minimal ascites, collections, and thickening of the omentum and peritoneum (11). US is superior to CT in revealing the multiple, fine, mobile septations characteristically found in TBP (12). Computed tomography (CT) is often preferred for evaluation of the peritoneum and other intra-abdominal viscera including the gastrointestinal tract. The peritoneum is commonly thickened and nodular. Thickened mesentery with mesenteric lymph nodes is seen in most cases. Ha et al. reported 69 % sensitivity in the diagnosis of peritoneal TB by CT scan (11). CT scan highlights the peritoneal, mesenteric, or omental involvement. The ascitic fluid in peritoneal TB has high attenuation values on computerized tomographic (CT) imaging (20-45 HU) (12). High attenuation ascites were also found in our patient from ultrasonography and CT abdomen. The rest patient's abdominal ultrasonography and CT findings supported the diagnosis of peritoneal TB.

No established standard therapy for ITP due to tuberculosis has been recognized. Anti-tuberculosis treatment and corticosteroids are effective in many cases. The prognosis of ITP due to tuberculosis is generally good. Weber et al. concluded that early diagnosis and initiation of treatment for tuberculosis should be given the highest priority to reduce the use of immunosuppressants, transfusion,

and the risk of haemorrhage. In adults, the treatments of secondary ITP differ depending on the underlying disease (3). Secondary ITP with infectious diseases does not tend to remit spontaneously (13). The treatment in secondary ITP must be focused to obtain complete remission of the underlying cause and not treating the decreased platelet number (14).

The absence of recurrent thrombocytopenia after the withdrawal of corticosteroids in the patient strongly supports the etiologic role of TB in producing ITP and reinforces the need for anti-tuberculous therapy in all patients with TB-related ITP (4). The patient received methyl prednisolone 16 mg every 8 hours orally after thrombocytopenia failed to remit spontaneously and had the tendency of worsening with platelet transfusion.

In cases of tuberculosis associated with ITP, the most important therapy is antituberculosis treatment. This treatment regimen can be combined with corticosteroids according to the degree of thrombocytopenia or the presence of bleeding (5). Adjunctive steroids may offer benefits by minimizing inflammation and preventing post-inflammatory fibrosis. Early trials showed that when corticosteroids were given in combination with antituberculosis medications there was no progression of TB (12,15). In patients, the combination of steroids and ATT did not worsen their peritoneal TB, instead, there was a reduction of abdominal symptoms and resolution of the disease.

The time from initiation of anti-tuberculosis treatment to PC recovery ranged from 2 days to 3 months (3). In cases that are responsive to treatment, there is usually an increase in the platelet count after one week of therapy, and a peak platelet count occurs in two to four weeks (5). An increase in platelet count was observed on 3rd day of steroid treatment in our patient. Steroids started to be tapered off when the patient's platelet count was above 100.000/ μ L which was achieved in 3 weeks.

The available data strongly suggest that regimens, which are curative for pulmonary TB, are also sufficient for peritoneal TB. There are currently five drugs that are considered first-line medications: isoniazid (INH), rifampicin (RIF), pyrazinamide (PZA), ethambutol (EMB) and

streptomycin (SM). In most circumstances, the treatment regimen for adult patients with previously untreated TB should consist of a 2-month initial phase of INH, RIF, PZA, and EMB given daily. This is followed by a continuation phase where INH and RIF are again given daily for another 4 months (13). The patient was treated with isoniazid (INH), pyrazinamide (PZA), and ethambutol (EMB) as 1st ATT regimen for his peritoneal TB.

DILI may occur with all currently recommended regimens for the treatment of TB infection, including isoniazid and rifampin (16). The presence of hepatotoxicity is confirmed if the increase in serum alanine aminotransferase (ALT) or aspartate aminotransferase (AST) or bilirubin is more than 2.5 times the upper limit of normal (ULN) with or without symptoms of hepatitis (17,18). There was an increase of AST and ALT more than 2.5 times the upper limit of normal (ULN) after the patient received ATT in 3 days. ATT was stopped. The AST and ALT patient decreased after ATT was stopped which confirmed the diagnosis of ATT-induced liver injury. ATT with a new regimen which consisted of Streptomycin, Isoniazid, and Ethambutol, was given after AST and ALT levels decreased below 2 times of ULN.

Thrombocytopenia may arise during therapy as an adverse effect of antitubercular drugs, especially rifampicin, and, rarely, ethambutol and pyrazinamide (19,20). Considering the side effect of thrombocytopenia of rifampicin, our patient also did not receive rifampicin as his ATT regimen which prolong his ATT therapy from 6 months to 12 months.

Tuberculosis can be associated with severe immune-mediated thrombocytopenia. Besides primary ITP, tuberculosis needs to be included in the differential diagnosis of a patient presenting with severe thrombocytopenia, especially in Indonesia as it is a highly endemic country. Thrombocytopenia as one of the side effects of ATT must be considered when we treat a patient with tuberculosis infection with thrombocytopenia as one of its manifestations. Recommended ATT regimen may be needed to be adjusted. In our patient, DILI which happened during ATT administration brought more challenges in our patient's tuberculosis management.

Our case highlights the importance of suspicion of tuberculosis infection as one of the causes of thrombocytopenia. Active pulmonary tuberculosis is usually the cause of ITP secondary, but in our patient peritoneal tuberculosis is one that caused thrombocytopenia. The limitation in our case report is that we can only diagnose the patient with probable peritoneal tuberculosis because we failed to obtain evidence of *M. tuberculosis* bacilli via GeneXpert faces, or chronic inflammation with granulomas and acid-fast bacilli from the histopathological analysis. We could not perform the adenosine deaminase (ADA) test because of the difficulty of obtaining ascites fluid due to it being minimal and loculated. We also did not perform a bone marrow biopsy or aspiration to exclude primary ITP, but only did an immature platelet fraction (IPF) test to examine platelet production in the bone marrow. But in a country with limited resources like Indonesia, the lack of availability of examinations needed for exact diagnosis should not hinder the management of the disease which can be lifesaving.

CONCLUSION

Thrombocytopenia in our patient was caused by TB-associated secondary ITP. The platelet count improved a few days after starting anti-tuberculosis and steroids. The diagnosis of tuberculosis in our case was based on clinical symptoms and radiological evidence. Response to therapy in the form of increased platelet count with steroid use and resolution of abdominal symptoms and improvement in CT scan abdomen with contrast re-evaluation with anti-tuberculosis drugs confirmed the diagnosis of ITP and peritoneal tuberculosis. During the disease, the patient experienced side effects of DILI due to ATT which brought a new challenge in his ITP and peritoneal TB treatment. Adjustment ATT regimen was needed and resulted in the resolution of the patient's ATT-induced liver injury, recovery of platelet count, and improvement in peritoneal TB.

Informed consent statement

Informed written consent was obtained from the patient for the publication of this report and any accompanying images.

Conflicts of interest

The authors report no conflict of interest and no financial and non-financial interest in the subject matter or materials discussed in this manuscript. The authors alone are responsible for the content and writing of this article.

REFERENCES

1. Dal MS, Dal T, Tekin R, Bodakçi E, Düzköprü Y, Ayyıldız MO. Idiopathic thrombocytopenic purpura associated with splenic tuberculosis: Case report. *Le Infezioni in Medicina*. 2013;21(1):50-55.
2. Nasa P, Juneja D, Sehra S, Singh HK, Prasad DB. Immune Thrombocytopenic Purpura in A Patient with Disseminated Tuberculosis: An Unusual Presentation. *Internat J Mycobact*. 2019;8(1):107-109.
3. Weber SF, B elard S, Rai S, Reddy R, Belurkar S, Saravu K. Immune Thrombocytopenia Secondary to Tuberculosis: A Case and Review of Literature. *Internat J Tubercul Lung Dis. The Official J Internat Union against Tuberculosis and Lung Dis*. 2017;21(4):466-470.
4. Ghobrial MW, Albornoz MA. Immune thrombocytopenia: A rare presenting manifestation of tuberculosis. *American J Hematol*. 2001;67(2):139-143.
5. Lugao R, Motta MP, de Azevedo MF, de Lima RG, Abrantes F, Abdala E, et al. Immune Thrombocytopenic Purpura Induced by Intestinal Tuberculosis in a Liver Transplant Recipient. *World J Gastroenterol*. 2014;20(25):8304-8308.
6. Kelton JG, Vrbensky JR, Arnold DM. How do we diagnose immune thrombocytopenia in 2018? *Hematology. Amer Society Hematol. Education Program*. 2018;(1):561-567.
7. Fajardo YA, Morales EI, Sua LF, Fern andez-Trujillo L. Immune Thrombocytopenic Purpura, A Rare Manifestation of Active Tuberculosis: Case Report. *Clinical Case Reports*. 2020;8(10):1974-1978.
8. Panda S, Meher LK, Dalai SP, Nayak S, Tripathy SK. A Case of Immune Thrombocytopenic Purpura Secondary to Pulmonary Tuberculosis. *J Clin Diag Res*. 2016;10(10):OD12-OD13.
9. Salib M, Lemay A-S, Buchholz M, Pavenski K. Thrombocytopenia and Microangiopathic Hemolytic Anemia Precipitated By Acute Pancreatitis: A Single Center Experience of Five Cases. *Disorders Of Platelet Number or Function. Blood. Poster I*. 2016;128(22):1377.
10. Kakil IR, Mubarak AA, Al Suob H, Burney MA, Al Azawi SH, Aboudi K. Tuberculosis Presenting

- as Immune Thrombocytopenia: A Case Report and Review of the Literature. *Qatar Medical J.* 2006;15(1):62-64.
11. Ahamed ZR, Shah J, Agarwala R, Kumar MP, Mandavdhare HS, Gupta P, et al. Controversies in classification of peritoneal tuberculosis and a proposal for clinical-radiological classification. *Expert Review of Anti-Infective Therapy.* 2019;17(8):547-555.
 12. Sanai FM, Bzeizi KI. Systematic review: Tuberculous peritonitis—presenting features, diagnostic strategies, and treatment. *Alimentary Pharmacol Therapeut.* 2005;22(8):685-700.
 13. Wada H, Sakashita T. A Case of Immune Thrombocytopenia Due to Miliary Tuberculosis Effectively Treated with Eltrombopag. *Respiratory Medicine Case Reports.* 2020;31:101320.
 14. Rama Krishna M, Gottam US, Mahendra N. Disseminated Tuberculosis with Severe Immune Thrombocytopenia. *Respir Med Case Reports.* 2019;27:100812.
 15. Soni H, Bellam BL, Rao RK, Kumar PM, Mandavdhare HS, Singh H, et al. Use of steroids for abdominal tuberculosis: A systematic review and meta-analysis. *Infection.* 2019;47(3):387-394.
 16. Saukkonen JJ, Cohn DL, Jasmer RM, Schenker S, Jereb JA, Nolan CM, et al. Hepatotoxicity of Antituberculosis Therapy Subcommittee. An official ATS statement: Hepatotoxicity of antituberculosis therapy. *Am J Respir Critical Care Med.* 2006;174(8):935-952.
 17. Basir N, Djabir YY, Santoso A. Antituberculosis Drug-Induced Severe Hepatotoxicity: A Case Series in National Lung Health Center Makassar. *Nusantara Medical Sci J.* 2020;5(1):44-50.
 18. Wesnawa MADP, Kusmiati T. Drug Induced Hepatitis pada Tuberkulosis Paru dengan Multisite Tuberkulosis Ekstraparu: [Drug-Induced Hepatitis in Mixed Pulmonary and Extrapulmonary Tuberculosis]. *J Respir.* 2019;5(2):34-40.
 19. Arora SK, Shah D. Severe Thrombocytopenia Secondary to Tubercular Lymphadenitis. *Ann Trop Paediat.* 2010;30(2):157-159.
 20. Sari AP, Koesoemaprodjo W. Thrombocytopenia in Young Patient due to Anti Tuberculosis Drugs: A Case Report. *J Respir.* 2020;6(1):5-12.

Immune Thrombocytopenic Purpura Secondary to Peritoneal Tuberculosis Patient with Anti-Tuberculosis Drug-Induced Liver Injury. A Case Report

ORIGINALITY REPORT

18%

SIMILARITY INDEX

12%

INTERNET SOURCES

13%

PUBLICATIONS

4%

STUDENT PAPERS

PRIMARY SOURCES

- 1 S. K. Arora, D. Shah. "Severe thrombocytopenia secondary to tubercular lymphadenitis", *Annals of Tropical Paediatrics*, 2013
Publication 2%
- 2 journal.unhas.ac.id
Internet Source 2%
- 3 link.springer.com
Internet Source 2%
- 4 Malla Rama Krishna, Uma Sri Gottam, Nagendra Mahendra. "Disseminated tuberculosis with severe immune thrombocytopenia", *Respiratory Medicine Case Reports*, 2019
Publication 1%
- 5 Hua LU, Yong-ren WANG, Ou JI, Wei XU, Jian-fu ZHANG, Qin-he FAN, Jian-yong LI. "Supraclavicular lymph node tuberculosis

presenting with immune thrombocytopenic purpura", Chinese Medical Journal, 2007

Publication

6	cyberleninka.org Internet Source	1 %
7	S. F. Weber, S. B�elard, S. Rai, R. Reddy, S. Belurkar, K. Saravu. "Immune thrombocytopenia secondary to tuberculosis: a case and review of literature", The International Journal of Tuberculosis and Lung Disease, 2017 Publication	1 %
8	journals.lww.com Internet Source	1 %
9	medcraveonline.com Internet Source	1 %
10	jidc.org Internet Source	1 %
11	rcastoragev2.blob.core.windows.net Internet Source	1 %
12	Saad R. Samra. "Severe thrombocytopenia and intracranial hemorrhage: Unusual presentation of tuberculosis", Egyptian Journal of Bronchology, 2017 Publication	<1 %
13	Submitted to Udayana University Student Paper	

<1 %

14

www.hindawi.com

Internet Source

<1 %

15

Submitted to Angeles University Foundation

Student Paper

<1 %

16

A Tamori. "Lamivudine therapy for hepatitis B virus reactivation in a patient receiving intra-arterial chemotherapy for advanced hepatocellular carcinoma", Hepatology Research, 2003

Publication

<1 %

17

Sasmith R Menakuru, Adelina Priscu, Vijaypal S Dhillon, Ahmed Salih. "The Development of Immune Thrombocytopenia Due to COVID-19 Presenting as Menorrhagia", Cureus, 2022

Publication

<1 %

18

bmcgastroenterol.biomedcentral.com

Internet Source

<1 %

19

open.library.ubc.ca

Internet Source

<1 %

20

www.clevelandclinic.org

Internet Source

<1 %

21

oamjms.eu

Internet Source

<1 %

22	static.frontiersin.org Internet Source	<1 %
23	www.doh.wa.gov Internet Source	<1 %
24	www.medbox.org Internet Source	<1 %
25	Ramazan Idilman. "Antituberculous therapy-induced fulminant hepatic failure: Successful treatment with liver transplantation and nonstandard antituberculous therapy", Liver Transplantation, 09/2006 Publication	<1 %
26	caelum.ucv.ve Internet Source	<1 %
27	discovery.dundee.ac.uk Internet Source	<1 %
28	discovery.ucl.ac.uk Internet Source	<1 %
29	docksci.com Internet Source	<1 %
30	www.ann-clinmicrob.com Internet Source	<1 %
31	www.respiratoryguidelines.ca Internet Source	<1 %

32

www.xiahepublishing.com

Internet Source

<1 %

33

"Tuberculosis of the Gastrointestinal system",
Springer Science and Business Media LLC,
2022

Publication

<1 %

Exclude quotes Off

Exclude matches Off

Exclude bibliography On

Immune Thrombocytopenic Purpura Secondary to Peritoneal Tuberculosis Patient with Anti-Tuberculosis Drug-Induced Liver Injury. A Case Report

GRADEMARK REPORT

FINAL GRADE

/0

GENERAL COMMENTS

Instructor

PAGE 1

PAGE 2

PAGE 3

PAGE 4

PAGE 5

PAGE 6

PAGE 7

PAGE 8
