

# A Patient With CD4+ T Cells Deficiency And HIV Negative With Pulmonary Tuberculosis, Tuberculous Pleuritis And Meningitis Tuberculosis

*by* Muhammad Vitanata Arfijanto

---

**Submission date:** 08-May-2023 10:15AM (UTC+0800)

**Submission ID:** 2086996273

**File name:** erculosis,\_Tuberculous\_Pleuritis\_And\_Meningitis\_Tuberculosis.pdf (456.03K)

**Word count:** 3340

**Character count:** 18810

## A patient with CD4+ T cells deficiency and HIV negative with pulmonary tuberculosis, tuberculous pleuritis and meningitis tuberculosis



Anak Agung Fendy Triwicaksana<sup>1</sup>, Musofa Rusli<sup>2,3\*</sup>, M. Vitanata Arfijanto<sup>2,3</sup>,  
Bramantono<sup>2,3</sup>, Nasronudin<sup>2,3</sup>, Usman Hadi<sup>2,3</sup>

### ABSTRACT

**Background:** CD4+ T cells deficiency generally occurs in human immunodeficiency virus (HIV) patients, leading to some infections such as pulmonary and extrapulmonary tuberculosis. A rare case of decreased CD4+ T cells is idiopathic CD4+ T cell lymphocytopenia, a rare and unexplained immunodeficiency syndrome with no evidence of HIV infection. In this case report, we are reporting a patient with CD4+ T cells deficiency, pulmonary tuberculosis, pleuritis tuberculosis, and meningitis with HIV test negative.

**Case Presentation:** A 58-year-old male was referred to the Emergency Department of Dr. Soetomo General Hospital with a gradual decrease of consciousness following six days of hospitalization at a private hospital. During hospitalization, one liter of fluid was evacuated from the right lung and analyzed, revealing tuberculosis infection. History of diabetes, hypertension, stroke, hepatitis, and cardiovascular disease was denied. The patient also never had chemotherapy or radiation treatment. Based on history taking, physical examination, and laboratory results, this patient has been diagnosed new case of pulmonary tuberculosis with deficiency CD4+ T cells and altered consciousness et causes meningitis tuberculosis with pleurisy tuberculosis. After 32 days of hospitalization with anti-mycobacterium therapy, the patient was improved and was discharged.

**Conclusion:** This case highlights the challenges of having the definitive cause of CD4+ T cells deficiency either active tuberculosis infection or idiopathic CD4+ lymphocytopenia. Therefore, serial analyses of CD4+ T cells are advised on the patient during the treatment with anti-tuberculosis drug.

**Keywords:** CD4+ T cells deficiency, pulmonary tuberculosis, pleurisy tuberculosis, meningitis tuberculosis, ICL.

**Cite This Article:** Triwicaksana, A.A.F., Rusli, M., Arfijanto, M.V., Bramantono., Nasronudin., Hadi, U. 2022. A patient with CD4+ T cells deficiency and HIV negative with pulmonary tuberculosis, tuberculous pleuritis and meningitis tuberculosis. *Bali Medical Journal* 11(2): 597-601. DOI: 10.15562/bmj.v11i2.3458

<sup>1</sup>Departemen of Internal Medicine, Universitas Airlangga, Surabaya, 60132, Indonesia;

<sup>2</sup>Division of Tropical and Infection Disease, Department of Internal Medicine, Universitas Airlangga, Surabaya, 60132, Indonesia;

<sup>3</sup>Division of Tropical and Infection Disease, Department of Internal Medicine, Dr Soetomo General Hospital, Surabaya, 60132, Indonesia;

\*Corresponding author:

Musofa Rusli;  
Division of Tropical and Infection Disease,  
Department of Internal Medicine,  
Universitas Airlangga, Surabaya, 60132,  
Indonesia;  
musofa-r@fk.unair.ac.id

Received: 2022-04-27

Accepted: 2022-06-30

Published: 2022-07-15

### INTRODUCTION

The CD4+ T cells have an essential role in the human immune system by providing help to B cells. CD4+ T cells also contribute to the antiviral responses by producing cytokines and enhancing the response of CD8+ T cells.<sup>1</sup> The deficiency of CD4+ T cells in blood, airways, and lymph nodes can occur due to anti-CD4 antibodies.<sup>2</sup> Human immunodeficiency virus (HIV) infection is the most common cause of CD4+ T cells deficiency by binding to CD4+ T cells molecules on the surface of T helper cells and replicating inside them. Destroying CD4+ T cells cause a decrease in the stable T cell population and leading to risk of infections caused by bacteria, mycobacteria, viruses, fungi, and parasites.<sup>3</sup> However, several cases of CD4+

T cells deficiency cannot be identified. Idiopathic CD4+ lymphocytopenia (ICL) is a rare immune defect with an unexplained CD4+ T cells deficit. In addition, individuals suffering from severe opportunistic infections are also associated with low CD4+ T cell counts. If the patient has no evidence of HIV infection, then ICL became an alternative explanation for CD4+ T cells deficiency.<sup>4</sup>

Another disease associated with CD4+ cells deficiency is tuberculosis. Tuberculosis is the most common leading cause of death among people infected with HIV worldwide.<sup>5</sup> In 2014, 1.2 million people living with HIV were infected with tuberculosis and over 32% died.<sup>6</sup> Several cases have shown that ICL is also involved in the immune responses to *Mycobacterium tuberculosis* infection.

A study found that among 259 reviewed cases of ICL, 19 patients were infected with *M. tuberculosis*.<sup>7</sup>

*M. tuberculosis* can infect other organs except lung causing extrapulmonary tuberculosis. Common manifestations of extrapulmonary tuberculosis include pleurisy tuberculosis and meningitis tuberculosis.<sup>8</sup> Pleurisy tuberculosis is the most common form of extrapulmonary tuberculosis and it is the commonest cause of unilateral pleural effusion in countries with a high tuberculosis burden.<sup>9</sup> Meningitis tuberculosis is associated with high morbidity and mortality and when meningitis tuberculosis is suspected, treatment should be commenced immediately without waiting for bacteriological proof of diagnosis. The incidence of pleurisy and meningitis

tuberculosis is higher in people living with HIV than in uninfected patients.<sup>9,10</sup> Here, we report the case of a patient with no history of HIV with a CD4+ T cells reduction with pulmonary and extrapulmonary tuberculosis.

**CASE PRESENTATION**

A 58-year-old male was referred to the Emergency Department of Dr. Soetomo General Hospital with a gradual decrease of consciousness following six days of hospitalization at a private hospital. At the private hospital, the level of consciousness started to decrease; the patient spoke confusingly, communicated barely, and closed his eyes often. Two weeks before the admission the patient had headaches, nausea, and vomiting that had gradually worsened. The local community health center has prescribed the patient anti-pain and anti-emetic. The patient also had progressive dyspnea, which was not relieved by rest but by sitting and sleeping sideways. The patient was reported to have a dry cough with fever for three weeks and lost eight kilograms in one month. During the hospitalization, approximately one liter of fluid was evacuated from the right lung, and the patient diagnoses with tuberculosis infection. History of diabetes, hypertension, stroke, hepatitis, and cardiovascular disease were denied and no history of prior swelling, bleeding, or transfusion. The patient also never had chemotherapy or radiation treatment.

Physical examination showed a Glasgow Coma Score (GCS) of 11 (E3V2M5); blood pressure 140/90 mmHg with a regular heart rate of 114x/min (strong pulsation); oxygen saturation of 97% while wearing a three liters per minute (lpm) nasal cannula; regular respiratory rate of 25 x/min and axillary temperature of 37.9°C. The patient had a normal body mass index, 20.7 kg/m<sup>2</sup>.

Head and neck examination revealed no anemic conjunctiva, icteric sclera, lymph enlargement, or thyroid gland enlargement. Chest examination revealed symmetrical breath movement without chest wall retraction. Chest percussion revealed dullness and decreasing tactile fremitus in the third half of the right lung. There was decreased vesicular sound in the third half of the right lung. The

**Table 1. Laboratory test results of the patient.**

Laboratory test	Lab parameter	Result
Blood analysis	Hemoglobin	14.0 g/dL
	Lymphocytes	7960/mm <sup>3</sup>
	Platelet	229000 /mm <sup>3</sup>
	Albumin	3.86 mm/h
	Blood urea nitrogen	18 mg/dL
	Creatine	0.73 mg/dL
	Sodium	136 mmol/L
	Potassium	3.7 mmol/L
	Chloride	106 mmol/L
	Blood glucose	116 mg/dL
	Lymphocyte	6.9%
	HIV rapid test	Negative
	HBsAg	Negative
	Aspartate transaminase (AST)	22 U/L
	Alanine transaminase (ALT)	21 U/L
	pH	7.48
	pCO <sub>2</sub>	40
	pO <sub>2</sub>	121
	HCO <sub>3</sub>	24.8
	BE	3.3
Urinalysis	Urinalysis	Within normal limit
Pleural fluid analysis	Adenosine deaminase (ADA) test	79IU/L
	Glucose	9 mg/dL
	Mononuclear	79%
	Polymorphonuclear	21%
	Protein	251 mg/dL
	Rivalta	Positive
	Cytology	Negative

bronchovesicular sound was heard in the left parahillar region. Heart, adnominal, and extremities examinations were all within normal limits. Laboratory tests revealed low count of lymphocyte count (Table 1). Adenosine deaminase (ADA) test of pleural fluid was 79IU/L, Rivalta test positive with protein 251 mg/dL (Table 1).

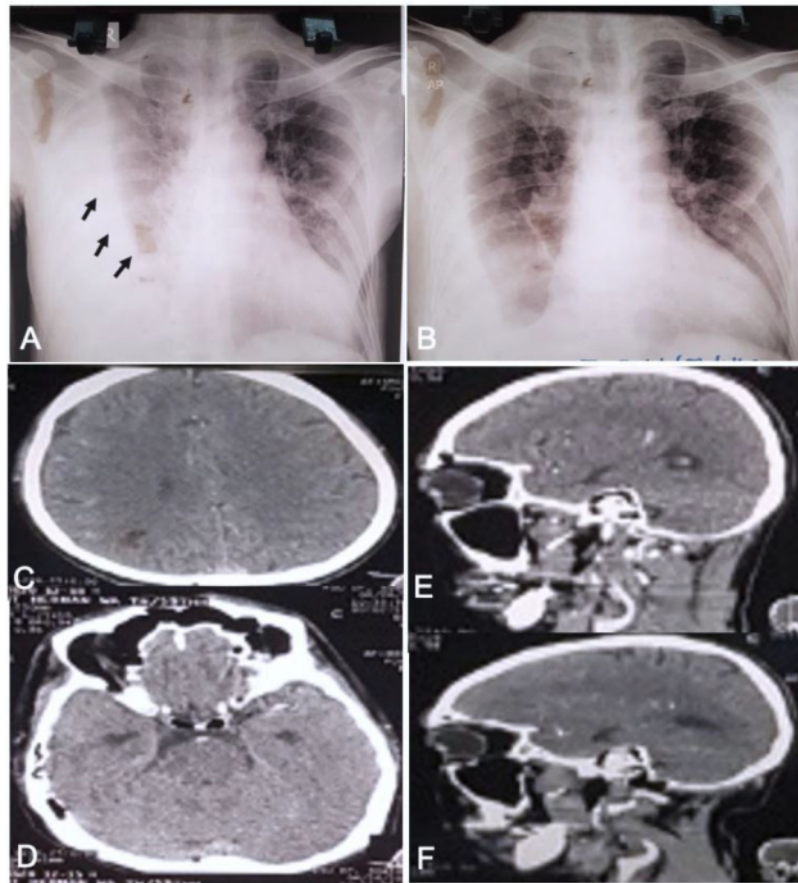
The chest radiograph (CXR) showed homogenous opacity in the right laterobasal hemithorax shadowing the right costophrenic sinus and fibroinfiltrate in the left and right suprahilar (Figures 1A and B). Neurologic diagnosed with suspected cerebrovascular accident (CVA) with differential diagnostics of tuberculous meningitis and bacterial meningitis. However, a head CT scan with contrast revealed no infection process, infarct, bleeding, or mass on brain parenchyma (Figure 1C-F).

Based on history taking, physical examination, and laboratory results, the patient was diagnosed with altered

consciousness due to meningitis tuberculous with differential diagnosis of bacterial meningitis with suspected new pulmonary tuberculosis and pleurisy tuberculosis. After five days of hospitalization, cerebrospinal fluid was analyzed for Gram stain and the acid-fast stain. Cerebrospinal fluids analysis demonstrated cell counts of 112 cell/mm<sup>3</sup>, mononuclear 98%, polymorphonuclear 2%, protein 225 mg/dL, glucose 9 mg/dL, cerebrospinal glucose: serum ratio of 0.075, positive result of acid-fast staining and CD4+ T cells counts 154 cells/mm<sup>3</sup>. The patient was diagnosed with a new case of pulmonary tuberculosis with ICL and altered consciousness due to meningitis tuberculous and pleurisy tuberculosis.

The patient was administered with anti-mycobacterium therapy for three days with isoniazid, rifampin, ethambutol, and pyrazinamide. After five days of treatment, additional therapy was given in which the patient was treated with dexamethasone





**Figure 1.** Chest radiograph and head CT-scan of the patient. (A) Chest radiograph showing homogenous opacity in right laterobasal hemithorax prior to fluid evacuation suggesting pleural effusion (black arrows). (B) Chest radiograph showing homogenous opacity in right laterobasal hemithorax shadowing the right costophrenic sinus, fibroinfiltrate in the left and right suprahilar post-evacuation of 1000 ml. (C-F) showing the normal head CT-scan.

and streptomycin until day 11 after which the streptomycin was discontinued. The patient showed improvement after 11 days of treatment with a restored sign of consciousness with GCS of 15 (E4V5M6), orientation to time, place, and person was good, dyspnea had improved, the speech had improved. Day 25 of hospitalization, the swallowing had improved and on day 32, the patient had no complaint and was discharged and was advised to have regular outpatient appointments on Department of Pulmonology, Neurology and Physiotherapy.

## DISCUSSION

CD4+ T cell is essential component in white blood cells that plays a central role in activating, coordinating, modulation, and regulating adaptive immune responses.<sup>11</sup> The deficiency of CD4+ T cells causes several problems, one of which is an infection caused by pathogens.<sup>12</sup> Several factors causes the deficiency of CD4+ T cells including HIV infection. CD4+ T cells deficiency in HIV patients is common in which HIV is attached to the CD4+ protein on the T cells surfaces and destroys CD4+ T cells, leading to a

weakened immune system.<sup>13</sup> If CD4+ T cells become depleted to less than 200 cells/UL, the body becomes more susceptible to opportunistic infections, particularly intracellular pathogens such as herpes simplex virus, *Mycobacterium*, *Listeria*, and intracellular fungal infection.<sup>14</sup> Our patient showed a CD4+ T cells deficiency to 154 cells/mm<sup>3</sup> and was diagnosed as having tuberculosis and CD4+ T cells deficiency pro evaluation with negative HIV test. This confirms that decreased CD4+ T cells are not associated with HIV.

Other factors contributing to the decline of CD4+ T cells are active tuberculosis and ICL.<sup>15</sup> The possibility of CD4+ T cell deficiency in tuberculosis may be caused by excessive and persistent stimulation during active tuberculosis infection. During developing immunity to *M tuberculosis* infection, CD4+ T cells act as antibodies to send signals to other effector cells. However, *M tuberculosis* dissemination causes CD4+ T cells to overuse functionally and inhibits the proliferation of CD4+ T cells.<sup>16</sup>

The CD4+ T cells deficiency in ICL patients is a rare case and ICL is a rare disease. Clinically, ICL manifests from asymptotically to the possibility of severe infections such as caused by *Candida*, cytomegalovirus, and *M. tuberculosis*. Some researchers hypothesize that apoptosis is the cause of CD4+ T cells deficiency ICL patients by T cell receptor cross-linking.<sup>17</sup> The most common infection in ICL patients is caused by *Cryptococcus neoformans* followed by *M. tuberculosis*.<sup>18</sup> In the present case report, the patient was positive for *M. tuberculosis* that infected multiple organs causing pulmonary tuberculosis, meningitis tuberculosis, and pleurisy tuberculosis. Pulmonary tuberculosis is the infectious and the most common form of tuberculosis, occurring in over 80% of cases.<sup>19</sup> A study found that patients who had recently been infected with *M tuberculosis* caused functional fatigue and reduced CD4+ T cells. This correlation between *M. tuberculosis* infection and CD4+ T cells which underlies that tuberculosis treatment will correlate with an increase in CD4+ T cells counts.<sup>20</sup> Meningitis tuberculosis also could cause

a decreased in CD4+ T cell levels.<sup>10</sup> The patient with pleural tuberculosis with CD4+ T cells deficiency with HIV was never reported. Pleural tuberculosis generally occurs at a young age with acute or subacute syndromes. Diagnosis of this disease uses pleural fluid biomarkers such as adenosine deaminase (ADA). Patients with ADA values >70 U/L are positive for pleural tuberculosis.<sup>21,22</sup>

Treatment of CD4+ T cells deficiency can be done by treating the infectious pathogens. In our case, the patient began to improve when anti-tuberculosis drugs were provided clinically. On day 32 of anti-tuberculosis treatment, the patient had no complaints and was advised to discharge. Anti-tuberculosis provided was isoniazid, rifampicin, and pyrazinamide. Since this anti-tuberculosis could cause the hepatitis, monitoring the side effects during treatment is essential and ethambutol is the only safe drug for people with liver disease.<sup>23,24</sup> Besides side effect monitoring, the risk drug interaction between anti-tuberculosis drugs and other drugs must be evaluated.

## CONCLUSION

We reported a case of a fifty-eight-year-old male suspected of CD4+ T cells deficiency with pulmonary and extra pulmonary tuberculosis (meningeal and pleural). The suspected etiology of CD4+ T cells deficiency, in this case, was either active tuberculosis infection or idiopathic CD4+ T cells lymphocytopenia. Therefore, CD4+ T cells recount was advised after tuberculosis treatment to ensure the patient's causative of CD4+ T cells deficiency. This patient highlights the difficulty of have definitive cause of the CD4+ T cells deficiency.

## PATIENT CONSENT

The patient's written informed consent was obtained to publish the case in an academic journal.

## ACKNOWLEDGMENTS

The authors are grateful to the entire hospital staff involved in patient care.

## DISCLOSURE OF CONFLICTS OF INTEREST

All authors declare that there is no conflict of interest.

## FUNDING

None.

## AUTHOR CONTRIBUTION

All authors contributed equally to the study.

## REFERENCES

- Swain SL, McKinstry KK, Strutt TM. Expanding roles for CD4+ T cells in immunity to viruses. *Nat Rev Immunol*. 2012;12(2):136–48. Available from: <https://pubmed.ncbi.nlm.nih.gov/22266691>
- Lin PL, Rutledge T, Green AM, Bigbee M, Fuhrman C, Klein E, et al. CD4 T cell depletion exacerbates acute Mycobacterium tuberculosis while reactivation of latent infection is dependent on severity of tissue depletion in cynomolgus macaques. *AIDS Res Hum Retroviruses*. 2012;05/04. 2012;28(12):1693–702. Available from: <https://pubmed.ncbi.nlm.nih.gov/22480184>
- Vidya Vijayan KK, Karthigeyan KP, Tripathi SP, Hanna LE. Pathophysiology of CD4+ T-Cell Depletion in HIV-1 and HIV-2 Infections. *Front Immunol*. 2017;8:580. Available from: <https://pubmed.ncbi.nlm.nih.gov/28588579>
- Mukherjee A, Lodha R, Kabra SK. Idiopathic CD4+ T-cell lymphocytopenia. *Indian J Pediatr*. 2009;76(4):430–2. Available from: <http://dx.doi.org/10.1007/s12098-009-0002-8>
- Chaudhary R, Bhatta S, Singh A, Pradhan M, Shrivastava B, Singh YI, et al. Diagnostic performance of GeneXpert MTB/RIF assay compared to conventional Mycobacterium tuberculosis culture for diagnosis of pulmonary and extrapulmonary tuberculosis, Nepal. *Narra J*. 2021;1(2). Available from: <http://dx.doi.org/10.52225/narra.v1i2.33>
- Soedarsono S, Mertaniasih NM, Kusmiati T, Permatasari A, Juliasih NN, Hadi C, et al. Determinant factors for loss to follow-up in drug-resistant tuberculosis patients: the importance of psycho-social and economic aspects. *BMC Pulm Med*. 2021;21(1):360. Available from: <https://pubmed.ncbi.nlm.nih.gov/34758794>
- Ahmad DS, Esmadi M, Steinmann WC. Idiopathic CD4 Lymphocytopenia: Spectrum of opportunistic infections, malignancies, and autoimmune diseases. *Avicenna J Med*. 2013;3(2):37–47. Available from: <https://pubmed.ncbi.nlm.nih.gov/23930241>
- Gopalaswamy R, Dusthacker VNA, Kannayan S, Subbian S. Extrapulmonary Tuberculosis—An Update on the Diagnosis, Treatment and Drug Resistance. *J Respir*. 2021;1(2):141–64. Available from: <http://dx.doi.org/10.3390/jor1020015>
- Jeon D. Tuberculous pleurisy: an update. *Tuberc Respir Dis (Seoul)*. 2014;04/25. 2014;76(4):153–9. Available from: <https://pubmed.ncbi.nlm.nih.gov/24851127>
- Marx GE, Chan ED. Tuberculous meningitis: diagnosis and treatment overview. *Tuberc Res Treat*. 2011/12/21. 2011;2011:798764. Available from: <https://pubmed.ncbi.nlm.nih.gov/22567269>
- Raphael I, Joern RR, Forsthuber TG. Memory CD4(+) T Cells in Immunity and Autoimmune Diseases. *Cells*. 2020;9(3):531. Available from: <https://pubmed.ncbi.nlm.nih.gov/32106536>
- França TGD, Ishikawa LLW, Zorzella-Pezavento SFG, Chiuso-Minicucci F, da Cunha M, Sartori A. Impact of malnutrition on immunity and infection. *J Venom Anim Toxins Incl Trop Dis*. 2009;15(3):374–90. Available from: <http://dx.doi.org/10.1590/s1678-91992009000300003>
- Suryono S, Nasronudin N. Clinical Description and Diagnosis of HIV/AIDS. *Indones J Trop Infect Dis*. 2015;5(1):23. Available from: <http://dx.doi.org/10.20473/ijtid.v5i1.212>
- Wingfield T, Wilkins E. Opportunistic infections in HIV disease. *Br J Nurs*. 2010;19(10):621–7. Available from: <http://dx.doi.org/10.12968/bjon.2010.19.10.93543>
- Naporn K, Insiripong S. Lymphocytopenia without HIV Infection. *The Southeast Asian journal of tropical medicine and public health*. 2016;47(3):503–5. Pubmed Central PMCID: 27405134.
- Yao S, Huang D, Chen CY, Halliday L, Wang RC, Chen ZW. CD4+ T cells contain early extrapulmonary tuberculosis (TB) dissemination and rapid TB progression and sustain multifactor functions of CD8+ T and CD3- lymphocytes: mechanisms of CD4+ T cell immunity. *J Immunol*. 2014/01/31. 2014;192(5):2120–32. Available from: <https://pubmed.ncbi.nlm.nih.gov/24489088>
- Wladis EJ. Idiopathic CD4+ Lymphocytopenia and Sjogren Syndrome. *Arch Ophthalmol*. 2005;123(7):1012. Available from: <http://dx.doi.org/10.1001/archophth.123.7.1012-a>
- Sikri V, Kaur H, Jain A. A rare case of idiopathic cluster of differentiation 4(+) T-cell lymphocytopenia presenting with disseminated tubercular infection. *Indian J Crit Care Med*. 2015;19(10):621–3. Available from: <https://pubmed.ncbi.nlm.nih.gov/26628830>
- Mertaniasih NM, Ananda IGY, Soedarsono S, Kusumaningrum D. Diagnosis Based on Detection of CXCL10 in Urine as Biomarker for The Determining Diagnosis of Active Lung Tuberculosis. *Indones J Trop Infect Dis*. 2021;9(1):57. Available from: <http://dx.doi.org/10.20473/ijtid.v9i1.22160>
- Jayaraman P, Jacques MK, Zhu C, Steblenko KM, Stowell BL, Madi A, et al. TIM3 Mediates T Cell Exhaustion during Mycobacterium tuberculosis—

- Infection. PLoS Pathog. 2016;12(3):e1005490–e1005490. Available from: <https://pubmed.ncbi.nlm.nih.gov/26967901>
21. Soedarsono S, Prinasetyo KWAI, Tanzilia M, Nugraha J. Changes of serum adenosine deaminase level in new cases of pulmonary tuberculosis before and after intensive phase treatment. Lung India. 2020;37(2):126–9. Available from: <https://pubmed.ncbi.nlm.nih.gov/32108596>
  22. Porcel JM. Advances in the diagnosis of tuberculous pleuritis. Ann Transl Med. 2016;4(15):282. Available from: <https://pubmed.ncbi.nlm.nih.gov/27570776>
  23. Kimmoun E, Samuel D. Antituberculous drugs in patients with chronic liver disease. J Gastroenterol Hepatol. 2002;17:S408–12. Available from: <http://dx.doi.org/10.1046/j.1440-1746.17.s3.36.x>
  24. Wande IN, Fuadi MR, Hadi S. The Correlation between total lymphocyte count, hemoglobin levels, lymphocyte/leukocyte ratio (LLR), and lymphocyte/neutrophil ratio (LNR) to CD4 levels in patients with Human Immunodeficiency Virus infection at Sanglah Hospital. Bali Med J. 2019;8(2):429. Available from: <http://dx.doi.org/10.15562/bmj.v8i2.1408>



This work is licensed under a Creative Commons Attribution

# A Patient With CD4+ T Cells Deficiency And HIV Negative With Pulmonary Tuberculosis, Tuberculous Pleuritis And Meningitis Tuberculosis

## ORIGINALITY REPORT

12%

SIMILARITY INDEX

6%

INTERNET SOURCES

7%

PUBLICATIONS

2%

STUDENT PAPERS

## PRIMARY SOURCES

- 1 Submitted to Universitas Nahdlatul Ulama Surabaya  
Student Paper 1%
- 2 [virologyj.biomedcentral.com](http://virologyj.biomedcentral.com)  
Internet Source 1%
- 3 Vingerhoets. "Superantigen activation of CD4+ and CD8+ T cells from HIV-infected subjects: role of costimulatory molecules and antigen-presenting cells (APC)", Clinical & Experimental Immunology, 1/1998  
Publication 1%
- 4 M. K. Chaffin. "Therapeutic effects of immune plasma in foals with Rhodococcus equi pneumonia", Equine Veterinary Journal, 06/10/2010  
Publication 1%
- 5 Arif Nur Muhammad Ansori, Viol Dhea Kharisma, Sahal Sabilil Muttaqin, Yulanda Antonius, Arli Aditya Parikesit. "Genetic



Variant of SARS-CoV-2 Isolates in Indonesia:  
Spike Glycoprotein Gene", Journal of Pure and  
Applied Microbiology, 2020

Publication

---

6	Submitted to Udayana University Student Paper	1 %
7	K D Kauffman, M A Sallin, S Sakai, O Kamenyeva et al. "Defective positioning in granulomas but not lung-homing limits CD4 T- cell interactions with Mycobacterium tuberculosis-infected macrophages in rhesus macaques", Mucosal Immunology, 2017 Publication	<1 %
8	es.scribd.com Internet Source	<1 %
9	synapse.koreamed.org Internet Source	<1 %
10	content.sciendo.com Internet Source	<1 %
11	journals.plos.org Internet Source	<1 %
12	www.europeanreview.org Internet Source	<1 %
13	www.researchsquare.com Internet Source	<1 %

---



14

Caiqi Cheng, Jun Zhou, Ruiying Chen, Yo Shibata, Reina Tanaka, Jun Wang, Jiaming Zhang. "Predicted Disease-Specific Immune Infiltration Patterns Decode the Potential Mechanisms of Long Non-Coding RNAs in Primary Sjogren's Syndrome", *Frontiers in Immunology*, 2021

Publication

&lt;1 %

15

Edward J. Wladis. "Idiopathic CD4+ Lymphocytopenia and Sjogren Syndrome", *Archives of Ophthalmology*, 2005

Publication

&lt;1 %

16

Hilal, T., P. Hurley, and M. McCormick. "Disseminated tuberculosis with tuberculous meningitis in an immunocompetent host", *Oxford Medical Case Reports*, 2014.

Publication

&lt;1 %

17

José M. Porcel. "Advances in the diagnosis of tuberculous pleuritis", *Annals of Translational Medicine*, 2016

Publication

&lt;1 %

18

Lingyun Shao, Xinyun Zhang, Yan Gao, Yunya Xu, Shu Zhang, Shenglei Yu, Xinhua Weng, Hongbo Shen, Zheng W. Chen, Weimin Jiang, Wenhong Zhang. "Hierarchy Low CD4+/CD8+ T-Cell Counts and IFN- $\gamma$  Responses in HIV-1+ Individuals Correlate with Active TB and/or M.tb Co-Infection", *PLOS ONE*, 2016

&lt;1 %

19

Shuyu Yao, Dan Huang, Crystal Y. Chen, Lisa Halliday, Richard C. Wang, Zheng W. Chen. "CD4 T Cells Contain Early Extrapulmonary Tuberculosis (TB) Dissemination and Rapid TB Progression and Sustain Multieffector Functions of CD8 T and CD3 Lymphocytes: Mechanisms of CD4 T Cell Immunity ", The Journal of Immunology, 2014

Publication

<1 %

---

20

[books.ersjournals.com](http://books.ersjournals.com)

Internet Source

<1 %

---

21

[etd.library.emory.edu](http://etd.library.emory.edu)

Internet Source

<1 %

---

22

[japsonline.com](http://japsonline.com)

Internet Source

<1 %

---

23

[www.recentmedicalfindings.com](http://www.recentmedicalfindings.com)

Internet Source

<1 %

---

24

Huan Xia, Wei Jiang, Xin Zhang, Ling Qin, Bin Su, Zhen Li, Jianping Sun, Yonghong Zhang, Tong Zhang, Xiaofan Lu, Hao Wu. "Elevated Level of CD4+ T Cell Immune Activation in Acutely HIV-1-Infected Stage Associates With Increased IL-2 Production and Cycling Expression, and Subsequent CD4+ T Cell Preservation", Frontiers in Immunology, 2018

Publication

<1 %

---

25

Lin, Philana Ling, Tara Rutledge, Angela M. Green, Matthew Bigbee, Carl Fuhrman, Edwin Klein, and JoAnne L. Flynn. "CD4 T Cell Depletion Exacerbates Acute *Mycobacterium tuberculosis* While Reactivation of Latent Infection Is Dependent on Severity of Tissue Depletion in Cynomolgus Macaques", *AIDS Research and Human Retroviruses*, 2012.

Publication

<1 %

26

Felisitas Farica Sutantoyo, Paulus Sugianto. "A malignant disseminated tuberculosis: concurrent intracranial tuberculosis with skipped multilevel spondylitis in a young immunocompetent patient", *Romanian Journal of Neurology*, 2022

Publication

<1 %

27

Jeffrey D. Coote, Angelina M. Dixon, Brigid E. O'Brien, Russell W. Steele. "Headache and Lethargy in a 6-Year-Old", *Clinical Pediatrics*, 2018

Publication

<1 %

Exclude quotes Off

Exclude matches Off

Exclude bibliography On

# A Patient With CD4+ T Cells Deficiency And HIV Negative With Pulmonary Tuberculosis, Tuberculous Pleuritis And Meningitis Tuberculosis

---

## GRADEMARK REPORT

---

FINAL GRADE

**/0**

GENERAL COMMENTS

**Instructor**

---

PAGE 1

---

PAGE 2

---

PAGE 3

---

PAGE 4

---

PAGE 5

---