



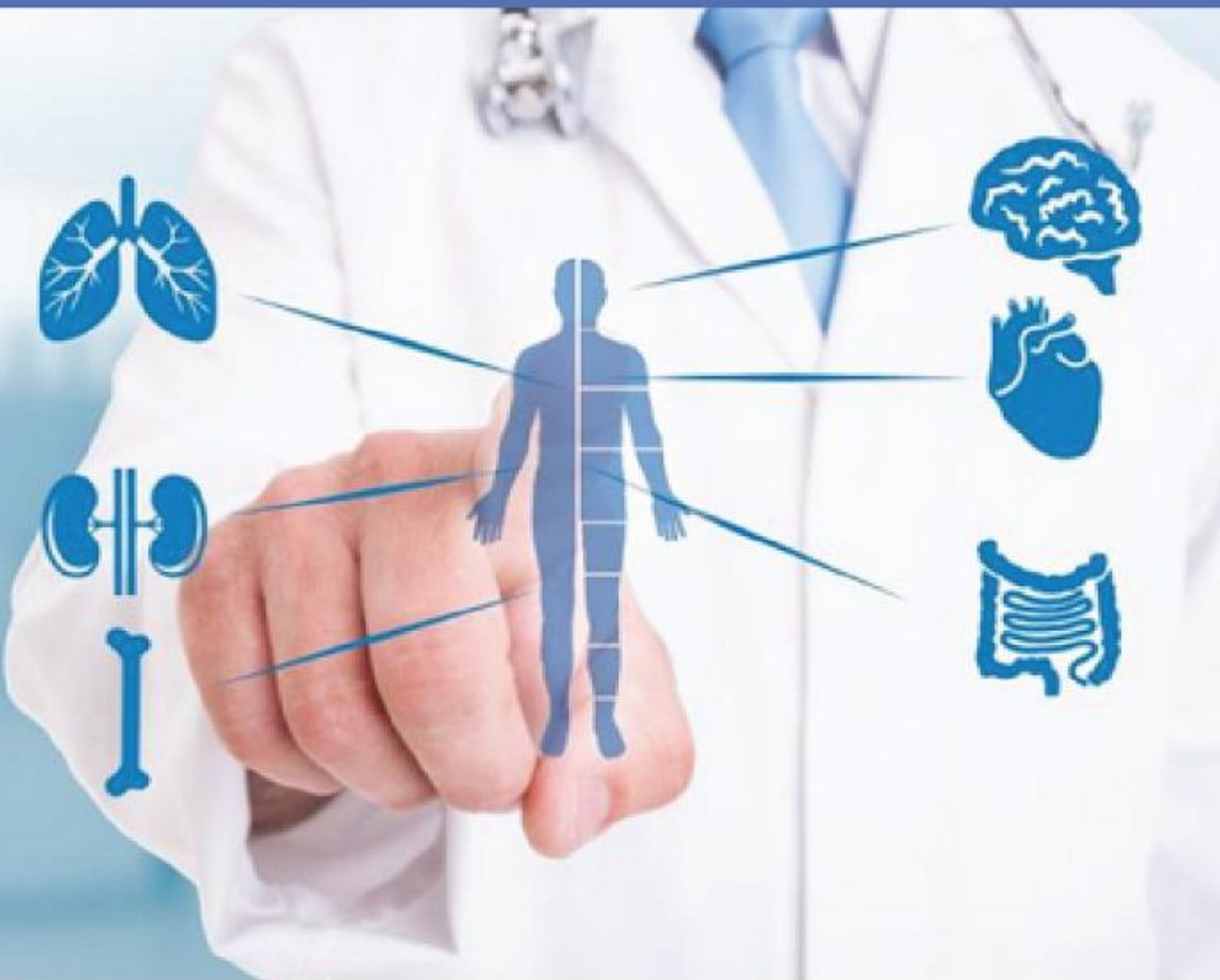Faculty of Medicine
Universitas Airlangga

Current Internal Medicine Research and Practice Surabaya Journal



PAPDI
Surabaya

Volume 03, No. 1 January 2022



E-ISSN 2721-544X

email:
cimrj@journal.unair.ac.id

Editorial Team



Prof. Usman Hadi, MD, PhD

Editor in Chief

Universitas Airlangga - Dr. Soetomo General Hospital, Surabaya, Indonesia

0000-0001-9348-7046

SiBMKckAAAAJ

55804160500

 6033004



Pranawa MD, PhD

Honorary Editor

Universitas Airlangga - Dr. Soetomo General Hospital, Surabaya, Indonesia

-

-

24492604300



-



Poernomo Boedi Setiawan, MD, PhD

Honorary Editor

Universitas Airlangga - Dr. Soetomo General Hospital, Surabaya, Indonesia

-

-

6507682592



6063860



Prof. Muhammad Miftahussurur, MD, PhD

Associate Editor

Universitas Airlangga - Dr. Soetomo General Hospital, Surabaya, Indonesia

0000-0003-1415-6033

CZifxcsAAAAJ

56323903000

 6031037



Sony Wibisono Mudjarnako, MD, PhD

Associate Editor

Universitas Airlangga - Dr. Soetomo General Hospital, Surabaya, Indonesia

0000-0003-1415-6033

py8JTXoAAAAJ

57200935068

 6069482



Prof. Jaap Middeldorp, MD, PhD

Editorial Board

Amsterdam University Medical Centers, Netherlands

0000-0002-0765-4125

BpidPdkAAAAJ

35493462100



-



Prof. Nasronudin, MD, PhD

Editorial Board

Universitas Airlangga - Dr. Soetomo General Hospital Surabaya, Indonesia

-
vg1wTxwAAAAJ

55516591900



6048817



Prof. Iswan A. Nusi, MD, PhD

Editorial Board

Universitas Airlangga - Dr. Soetomo General Hospital Surabaya, Indonesia

-
Xy8J3UwAAAAJ

56543515200



6064196



Prof. Ami Ashariati, MD, PhD

Editorial Board

Universitas Airlangga - Dr. Soetomo General Hospital Surabaya, Indonesia

0000-0003-0508-4496

0qQhPOsAAAAJ

28767507600



6063540



Prof. Agung Pranoto, MD, MSc, PhD

Editorial Board

Universitas Airlangga - Dr. Soetomo General Hospital Surabaya, Indonesia

-
TnV8ao8AAAAJ

6507008841



6068255



Prof. Djoko Santoso, MD, PhD

Editorial Board

Universitas Airlangga - Dr. Soetomo General Hospital Surabaya, Indonesia

-
pidodrUAAAAJ

55383692000



256881



Wachid Putranto, MD, PhD

Editorial Board

Universitas Sebelas Maret, Surakarta, Indonesia

-
B7JLYOQAAAAJ
57201032172

 6717367



I Gusti Putu Suka Aryana, MD, PhD

Editorial Board

Udayana University, Bali, Indonesia

0000-0001-8582-2254
eWkwQFoAAAAJ
37062993600

 6070903



Gatot Soegiarto, MD, PhD

Editorial Board

Universitas Airlangga - Dr. Soetomo General Hospital Surabaya, Indonesia

-
EZ1e-Ziaaaaj
57193717004

 5987257



Prof. Andi Makbul Aman, MD, PhD

Editorial Board

Hasanuddin University, Makassar, Indonesia

0000-0002-1310-9721
sXD4PiMAAAAJ
57193706169

 6068486



Athfiyatul Fatati, S.Ant

Managing Editor

Universitas Airlangga, Surabaya, Indonesia

Published: 2022-01-31

ORIGINAL ARTICLE

CORRELATION OF METABOLIC SYNDROME WITH GENU OSTEOARTHRITIS IN TYPE 2 DIABETES MELLITUS PATIENTS

DOI : 10.20473/cimrj.v3i1.28169

Diaz Syafrie Abdillah , Ardyarini Dyah Savitri , Effendi .

1-4

 Abstract : 343

 PDF : 220

[PDF](#)

BIOFILM FORMATION AND ANTIMICROBIAL RESISTANCE OF ESCHERICHIA COLI IN VITRO TOWARDS CEFTRIAZONE AND CEFIXIME

DOI : 10.20473/cimrj.v3i1.32549

Jihan Kalishah , Dominicus Husada , M Vitanata Arfijanto , Agung Dwi Wahyu Widodo

5-8

 Abstract : 486

 PDF : 185

[PDF](#)

CORRELATION BETWEEN HEALTHCARE SERVICE QUALITY AND HIV TESTING SERVICES PATIENT'S SATISFACTION IN KEDUNGORO PRIMARY HEALTH CARE SURABAYA

DOI : 10.20473/cimrj.v3i1.32586

Arinda Agung Katritama , Pudji Lestari , Muhammad Vitanata Arifijanto

9-12

 Abstract : 388

 PDF : 184

[PDF](#)

CHARACTERISTIC OF CHRONIC COMPLICATIONS IN TYPE 2 DIABETIC PATIENT BASED ON ASIAN PERSPECTIVE

DOI : 10.20473/cimrj.v3i1.31412

Corina Ong

13-15

 Abstract : 424

 PDF : 263

[PDF](#)

CASE REPORT

DIAGNOSTIC AND MANAGEMENT PROBLEMS OF HYPERTHYROIDISM IN A PATIENT WITH TESTICULAR SEMINOMA

DOI : 10.20473/cimrj.v3i1.29969

Dicky Febrianto , Hermina Novida

16-21

 Abstract : 591

 PDF : 299


[PDF](#)

SUICIDE ATTEMPT IN ELDERLY: AN OVERLOOKED COMPLICATION OF LATE-LIFE DEPRESSION

DOI : 10.20473/cimrj.v3i1.32537

Yhan Batista , Novira Widajanti , Agustina Konginan

22-25

 Abstract : 316

 PDF : 198

[PDF](#)

REVIEW ARTICLE


EXPANDED DENGUE SYNDROME

DOI : 10.20473/cimrj.v3i1.32536

Agustinus Vincent , Bramantono - , Usman Hadi , **Muhammad Vitanata Arifijanto**

26-32

 Abstract : 351

 PDF : 807

[PDF](#)

Expanded Dengue Syndrome

Agustinus Vincent , Bramantono , Usman Hadi , M. Vitanata Arfijanto 

Department of Internal Medicine, Faculty of Medicine, Universitas Airlangga – Dr. Soetomo General Hospital Surabaya, Indonesia

ABSTRACT

Dengue viral infection (DVI) is a debilitating arthropod-borne disease that has been rapidly spread in several regions of the world in recent years. The spectrum of the disease varies from mild self-limiting illness to dengue fever (DF) to more severe and fulminating forms, i.e., dengue hemorrhagic fever (DHF), dengue shock syndrome (DSS), and expanded dengue syndrome (EDS). The pathogenesis of EDS is not clear amid the lack of studies on animal models. In the absence of in vitro experiments, the disease spectrum is challenging to elucidate and mimic for humans. Recent advances in research on atypical complications of EDS demonstrate the involvement of other major organs such as the kidney, lung, heart, and central nervous system. Histopathological findings demonstrate the presence of hemorrhage, edema, and inflammatory infiltrates in these organs. The spectrum of Dengue viral infection varies from mild self-limiting illness to dengue fever to more severe and fulminating forms, i.e., dengue hemorrhagic fever, dengue shock syndrome, and expanded dengue syndrome. Apart from the classical presentation, dengue infection can result in a myriad of unusual clinical manifestations grouped under the title expanded dengue syndrome. These findings urge more focused and comprehensive investigations to explore such relationships so that high-risk patients could be identified immediately during their presentation to the hospitals.

Keywords: Expanded dengue syndrome, Pathogenesis, Organ-specific manifestation

Correspondence: Bramantono

E-mail: ibambramantono@gmail.com

Article history: •Received 4 November 2021 •Received in revised form 21 November 2021 •Accepted 4 December 2021 •Available online 31 January 2022

INTRODUCTION

Dengue viral infection (DVI) is a debilitating arthropod-borne disease that has been rapidly spread in several regions of the world in recent years (Messina et al., 2014). The disease is widespread throughout the tropics, with local variations in risk, and is influenced by rainfall, temperature, and unplanned rapid urbanization. The spectrum of the disease varies from mild self-limiting illness to dengue fever (DF) to more severe and fulminating forms, i.e., dengue hemorrhagic fever (DHF) and dengue shock syndrome (Mallhi et al., 2017). In recent years with the geographical spread of dengue and more involvement of adults, there have been increasing reports of DVI with unusual manifestations, termed as “expanded dengue syndrome” (EDS). These atypical and unusual organopathies include intricacies of major organs, such as the liver, kidney, heart, lungs, and nervous system. They could be explained as a complication of severe profound shock or associated with underlying host conditions or co-infections. The involvements of various organs are increasingly being reported in DHF. At the same time, EDS can also occur during DF without any evidence of plasma leakage (Mallhi et al., 2021).

The global burden of dengue is formidable and represents a growing challenge to health authorities. Knowledge of dengue's geographical distribution and burden is essential for understanding its contribution to global morbidity and mortality. The surge in dengue has been most marked in Asia. It accounts for 75% of the global dengue burden, costing Southeast Asia US\$1 billion annually. It is estimated that among 2.5 billion people at

risk globally, about 1.8 billion reside in Asia. Southeast Asia records approximately 2.9 million dengue episodes and 5906 fatality cases annually, with a yearly monetary burden of \$950 million (Shepard et al., 2013). According to WHO, from 1968 to 2009, Indonesia was one of the highest dengue-endemic areas in Southeast Asia. In 2016, from 34 provinces in Indonesia, dengue cases were 202314 patients with 1593 deaths. From January to May 2017, there were 17887 cases with 115 deaths. Until September 2017, there were 302 cases of DHF in Surabaya (Kemenkes RI, 2017). In Dr. Soetomo General Hospital, there were 156 cases of DHF with 30 cases of EDS from 2017-to 2018. Mortality was caused by myocarditis, kidney failure, and acute respiratory distress syndrome (Avina et al., 2020).

PATHOGENESIS

Until now, most experts still believe in the secondary heterologous infection hypothesis or the sequential infection hypothesis, which states that DHF can only occur if a person has been infected with dengue virus infection for the first time, then gets another infection with a different virus serotype within six months to 5 years (Sri et al., 2014). The pathogenesis of dengue virus infection is related to:

- Virus factors such as serotypes, the number of viruses, and the level of virulence.
- Host factors, genetics, age, nutritional status, comorbid disease, and host-virus interactions
- Environmental factors, seasons, climate, air temperature, population density, and level of urbanization

The role of the immune system in dengue virus infection are:

- a. Primary infection offers lifelong immunity to the causative serotype
- b. Secondary infection with a different virus serotype (secondary heterologous infection) will have severe clinical manifestations compared to the primary infection. For one year, there was a history of diabetes mellitus controlled with metformin 500 milligrams three times daily. She had controlled hypertension for two years with amlodipine 10 milligrams daily. There was a history of being admitted to the Psychiatric ward one month ago for four days, diagnosed with severe depression episode and suicide attempt. She received clobazam 5 milligrams twice daily and sertraline 25 milligrams once daily. The history of recreational drugs abuse was denied. There is no psychosis history in her family. She is a widow with four children. Her husband, a former military, died 12 years ago due to a heart attack. She just moved into a second child's house for one month. Before moving into her second

In general, the pathogenesis of dengue virus infection is a complex interaction of various components of the immune system that occur in an integrated manner. The most important immune cells are dendritic cells, monocytes/macrophages, endothelial cells, and platelets. As a result of these complex interactions, various inflammatory cytokines will be released, and a complement cascade will be activated, with activation of T cells. If the immune response is too excessive, large amounts of cytokines and inflammatory mediators will be released, leading to various disorders that eventually correlate with dengue virus infection signs and symptoms.

The critical determinant of disease severity in the majority of patients with dengue is hypovolaemia secondary to increased systemic vascular permeability and plasma leakage. A particular pattern of hemostatic abnormalities typically evolves parallel with the plasma leakage. However, coagulopathy is not always accompanied by clinical manifestations of bleeding. Close observation for signs of plasma leakage is critical from the end of the febrile phase. The most common method of monitoring leakage relies on identifying relative haemoconcentration, determined by tracking changes in serial hematocrit measurements. Unfortunately, the method is relatively insensitive, particularly if the patient is receiving parenteral fluid therapy and the baseline hematocrit value for an individual is unknown (Yacoub et al., 2014).

The pathogenesis of dengue-associated vasculopathy is likely to be multifactorial, including various host and viral factors. Complement activation mediated by soluble and membrane-associated nonstructural protein 1 (NS1) might have a role in generating anaphylatoxins and the terminal SC5b-9 complement complex. High levels of NS1 and SC5b-9 in the plasma of patients with dengue correlated with disease severity and were also found in large amounts, together with the anaphylatoxin C5a, in the plasma of patients with DSS. NS1 bound to endothelial cells can then be targeted by cross-reactive NS1 antibodies during secondary infections, leading to complement-mediated cytolysis and endothelial cell damage. Immunopathogenic theories suggest a greater T cell response in severe DENV infection than in mild infection, with cells that produce high levels of cytokines predominating. The resulting excessive proinflammatory response, particularly by tumor necrosis factor (TNF), has been implicated in increased vascular

permeability. Sera from patients with dengue has been shown to induce endothelial cell activation *in vitro*. This effect can be inhibited by anti-TNF monoclonal antibodies (Yacoub et al., 2013). Later in the disease course, TNF and other vasoactive mediators can enhance vascular permeability. The vasoactive cytokine vascular endothelial growth factor (VEGF) and its soluble receptors might also have a role in increasing vascular permeability, although these results have not been supported by findings from other studies (Seet et al., 2009).

EXPANDED DENGUE SYNDROME

In recent years with the geographical spread of dengue and more involvement of adults, there have been increasing reports of DVI with unusual manifestations, termed as "expanded dengue syndrome." These atypical and unusual organopathies include intricacies of major organs, such as the liver, kidney, heart, lungs, and nervous system. They could be explained as a complication of severe profound shock or associated with underlying host conditions or co-infections. The involvements of various organs are increasingly being reported in DHF. At the same time, EDS can also occur during DF without any evidence of plasma leakage (WHO, 2011). These atypical manifestations were previously termed as "unusual complications" by WHO. Currently, EDS is a new entity incorporated into WHO guidelines. The immunopathological mechanisms during dengue infection primarily target endothelium, resulting in vascular permeability and coagulation disorders that can explain these varied systemic involvements.

The pathogenesis of EDS is not clear amid the lack of studies on animal models. In the absence of *in vitro* experiments, the disease spectrum is challenging to be elucidated and mimic for humans (Bhatt et al., 2013). However, autopsy data from human studies is of utmost importance and provides satisfactory answers to various questions related to etiological factors of EDS. These studies also provide information on target tissues and possible mechanisms for the dengue virus to infect specific organs. Most of these studies report histopathological findings among fatal dengue cases and report the liver, spleen, and lymph nodes as major target organs for the dengue virus. Recent advances in research on the atypical complication of EDS demonstrate the involvement of other major organs such as the kidney, lung, heart, and central nervous system. Histopathological findings demonstrate the presence of hemorrhage, edema, and inflammatory infiltrates in these organs (Mallhi et al., 2015).

Both children and older age in adults were demographical risk factors for progression to severe disease. Pre-existing diabetes, hypertension, renal disease, and cardiovascular disease were also associated with progression to severe disease. In addition, DENV-2 infection, secondary infection, a lower platelet count, lower serum albumin, and higher AST and ALT concentrations detected during the febrile phase were significantly associated with progression to severe disease. The finding of a higher risk of progression to severe disease in older adults could be due to co-existing diabetes, hypertension, or renal disease, which are common in older adults. Children were at a higher risk of progression to severe disease, which might be due to increased vascular filtration capacity among younger children (Sangkaew et al., 2021).

Diabetes and hypertension were included as risk factors for progression to severe illness in the 1997 and 2011 WHO guidelines (WHO, 2011). Factors including pre-existing

vasculature damage and associated endothelial activation might contribute. Chronic kidney disease could result in increased concentrations of pro-inflammatory cytokines, adding to the risk of vascular injury during dengue infections. Uraemia, commonly found in chronic kidney disease, also causes endothelial dysfunction, predisposing individuals to worse dengue-associated vasculopathy (Yacoub et al., 2017).

Obese patients were at high risk of developing complications and death due to their stronger immune response than malnourished patients (Guzman et al., 2010). DENV infected obese patients possess many clinical parameters suggestive of more severe clinical manifestations as evidenced by a higher frequency of haemoconcentration, severe thrombocytopenia, elevations of creatinine, liver enzymes. Hypothetically, obesity may affect the severity of dengue through inflammation pathways. The increased deposition of white adipose tissue (WAT) in obese individuals leads to increased production of Interleukin (IL)-6, IL-8, and Tumor Necrosis Factor-Alpha (TNF- α). IL-6, IL-8, and TNF- α were essential inflammation pathway mediators that increase capillary permeability (Calobro et al., 2005).

ORGAN-SPECIFIC MANIFESTATION

Cardiac Manifestations

Cardiac manifestations of dengue include functional myocardial impairment, arrhythmias, and myocarditis, which can occur through some mechanisms. Dengue myocarditis has been described using various diagnostic criteria, in some case reports and small case series from endemic areas (Yacoub et al., 2014). Arifjanto et al. reported an 18 years old woman with acute myocarditis due to DVI based on laboratory findings, including thrombocytopenia hemoconcentration, with positive results for NS1 and dengue IgM, IgG examination, elevated CKMB, elevated troponin, and hyperechogenic cardiographic features (Arifjanto et al., 2018). However, very few patients with dengue have a formal cardiac assessment, so the frequency of subclinical dengue myocarditis and its relative contribution to the hemodynamic instability in severe dengue remains to be demonstrated (Marques et al., 2013).

a. Functional studies

Myocardial dysfunction in acute dengue has been documented in several studies using various techniques. Dysfunction is transient, except in a minority of fulminant cases of fatal myocarditis. Most patients have a normal cardiac function by the end of their acute illness. No long-term follow-up studies have been conducted, and no definitive evidence of progression to dilated cardiomyopathy exists. The pathogenic mechanisms underlying functional myocardial impairment remain to be elucidated, but as most of the patients do not have evidence of myocardial damage, direct viral invasion of cardiomyocytes is unlikely. Other postulated mechanisms include myocardial edema from local capillary leakage, the presence of a circulating myocardial depressant factor (for example, one or more pro-inflammatory mediators), coronary hypoperfusion, altered calcium homeostasis, or a combination of these factors. By contrast, in fulminant dengue myocarditis, evidence exists of widespread myocyte damage with substantial increases in levels of cardiac biomarkers, ST-segment changes on ECG mimicking acute myocardial infarction, and cardiac-specific

symptoms and clear signs of functional impairment. Like fulminant myocarditis of other aetiologies, dengue myocarditis is associated with high mortality. The pericardium can also be affected by dengue, but less frequently than the myocardium, with very few reports of isolated dengue pericarditis (Daniel et al., 2013). However, pericardial effusions are observed occasionally, particularly in severe dengue. They are likely related to the severity of systemic plasma leakage from the capillaries. Large, clinically relevant pericardial effusions are extremely rare but have been documented (Miranda et al., 2013).

b. Electrocardiographic (ECG) studies

ECG alterations reported in dengue are often transient and nonspecific, including sinus bradycardia, atrio-ventricular block, T wave, and ST-segment abnormalities. The underlying mechanisms for these electrical abnormalities have not been adequately explored. Possibilities include altered autonomic tone, electrolyte, calcium derangements, or subclinical myocarditis. The clinical relevance of ECG alterations in dengue remains speculative. However, an obvious concern is a bradyarrhythmia starting in the critical phase when hypovolaemia is also present. The inability to mount an appropriate heart rate response to maintain cardiac output may add to hemodynamic instability. Cautious attention to fluid balance and hemodynamic monitoring is warranted in these patients (La-orkhun et al., 2011).

c. Pathologic studies

Histopathological studies of the heart in patients with dengue are lacking, with only a limited number of autopsy studies published and no reports of endomyocardial biopsies from patients with suspected dengue myocarditis. Autopsies of five patients from Sri Lanka showed predominantly interstitial edema, inflammation, and myocardial fiber necrosis. These individuals had clinical syndromes that would be consistent with fulminant myocarditis, with associated ECG, echocardiographic, and cardiac biomarker abnormalities (Weerakon et al., 2011).

Pulmonary Manifestations

Acute respiratory distress syndrome (ARDS) is a significant complication in severe forms of dengue viral infection. Dengue virus (DENV) antigen is found in alveolar cells during ARDS. It causes increased vascular permeability in alveoli resulting in interstitial and alveolar edema. ARDS in DHF and DSS is manifested as pleural effusion, pulmonary hemorrhage, pneumonia, and shock, which can result in severe dyspnea. The pulmonary pathogenesis includes pleural effusion, increased vascular permeability, plasma leakage, and hemostasis abnormalities (Mohamed et al., 2013).

Virus replication primarily takes place in the lung epithelium during DVI. The fact that lungs are susceptible to dengue infection is supported by dengue virus particles in lungs cells, viral RNA synthesis in the cell, and the release of viral particles in the supernatants. The order of efficiency of replication of DENV in lung cells is as follows: DENV-2 > DENV-3 > DENV-4 > DENV-1 (Lee et al., 2007).

The lung epithelial cells are possibly targeted by the DENV. Both IL-6 and RANTES play a pivotal role in the pathogenesis of dengue-associated pulmonary complications. Existing data elaborated that IL-6 and RANTES expressions are elevated in DENV-2 infection

(Lee et al., 2007).

Gastrointestinal Manifestations

a. Acute acalculous cholecystitis

Acute acalculous cholecystitis is usually manifested with right upper quadrant pain. Altered liver function tests are usually present. Thickened (>3.5 mm) edematous gallbladder wall with no stone and positive sonographic Murphy's sign (maximum tenderness of sonographically localized gallbladder) is diagnostic for acute acalculous cholecystitis. The exact pathogenesis of acalculous cholecystitis is poorly understood. However, in DHF, direct viral invasion with plasma leakage and serous effusion from increased vascular permeability is thought to thicken the gallbladder wall (Tavares et al., 2019). A recent study in Indonesia has conducted a prospective cohort study showing increased GBWT during severe dengue and reduced GBWT after resolution of the illness. The GBWT showed a progressive increase between days 3 to 8 of illness, corresponding to the critical phase of dengue fever (Michels et al., 2013).

b. Acute Pancreatitis

Acute pancreatitis in dengue infection presents with similar features as with other causes. The exact pathogenesis is poorly understood but has been postulated to result either from direct invasion by the virus itself, causing inflammation and destruction of pancreatic acinar cells; or pancreatic damage due to dengue shock syndrome; or an acute viral infection causing an autoimmune response to pancreatic islet cells and development of edema of the ampulla of Vater with obstruction to the outflow of pancreatic fluid. Raised pancreatic enzymes and edematous pancreas on ultrasound are evident. Though mortality is high in other etiology, acute pancreatitis as EDS usually runs a benign course (Anam et al., 2016).

c. Spontaneous splenic rupture

Spontaneous splenic rupture is when non-traumatic splenic rupture occurs in a histologically proven normal spleen. It is a very rare and potentially fatal form of EDS. It can occur in both the acute and recovery phase of DHF. The spleen, frequently congestive, bears subcapsular hematomas in 15% of cases. Left upper quadrant pain and shock is the usual manifestation. The exact mechanism is yet to understand completely, but hypothesized as increased intrasplenic tension caused by cellular hyperplasia and engorgement; compression by abdominal muscles during sneezing, coughing, or defecation; and vascular occlusion causing thrombosis and infarction, interstitial and subcapsular bleed, stripping of the capsule and finally capsular rupture. In dengue, it is thought to be due to a combination of coagulation factors and severe thrombocytopenia (Anam et al., 2013).

d. Hepatic manifestations

Elevation of liver transaminases was greater in patients with DHF than DF, and aspartate transaminase (AST) levels were higher than alanine aminotransferase (ALT) levels. It is assumed that the latter may be a result of myositis. Although the liver is frequently involved in dengue infection, hepatic injury is usually mild to moderate. However, reported cases of acute hepatic failure complicated with hepatic encephalopathy, hepatorenal syndrome, severe bleeding, and metabolic acidosis. It has also been reported that acute hepatic failure is known to occur in patients with dengue infection without plasma leakage (Suganthan et al., 2020). Hepatic dysfunction is a crucial feature seen in DENV infection. Hepatocytes and Kupffer cells are prime targets

for DENV infection, as confirmed in biopsies and autopsies of fatal cases. For infecting cells, the major rate-limiting step is the viral attachment to the receptors present on the host cell surface. An eventual outcome of hepatocyte infection by DENV is cellular apoptosis. A phenomenon demonstrated both in vivo and in vitro (Umankath et al., 2020). The dengue infection had a varied presentation, as far as liver involvement is concerned (i.e., it presented as anicteric hepatitis, icteric hepatitis, Acute liver failure (ALF), acute on chronic liver failure (ACLF), and worsening liver failure in a previously decompensated cirrhosis). The incidence of ALF due to dengue infection in adults is reported somewhere between 5.2–8.9%. Patients with cirrhosis had a prolonged hospital stay and a higher complication rate, leading to significantly higher mortality than those without cirrhosis or liver disease. Dengue leading to liver failure and the subsequent outcome could be predicted independently based upon the presence of jaundice (total serum bilirubin >7mg/dL) or impaired hepatic synthetic function, i.e., coagulopathy: INR of >2. Deranged LFT in addition to thrombocytopenia and hemoconcentration is a clue for dengue-related liver involvement. Patients with an underlying liver disease without cirrhosis can develop liver failure and need to be managed aggressively. Dengue infection is greatly masked by liver disease due to disproportionately low hemoglobin (in contrast to hemoconcentration) and low platelet count, but transient liver enzyme elevation with AST > ALT is a clue for suspecting dengue infection. Jaundice is uncommon with dengue, but the presence of jaundice or coagulopathy could be a red-flag sign (Kulkarni et al., 2019).

Renal Manifestations

Renal involvement is one of the most significant target organ involvements in dengue viral infection (DVI). There is a broad spectrum of renal diseases in dengue patients. Such complications include elevation of the serum creatinine (SCr) levels, acute kidney injury (AKI), acute tubular necrosis (ATN), hemolytic uremic syndrome (HUS), proteinuria, glomerulopathy, and nephrotic syndrome (Lizaragga et al., 2014). In recent years, dengue-induced AKI (DAKI) has evolved as an important emerging complication of DVI. The prevalence of AKI in dengue cases has been observed in 14.2% of patients with DVI. Dengue patients with AKI portend significant morbidity, mortality, and healthcare cost (Mallhi et al., 2015).

Proteinuria was the most common presentation seen in 9.02% of patients (Eswarappa et al., 2019). Vasanwala et al. reported two DHF patients with nephrotic-range proteinuria without increasing serum creatinine, hematuria, or urinary casts. Proteinuria of 8.09 g and 8.97 g/day was noted, with spontaneous remission seen by day-10 in the first patient and spontaneous reduction of proteinuria by more than 50% on day-11 in the second patient. (Vasanwala et al., 2009). Acute dengue infection with underlying renal parenchymal diseases predisposed the patient to develop DAKI. The associated renal diseases were glomerulonephritis, nephrotic range proteinuria, lupus nephritis, IgA nephropathy, mesangioproliferative glomerulonephritis, and systemic lupus erythematosus (Lim et al., 2019).

Several mechanisms have been proposed to elaborate the etiology and pathophysiology of dengue-induced renal disorders, including direct action by the virus, hemodynamic instability, rhabdomyolysis, hemolysis, and acute glomerular injury. The available literature shows the direct viral invasion of the kidney or the hemodynamic

fluctuations during dengue infection as the most important attributes of the kidney involvements in addition to the non-immunological mechanisms. The immune system might also play a crucial role in the renal intricacies of dengue. Low levels of serum complement (C3) have been reported in DHF patients, especially when shock, sepsis, hemolysis, and rhabdomyolysis are not evident. The hemodynamic instability in dengue patients is believed to be a result of inflammatory cytokines, particularly tumor necrosis factor- α (TNF- α), interleukin (IL)-6, IL-17, and IL-18, all of which are produced by dengue infected monocytes and mast cells. These hemodynamic factors lead to renal disorders among patients with dengue infection. Autoimmunity induced by molecular mimicry is another possible mechanism for dengue-associated renal disease. This phenomenon has also been reported in other viral infections, namely, coxsackievirus and Epstein-Barr virus. Autoantibodies against platelets, endothelial cells, and coagulatory molecules have been demonstrated in patients with dengue virus infection. They are believed to be a consequence of cross-reactivity to dengue virus antigen, NS1, prM, and E proteins, respectively. These antibodies can cause platelet dysfunction, endothelial injury, and coagulopathy upon binding to their corresponding antigens. Autoimmunity has been reported in dengue patients with serologically and pathologically confirmed anti-glomerular basement membrane (GBM) disease in association with positive p-anti-neutrophil cytoplasmic antibody (p-ANCA) and anti-myeloperoxidase antibody (AMA) on serologic studies (Lizaragga et al., 2015).

Neurologic manifestations

Neuropathogenesis is likely associated with direct invasion of the CNS by the virus, autoimmune reactions, and metabolic alterations. The dengue virus is considered neurotropic (Li et al., 2017). Until 2012, neurological complications of dengue virus infection were classified into three categories based on pathogenesis as proposed by Murthy, Marzia, and colleagues: (1) metabolic disturbance, e.g., encephalopathy; (2) viral invasion, including encephalitis, meningitis, myositis, and myelitis; (3) autoimmune reactions, including acute disseminated encephalomyelitis, neuromyelitis optica, optic neuritis, myelitis, encephalopathy, and Guillain-Barré syndrome (Puccioni-Sohler et al., 2012). Encephalitis and encephalopathy are the most common neurological presentations of dengue infection (Solbrig et al., 2015).

a. Encephalitis

Encephalitis is among the most common neurological manifestations of DVI. Dengue encephalitis is found in the three classical disease groups of dengue classification, including DF, DHF, and DSS. Recent studies showed that the neuropathy associated with DENV and its ability to invade CNS resulted in an expanded clinical spectrum of encephalitis. The neuropathogenesis of dengue encephalitis is primarily concerned with neurotropism, i.e., viral invasion. In vitro studies have demonstrated that mutant DENV-1 causes extensive leptomeningitis and encephalitis in mice. It is hypothesized that mutant DENV can cross the blood-brain barrier due to neurotropism. Dengue virus neurotropism can also be evidenced by detecting intrathecal synthesis of specific antibodies in patients with dengue myelitis (Solbrig et al., 2015).

b. Encephalopathy

Encephalopathy caused by dengue fever can be reflected by reduced sensitivity, cognitive impairment,

convulsions, and personality and behavior disorders, including acute mania, depression, emotional lability, anxiety, and psychosis. Dengue-associated encephalopathy is generally severe, with around 50% of the affected patients succumbing (Baldaçara et al., 2013).

c. Meningitis

Meningitis refers to the inflammation of protective layers around the CNS called meninges. Dengue-induced meningitis is attributed to the direct tissue lesion caused by the virus because of its neurotropism, capillary hemorrhage, disseminated intravascular coagulation (DIC), and metabolic disorders (Solbrig et al., 2015).

d. Transverse myelitis

Spinal cord involvement during dengue infection is infrequent. Acute transverse myelitis is a type of spinal cord involvement observed among dengue patients. Acute transverse myelitis (ATM) may occur during DVI or post-infection. Post-infectious immune-mediated myelitis usually develops within 14 days after initial symptoms. In contrast, parainfectious myelitis can occur among patients within the first seven days of infection. Both viral neurotropism and post-infectious mechanisms are involved in the pathogenesis of dengue-associated myelitis. DENV is pathogenic to the neural tissues. This direct pathogenic effect is evident by the presence of viral antigens in the CSF of patients. Viral antigen in the CSF can be detected during the early stage of the infection. Moreover, viral antigens can be isolated from the brain, brainstem, and spinal cord, where the virus can infect neural tissues. The pathogenesis of post-infectious myelitis revolves around the transient autoimmune reactions against myelin or other self-antigens, possibly by molecular mimicry or by nonspecific activation of auto-reactive T-cell clones (Murthy et al., 2010).

e. Hypokalemic paralysis

Several authors reported Dengue-associated hypokalemic paralysis. However, most studies were based on isolated case reports and short series (Li et al., 2017). The pathogenesis of hypokalemic paralysis in dengue remains obscure. It can be hypothesized that hypokalemia during DVI might be attributed to serum potassium redistribution in cells and increased urinary excretion of potassium due to transient renal tubular dysfunction. The leakage of plasma through a vascular wall is considered central in the pathogenesis of dengue-induced hypokalemia. Unlike other hemorrhagic viral infections, overt endothelial damage and cytopathic effects on endothelial cells are not indicated in DVI. The endothelial damage during DVI might be triggered by antibodies secreted by B lymphocytes and cytokines involved in the cell-mediated immunity. These cytokines include tumor necrosis factor- α (TNF- α), interferon- γ (IFN- γ), and interleukins (IL-2, IL-6, IL-1 β , and IL-8). Activation of endothelial cells enhances this inflammatory response, resulting in overexpression of various chemokines and vascular endothelial growth factors (VEGF). The endothelial dysfunction results in fluid and electrolytes out of the vascular compartment and reduced serum potassium levels (Li et al., 2017). Moreover, kidney function impairment caused by glomerular, tubular, interstitial, or vascular endothelial damage is another important factor associated with hypokalemia in DVI. Dengue-

induced acute kidney injury with hypokalemia is a highly morbid and fatal complication of DVI (Mallhi et al., 2015).

CONCLUSION

The spectrum of dengue virus infection varies from mild self-limiting illness to dengue fever (DF) to more severe and fulminating forms, i.e., dengue hemorrhagic fever (DHF) and dengue shock syndrome. WHO introduced EDS to refer to cases with a clinical spectrum not included in either DHF or DSS. The most commonly affected organs in EDS are the liver, kidney, lung, heart, and brain, with dengue myocarditis being associated as the leading cause of the fatal outcome. A comprehensive understanding of EDS will lead us to better assessment and therapy. A clinician should be aware of signs of organ dysfunction to detect a potentially severe dengue virus infection immediately.

ACKNOWLEDGEMENT

Universitas Airlangga grant supported this research.

CONFLICT OF INTEREST

The authors declare there is no conflict of interest.

REFERENCES

- Anam AM, Rabbani R, Shumy F, Polash MM. 2016. Subsequent Pancreatitis and Haemothorax in a Patient of Expanded Dengue Syndrome. *Trop Doct* 46:40-42.
- Anam AM, Polash MMI, Islam MM, Bhuiyan MMR, Nooruzzaman ARM, Uddin MN. 2013. Spontaneous Splenic Rupture in Severe Dengue. *Bangladesh Crit Care J* 1:59-62.
- Arifjanto MV, Luqmana HP, Rusli M, Bramantono. 2018. An expanded dengue syndrome patient with manifestation myocarditis: case report 2018. *IOP Conf. Ser.: Earth Environ Sci* 125:012094.
- Avina FA, Aryati, Suhintam. 2020. Prevalence of Expanded Dengue Syndrome in Patients with Dengue Virus Infection at the Dr. Soetomo Hospital Surabaya in 2017 – 2018. *Indonesia Journal of Clinical Pathology and Medical Laboratory* 26(3):307-311.
- Bhatt S, Gething PW, Brady OJ, Messina JP, Farlow AW, Moyes CL, et al. 2013. The global distribution and burden of dengue. *Nature* 496(7446):504.
- Baldaçara L, Ferreira JR, Filho LC, Venturini RR, Coutinho OM, Camarço WC, et al. 2013. Behavior disorder after encephalitis caused by dengue. *J Neuropsychiatry Clin Neurosci* 25:E44. doi: 10.1176/appi.neuropsych.12020040.
- Calabro P, Chang DW, Willerson JT, Yeh ET. 2005. Release of C-reactive protein in response to inflammatory cytokines by human adipocytes: linking obesity to vascular inflammation. *J Am Coll Cardiol* 46(6):1112-1113.
- Daniel RA, Silva AR, Neppelenbroek VB, Feres O, Bestetti RB. 2013. Fulminant myocarditis and viral infection. *J Clin Virol* 58:1-3.
- Eswarappa M, Reddy SB, John MM, Suryadevara S, et al. 2019. Renal Manifestations of Dengue Viral Infection. *Saudi J Kidney Dis Transpl* 30(2):394-400.
- Guzman MG, Halstead SB, Artsob H, et al. 2010. Dengue: a continuing global threat. *Nat Rev Microbiol* 8(suppl): S7-16.
- Hadi U, Bramantono, Vitanata M, Rusli M, Rahman BE, Asmarawati T, Marfiani E, Triyono EA. 2021. Diagnostic Patterns of Suspected Covid-19 Patients Using Scor Covid-19, PCR Test and Serological Test in Dr. Soetomo Hospital Surabaya, Indonesia. *Current Internal Medicine Research and Practice Surabaya Journal* 2(2):25-28.
- Health Ministry of the Republic of Indonesia. Profil kesehatan Provinsi Jawa Timur tahun 2017–2018. Accessed 9 June 2021. Available at <http://www.depkes.go.id>
- Kulkarni AV, Choudhury AK, Premkumar M, Jain P, Gupta E, Sarin SK. 2019. Spectrum, manifestations and outcomes of dengue infection in individuals with and without liver disease. *J Clin Transl Hepatol* 7(2):106–111. doi: 10.14218/JCTH.2018.00047.
- La-Orkhun V, Supachokchaiwattana P, Lertsapcharoen P, Khongphatthanayothin A. 2011. Spectrum of cardiac rhythm abnormalities and heart rate variability during the convalescent stage of dengue virus infection: a Holter study. *Ann Trop Paediatr* 31:123–128.
- Lee YR, Su CY, Chow NH, Lai WW, Lei HY, Chang CL, et al. 2007. Dengue viruses can infect human primary lung epithelia as well as lung carcinoma cells, and can also induce the secretion of IL-6 and RANTES. *Virus Res* 126(1–2):216–225.
- Li G-H, Ning Z-J, Liu Y-M and Li X-H. 2017. Neurological Manifestations of Dengue Infection. *Front Cell Infect Microbiol* 7:449. doi: 10.3389/fcimb.2017.00449.
- Lim CTS, Fuah KW, Lee SE, et al. 2019. Dengue-Associated Acute Kidney Infection: An Updated and Comprehensive Qualitative Review of Literature. *EMJ Nephrol* 7(1):86-94.
- Lizarraga KJ, Nayer A. 2014. Dengue-associated kidney disease. *J Nephropathol* 3(2):57.
- Lizarraga KJ, Florindez JA, Daftarian P, Andrews DM, Ortega LM, Mendoza JM, et al. 2015. Anti-GBM disease and ANCA during dengue infection. *Clin Nephrol* 83(2):104–110.
- Mallhi TH, Khan AH, Sarriff A, Adnan AS, Khan YH. 2017. Determinants of mortality and prolonged hospital stay among dengue patients attending tertiary care hospital: a cross-sectional retrospective analysis. *BMJ Open* 7(7):e016805.
- Mallhi TH, Khan AH, Adnan AS, Sarriff A, Khan YH, Jummaat F. 2015. Clinico-laboratory spectrum of dengue viral infection and risk factors associated with dengue hemorrhagic fever: a retrospective study. *BMC Infect Dis* 15(1):399.
- Mallhi TH, Khan AH, Adnan AS, Sarriff A, Khan YH, Jummaat F. 2015. Incidence, characteristics and risk factors of acute kidney injury among dengue patients: a retrospective analysis. *PLoS ONE* 10(9):e0138465. doi:10.1371/journal.pone.0138465.
- Mallhi TH, Khan AH, Adnan AS, Tanveer N, Aftab RA. 2021. Expanded Dengue Syndrome. *Springer Nature Singapore*. doi.org/10.1007/978-981-15-7337-8.
- Marques N, Gan VC, Leo YS. 2013. Dengue myocarditis in Singapore: two case reports. *Infection* 41: 709–714.
- Messina JP, Brady OJ, Scott TW, Zou C, Pigott DM, Duda KA, et al. 2014. Global spread of dengue virus types: mapping the 70 year history. *Trends Microbiol* 22(3):138–146.
- Michels M, Sumardi U, de Mast Q, Jusuf H, Puspita M, Dewi IMW, et al. 2013. The predictive diagnostic value of serial daily bedside ultrasonography for severe dengue in Indonesian adults. *PLoS Negl Trop Dis* 7: e2277.

- Miranda CH, et al. 2013. Evaluation of cardiac involvement during dengue viral infection. *Clin Infect Dis* 57:812–819.
- Murthy J. 2010. Neurological complications of dengue infection. *Neurol India* 58(4):581.
- Puccioni-Sohler M, Orsini M, Soares CN. 2012. Dengue: a new challenge for neurology. *Neurol Int* 4:e15. doi:10.4081/ni.2012.e15.
- Sangkaew S, Ming D, Boonyasiri A, et al. 2021. Risk predictors of progression to severe disease during the febrile phase of dengue: a systematic review and meta-analysis. *Lancet Infect Dis* 21:1014-1026.
- Seet RC, Chow AW, Quek AM, Chan YH, Lim EC. 2009. Relationship between circulating vascular endothelial growth factor and its soluble receptors in adults with dengue virus infection: a case-control study. *Int J Infect Dis* 13:e248–e253.
- Shepard DS, Undurraga EA, Halasa YA. 2013. Economic and disease burden of dengue in Southeast Asia. *PLoS Negl Trop Dis* 7(2):e2055.
- Solbrig MV, Perng GC. 2015. Current neurological observations and complications of dengue virus infection. *Curr. Neurol Neurosci Rep* 15:29. doi:10.1007/s11910-015-0550-4.
- Sri rezeki HH, Sugeng S, Suharyono W, Thomas S. 2014. *Tata laksana Demam Dengue/Demam berdarah Dengue*. Jakarta, Dirjen P2M & PLP, Depkes RI.
- Suganthan N, Sakthilingham G, Kumanan T. 2020. Dengue fever complicated with acute liver failure: A case report of expanded dengue syndrome and literature review. *SAGE Open Med Case Rep*.
- Tavares MA, Joao GAP, Bastos, MS, et al. 2019. Clinical relevance of gallbladder wall thickening for dengue severity: cross sectional study. *PLoS ONE* 14(8):e0218939.
- Umakanth M, Suganthan N. 2020. Unusual Manifestations of Dengue Fever: A Review on Expanded Dengue Syndrome. *Cureus* 12(9):e10678. doi 10.7759/cureus.10678.
- Vasanwala FF, Puvanendran R, Ng JM, Suhail SM. 2009. Two cases of self-limiting nephropathies secondary to dengue haemorrhagic fever. *Singapore Med J* 50:e253-e255.
- Weerakoon KG, et al. 2011. Histopathological diagnosis of myocarditis in a dengue outbreak in Sri Lanka, 2009. *BMC Res Notes* 4,268.
- World Health Organization. 2009. Special Programme for Research and Training in Tropical Diseases, World Health Organization. Department of Control of Neglected Tropical Diseases, World Health Organization. Epidemic and Pandemic Alert and Response. *Dengue: guidelines for diagnosis, treatment, prevention and control*. Geneva, World Health Organization.
- World Health Organization. 2011. *Comprehensive guidelines for prevention and control of dengue and dengue haemorrhagic fever*, Revised and extended edition. Geneva, World Health Organization.
- Yacoub S, Lam PK, Huynh TT, et al. 2017. Endothelial nitric oxide pathways in the pathophysiology of dengue: a prospective observational study. *Clin Infect Dis* 65:1453–1461.
- Yacoub S, Wertheim H, Simmons CP, Screaton G, Wills B. 2014. Cardiovascular manifestations of the emerging dengue pandemic. *Rev Cardiol* 11:335–345.
- Yacoub S, Mongkolsapaya J, Screaton G. 2013. The pathogenesis of dengue. *Curr Opin Infect Dis* 26:284–289.