



Case Report

Oral squamous cell carcinoma with essential thrombocythemia and positive JAK2 (V617F) mutation

Kurnia H. Rahman, DDS^a, Meircurius D.C. Surboyo, MDS^a, Desiana Radithia, Ph.D^b,
Adiastuti E. Parmadiati, MDS^b, Asdi Wihandono, MD^c and Diah S. Ernawati^{b,*}

^aOral Medicine Recidency, Faculty of Dental Medicine, Universitas Airlangga, Indonesia

^bDepartment of Oral Medicine, Faculty of Dental Medicine, Universitas Airlangga, Indonesia

^cDepartment of Surgical Oncology, Faculty of Medicine, Universitas Airlangga, Indonesia

Received 16 June 2021; revised 9 September 2021; accepted 15 September 2021; Available online 15 November 2021

المخلص

كثرة الصفائح المجهولة السبب هي حالة ناتجة عن ارتفاع عدد الصفائح الدموية وطفرة جاك-2 إيجابية. هناك زيادة في حدوث الورم الخبيث، مثل سرطان الخلايا الحرفية الفموي، لدى مرضى كثرة الصفائح المجهولة السبب. الهدف من تقرير الحالة هذا هو توثيق حالة جديدة لمرضى مصاب بسرطان الخلايا الحرفية الفموي، بعد تشخيص حالته بكثرة الصفائح المجهولة السبب وطفرة جاك-2 إيجابية. كانت المريضة امرأة تبلغ من العمر 42 عاماً تشكو من قرحة وآلم في اللسان الجانبي الأيمن لمدة ثلاثة أشهر. بعد أسبوعين، خف الآلم، ومع ذلك، كان هناك تورم وآلم واضح على القرحة. تم تشخيص حالة المريضة بكثرة الصفائح المجهولة السبب وطفرة جاك-2 الإيجابية وبدأت في الخضوع للعلاج بهيدروكسي يوريا منذ ثلاثة أشهر. استند تشخيص سرطان الخلايا الحرفية الفموي على علم الخلايا التقشري والتصوير بالرنين المغناطيسي. تم علاج المريض بغسول فم مطهر لمنع العدوى الثانوية وإحالاته إلى طبيب الأورام لعلاج سرطان الخلايا الحرفية الفموي. من الممكن استخدام العلامات المشتبه بها لكثرة الصفائح وطفرة جاك-2 الإيجابية لتحديد تشخيص سرطان الخلايا الحرفية الفموي.

الكلمات المفتاحية: السرطان؛ كثرة الصفائح المجهولة السبب؛ صفائح؛ طفرة؛ سرطان الخلايا الحرفية الفموي

Abstract

Essential thrombocythemia is a condition caused by a high platelet count and a positive JAK2 (V617F) mutation. There is an increasing occurrence of malignancy,

such as oral squamous cell carcinoma (OSCC), in patients with essential thrombocythemia. The objective of this case report is to document the novel instance of a patient with OSCC after being diagnosed with essential thrombocythemia and a positive JAK2 (V617F) mutation. The patient was a 42-year-old female who complained of an ulcer and pain in the dextral lateral tongue for three months. After two weeks, the pain diminished; however, there was swelling and tenderness on the ulcer. The patient was diagnosed with essential thrombocythemia and a positive JAK2 (V617F) mutation and began undergoing hydroxyurea therapy three months prior to the OSCC diagnosis. The diagnosis of OSCC was based on exfoliative cytology and MRI. The patient was treated with an antiseptic mouthwash to prevent secondary infection and referred to an oncologist to manage the OSCC. It is possible to use the suspected markers of thrombocytosis and a positive JAK2 (V617F) mutation to define the OSCC diagnosis.

Keywords: Cancer; Essential thrombocythemia; JAK2; Mutation; Oral squamous cell carcinoma; Platelet

© 2021 The Authors.

Production and hosting by Elsevier Ltd on behalf of Taibah University. This is an open access article under the CC BY-NC-ND license (<http://creativecommons.org/licenses/by-nc-nd/4.0/>).

* Corresponding address: Department of Oral Medicine, Faculty of Dental Medicine, Universitas Airlangga, Jln. Prof. Dr. Moestopo No 47, Surabaya, 60132, Indonesia.

E-mail: diah-s-e@fkg.unair.ac.id (D.S. Ernawati)

Peer review under responsibility of Taibah University.



Production and hosting by Elsevier

Introduction

Oral cancer is currently one of the most extensive health problems worldwide. Data published by the World Health

Organization (WHO) in 2012 indicated a higher occurrence and mortality rate in South-East Asia than in America, Africa, and Europe. The same data also showed that there were 103,464 incidents of oral cancer annually in South-East Asia, with an annual mortality rate of 25,202. Oral squamous cell carcinomas (OSCC) account for over 90% of all cases of oral cancer. Oral cancer is currently recognised as the sixth most deadly form of cancer in the human body.¹

A patient's genetic predisposition and environmental influences affect the accumulation of the multiple genetic alterations required, and thus affect the development of OSCC. The genetic alterations consist of tumour suppressor genes inactivated through genetic events such as mutation, loss of heterozygosity, removal, or epigenetic modifications such as DNA methylation or chromatin remodelling. Overexpression due to gene amplification, increased transcription, or changes in structure due to mutations that lead to increased transforming activity can activate the oncogenes.²

Thrombocytopenia is a condition that creates a high platelet count. Thrombocytopenia is seen as a primary disease (primary myeloproliferative disease) or as a reactive (secondary) disease to that of other bone marrow diseases. Primary thrombocytopenia or essential thrombocytosis are classifications derived from the myeloproliferative disorder caused by the Janus Kinase 2 (JAK2) mutation,³ one of the JAKs family, which includes.

JAK1, JAK3, and TYK2. The activation of JAK2 through activating the signal transducer and activator of transcription (STAT) by JAK-catalyzed phosphorylation, is included in the hematopoietic process.⁴ The JAK2 mutation affects calreticular receptors in megakaryocytes, resulting in STAT activation and causing the excessive proliferation of platelet, called thrombocytopenia. Thrombocytopenia with positive JAK2 manifests in the form of increased platelet levels.^{4,5} The increased number of platelets affects the production of the platelet-derived growth factor (PDGF), which is a proangiogenic factor that affects cell differentiation and increases cell survival. The PDGF signaling

pathways are key regulators of angiogenesis, tumor growth hormone, and tumor survival.⁶

A high number of platelets circulating in the blood can result in various diseases. The role of platelets includes serving as an energy source for tumours, providing a growth factor to tumours, and being the key element of cancer growth and metastasis. The association between thrombocytopenia and cancers has been proven in the relevant literature, and the apparent increase in platelet count has been ascribed to many malignancies, but there is limited data regarding oral malignancies.⁶ This case presents the appearance of OSCC on the lateral tongue of a woman with essential thrombocytopenia who tested positive for JAK2 (V617F) mutation.

Case report

Patient history

The patient was a 42-year-old female whose chief complaint was the sudden appearance of a small ulcer with pain on the dextral lateral tongue, which persisted for three months (Figure 1A and 1B). The pain was mild (Wong Baker Face Pain Scale = 2), did not interfere with the patient's daily activities, and continued for two weeks, after which the pain reduced, but there was swelling around the ulcer. The patient self-medicated with Mycostatin oral drops and dental gel containing aloe vera for three weeks, but there no change was noticed. The patient stated that she rarely developed ulcers. The last time she had experienced an ulcer was on the buccal mucosa six months prior to the present ulcer, caused by biting herself, and this healed naturally.

Extraoral examination, on palpation, showed that the submandibular lymph node was soft and palpably able to move. The intraoral examination revealed a solitary ulcer, 2 × 5 mm in size, the base of which was yellowish-white with a clear boundary, regular border, elevated induration, hard palpation around the lesion, and pain (Wong–Baker Scale score 2).

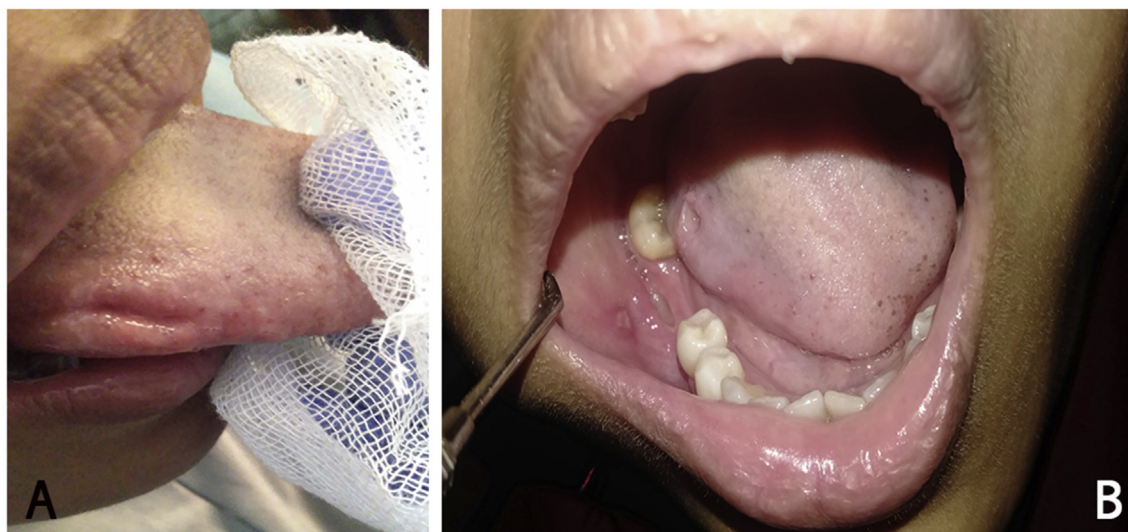

Figure 1: The oral ulcer in the lateral side of the tongue.

Table 1: The blood analysis.

Parameter	Value	Normal range
Haemoglobin	13.5	11.5–16.5
Erythrocyte	5.14	4.0–5.2
Haematocrit	43	36–46
MCV	84	80–100
MCH	26.3	26.0–34.0
MCHC	31.4	31.0–37.0
RDW	12.8	11.5–14.5
Leucocytes	8300	4400–11,300
Eosinophil	3	2–4
Basophil	1	0–1
Neutrophil segment	67	3–5
Lymphocytes	24	50–70
Monocyte	5	25–40
Thrombocyte	837,000*	150,000–450,000
SER	16	0–25
Prothrombin Time	10.7	9.7–13.1
JAK2 V617F	Positive*	Negative

*abnormal value.

Complete blood count

The patient had a history of thrombocytosis (increased platelet count of 837000/ μl), and a positive JAK2 (V617F) mutation was detected three months prior to the OSCC

diagnosis. Blood test parameters such as haemoglobin, red blood cells, erythrocyte index, white blood cells, sedimentation erythrocytes rate (SER), and prothrombin time were normal under the circumstances (Table 1). The patient had been undergoing hydroxyurea treatment twice daily with a dose of 500 mg until the day she presented. During the therapy with hydroxyurea, the patient had no intraoral complaint.

Cytological examination

Scraping was conducted on the ulcer twice. The smear contained clusters and distributions of round nucleated cells; some were enlarged with an atypical high nucleus and cytoplasm ratio, some were hyperchromic, with several prominent subnuclei, and there was reddish cytoplasm on the background of several mononuclear inflammatory cells (Figure 2). The conclusion was squamous epithelial cells with medium and severe dysplasia with inflammation.

Magnetic resonance imaging (MRI)

The patient was referred to an oncologist after the cytological examination was performed. The oncologist performed a 3T MRI of the axial section of the head with a contrast injection of gadolinium 10 cc T1+, and a sequence of visibly contrasted lesions with firm borders and regular

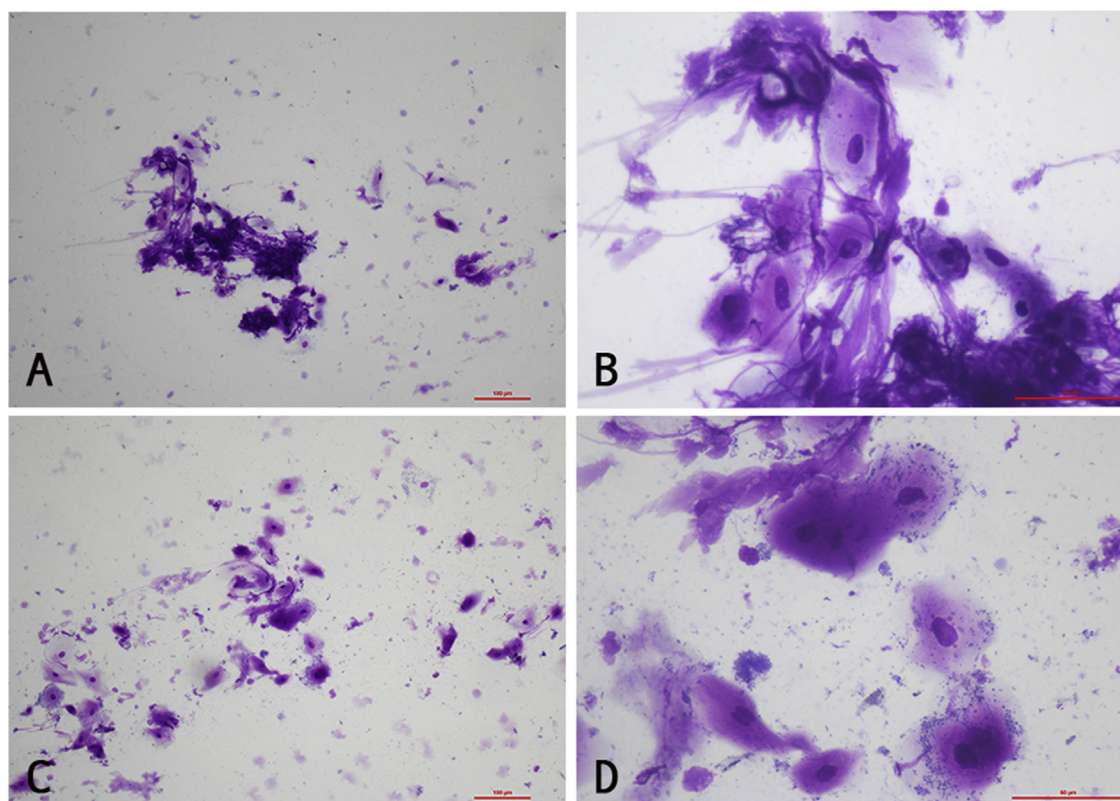


Figure 2: Epithelial cell appearance of dextral lateral tongue scraped on a light microscope. A and C with 100x magnification; B and D with 400x magnification.

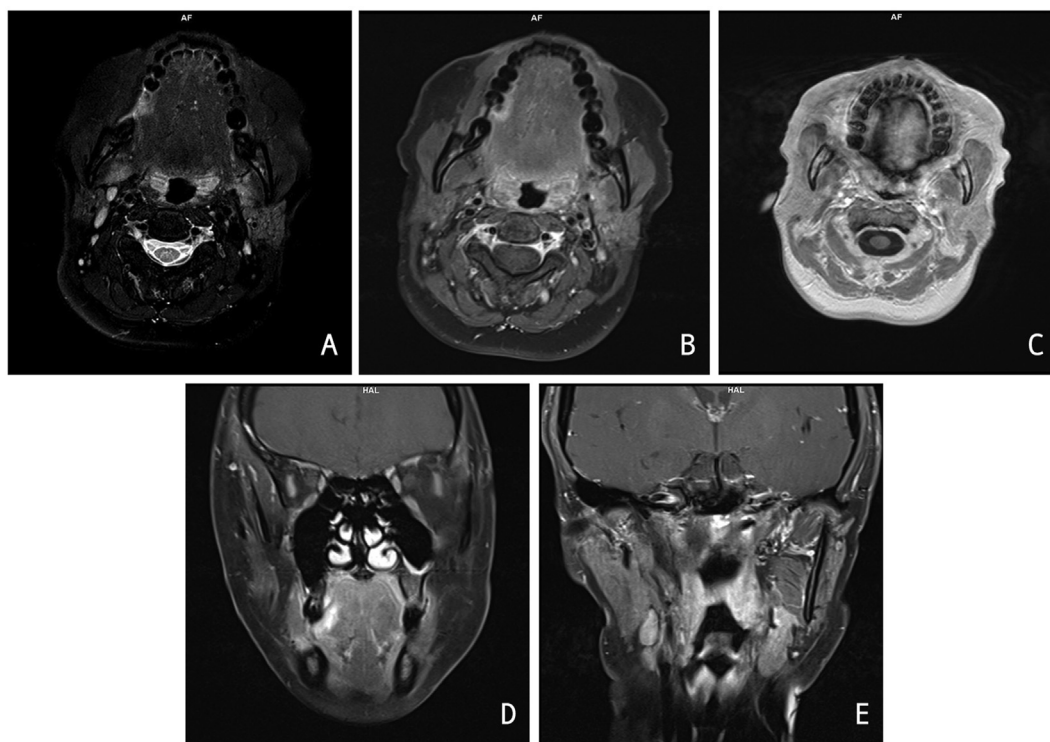


Figure 3: MRI of the head.

edges, sizes in the region of 0.70 cm \times 1.17 cm and thickness of 0.57 cm were visible in the right lingual region, and gave the impression of early malignancy (Figure 3A, B, and C).

The 3T MRI results discovered multiple enlargements in the right and left sub mandible, with the largest size in the region of around 0.8 cm in the right submandibular gland (Figure 3D and E).

Oral treatment

The treatment was an antiseptic mouthwash containing povidone iodine 1% to prevent secondary infection and occlusal adjustment to prevent the mechanical irritation from tooth 47. The patient was referred to an oncologist for a hemi glossectomy.

Discussion

The intraoral examination revealed a solitary ulcer, 2 \times 5 mm in size, with the base of the ulcer being yellowish-white with a clear boundary, regular border, elevated induration, hard palpation around the lesion, and pain. Based on clinical presentation, OSCC was suspected. A cytological examination confirmed the cell morphology, and the results of the examination were a distribution of round nucleated cells; some were enlarged with an atypical high nucleus and cytoplasm ratio, hyperchromic, with several prominent sub-nuclei, and a reddish cytoplasm on the background of several mononuclear inflammatory cells.

MRI examinations provide satisfactory accuracy for pre-operatively estimating tumour thickness and predicting the existence of occult cervical nodal metastasis. In the planning of treatments, clinicians favour MRI, since it is the preferred

modality in the evaluation and staging of oral cavity malignancies.⁷ The 3T MRI showed no visible mass expansion in the surrounding area. Multiple submandibular lymph nodes were enlarged, with the largest being 0.8 cm in size on the right submandibular lymph node and a possible initial description of malignancy.

Three months before the lesion on the tongue appeared, the patient was diagnosed with essential thrombocythemia on account of the discovery of an increased platelet count, and a positive marker for JAK2 (V617F) mutation. The increased platelet count or thrombocytosis had caused the appearance of several malignant tumours, including oesophageal, kidney, breast, stomach, uterine, prostate, and colorectal cancers. The incidence of cancer in males with thrombocytosis has increased by 11.6% and females have an increased incidence rate of 6.2%.⁸ To identify clinically significant thrombocytosis, a platelet count of $\geq 450 \times 10^9/L$ is a generally accepted value, with individual variations.⁹ In patients whose blood test results suggest thrombocytosis, a cancer diagnosis should be considered,¹⁰ even if cancer is not initially suspected.¹¹

Essential thrombocythemia is diagnosed following four main criteria: platelet count $> 450 \times 10^9/L$; proliferation of bone marrow; failure to meet the WHO criteria for BCR-ABL-1 positive chronic myeloid leukaemia, primary myelofibrosis, myelodysplastic syndrome polycythaemia vera, or other myeloid neoplasm; and the presence of JAK2, CALR, or MPL mutation.¹² Cases of oral cancer with essential thrombocythemia and positive JAK2 (V617F) mutation are rarely reported. Cases of tongue cancer with essential thrombocythemia were reported by Kondo et al. (2012)¹³ and Onozato et al. (2016).¹⁴ Hasegawa et al. (2018) reported essential thrombocythemia and mouth floor

cancer.¹⁵ Even though the platelet count and JAK2 (V617F) mutation tested positive in this patient, essential thrombocythemia was considered as the diagnosis by the doctor and the patient received hydroxyurea therapy until they presented with the ulcer.

The JAK2 (Janus kinase 2) gene is located in chromosome 9p24 and is encoded with the JAK2 protein, which is a cytoplasmic tyrosine kinase part of the JAK2 protein that has an important role in the signal transduction of various hematopoietic growth factors.¹⁶ A variety of cytokines responded to the JAK2 gene when it was activated and assisted with the survival and proliferation of the cell JAK2 (V617F) mutation, which resulted in changing the signalling process of the cell, causing the signalling process to become irregular, which gave rise to disease.¹⁷

The four members of the JAKs family are JAK1, JAK2, JAK3, and TYK2. By activating signal transducer and activator of transcription (STAT) by JAK-catalyzed phosphorylation, where STAT translocated into nucleus and transcription RNA, this process was involved in the hematopoietic process.⁴ JAK 2 mutation has mutation in the chaperone protein calreticular receptor in (CalR) megakaryocytes, resulting in STAT activation and causing excessive proliferation of platelet, called thrombocythemia. Thrombocythemia with positive JAK2 (V617F) manifests in the form of increased platelet levels.^{4,5} The platelets have a growth factor called the platelet-derived growth factor (PDGF), which is a proangiogenic factor that affects cell differentiation and increases cell survival. The PDGF signaling pathways are key regulators of angiogenesis, tumor growth hormone, and tumor survival.⁶ Increased PDGF activity has been associated with the development and progression of human malignancies including head, neck, and oral cancer.⁵

Myeloproliferative neoplasm is commonly associated with JAK2 (V617F) mutation in hematopoietic cells including polycythaemia vera, essential thrombocytopenia, and myelofibrosis.¹⁸ The presence of a high platelet count and a positive JAK2 (V617F) mutation were detected in this patient. According to the WHO classification in 2008, JAK2 positivity was accepted as one of the major indicators in the diagnosis of myeloproliferative neoplasm. The WHO reported that the JAK2 mutation frequency in essential thrombocytopenia is about 50%.³

Most of the literature has reported JAK2 mutation detection in breast, lung, and gastric tumors, but few studies have reported JAK gene mutation implication in head and neck squamous cell carcinoma. JAK and STAT activation has been implicated in cell proliferation and the survival of many cancers including head and neck squamous cell carcinoma, but this rarely occurs. In this case, there was a confirmed condition with JAK2 mutation and increased platelet number.⁵ Increased platelets will increase PDGF production and induce the occurrence of malignancies changing from epithelial squamous in the tongue with risk factors from chronic mechanical irritation.

Oral lesion therapy in this case was the prescription of antiseptic mouthwash through povidone iodine 1% to prevent secondary infection, occlusal adjustment to prevent grinding teeth, and the referral of the patient to an

oncologist for a hemi glossectomy. The occlusal adjustment for tooth 47 aimed to reduce chronic inflammation due to chronic mechanical irritation,¹⁹ which was contemplated as a possible risk factor for oral carcinogenesis.²⁰ Povidone iodine 1% was chosen as a mouthwash because it significantly reduces microbes in the oral cavity and the oropharynx.²¹ Iodophor solution that contains a water-soluble complex of iodine and polyvinylpyrrolidone (PVP) with broad microbicidal activity is called povidone iodine. Polyvinylpyrrolidone iodine (PVPI) complex in a solution gradually releases free iodine, killing eukaryotic or prokaryotic cells through the iodination of lipids and the oxidation of cytoplasmic and membrane compounds. Various microbicidal activities against bacteria, fungi, protozoa, and viruses are indicated by this agent.²²

Conclusion

Thrombocytosis and positive markers in JAK2 (V617F) mutation are suspected markers for the definition of OSCC and can be used for diagnosis. The role of the dentist here is the early detection of lesions, the maintenance of oral hygiene, and the prevention of secondary infections.

Source of funding

This research did not receive any specific grant from funding agencies in the public, commercial, or not-for-profit sectors.

Conflict of interest

The authors have no conflicts of interest to declare.

Ethical approval

The authors confirm that this study was prepared in accordance with COPE roles and regulations. Given the nature of the study, an IRB review was not required.

Consent

The author certifies that the patient had provided her informed consent and was notified of the possible use of clinical images and other clinical information in reporting in journals. The identity of the patient, such as her name and initials, will not be mentioned to maintain confidentiality.

Authors contributions

KHR collected and organised the data and writing of the manuscript; MDCS engaged in reference collection and the writing of the manuscript; DR revised the manuscript; DSE revised the manuscript; and AW provided examination and interpretation. All authors have critically reviewed and approved the final draft and are responsible for the content and similarity index of the manuscript.

References

- Gracia I, Utoro T, Supriatno S, Astuti I, Heriyanto DS, Pramono D. Epidemiologic profile of oral squamous cell carcinoma in Yogyakarta, Indonesia [Internet] **Padjajaran J Dent** 2017; 29: 32–37. Available from: <http://jurnal.unpad.ac.id/pjd/article/view/11614>.
- Gupta S, Kushwaha VS, Verma S, Khan H, Bhatt MLB, Husain N, et al. Understanding molecular markers in recurrent oral squamous cell carcinoma treated with chemoradiation. **Heliyon** 2016; 2.
- Yokus O, Gedik H. Jak-2 mutation frequency in patients with thrombocytosis. **Casp J Intern Med** 2018; 9: 189–193.
- Morris R, Kershaw NJ, Babon JJ. The molecular details of cytokine signaling via the JAK/STAT pathway. **Protein Sci** 2018; 27: 1984–2009.
- Sen M, Pollock NI, Black J, DeGrave KA, Wheeler S, Freilino ML, et al. JAK kinase inhibition abrogates STAT3 activation and head and neck squamous cell carcinoma tumor growth. **Neoplasia (United States)** 2015; 17: 256–264.
- Lin LH, Lin JS, Yang CC, Cheng HW, Chang KW, Liu CJ. Overexpression of platelet-derived growth factor and its receptor are correlated with oral tumorigenesis and poor prognosis in oral squamous cell carcinoma. **Int J Mol Sci** 2020; 21.
- Singh A, Thukral CL, Gupta K, Sood AS, Singla H, Singh K. role of MRI in evaluation of malignant lesions of tongue and oral cavity [Internet] **Pol J Radiol** 2017; 82: 92–99. Available from: <http://www.polradiol.com/abstract/index/idArt/899352>.
- Bailey SER, Ukoumunne OC, Shephard EA, Hamilton W. Clinical relevance of thrombocytosis in primary care: a prospective cohort study of cancer incidence using English electronic medical records and cancer registry data. **Br J Gen Pract** 2017; 67: e405–e413.
- Catani MV, Savini I, Tullio V, Gasperi V. The “Janus Face” of platelets in cancer [Internet] **Int J Mol Sci** 2020; 21: 788. Available from: <https://www.mdpi.com/1422-0067/21/3/788>.
- Ankus E, Price SJ, Ukoumunne OC, Hamilton W, Bailey SER. Cancer incidence in patients with a high normal platelet count: a cohort study using primary care data. **Fam Pract** 2018; 35: 671–675.
- Kmietowicz Z. Thrombocytosis is linked to increased cancer risk, study finds. **The BMJ**. 2017; 357: 691109.
- Kleman A, Singavi AK, Michaelis LC. Current challenges in the management of essential thrombocythemia. **Clin Adv Hematol Oncol** 2017; 15: 773–783.
- Kondo E, Ueda M, Yamashita T, Nakajima Y, Rin S, Fujita M. Therapeutic experience with tongue cancer in a patient who had essential thrombocythemia: a case report [Internet] **Japanese J Oral Maxillofac Surg** 2012; 58: 123–127. Available from: <http://jlc.jst.go.jp/DN/JST.JSTAGE/jjoms/58.123?lang=en&from=CrossRef&type=abstract>.
- Onozato Y, Tomioka H, Takahara N, Ohsako T, Harada H. A case of tongue cancer accompanied by essential thrombocythemia [Internet] **Japanese J Oral Maxillofac Surg** 2016; 62: 460–465. Available from: <http://jlc.jst.go.jp/DN/JST.JSTAGE/jjoms/58.123?lang=en&from=CrossRef&type=abstract>.
- Hasegawa T, Munakata K, Ogawa C, Iesaki N, Asoda S, Miyashita H, et al. A case of mouth floor cancer accompanied with essential thrombocythemia [Internet]. **J Japanese Soc Oral Oncol** 2018; 30: 159–166. Available from: https://www.jstage.jst.go.jp/article/jsot/30/4/30_159/article/-char/ja/
- de Freitas RM, de Oliveira Santos M, da Costa Maranduba CM. The JAK2 gene as a protagonist in chronic myeloproliferative neoplasms. **Rev Bras Hematol Hemoter** 2013; 35: 278–279.
- Akada H, Akada S, Hutchison RE, Sakamoto K, Wagner KU, Mohi G. Critical role of Jak2 in the maintenance and function of adult hematopoietic stem cells. **Stem Cell** 2014; 32: 1878–1889.
- Sano S, Wang Y, Yura Y, Sano M, Oshima K, Yang Y, et al. JAK2V617F-Mediated clonal hematopoiesis accelerates pathological remodeling in murine heart failure. **JACC Basic to Transl Sci** 2019; 4: 684–697.
- Choi S, Myers JN. Molecular pathogenesis of oral squamous cell carcinoma: implications for therapy. **J Dent Res** 2008; 87: 14–32.
- Piemonte E, Lazos J, Belardinelli P, Secchi D, Brunotto M, Lanfranchi-Tizeira H. Oral cancer associated with chronic mechanical irritation of the oral mucosa. **Med Oral Patol Oral Cir Bucal** 2018; 23: e151–e160.
- Surboyo M, Ernawati D, Parmadiati A. Glossitis mimicking median rhomboid glossitis induced by throat lozenges and refreshment candies. **J Int Oral Health** 2019; 11: 323–328.
- Eggers M. Infectious disease management and control with povidone iodine [Internet] **Infect Dis Ther** 2019; 8: 581–593. Available from: <https://doi.org/10.1007/s40121-019-00260-x>.

How to cite this article: Rahman KH, Surboyo MDC, Radithia D, Parmadiati AE, Wihandono A, Ernawati DS. Oral squamous cell carcinoma with essential thrombocythemia and positive JAK2 (V617F) mutation. *J Taibah Univ Med Sc* 2022;17(2):326–331.