

# 2021 - Urology Annal - Scrotal abscess due to urethral fistula in SCI patient with prolonged indwelling urinary catheter

*by M Faris*

---

**Submission date:** 04-Apr-2023 11:09AM (UTC+0800)

**Submission ID:** 2055253652

**File name:** la\_in\_SCI\_patient\_with\_prolonged\_indwelling\_urinary\_catheter.pdf (1.01M)

**Word count:** 1434

**Character count:** 7997

## Case Report

# Scrotal abscess due to urethral fistula in spinal cord injured patient with prolonged indwelling urinary catheter

Wahjoe Djatisoesanto, I. G. M. Aswin R. Ranuh<sup>1</sup>, Muhammad Faris<sup>1</sup>, Eko Agus Subagio<sup>1</sup>, Asra Al Fauzi<sup>1</sup>

Departments of Urology and <sup>1</sup>Neurosurgery, Universitas Airlangga, Dr. Soetomo General Academic Hospital, Surabaya, Indonesia

## Abstract

We report a case of scrotal abscess due to urethral fistula in a paraplegic patient with spinal cord injury. On clinical examination, an urinary catheters was placed, and the left scrotal area were swollen, redness and painless. Retrograde urethrography suggested an urethral fistula with extension spreading of contrast medium into the scrotum. The case was diagnosed as urethral fistula with scrotal abscess. The patient was successfully treated with cystostomy, scrotal incision, and pus drainage. Early detection and proper management provide opportunities to improve the outcome of this disease.

**Keywords:** Scrotal abscess, spinal cord injury, urethral fistula

**Address for correspondence:** Dr. Asra Al Fauzi, Department of Neurosurgery, Faculty of Medicine, Dr. Soetomo General Academic Hospital, Universitas Airlangga, Jl. Prof. Dr. Moestopo 6-8, Surabaya, Indonesia.  
E-mail: asrafauzi@yahoo.com

**Received:** 06.03.2020, **Accepted:** 13.10.2020, **Published:** 19.01.2021.

## INTRODUCTION

Urethral fistulas are rare in males<sup>[1,2]</sup> and can be congenital or acquired.<sup>[2,3]</sup> Scrotal abscess is one of the complications that can occur in the urethral fistula which needs proper treatment to prevent more serious complications. Patients with paraplegia may present with acquired fistula and scrotal abscess as a result of prolonged urinary catheterization.<sup>[2,3]</sup> We report a case of a paraplegic male patient following spinal cord injury presented with urethral fistula and scrotal abscess.

## CASE REPORT

A 39-year-old male paraplegic was transferred from another hospital for further treatment and rehabilitation. He had suffered a thoracolumbar spine injury after fell from great high 8 months earlier. The patient had a spinal surgery after the incident. During rehabilitation treatment in our

hospital, the patient had suffered total urinary incontinence and indwelling urinary catheterization was continued. He had totally paraplegic with sensory disturbance below umbilicus. During rehabilitation treatment, he noticed a painless scrotal mass that becoming larger. On physical examination was remarkable for scrotal mass and redness. A palpable mass was found in the left hemiscrotum near the peno-scrotal junction. A retrograde urethrography workup was done for the patient, and demonstrated a 0.5 cm tract of fistula with the interval of 7.5 cm from the external urethra orifice [Figure 1]. Patient then was diagnosed with paraplegia complicated with urethral fistula and scrotal abscess. A suprapubic cystostomy followed by abscess incision and drainage was done urgently [Figure 2]. Approximately 150 ml of pus was drained from the abscess cavity. A penrose drain was placed in the abscess. Following culture were positive for *Klebsiella pneumoniae*. Antibiotics

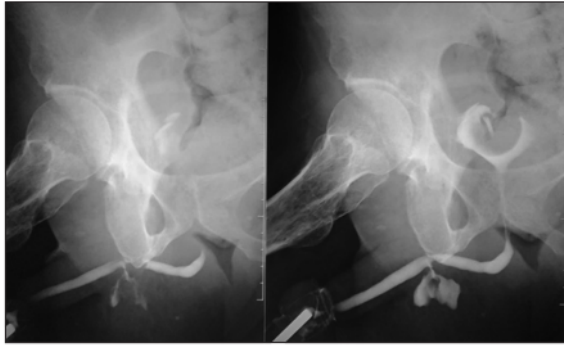
5

Access this article online	
Quick Response Code:	Website: <a href="http://www.urologyannals.com">www.urologyannals.com</a>
	DOI: <a href="https://doi.org/10.4103/UA.UA_21_20">10.4103/UA.UA_21_20</a>

1  
This is an open access journal, and articles are distributed under the terms of the Creative Commons Attribution-NonCommercial-ShareAlike 4.0 License, which allows others to remix, tweak, and build upon the work non-commercially, as long as appropriate credit is given and the new creations are licensed under the identical terms.

For reprints contact: [reprints@medknow.com](mailto:reprints@medknow.com)

**How to cite this article:** Djatisoesanto W, Ranuh IG, Faris M, Subagio EA, Al Fauzi A. Scrotal abscess due to urethral fistula in spinal cord injured patient with prolonged indwelling urinary catheter. Urol Ann 2021;13:83-5.



**Figure 1:** Retrograde urethrogram showing the urethral fistula arising from penoscrotal part and extension spreading from contrast medium into the scrotum

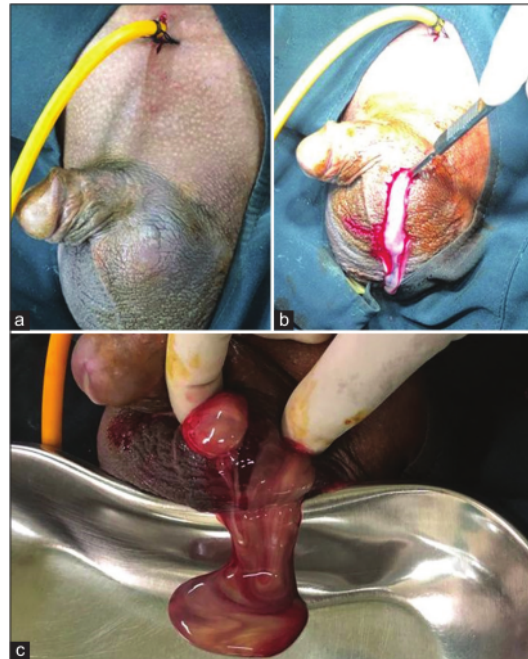were given accordingly. The patient had no other complaint following the surgery and as for the patient's neurological condition we continue for rehabilitation program. After 7 days, there was reduction of the scrotal mass and no systemic infection was detected. The patient was discharged with suprapubic catheter and referred back to the original hospital for further treatment and observation.

## DISCUSSION

Urethral fistula is a rare occurrence in men.<sup>[1,2]</sup> They may be congenital or acquired, and possibly caused include infection, inflammatory disease, neoplasm, congenital condition, trauma and iatrogenic injury.<sup>[1]</sup> Paraplegic patient has a higher risk of urethral fistula due to prolonged urinary catheterizations.<sup>[1]</sup> In a patient with paraplegia that treated with long-term catheterization, as in our case, we hypothesized that prolonged catheterization during the course of the primary disease, sensory disturbance and chronic immobilization might lead to pressure necrosis in the urethral wall and finally result in the formation of urethroscrotal fistula. With the presence of urine stasis and urinary tract infection eventually results in a scrotal abscess.

The etiology of scrotal abscesses varies greatly, some of which have been reported including epididymo-orchitis, neglected testicular torsion, spread from intra-abdominal abscess and hematogenous route of systemic infection.<sup>[4]</sup> In differential diagnosis of a scrotal mass in patient with paraplegia, especially when a urinary tract infection observed, epididymo-orchitis and urethro-scrotal abscess should be suspected.<sup>[5]</sup> Retrograde urethrography is considered a standard diagnostic technique for the morphology of the urethra and to confirm and characterize the fistula.<sup>[1,5]</sup>

The goal of the treatment is aimed to prevent urinary sepsis by medical management using appropriate antibiotics



**Figure 2:** Cystostomy followed by abscess incision and drainage. (a) Cystostomy was done for suprapubic catheter placement. (b) Scrotal incision. (c) 150 ml of pus were drained

and sometimes needs aggressive treatments. Some of the fistulas can be treated with simple procedures such as urethral catheterization and follow-up, but some of the others needs a surgical procedure.<sup>[6]</sup> In our case, in the presence of scrotal abscess complications, immediate action is needed to prevent more severe complications. We performed suprapubic cystostomy with scrotal incision to evacuate the abscess and then a penrose drain was placed in the abscess. With proper treatment, this kind of case can be handled well, as in our case.

## CONCLUSION

Long-term urinary catheterization may result in many complications which are sometimes quite severe and can cause high morbidity and mortality if not treated properly. Cases of spinal cord injury with paraplegia are a risk factor for urethral fistula. Physician who involves in managing urinary catheters should not ignore the possible serious complication such as urethral fistula with scrotal abscess. It is important to evacuate abscess and pus as soon as possible and offer quick diagnosis and treatment to prevent further complications.

## Declaration of patient consent

The authors certify that they have obtained all appropriate patient consent forms. In the form the patient (s) has/have

Djatisoesanto, *et al.*: Scrotal Abscess as complication in spinal cord injured patient

given his/her/their consent for his/her/their images and other clinical information to be reported in the journal. The patients understand that their names and initials will not be published and due efforts will be made to conceal their identity, but anonymity cannot be guaranteed.

6

#### Financial support and sponsorship

Nil.

#### Conflicts of interest

There are no conflicts of interest.

#### REFERENCES

1. Parlak S, Okay AE. Urethroscrotal fistula: A rare cause of scrotal swelling. *Pol J Radiol* 2016;81:438-40.
2. Stizzo M, Arcaniolo D, Quattrone C, Balsamo R, Terribile M, Manfredi C, *et al.* Scrotal abscess drained by iatrogenic urethral fistula in an adult diabetic male. *Case Rep Urol* 2017;2017:1-3.
3. Tokgoz O, Tokgoz H, Yildiz S. Urethral diverticulum presenting as a scrotal mass in a paraplegic male: Report of a case and review of the literature. *Cent European J Urol* 2011;64:182-3.
4. Ramareddy RS, Alladi A. Scrotal abscess: Varied etiology, associations, and management. *J Indian Assoc Pediatr Surg* 2016;21:164-8.
5. El Ammari JE, Riyach O, Absaini M, Ahallal Y, El Fassi MJ, Farib MH. Acquired urethral diverticulum in a man with paraplegia presenting with a scrotal mass: A case report. *J Med Case Rep* 2012;6:392.
6. Bozkurt A, Karabakan M, Soyurk M, Hirik E, Nuhoglu B. Urethrogluteal fistula developing secondary to the use of clean intermittent self-catheterization: First case report in the literature. *Case Rep Urol* 2014;2014:1-4.

# 2021 - Urology Annal - Scrotal abscess due to urethral fistula in SCI patient with prolonged indwelling urinary catheter

## ORIGINALITY REPORT

13%

SIMILARITY INDEX

7%

INTERNET SOURCES

10%

PUBLICATIONS

0%

STUDENT PAPERS

## PRIMARY SOURCES

- 1 Chiaravalloti, Agostino, Roberta Danieli, Cristiana Ragano Caracciolo, Laura Travascio, Maria Cantonetti, Andrea Gallamini, Manlio Guazzaroni, Antonio Orlacchio, Giovanni Simonetti, and Orazio Schillaci. "Initial Staging of Hodgkin's Disease : Role of Contrast-Enhanced 18F FDG PET/CT", *Medicine*, 2014.  
Publication 3%
- 2 [hdl.handle.net](http://hdl.handle.net)  
Internet Source 2%
- 3 Aliseydi Bozkurt, Mehmet Karabakan, Mehmet Soy Turk, Erkan Hirik, Barış Nuhoglu. "Urethrogluteal Fistula Developing Secondary to the Use of Clean Intermittent Self-Catheterization: First Case Report in the Literature", *Case Reports in Urology*, 2014  
Publication 2%
- 4 P. Ramakrishnan, A. Karimah, K. Kuntaman, A. Shukla et al. "Religious/Spiritual Characteristics of Indian and Indonesian

# Physicians and Their Acceptance of Spirituality in Health care: A Cross-Cultural Comparison", Journal of Religion and Health, 2014

Publication

5

moam.info

Internet Source

1 %

6

www.ijfmt.com

Internet Source

1 %

7

"Normal and Abnormal Scrotum", Springer Science and Business Media LLC, 2022

Publication

1 %

Exclude quotes Off

Exclude matches < 10 words

Exclude bibliography On

# 2021 - Urology Annal - Scrotal abscess due to urethral fistula in SCI patient with prolonged indwelling urinary catheter

---

GRADEMARK REPORT

---

FINAL GRADE

**/0**

GENERAL COMMENTS

**Instructor**

---

PAGE 1

---

PAGE 2

---

PAGE 3

---