

2021 - Case Rep Oncol - Long Completely Cystic Sciatic Schwannoma, A Rare Case

by M Faris

Submission date: 04-Apr-2023 11:06AM (UTC+0800)

Submission ID: 2055250605

File name: col_-_Long_Completely_Cystic_Sciatic_Schwannoma,_A_Rare_Case.pdf (758.33K)

Word count: 3179

Character count: 17203

Case Report

8

Long Completely Cystic Sciatic Schwannoma: A Rare Case

Sri Andreani Utomo^{a, b} Abdul Hafid Bajamal^c Muhammad Faris^c
Djohan Ardiansyah^d Johannes Hadi Lunardhi^e

^aDoctoral Program Health Science, Airlangga University, Surabaya, Indonesia; ^bRadiology Department, Airlangga University, Surabaya, Indonesia; ^cNeurosurgery Department, Airlangga University, Surabaya, Indonesia; ^dNeurology Department, Airlangga University, Surabaya, Indonesia; ^ePathology and Anatomy Department, Airlangga University, Surabaya, Indonesia

Keywords

Completely cystic schwannoma · Long formation · Sciatic · Schwannoma

Abstract

Schwannomas are the most common peripheral nerve sheath tumors. Benign schwannomas with malignant transformation are rarely reported. Most common schwannomas occur in the head and neck region. Sciatic schwannomas are rare, as are completely cystic schwannomas. Sciatic nerve schwannomas represent less than 1% of all schwannomas. Benign tumors in the sciatic nerve consist of 60% neurofibromas and 38% schwannomas. In general, a schwannoma induces chronic symptoms. It can be misleading, sometimes mimicking degenerative spinal pathology due to disc herniation. Schwannoma involving the sciatic nerve can be asymptomatic or may present with sciatica or neurological deficits. Most schwannomas are solid or heterogeneous tumors, and completely cystic schwannomas are rare. The differential diagnoses of nondiscogenic sciatica include lumbar disc herniation, tumor, abscess, hematoma, facet syndrome, lumbar instability, sacroiliitis, piriformis syndrome, and sciatic neuritis. We report a rare case of a long completely cystic sciatic schwannoma in the left foraminal L5–S1 zone extending to the left ischial groove with chronic sciatica that was diagnosed radiologically with a combination of conventional MRI and MR neurography and confirmed histopathologically by surgical resection. The patient previously had conservative therapy, but the complaints were not reduced. Nonsurgical therapy is considered the first choice, and surgical therapy is indicated in cases that do not respond to conservative therapy, with recurrent cysts, severe pain, or neurological deficits.

© 2021 The Author(s).
Published by S. Karger AG, Basel

Sri Andreani Utomo
Neurology Department, Medical Faculty
Airlangga University
Jl. Prof. Dr. Moestopo 6–8, Surabaya 60286 (Indonesia)
sri.andreani@fk.unair.ac.id

Introduction

12

Schwannomas are benign soft tissue tumors that arise from the sheaths of the peripheral nerves. Another name for this disorder is neurinoma or neurilemmoma [1]. It generally appears as a solid solitary tumor, but it can also be heterogeneous. Completely cystic schwannoma is a rare case [2, 3].

About 45% of schwannomas occur in the head and neck region, and the most common intracranial schwannoma is from the vestibulocochlear nerve (VIII) [4]. The incidence of schwannomas and neurofibromas is 25–30% of intraspinal masses; they may be intradural (70–75%), extradural (15%), or a combination of both (15%) [5]. Sciatic nerve schwannomas are rare [6].

We describe a rare case of long sciatic completely cystic schwannoma in left foraminal zone L5–S1, corresponding to the passage of the sciatic nerve to the left sciatic sulcus at the level of the left lateral presacral space. Symptoms in sciatic nerve schwannomas are usually associated with sciatica and are often diagnosed late [7].

14

Case Report

A 35-year-old woman presented to our center with a history of radicular pain for 8 months. Pain was radiating from the lower back to the left leg, accompanied by occasional tingling since January 2020. This complaint was getting worse, and the patient was very disturbed by August 2020. There were no autonomic disorders and weakness of the left leg muscles, and no history of trauma or injury.

Neurological examination revealed left sciatica. The leg muscle strength in flexion and extension of the left upper and lower limbs was normal. Abduction and adduction were

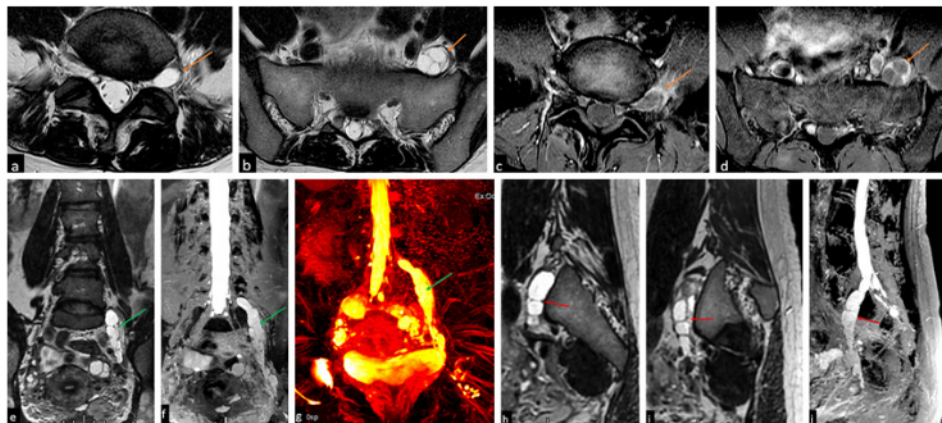


Fig. 1. Contrast-enhanced lumbosacral MRI. 3-T MRI was performed in axial T2FRFSE, sagittal T1FSE, T2FRFSE, and T2 Fat Sat, and MR neurography with 3D STIR. **a, b** Axial T2-weighted sequence demonstrating a cystic mass (orange arrows) in foraminal zone L5–S1 along the passage of the ischial nerve to the left ischial sulcus at the level of the left lateral presacral space. **c, d** Enhanced T1-weighted sequence demonstrating peripheral rim contrast enhancement (orange arrows) consistent with an encapsulated cystic mass. **e–j** Coronal T2-weighted sequence (**e, f**) and 3D STIR MR neurography (**g**) (green arrows), as well as sagittal T2-weighted sequence (**h, i**) and MR neurography (**j**) showing a long mass in the sciatic nerve in the foraminal zone and the left sulcus (red arrows) with a lesion length of ± 13.90 cm and a maximal diameter of ± 1.91 cm.

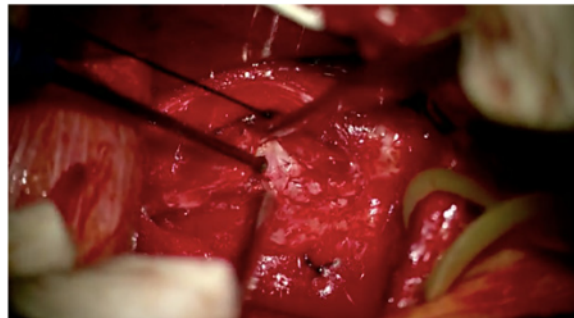


Fig. 2. During the operation, a tumor was seen originating from the sciatic nerve sheath.

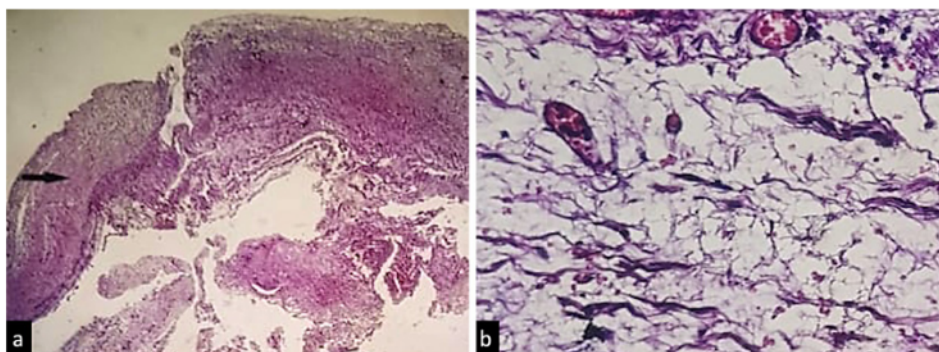


Fig. 3. **a** Histopathological examination (H&E, $\times 40$) showing a rich cell neoplasm, with bland round-to-spindle-shaped and wavy nuclei, loosely arranged in sheets; the margin of the tumor is lined by a well-defined fibrous capsule (black arrow). **b** Area of microcyst formation, suggesting schwannoma (H&E, $\times 400$).

normal. On sensory examination, there was mild hypesthesia along the left L5–S1 dermatome. The provocation test (Lasègue, Kernig, Bragard, and Sicard) was negative.

Electromyography results showed left neuropathic irritation at L4, L5, S1, and S2. The most severe was in the left L5 muscle, whereas it was light in L4 and S2. There was no evidence of denervation on electromyography.

Lumbosacral gadolinium-based contrast MRI in August 2020 showed a long solitary mass, with a completely cystic component, in the left foraminal zone of L5–S1, corresponding to the passage of the ischial nerve to the left ischial groove at the level of the left lateral presacral space with a lesion length of ± 13.90 cm and a maximal diameter of ± 1.91 cm. The mass was hypointense on the T1-weighted image and hyperintense on the T2-weighted image, and post-contrast showed a peripheral rim contrast enhancement. The mass caused severe stenosis of the left foraminal zone at the L5–S1 level. There was no attachment to the pelvic organs. We also used MR neurography, which can clarify the origin of a lesion and the course of nerves. In this case, MR neurography clearly showed the location of the mass in the sciatic nerve to the left ischial groove (Fig. 1).

The patient was on conservative therapy, but the complaints were not reduced. Two months later, the patient underwent surgery to resect the tumor and rescue the involved nerve roots (Fig. 2). A histopathological examination was performed (Fig. 3). Then, an MRI evaluation was also carried out after surgery; only a small residual cystic mass was obtained

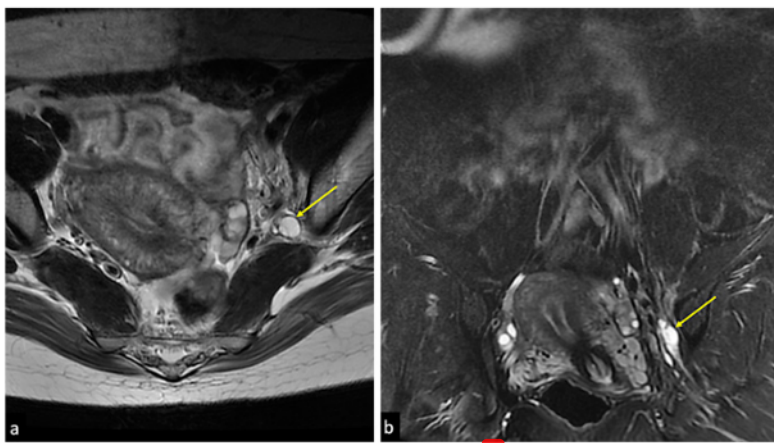


Fig. 4. **a** MRI evaluation after surgery. **b** Axial coronal T2-weighted sequence demonstrating a small residual cystic mass in the anteromedial left sciatic notch with a size of $\pm 1.03 \times 0.78 \times 2.60$ cm.

(Fig. 4). The patient recovered completely from the pain and there was no neurological deficit after surgery.

Discussion

Peripheral nerve sheath tumors are rare conditions; the nerve sheath emerges from the neuroectoderm and neural crest. Schwannomas are the most common peripheral nerve sheath tumors arising from Schwann cells [1, 5]. Predilection sites are in the head, neck, mediastinum, and retroperitoneal regions, whereas involvement of the sciatic nerve is very rare [8]. Schwannomas generally are solitary lesions (90%), but they are usually associated with neurofibromatosis type 2 (abnormality of chromosome 22), especially with multiple lesions [1].

Schwannomas most commonly occur between 20 and 50 years of age, without a gender predilection [9]. Malignant transformation of schwannoma is rare, at approximately 5% [6]. Although benign, schwannomas can undergo degenerative changes such as cystification, bleeding, calcification, and hyalinization [10]. Large cases of solitary cystic degeneration, as in our case, are relatively rare [9–11].

Schwannoma is a benign and slow-growing lesion; it generally has chronic symptoms. It can be misleading, sometimes mimicking degenerative spinal pathology due to disc herniation. It often induces symptoms of radicular pain, and sensory or motor disturbances [12]. When involving the sciatic nerve, it can be asymptomatic or may present with sciatica or neurological deficits [13].

The sciatic nerve is formed by a combination of five nerves in the lumbar and sacral spine (L4–S3). These nerve fibers are responsible for the motor and sensory functions of the lower body [14]. Disorders in this region can produce a symptom called sciatica [15]. The differential diagnoses of nondiscogenic sciatica include lumbar disc herniation, tumor, abscess, hematoma, facet syndrome, lumbar instability, sacroiliitis, piriformis syndrome, and sciatic neuritis [16]. Benign tumors in the sciatic nerve consist of neurofibromas (60%) and schwannomas (38%) [8]. Sciatic nerve schwannomas are rare, with a prevalence of less than 1% of

all schwannomas [5, 10]. However, we have not found any report of a case such as our patient, with a solitary long sciatic schwannoma with a completely cystic component arising from the foraminal zone to the ischiatic sulcus. Our patient had symptoms of radicular pain and exhibited longstanding sciatica, caused by disc herniation and compression of the nerve sheath. The tumor arose from foraminal zone L5–S1 following the passage of the sciatic nerve to the left ischial groove. MRI is the most sensitive imaging technique to identify the morphology of these lesions. MR neurography combined with conventional MRI can identify the morphology and origin of the tumor and can be used for evaluation preoperatively, so that patients can immediately undergo management therapy. This was the case where the patient was diagnosed before surgery with MRI and was successfully operated on with satisfactory results and a very small residual mass.

On MRI, schwannoma shows a signal iso- or hypointensity on T1-weighted images and mild-to-marked hyperintensity on T2-weighted images as compared to the spinal cord, with various focal areas, such as areas of hyperintensity in cystic lesions, hypointensity representing bleeding, dense cellularity, or collagen deposition. Contrast administration shows various enhancement patterns, from homogeneous enhancement to peripheral enhancement in some others. These lesions can be degenerative changes with cyst formation, calcification, hemorrhage, and hyalinization [9, 14].

MR neurography (MRN) is a relatively new imaging technique for the specific assessment of peripheral nerves. It more clearly shows the origin of a tumor on the nerve, its length, and its relationship to the surrounding nerves. The accuracy of MR neurography is greater than that of conventional MRI ($p < 0.05$) [12]. MR neurography is ideal for use in 3.0-T MRI with a protocol following graded fluid signal-sensitive sequences with fat suppression [5]. Identification of peripheral nerve disorders with MR neurography can be seen from changes in signal intensity, especially on T2-weighted images, followed by changes in nerve morphology, as well as disorganization or absence of a characteristic fascicular pattern. 3D STIR-SPACE with contrast can clearly show important information about the origin of a tumor in the nerve, the extent of its involvement, and its relationship to the adjacent nerves [11, 17]. Conventional MRI combined with MR neurography can clearly show the morphological information and the origin of the tumor [11, 17].

Long sciatic completely cystic schwannomas, as in this case, may be confused with other cystic lesions; differentiating them before surgery is important, and in this case, contrast-enhanced MRI played a vital role. The main lesion that should be considered in the differential diagnosis of this case is neurofibroma [9].

Usually, schwannomas are solitary, well-defined, encapsulated tumors located eccentrically on the nerve root and originating from the proximal nerve or spinal nerve root. On MRI, schwannoma is homogeneous on T2-weighted images. Neurofibromas are generally multiple, lack tumor capsules, originate from the distal nerve, and cause fusiform enlargement of the distal nerve. Neurofibromas are usually heterogeneous, rarely homogeneous, on T1- and T2-weighted images [1, 5]. Schwannomas can be resected without loss of nerve continuity, whereas neurofibromas are set deeply within the nerves and thus require complete resection [9].

Histologically, schwannoma shows Antoni A and B tissue, with a greater ratio of Antoni B than Antoni A tissue [9]. The characteristic pattern of Antoni A tissue is the Verocay body, while Antoni B tissue is characterized by a diffuse cellular structure with a round nucleus [18]. On MRI, the dominant type 1 tumor (Antoni A) tends to be small and homogeneous, while heterogeneous tumors (with or without cystic degeneration) tend to have a type 2 proportion (Antoni B) [1].

Nonsurgical therapy is considered the first choice in patients without neurological deficits, because spontaneous regression of the cyst may occur. This therapy consists of analgesics, physiotherapy, bracing, facet injection, and cyst aspiration. Surgical resection of cysts

is indicated in cases that do not respond to conservative therapy, as well as with recurrent cysts, severe pain, or neurological deficits [16]. In small tumors, extracapsular microscopic resection together with gentle dissection of the nerve fibers from the tumor capsule may be performed. Large tumors require intracapsular debulking first [7, 18]. In the majority of peripheral nerve schwannomas, total tumor resection without a significant neurological deficit can be achieved. Schwannomas have a good prognosis and a low incidence of recurrences, unlike neurofibromatosis [8].

Conclusions

Schwannoma is a benign neoplasm. Sciatic nerve schwannomas are rare cases and should be a warning possibility in young adults presenting with sciatica. We presented a rare case of histopathologically proven long sciatic completely cystic schwannoma of left foraminal zone L5–S1 extending to the left ischial sulcus. MR neurography combined with conventional MRI is a technique of great clinical value aiding in early diagnosis and localization before surgery, and must be confirmed histologically. Nonsurgical therapy is considered the first choice, and surgical therapy is indicated in cases that do not respond to conservative therapy, as in cases with recurrent cysts, severe pain, or neurological deficits.

Acknowledgments

Special thanks are due to Vivid Umu Varidha for completing the data.

Statement of Ethics

S.A. Utomo confirmed that ³written informed consent was obtained from the patient for the publication of the case (including publication of images).

Conflict of Interest Statement

The authors have ²no conflicts of interest to declare.

Funding Sources

We did not receive any funding.

Author Contributions

S.A. Utomo contributed to preparing the case report's design, collecting and analyzing the data on the patient, and writing and submitting the manuscript. A.H. Bajamal contributed to reviewing this article and advising on the methodology design. M. Faris contributed to reviewing this article and the surgical picture of the patient. D. Ardiansyah contributed to reviewing this article and clinical examination of the patient. J.H. Lunardhi contributed to reviewing this article and the histopathology of the patient.

7

Data Availability Statement

The case report data used to support the findings of this study are included in the article. The case report data are not under current embargo while the case findings are commercialized.

References

- 1 Crist J, Hodge JR, Frick M, Leung FP, Hsu E, Gi MT, et al. Magnetic resonance imaging appearance of schwannomas from head to toe: a pictorial review. *J Clin Imaging Sci*. 2017 Oct;7:38.
- 2 Parmar H, Patkar D, Gadani S, Shah J. Cystic lumbar nerve sheath tumours: MRI features in five patients. *Australas Radiol*. 2001;45(2):123–7.
- 3 Arnautovic K, Arnautovic A. Extramedullary intradural spinal tumors: a review of modern diagnostic and treatment options and a report of a series. *Bosn J Basic Med Sci*. 2009 Oct;9(Suppl 1):S40–5.
- 4 Crist J, Hodge JR, Frick M, Leung FP, Hsu E, Gi MT, et al. Magnetic resonance imaging appearance of schwannomas from head to toe: a pictorial review. *J Clin Imaging Sci*. 2017 Oct;7:38.
- 5 Parmar HA, Ibrahim M, Castillo M, Mukherji SK. Pictorial essay: diverse imaging features of spinal schwannomas. *J Comput Assist Tomogr*. 2007;31(3):329–34.
- 6 Rhanim A, ElZanati R, Mahfoud M, Berrada MS, El Yaacoubi M. A rare cause of chronic sciatic pain: schwannoma of the sciatic nerve. *J Clin Orthop Trauma*. 2013;4(2):89–92.
- 7 Blanchard C, Dam-Hieu P, Zagnoli F, Bellard S. Sciatalgie chronique révélant un schwannome du nerf sciatique. *Rev Med Interne*. 2008;29(9):748–50.
- 8 Naik H, Velho V. Sciatic nerve schwannoma: a rare case. *Neurol India*. 2019 Jan–Feb;67(Suppl ment):S151–3.
- 9 Jerbi Omezzine S, Zaara B, Ben Ali M, Abid F, Sassi N, Hamza HA. A rare cause of non discal sciatica: schwannoma of the sciatic nerve. *Orthop Traumatol Surg Res*. 2009;95(7):543–6.
- 10 Kasliwal MK, Kale SS, Sharma BS, Suri V. Totally cystic intradural extramedullary schwannoma. *Turk Neurosurg*. 2008;18(4):404–6.
- 11 Himmiche M, Benzagmout M, Alami B, Benabdellah IS, Chakour K, Chaoui ME. Giant cystic schwannoma of the cauda equina. *Ann Afr Med*. 2019 Jul–Sep;18(3):180–3.
- 12 Zhai H, Lv Y, Kong X, Liu X, Liu D. Magnetic resonance neurography appearance and diagnostic evaluation of peripheral nerve sheath tumors. *Sci Rep*. 2019;9(1):1–8.
- 13 Mansukhani SA, Butala RR, Shetty SH, Khedekar RG. Sciatic nerve schwannoma: a case report. *J Orthop Surg (Hong Kong)*. 2015;23(2):259–61.
- 14 Cejas C, Aguilar M, Falcón L, Caneo N, Acuña MC. Neurografía por resonancia magnética de alta resolución (3Tesla) del nervio ciático. *Radiologia*. 2013;55(3):195–202.
- 15 Rana Magar N, Hui M, Min Z, Ming Z. Spinal cystic schwannoma: an MRI evaluation. *J Coll Physicians Surg Pak*. 2014 Feb;24:145–7.
- 16 Al-Habsi S, Al-Ghafri K, Elsaïd M, Al-Subhi A, Al-Kindi H, Al-Baccouche K. Lumbar facet cyst as a rare cause of l5 radiculopathy: a case report. *Case Reports Orthop Res*. 2020;3:34–41.
- 17 Agnollitto PM, Chu MWK, Simão MN, Nogueira-Barbosa MH. Sciatic neuropathy: findings on magnetic resonance neurography. *Radiol Bras*. 2017;50(3):190–6.
- 18 Wippold FJ, Lubner M, Perrin RJ, Lämmle M, Perry A. Neuropathology for the neuroradiologist: Antoni A and Antoni B tissue patterns. *AJNR Am J Neuroradiol*. 2007;28(9):1633–8.

2021 - Case Rep Oncol - Long Completely Cystic Sciatic Schwannoma, A Rare Case

ORIGINALITY REPORT

12%

SIMILARITY INDEX

8%

INTERNET SOURCES

11%

PUBLICATIONS

0%

STUDENT PAPERS

PRIMARY SOURCES

1	Jamie Crist, Jacob R Hodge, Matthew Frick, Fiona P Leung, Eugene Hsu, Ming Tye Gi, Sudhakar K Venkatesh. "Magnetic Resonance Imaging Appearance of Schwannomas from Head to Toe: A Pictorial Review", Journal of Clinical Imaging Science, 2017 Publication	2%
2	scielo.pt Internet Source	2%
3	f6publishing.blob.core.windows.net Internet Source	1%
4	"Diagnostic Assessment and Treatment of Peripheral Nerve Tumors", Springer Science and Business Media LLC, 2021 Publication	1%
5	www.scielo.br Internet Source	1%
6	clinicalgate.com Internet Source	1%

7	www.hindawi.com Internet Source	1 %
8	annalsafrmed.org Internet Source	1 %
9	Antonio Meola, Scott Soltys, Adam Schmitt, Peter C. Gerszten, Steven D. Chang. "Stereotactic Radiosurgery for Benign Spinal Tumors", Neurosurgery Clinics of North America, 2020 Publication	<1 %
10	www.pharmahealthsciences.net Internet Source	<1 %
11	FDI World Dental Federation. "AWDC 2015 – Abstract book - Tuesday, 22 September 2015 - FREE COMMUNICATION SESSIONS 01–20 and POSTER SESSIONS 01–16", International Dental Journal, 2015 Publication	<1 %
12	mayoclinic.pure.elsevier.com Internet Source	<1 %
13	synapse.koreamed.org Internet Source	<1 %
14	www.eajm.org Internet Source	<1 %

Exclude quotes Off

Exclude matches < 10 words

Exclude bibliography On

2021 - Case Rep Oncol - Long Completely Cystic Sciatic Schwannoma, A Rare Case

GRADEMARK REPORT

FINAL GRADE

/0

GENERAL COMMENTS

Instructor

PAGE 1

PAGE 2

PAGE 3

PAGE 4

PAGE 5

PAGE 6

PAGE 7
