

# 2022 - IJSCR - Lumbar disc herniation in a 15 year old girl

*by M Faris*

---

**Submission date:** 04-Apr-2023 11:14AM (UTC+0800)

**Submission ID:** 2055259736

**File name:** 2022\_-\_IJSCR\_-\_Lumbar\_disc\_herniation\_in\_a\_15\_year\_old\_girl.pdf (598.49K)

**Word count:** 2545

**Character count:** 14146



ELSEVIER

3  
Contents lists available at ScienceDirect

International Journal of Surgery Case Reports

journal homepage: [www.elsevier.com/locate/ijscr](http://www.elsevier.com/locate/ijscr)6  
Case reportLumbar disc herniation in a 15-year-old girl: A case report<sup>☆</sup>

Fachriy Balafit<sup>a</sup>, Muhammad Faris<sup>a, b, \*, \*\*</sup>, Eko Agus Subagio<sup>a</sup>, Abdul Hafid Bajamal<sup>a</sup>,  
Annie Kusumadewi<sup>c</sup>

<sup>a</sup> Department of Neurosurgery, Universitas Airlangga – Dr. Soetomo General Academic Hospital, Surabaya, East Java, Indonesia<sup>b</sup> Department of Neurosurgery, Adi Husada Undaan Hospital, Surabaya, East Java, Indonesia<sup>c</sup> Department of Pediatrics, Adi Husada Undaan Hospital, Surabaya, East Java, Indonesia

## ARTICLE INFO

## Keywords:

Lumbar disc herniation  
Pediatric  
Surgery  
Case report

## ABSTRACT

**Introduction:** Lumbar disc herniation (LDH) is uncommon in the pediatric population. The lumbar spine biodynamics and architecture change with age, with adults being more susceptible to LDH than children. When conservative treatment fails for pediatric LDH, surgery may be considered. We described an unusual instance of pediatric lumbar disc herniation that was successfully treated with microdiscectomy.

**Case presentation:** A 15-year-old patient presented with back discomfort and pain in her left leg that had been deteriorating for over 4 years. Conservative treatment with nonsteroidal anti-inflammatory medications and piriformis injection is ineffective. An MRI of her lumbosacral spine revealed that the left L4 root was compressed by a disc herniation at the L4/L5 level. A microdiscectomy was performed on the patient. Within 48 h of surgery, the patient was released home with significant alleviation in sciatic discomfort.

**Discussion:** In the pathogenesis of LDH, trauma and a sedentary lifestyle are important factors. Back pain and radiating pain are typical LDH symptoms. If conservative treatment does not result in a positive outcome, the microdiscectomy procedure is the surgical approach of choice. Long-term outcomes have demonstrated the efficacy and safety of this procedure.

**Conclusion:** Every child who presents with back pain or radiculopathy should undergo a thorough evaluation for LDH especially if they have a high body mass index (BMI) or a history of trauma. Careful patient selection and preoperative evaluation result in extremely excellent surgery outcomes in pediatric LDH.

## 1. Introduction

Herniation of lumbar intervertebral disc<sup>8</sup> is a common lumbar spine disorder that is frequently encountered in the adult population. On the other hand, lumbar disc herniation (LDH) rarely occurs in the pediatric population. The changes in lumbar spine biodynamics and anatomy are age-related, where adults are at greater risk for LDH than pediatrics [1]. It is unclear whether findings in adult LDH can be compared to those in pediatric patients, but they may be related to one another and have different clinical and natural histories [2]. Additionally, pediatric LDH is still poorly understood [3].

Due to the low prevalence of pediatric LDH cases, pediatric patients with LDH are frequently misdiagnosed [2]. The incidence of pediatric LDH accounts for 0.4–15.4 % of surgically treated patients with LDH [4].

In pediatric LDH without neurological deficit, a trial of conservative treatment is typically advised as the appropriate initial management before surgery. Surgical management may be indicated for pediatric LDH that fails with conservative treatment [2,3]. We reported an uncommon case of lumbar disc herniation in pediatrics, which was successfully treated with microdiscectomy. This case report has been reported in line with the SCARE Criteria [5].

## 2. Case presentation

A 15-year-old female patient was brought by her parents to the neurosurgery outpatient clinic in Adi Husada Undaan Hospital, Surabaya, East Java, Indonesia on January 2022 due to back discomfort and pain in her left leg for over 4 years worsening over the last 6 months. The

**Abbreviations:** MRI, Magnetic resonance imaging; LDH, Lumbar Disc Herniation.

<sup>☆</sup> Submission statement: This manuscript is original and has not been submitted elsewhere in part or in whole.

<sup>\*</sup> Corresponding author at: Department of Neurosurgery, Airlangga University – Dr. Soetomo General Academic Hospital, Surabaya, East Java, Indonesia.

<sup>\*\*</sup> Corresponding author at: Department of Neurosurgery, Adi Husada Undaan Hospital, Surabaya, East Java, Indonesia.

E-mail address: [mfarisms@fk.unair.ac.id](mailto:mfarisms@fk.unair.ac.id) (M. Faris).

<sup>7</sup> <https://doi.org/10.1016/j.ijscr.2022.107560>

Received 16 July 2022; Received in revised form 23 August 2022; Accepted 23 August 2022

Available online 27 August 2022

2210-2612/© 2022 The Authors. Published by Elsevier Ltd on behalf of IJS Publishing Group Ltd. This is an open access article under the CC BY-NC-ND license (<http://creativecommons.org/licenses/by-nc-nd/4.0/>).

patient frequently carries heavy loads and experiences repetitive trauma. There was no improvement in her symptoms despite treatment with nonsteroidal anti-inflammatory drugs (NSAIDs). The patient consumed Ibuprofen 400 mg three times a day (Farsifen®, Ifars Pharmaceutical Laboratories, Central Java, Indonesia). She also had piriformis injection of Triamcinolone (10 mg/mL) 2 mL (Trilac®, Novell Pharmaceutical Labs, Jakarta, Indonesia) in the past. A physical examination was then performed, and it revealed that the left leg had tested positive for straight-leg raising. There was no evidence of hypoesthesia, bladder dysfunction, or bowel dysfunction, and the motor function was affected. She had a body mass index of 27.3 kg/m<sup>2</sup> (overweight). Magnetic resonance imaging (MRI) of her lumbosacral spine revealed a disc herniation at the L4/L5 level, compressing the left L4 root, as shown in (Fig. 1). The patient was diagnosed with LDH at the L4/L5 level and prepared for surgery. Full laboratory investigations showed normal results. The surgery was done by a consultant spine surgeon in our institution. The open microdiscectomy method was then chosen because it is minimally invasive, has good visualization, and carries a low risk of complications.

The patient underwent a microdiscectomy. Prolapsed part of the L4/L5 intervertebral disc was gently removed from the intervertebral foramen and spinal canal. Some free parts of the degenerated disc were removed through the annulus fibrosus. There were no complications during surgery. After surgery, the patient made significant progress. Within 48 h after surgery, the patient was sent home with a marked reduction in sciatic pain. Following discharge, the patient returned for follow-up visits at regular intervals (every 1 month) to the neurosurgery unit. At each patient visit, a clinical and neurological examination was performed. The patient showed good clinical improvement as well as remarkable motor function. No signs of neurological deficit or sciatic pain in her left leg after a three-month follow-up period.

### 3. Discussion

Lumbar disc herniation is a very rare disorder in pediatrics, and it accounts for about 0.5–6.8 % of entire patients hospitalized for LDH, with a higher incidence in Japanese children [6–8]. This study itself is the first pediatric LDH case report in Indonesia. Theoretically, there are

typically no degenerative changes in pediatric LDH. Trauma, particularly from sports or self-reported incidents like heavy lifting, is anticipated to be a trigger for LDH in children and adolescents [3]. The incidence of trauma in pediatric patients with herniated discs ranges from 36 to 100 % [9]. Genetic factors and vertebral abnormalities such as scoliosis are also associated with LDH in children and adolescents [10]. Compared to age and gender, this patient's body mass index of 27.3 indicates that she was overweight, which is a risk factor for the development of lumbar disc disease [11].

One of the factors that contribute to LDH in this patient is axial overloading, which is typically brought on by sedentary and seated lifestyle [12]. Recent research on caprine intervertebral discs revealed that, when compared to physiological loading and dynamic overloading, static overloading particularly increased the risk of posterior herniation [12,13]. Additionally, studies have demonstrated that being overweight can hasten the metabolism, add to the load on the lumbar disc, and accelerate degenerative processes [14].

Cahill et al. reported that 95 % of LDH in children complained of pain radiating down the leg and 85 % complained of back pain [15]. Bladder and bowel dysfunction is rare complaints. The most common operated segment in pediatric LDH is L4–5, accounting for 45 % of surgeries, followed by L5–S1 (36%), and L3–4 (7 %). The time from symptom onset to surgical treatment in pediatric LDH is often delayed. This extended period of time is the result of both the delayed diagnosis and the time required to try conservative treatment, which should be the initial course of action [3]. This initial misdiagnosis is a reflection of the low prevalence of LDH in children and the frequent exclusion of radiculopathy from the initial differential diagnosis of leg pain [15]. Patients should undergo herniated disc surgery if they have neurological deficits or unremitting pain [16]. Spinal fusion is not recommended for children, thus a minimally invasive approach should be chosen to avoid complications of spinal growth in children [3,15]. Importantly, this case report indicates that microdiscectomy is an effective and safe procedure for pediatric patients. The prolapsed part of the L4/L5 intervertebral disc was gently removed from the intervertebral foramen and spinal canal. Some free parts of the degenerated disc were removed through the annulus fibrosus. The patient was discharged home within 48 h after surgery.

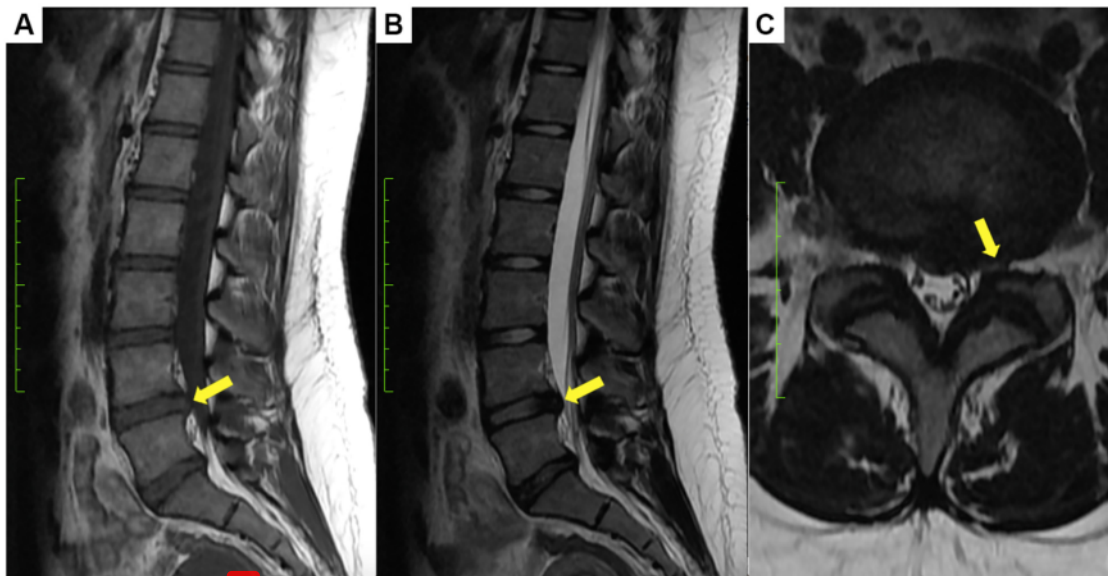


Fig. 1. A Sagittal T1, B sagittal T2, and C axial T2 show the disc herniation compressing the left L4 root.

In pediatric patients with symptomatic lumbar disc disease for whom conservative management has failed, microdiscectomy is a safe and effective treatment for long-term pain relief and return to daily activities [16]. According to studies, the microdiscectomy procedure has a good outlook, with an overall success rate of 79–84 % over the following 20 years [17]. To further improve the quality of life, a healthy lifestyle is required, including regular exercise, a balanced diet, and regular follow-up [14]. In this instance, the patient was instructed to follow up every month for three months, and there was a clinically significant improvement in our patient.

The patient feels that each choice made by the clinician will improve their quality of life. The doctor has given the patient's necessary treatment. The patient and family continue to have high expectations for our team because they are appreciative of the treatment's initial success.

#### 4. Conclusion

This is the first pediatric LDH case report in Indonesia. Lumbar disc herniation is often not considered in the pediatric age group. Diagnosis is often delayed due to lack of experience in dealing with this condition in children. Any pediatric patient who presents with back pain or radiculopathy must be thoroughly investigated to avoid misdiagnosis, especially in those with a high body mass index or history of trauma. The surgical technique with open microdiscectomy has been shown to provide good clinical effectiveness for pediatric LDH cases. During the time of follow-up, there were no issues with the surgery itself or its aftermath. LDH should be taken into account in all age groups so that a more accurate diagnosis and course of treatment can be followed to enhance the patient's quality of life.

#### Provenance and peer review

Not commissioned, externally peer-reviewed.

#### Funding

None.

#### Ethical approval

All ethical principles were considered in conducting this case report. All patient information kept confidential.

#### Consent

Written informed consent was obtained from the patient for publication of this case report and accompanying images. A copy of the written consent is available for review by the Editor-in-Chief of this journal on request.

#### Author contribution

Muhammad Faris - data collection, manuscript writing, critically revising article, reviewed final version of article

Fachriy Balafif - study concept, patient contribution, revising article, reviewed final version of article, study oversight, creation of figures

Eko Agus Subagio - data collection, critically revising article, reviewed final version of article

Abdul Hafid Bajamal - study concept, patient contribution, revising

article, reviewed final version of article

#### Registration of research studies

Not applicable.

#### Guarantor

Dr. Muhammad Faris.

#### 10

#### Declaration of competing interest

The authors declare that they have no conflict of interest.

#### References

- [1] S. Ozgen, D. Konya, O. Toktas, A. Dağçınar, M. Ozek, Lumbar disc herniation in adolescence, *Pediatr. Neurosurg.* 43 (2007) 77–81, <https://doi.org/10.1159/000098377>.
- [2] A.L.B. Raghu, A. Wiggins, J. Kandasamy, Surgical management of lumbar disc herniation in children and adolescents, *Clin. Neurol. Neurosurg.* 185 (2019), 105486, <https://doi.org/10.1016/j.clineuro.2019.105486>.
- [3] L. Dang, Z. Liu, A review of current treatment for lumbar disc herniation in children and adolescents, *Eur. Spine J.* 19 (2010) 205–214, <https://doi.org/10.1007/s00586-009-1202-7>.
- [4] W.F. Lavelle, A. Bianco, R. Mason, R.R. Betz, S.A. Albanese, Pediatric disk herniation, *J. Am. Acad. Orthop. Surg.* 19 (2011) 649–656, <https://doi.org/10.5435/00124635-201111000-00001>.
- [5] R. Agha, T. Franchy, C. Sohrabi, G. Mathew, for the SCARE Group, The SCARE 2020 guideline: updating consensus CAsE REport (SCARE) guidelines, *Int. J. Surg.* 84 (2020) 226–230, <https://doi.org/10.1016/j.itsm.2020.101607%0A>, doi: 10.1016/j.ijso.2020.02.034%0Ahttps://onlinelibrary.wiley.com/doi/abs/10.1111/cjag.12228%0Adoi:10.1016/j.jssci.2020.104773%0Adoi:10.1016/j.jinf.2020.04.011%0Ahttps://doi.o.
- [6] M. Luukkonen, K. Partanen, M. Vapalahti, Lumbar disc herniations in children: a long-term clinical and magnetic resonance imaging follow-up study, *Br. J. Neurosurg.* 11 (1997) 280–285, <https://doi.org/10.1080/02688699746041>.
- [7] A. Kurihara, O. Kataoka, Lumbar disc herniation in children and adolescents. A review of 70 operated cases and their minimum 5-year follow-up studies 5 (1980) 443–451.
- [8] J.F. Martínez-Lage, V. Fernández Cornejo, F. López, M. Poza, Lumbar disc herniation in early childhood: case report and literature review, *Childs Nerv. Syst.* 19 (2003) 258–260, <https://doi.org/10.1007/s00381-003-0720-6>.
- [9] J.F. Martínez-Lage, V. Fernández Cornejo, F. López, M. Poza, Lumbar disc herniation in early childhood: case report and literature review, *Childs Nerv. Syst.* 19 (2003) 258–260, <https://doi.org/10.1007/s00381-003-0720-6>.
- [10] K. Haddadi, Pediatric lumbar disc herniation: a review of manifestations, diagnosis and management, *J. Pediatr. Rev.* 4 (2016), <https://doi.org/10.11795/jpr-4725>.
- [11] X. Xu, X. Li, W. Wu, Association between overweight or obesity and lumbar disk diseases: a meta-analysis, *J. Spinal Disord. Tech.* 28 (2015) 370–376, <https://doi.org/10.1097/BSD.0000000000000235>.
- [12] R.M. Amin, N.S. Andrade, B.J. Neuman, Lumbar disc herniation, *Curr. Rev. Musculoskelet. Med.* 10 (2017) 507–516, <https://doi.org/10.1007/s12178-017-9441-4>.
- [13] G.D. Schroeder, C.A. Guyre, A.R. Vaccaro, The epidemiology and pathophysiology of lumbar disc herniations, *Semin. Spine Surg.* 28 (2016) 2–7, <https://doi.org/10.1053/j.semss.2015.08.003>.
- [14] Y. Li, J.-J. Shi, J. Ren, H.-S. Guan, Y.-P. Gao, F. Zhao, J. Sun, Relationship between obesity and lumbar disc herniation in adolescents, *Zhongguo Gu Shang* 33 (2020) 725–729.
- [15] K.S. Cahill, I. Dunn, T. Gunnarsson, M.R. Proctor, Lumbar microdiscectomy in pediatric patients: a large single-institution series, *J. Neurosurg. Spine* 12 (2010) 165–170, <https://doi.org/10.3171/2009.9.SPINE09756>.
- [16] M. McAvoy, Heather J. McCrea, V. Chavakula, H. Choi, W.L. Bi, R.A. Mekary, S. Stone, M.R. Proctor, Long-term outcomes of lumbar microdiscectomy in the pediatric population: a large single-institution case series, *J. Neurosurg. Pediatr.* 24 (2019) 549–557.
- [17] G.J. Dohrmann, N. Mansour, Long-term results of various operations for lumbar disc herniation: analysis of over 39,000 patients, *Med. Princ. Pract.* 24 (2015) 285–290, <https://doi.org/10.1159/000375499>.

# 2022 - IJSCR - Lumbar disc herniation in a 15 year old girl

## ORIGINALITY REPORT

17%

SIMILARITY INDEX

11%

INTERNET SOURCES

15%

PUBLICATIONS

0%

STUDENT PAPERS

## PRIMARY SOURCES

1	Kevin S. Cahill. "Lumbar microdiscectomy in pediatric patients: a large single-institution series : Presented at the 2009 Joint Spine Section MeetingClinical article", Journal of Neurosurgery Spine, 02/2010 Publication	3%
2	aymane jbilou, Younes Aggouri, Anass Ahallat, Said Aitlaalim. "Perforated voluminous duodenal Burkitt lymphoma causing severe peritonitis, a case report", Research Square Platform LLC, 2023 Publication	2%
3	meindoctor.com Internet Source	2%
4	geb.uni-giessen.de Internet Source	2%
5	surgicalneurologyint.com Internet Source	2%
6	www.scilit.net Internet Source	1%

7	<a href="http://openaccess.city.ac.uk">openaccess.city.ac.uk</a> Internet Source	1 %
8	Julian Cahill, Geoffrey Frost, Guirish A. Solanki. "Paediatric lumbar disc herniation in the very young: A case-based update", Child's Nervous System, 2011 Publication	1 %
9	<a href="http://www.semanticscholar.org">www.semanticscholar.org</a> Internet Source	1 %
10	<a href="http://www.gavinpublishers.com">www.gavinpublishers.com</a> Internet Source	1 %
11	<a href="http://www.bmj.com">www.bmj.com</a> Internet Source	1 %
12	<a href="http://www.sciencegate.app">www.sciencegate.app</a> Internet Source	1 %
13	Paolo Tortori-Donati. "Spinal Trauma", Pediatric Neuroradiology, 2005 Publication	<1 %
14	<a href="http://www.psmid.org.ph">www.psmid.org.ph</a> Internet Source	<1 %

Exclude quotes Off

Exclude matches < 10 words

Exclude bibliography On

# 2022 - IJSCR - Lumbar disc herniation in a 15 year old girl

---

GRADEMARK REPORT

---

FINAL GRADE

**/0**

GENERAL COMMENTS

**Instructor**

---

PAGE 1

---

PAGE 2

---

PAGE 3

---