
A manuscript number has been assigned: IJSCASEREPORTS-D-22-01040

1 pesan

International Journal of Surgery Case Reports <em@editorialmanager.com>

16 Agustus 2022 pukul 23.34

Balas Ke: International Journal of Surgery Case Reports <ijscasereports@elsevier.com>

Kepada: Muhammad Faris <mfarisns@fk.unair.ac.id>

Ms. Ref. No.: IJSCASEREPORTS-D-22-01040

Title: One-stage Anterior Approach for Long-segment Subaxial Cervical Spondylitis Tuberculosis: A Case Report
International Journal of Surgery Case Reports

Dear Dr. Faris,

Your submission "One-stage Anterior Approach for Long-segment Subaxial Cervical Spondylitis Tuberculosis: A Case Report" has been assigned manuscript number IJSCASEREPORTS-D-22-01040.

To track the status of your paper, please do the following:

1. Go to this URL: <https://www.editorialmanager.com/ijscasereports/>
2. Enter your login details
3. Click [Author Login]
This takes you to the Author Main Menu.
4. Click [Submissions Being Processed]

Thank you for submitting your work to International Journal of Surgery Case Reports.

Kind regards,

Maliha Agha
Assistant Managing and Executive Editor
International Journal of Surgery Case Reports

In compliance with data protection regulations, you may request that we remove your personal registration details at any time. (Use the following URL: <https://www.editorialmanager.com/ijscasereports/login.asp?a=r>). Please contact the publication office if you have any questions.

Your submission

2 pesan

International Journal of Surgery Case Reports <em@editorialmanager.com> 9 September 2022 pukul 19.24
Balas Ke: International Journal of Surgery Case Reports <ijscasereports@elsevier.com>
Kepada: Muhammad Faris <mfarisns@fk.unair.ac.id>

Ms. Ref. No.: IJSCASEREPORTS-D-22-01040

Title: One-stage Anterior Approach for Long-segment Subaxial Cervical Spondylitis Tuberculosis: A Case Report
International Journal of Surgery Case Reports

Dear Dr. Faris,

Reviewers have now commented on your paper. You will see that they are advising that you revise your manuscript. If you are prepared to undertake the work required, we would be pleased to reconsider our decision.

For your guidance, reviewers' comments are appended below.

If you decide to revise the work, please submit a list of changes or a rebuttal against each point which is being raised when you submit the revised manuscript.

To submit a revision, please go to <https://www.editorialmanager.com/ijscasereports/> and login as an Author.

Your username is: mfarisns

<https://www.editorialmanager.com/ijscasereports/l.asp?i=740669&l=SJDQ8T41>

On your Main Menu page is a folder entitled "Submissions Needing Revision". You will find your submission record there.

Finally, we would appreciate if you could submit your revised paper by Sep 19, 2022.

Yours sincerely,

The Editors
International Journal of Surgery Case Reports

Have you considered publishing a protocol for your next study? You can now publish your study protocol with IJS Protocols, our pioneering new journal for surgical protocols, visit <http://www.ijsprotocols.com> for more details.

Reviewers' comments:

Managing Editor

Please can you make the following changes/checks:

1. Please ensure your case report is compliant with the SCARE Guidelines 2020: <http://www.scareguideline.com> and submit a completed SCARE 2020 checklist.

Please pay particular attention to the following criteria which are often missed:

- Who performed the procedure? (item 9d)
- patient perspective (item 12)
- Drug history, family history including any relevant genetic information, and psychosocial history (item 5d)
- Where relevant - intervention adherence and tolerability (item 10c)
- Post-intervention considerations (item 9f)

2. Please also ensure you state that the work has been reported in line with the SCARE 2020 criteria:

Agha RA, Franchi T, Sohrabi C, Mathew G, for the SCARE Group. The SCARE 2020 Guideline: Updating Consensus Surgical CAse REport (SCARE) Guidelines, International Journal of Surgery 2020;84:226-230.

3. Please cite the SCARE 2020 paper above in your text in the methods section and the add the reference to your references section.

4. Please ensure you submit a structured abstract with sub-headings as follows:
Introduction and importance, Case presentation, clinical Discussion, Conclusion

5. Can you also please ensure you go through the entire manuscript and check the spelling, grammar and syntax and ensure the language is concise. If you need our author support services, you can access them here:

<https://www.ijspg.com/services/author-support>

6. Please be very clear about what this adds to the existing literature and clearly detail learning points.

7. Please ensure you submit your work with a Research Registry unique identifying number (UIN) if its first in man i.e. the first time a new device or surgical technique is performed: www.researchregistry.com – it can't progress without being registered. Please ensure you also state your registration UIN in your methods section and reference it including a hyperlink to it if registration is appropriate.

8. If you haven't already, please include your "highlights" which are 3-5 bullet points summarising the novel aspects and/or learning points (maximum 85 characters, including spaces, per bullet point).

9. The consent statement in the author form is not suitable. We need a statement like this:

Written informed consent was obtained from the patient for publication of this case report and accompanying images. A copy of the written consent is available for review by the Editor-in-Chief of this journal on request.

Please see consent section in instructions to authors for further information.

10. Please ensure any images/figures/photos are suitably anonymised with no patient information or means of identifying the patient.

11. Please add a Guarantor on the Author form, if you haven't already.

The guarantor is that individual who accepts full responsibility for the work and/or the conduct of the study, had access to the data, and controlled the decision to publish.

12. Please add the following statement above references:

Provenance and peer review

Not commissioned, externally peer-reviewed

13. Above references, please state the following headings with your response (if something doesn't apply, say N/a or none or none declared):

- conflicts of interest
- sources of funding
- ethical approval

- consent
- author contribution
- research registration (for case reports detailing a new surgical technique or new equipment/technology)
- Guarantor

14. Author Form

Please ensure that you have completed and uploaded the correct author form for IJS Case Reports:

https://www.elsevier.com/__data/promis_misc/2020_IJSCR_Author_Disclosure_Form.docx.

Please also make sure that you complete each section of the form.

Or for AMS:

https://www.elsevier.com/__data/promis_misc/2020_AMSU_Author_Disclosure_Form.docx

Reviewer #1: - The introduction is well-written.

- The follow-up is lacking.
- The word Pott's disease is not included in the text.
- Where are the pictures of the radiographies and the surgical field?
-

Reviewer #2: 1. What is new in this case, justifying publication 2

2. Type of neck pain and details not given.
3. Muscle Power, Sensory loss and other Neurological signs not given.
4. Why pain was in lower limb when pathology in Cervical area?
5. What is radical surgery?
6. Pus sent for pathologic and culture not correct.
7. Conclusion is not properly written and presented.
8. No follow up given?
9. No mention about Anti TB Drugs.
10. Only few Reference are relevant to the topic
11. Reference mostly incomplete.
12. Marks - 40%
13. Not Accepted.

Reviewer #3: * Figures are missing in the article and therefore figures must be loaded when submitting

- * Highlight needs to be rewritten with the novelty of the study and contributions.
- * Abstract needs to be rewritten without grammatical and spelling errors.
- * This paper needs to be edited.
- * Missing references should be added in overall the article such as 'the recent publications regarding the anterior approach for cervical spondylitis....' The recent studies must be cited.
- * Line numbers should be added.
- * New and more updated references should be added.
- * Article writing rules must be followed.

In compliance with data protection regulations, you may request that we remove your personal registration details at any time. (Use the following URL: <https://www.editorialmanager.com/ijscasereports/login.asp?a=r>). Please contact the publication office if you have any questions.



muhammad faris <mfarisns@fk.unair.ac.id>

Submission Confirmation for IJSCASEREPORTS-D-22-01040R1

2 pesan

International Journal of Surgery Case Reports <em@editorialmanager.com> 19 September 2022 pukul 21.54
Balas Ke: International Journal of Surgery Case Reports <ijscasereports@elsevier.com>
Kepada: Muhammad Faris <mfarisns@fk.unair.ac.id>

Ms. Ref. No.: IJSCASEREPORTS-D-22-01040R1

Title: One-stage Anterior Approach for Long-segment Subaxial Cervical Spondylitis Tuberculosis: A Case Report
International Journal of Surgery Case Reports

Dear Muhammad,

This message is to acknowledge that I have received your revised manuscript for reconsideration for publication in International Journal of Surgery Case Reports.

You may check the status of your manuscript by logging into the Editorial Manager as an author at <https://www.editorialmanager.com/ijscasereports/>.

Thank you for submitting your work to International Journal of Surgery Case Reports.

Kind regards,

Editorial Office
International Journal of Surgery Case Reports

In compliance with data protection regulations, you may request that we remove your personal registration details at any time. (Use the following URL: <https://www.editorialmanager.com/ijscasereports/login.asp?a=r>). Please contact the publication office if you have any questions.

Your Submission

2 pesan

International Journal of Surgery Case Reports <em@editorialmanager.com> 19 September 2022 pukul 23.21
Balas Ke: International Journal of Surgery Case Reports <ijscasereports@elsevier.com>
Kepada: Muhammad Faris <mfarisns@fk.unair.ac.id>

Ms. Ref. No.: IJSCASEREPORTS-D-22-01040R1

Title: One-stage Anterior Approach for Long-segment Subaxial Cervical Spondylitis Tuberculosis: A Case Report
International Journal of Surgery Case Reports

Dear Dr. Faris,

I am pleased to inform you that your paper "One-stage Anterior Approach for Long-segment Subaxial Cervical Spondylitis Tuberculosis: A Case Report" has been accepted for publication in International Journal of Surgery Case Reports.

This journal is fully open access; all articles will be immediately and permanently free for everyone to read and download. To provide Open Access, this journal has a publication fee which needs to be met by the authors or their research funders.

In the next few days, you will be receiving information via email to allow you to choose one of the CC license options, providing funding information and a link to our payment system.

Learn about publishing Open Access in this journal: <http://www.elsevier.com/journals/International-Journal-of-Surgery-Case-Reports/2210-2612/open-access-options>

We appreciate and value your contribution to International Journal of Surgery Case Reports. We regularly invite authors of recently published manuscript to participate in the peer review process. If you were not already part of the journal's reviewer pool, you have now been added to it. We look forward to your continued participation in our journal, and we hope you will consider us again for future submissions.

Yours sincerely,

The Editors
International Journal of Surgery Case Reports

Comments from the editors and reviewers:

Please cite and reference SCARE during proofing:

Agha RA, Franchi T, Sohrabi C, Mathew G, for the SCARE Group. The SCARE 2020 Guideline: Updating Consensus Surgical Case Report (SCARE) Guidelines, International Journal of Surgery 2020;84:226-230.

In compliance with data protection regulations, you may request that we remove your personal registration details at any time. (Use the following URL: <https://www.editorialmanager.com/ijscasereports/login.asp?a=r>). Please contact the publication office if you have any questions.

One-stage Anterior Approach for Long-segment Subaxial Cervical Spondylitis Tuberculosis: A Case Report

 The corrections made in this section will be reviewed and approved by a journal production editor.

Rifqi Aulia Destiansyah, Eko Agus Subagio, Abdul Hafid Bajamal, Muhammad Faris*, mfarisns@fk.unair.ac.id

Department of Neurosurgery, Universitas Airlangga – Dr. Soetomo General Academic Hospital, Surabaya, East Java, Indonesia

*Corresponding author at: Department of Neurosurgery, Airlangga University – Dr. Soetomo General Academic Hospital, Mayjen Prof. Dr. Moestopo Street No. 6-8, 60286 Surabaya, East Java, Indonesia.

Abstract

Background: Spondylitis TB on cervical region is a rare disease, that may lead to severe neurological complications. The anterior approach is considered as a gold standard for cervical spine tuberculosis. Available studies and literature have not precisely mentioned on how many levels are acceptable for this disease and still up for discussion.

Case presentation: A 45-year-old Asian male was brought from a rural hospital to our outpatient clinic with progressive weakness of all extremities for 3 months. Cervical x-ray and MRI showed three-levels of vertebral body destruction, suggesting a cervical spondylitis TB. Patient had debridement, corpectomy on C4, 5, 6, fusion with cage, and anterior plating from C3 to Th1 in a one-stage anterior approach. Immediately after the surgery, the patient had no complaints of pain, and he was able to walk on his own. One year follow-up after the surgery, no residual neurological impairment is detected and had no limitation in daily activities. Cervical x-ray and MRI showed good ossification and improvement of lordotic curvature.

Conclusion: Treatment of cervical spondylitis TB which involved three-levels of vertebrae using one-stage anterior approach provides a good rate of deformity correction along with clinical improvement and long-term well-being of the patient.

Keywords:

Cervical spondylitis, Tuberculosis, Surgery, Anterior approach, Extrapulmonary TB

Abbreviations

No keyword abbreviations are available

1.1 Introduction

Tuberculosis (TB) remained a significant disease burden and causes huge economic loss worldwide. Indonesia has a numerous TB prevalence, with 759 out of 100,000 people (95% CI: 589,7-960,8) suffering from this disease. 60% of the new TB cases worldwide, are accounted from 6 countries, including Indonesia [1]. Spinal tuberculosis is one form of extrapulmonary TB frequently observed. At present, there is no data about the incidence and prevalence of spinal tuberculosis, both worldwide and per country [2].


Spinal tuberculosis (Pott's disease) on the cervical region is a rare incidence, varying from 2 to 12% of all cases of spinal tuberculosis. Cervical TB could lead to severe neurological symptoms, thus, should be diagnosed and managed with extra care. Surgical approaches to cervical spinal tuberculosis are still contentious. There are 3 surgical approaches available: anterior, posterior, and both (360°). The anterior approach is considered a gold standard for cervical spine tuberculosis, since the disease usually involves the anterior column, allowing direct access to the focus of the disease, and providing better stabilization [3]. However, available studies and literature nowadays have not precisely mentioned how many levels are acceptable for this approach, thus, procedures involving more than two levels of vertebrae are still up for debate. We present a case with a 45-years old male with cervical spine tuberculosis managed with merely one stage of anterior approach with a good outcome, with a one-year follow-up without any pulmonary TB symptoms. [This article is reported based on SCARE 2020 \[10\]](#).

2.2 Case presentation

A 45-years-old Asian male patient came to our academic general hospital outpatient clinic, referred from a countryside hospital. The patient suffered from weakness on all extremities for 3 months before admission. Patient realized the symptoms got worse when driving a car and he was unable to walk for 1 month. Two weeks later, patient felt weakness on upper extremities, alongside a tingling sensation. Patient also complained of neck pain. Pain was radiating to both hands and legs. There was no history of fever, decreased body weight, long period of cough and contact with TB patients. However, there was night sweating for 5 months before admission. History of trauma was denied. There were no disturbances on urination and defecation.

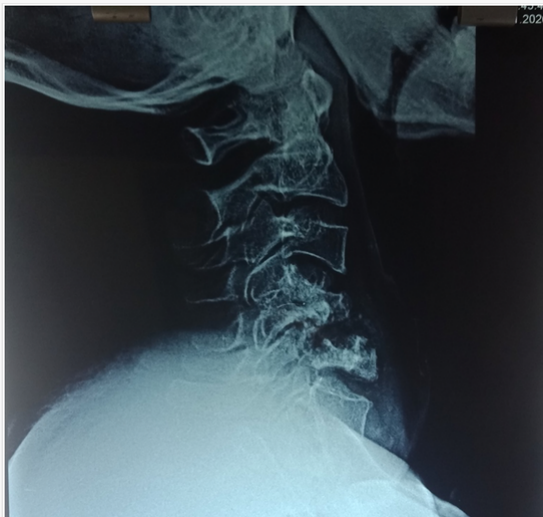From physical examination, we found normal vital sign. Neurological examination showed tetra-paresis with motoric power of 3 on all extremities, hypoesthesia on C4 level and below, increased physiologic reflexes and positive pathologic reflexes (Babinski and Chaddock) on both sides with normal anal sphincter tones and bulbocavernosus reflex.

We did several radiologic examinations for attaining a diagnosis. Cervical x-ray showed destruction on C4, 5 and 6, kyphotic curvature with Cobb's angle of 8.5° (Fig. 1). Cervical MRI with contrast showed three-level vertebral bodies and disc destructions at C4, C5 and C6 with hypointense mass on T1 and isointense on T2 at anterior C3, 4, 5, 6 and Th1, suspected as a cervical tuberculosis infection (Fig. 2), and regiment of TB drugs was subsequently given to the patient.


 Images are optimised for fast web viewing. Click on the image to view the original version.

alt-text: Fig. 1

[Fig. 1](#), [Fig. 1](#)

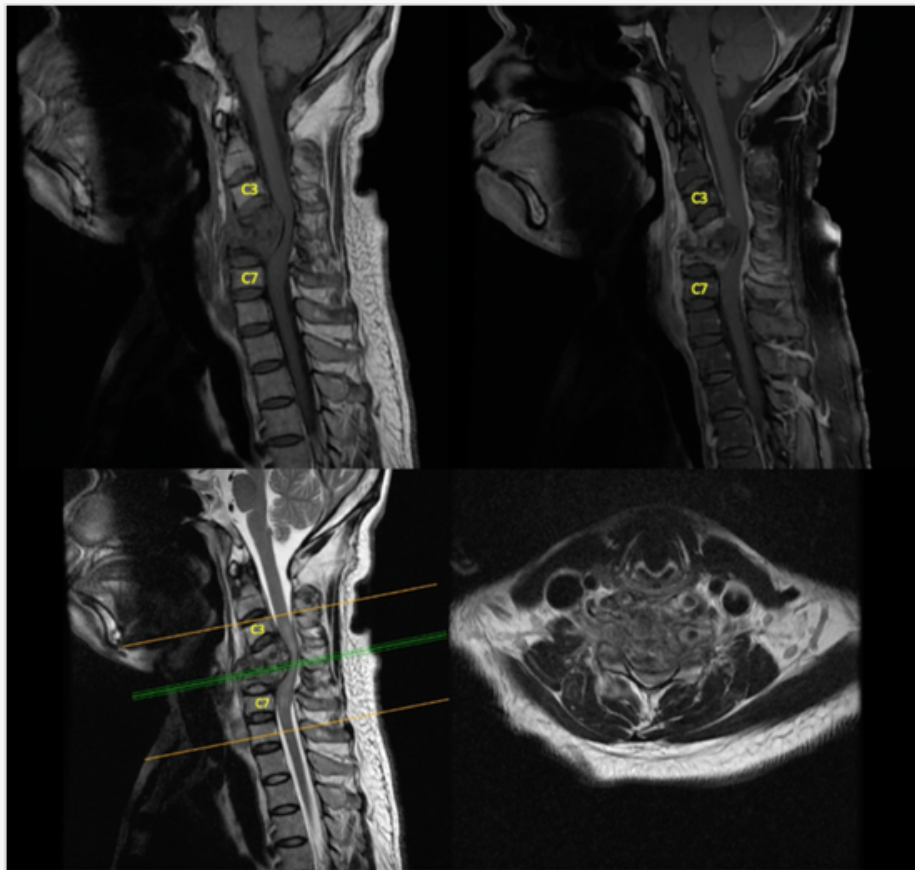


Pre-operative lateral cervical X-ray.

 Images are optimised for fast web viewing. Click on the image to view the original version.


alt-text: Fig. 2

~~Fig. 2~~ [Fig. 2](#)



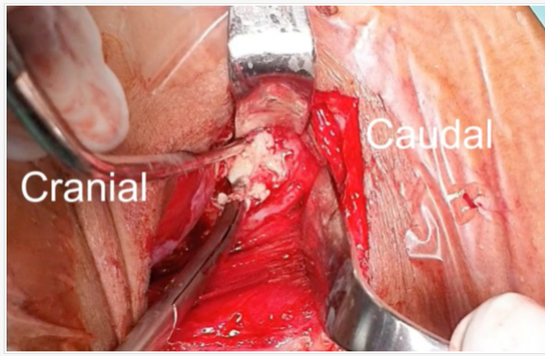
Cervical MRI, T1 with contrast and T2 Sequence.

As the cord compression is located anteriorly and the aim was to correct kyphotic of the cervical curvature, we decided to do debridement, corpectomy on three-levels of C4, 5, and 6, fusion with cage and anterior plating from C3 to Th1, all with a one-stage anterior approach. After dissection was done, we found bony destructions on C4, 5, and 6, with the abscess flowing (Fig. 3). Abscess was evacuated and specimen was sent to microbiology for further examination (gram and specific staining for TB, culture), showed MTB with no Rifampicin resistance, thus, medication for extra pulmonary TB was continued until 9 months.

 Images are optimised for fast web viewing. Click on the image to view the original version.


alt-text: Fig. 3

Fig. 3, Fig. 3



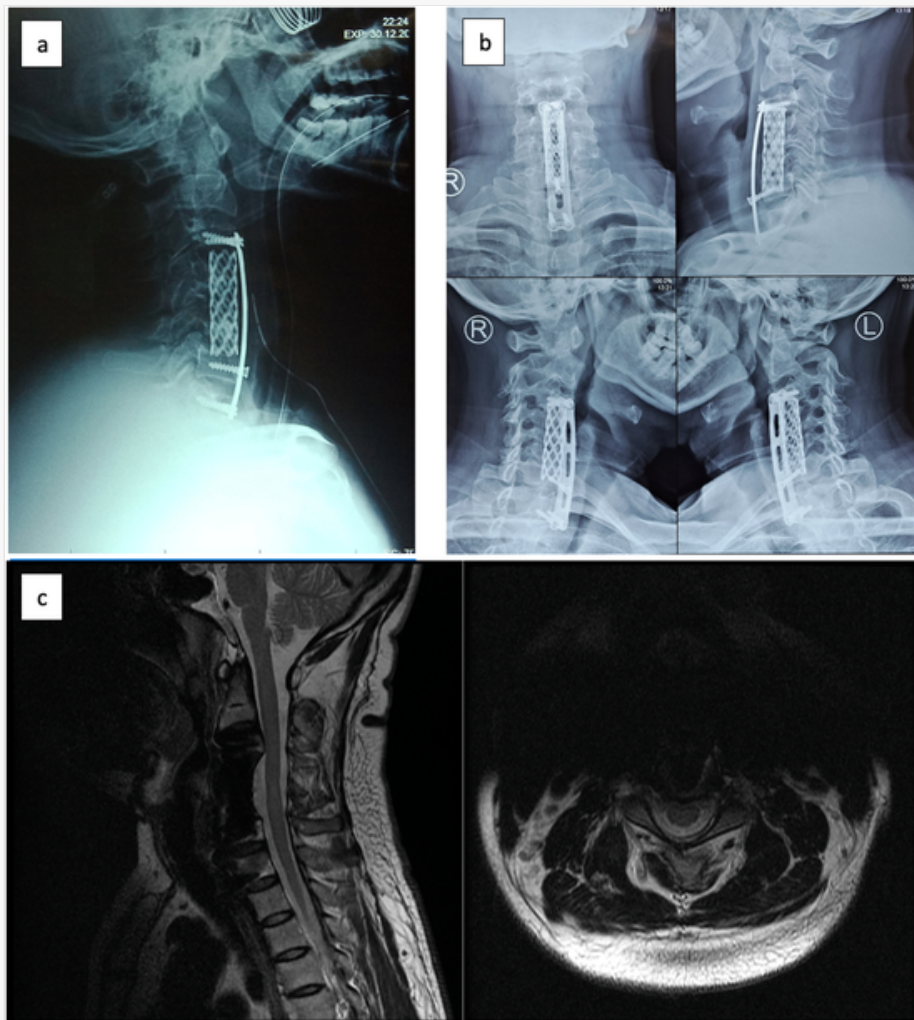
Anterior abscess showed up after dissection.

Corpectomy on three-levels on C4, 5, and 6 was done. Furthermore, instrumentation for anterior column reconstruction with cylindrical cage, bone grafting, and cervical plate was applied. A post-operative cervical x-ray showed the return of cervical lordosis curvature, placement of anterior instrumentation with hollow cage, screw and plating ([Fig. 4a](#)).

 Images are optimised for fast web viewing. Click on the image to view the original version.

alt-text: Fig. 4

[Fig. 4](#)[Fig. 4](#)



(a) Cervical X-Ray early post-operative; (b) 1-year post-operative follow-up Cervical X-ray; (c) 1-year post-operative follow-up Cervical MRI.

Immediately after the surgery, the patient had no complaints of pain, and he was able to walk on his own. One year follow-up after the surgery, no residual neurological impairment is detected, patient is able to run and had no limitation in daily activities. One year following the surgery the patient still had no complaints and able to conduct rigorous physical activity. Cervical x-ray and MRI were done and showed good ossification and improvement of lordotic curvature (Fig. 4b,c).

3.3 Discussion

Spinal TB (Pott's disease) is a detrimental form of TB and is common in young-adult, particularly in developing country like Indonesia. The World Health Organization (WHO) data, implied an envisioned incidence of 10 million new TB cases in 2018, of which Southeast Asia subsidized to 44% of the worldwide cases [1]. Nevertheless, it is frequently missed or misdiagnosed because of inadequate standard health care centers, mainly in the remote areas [2]. Even though the occurrence of tuberculosis in general and spinal TB has less numbers in developed countries, it is far on the upwards thrust with most of these patients being immigrants from TB endemic regions [4]. In the UK, in over 6-years period, from 1999 to 2004, 729 patients had TB; of those, 8% (61 cases) had musculoskeletal involvement, with 30 patients had spinal TB. Immigrants from endemic areas, such as the Indian subcontinent fashioned most of those patients [5].

Spine is involved in up to 50% of patients with osteoarticular TB. Cervical spine is a complex anatomic region so that the structure is susceptible to any anomalies lies within [6]. Cervical spondylitis TB affected 4.2 to 12% of all spinal TB cases. The resultant lesions lead to the development of cervical spine instability (CSI), neurological deficits, severe and progressive kyphosis, paraspinal and epidural abscess, and granuloma leading to cervicomedullary compression [7]. Cervical spondylitis TB grade was reported by Wang et al. on Xiangya Institutes of Medical sciences cervical tuberculosis grading system. In this study, it was described that grade 1 patients were initially managed conservatively, whereas grade 2 patients immediately underwent surgery A (anterior debridement/ decompression and fusion with autogenous bone grafting; Fig. 1), and grade 3 patients underwent PA/AP surgery (posterior fixation with instrumentation, followed by simultaneous or sequential anterior debridement/decompression and fusion [8].

Opinions in the literature regarding the management of cervical spondylitis TB have periodically fluctuated from completely conservative to radical surgical management. This transformation rose largely because many studies have been an isolated case report or because cervical spondylitis TB cases have been included in larger studies of tubercular afflictions of the skeletal system. Studies available to address specifically on cervical spondylitis TB generally reflected on surgeon's individual preference rather than based on clear guidelines. There are reports for anterior instrumentation and was accepted by spine surgeons worldwide, as in the cervical spondylitis TB, anterior part of the vertebral body; which is the most common focus of infection, thus, anterior decompression and instrumentation should be the reasonable procedure of choice [3].

However, the recent publications regarding anterior approach for cervical spondylitis TB has not been standardized on how many levels **is are** acceptable for this procedure. Srivastava et al. published their study about anterior approach for cervical spondylitis TB of 46 patients, with the C5-C6 involvement of more than 50% of the cases (24 of 46 cases) but none involve more than two levels of the vertebrae [9]. In our case, we decided to use the anterior approach with 3 levels of vertebrae, as the surgical indication was to correct the kyphosis of the patient. Pre-operative Cobb's angle was 8.5° kyphosis, which after the procedure became 13.5° lordosis. On the clinical significancy, there was an immediate neurological improvement on the patient.

4.4 Conclusion

Based on the result and outcome of this case, treatment of cervical spondylitis TB which involved three-levels of vertebrae using one-stage anterior approach including anterior debridement, corpectomy, instrumentation, and fusion, it can be concluded that this procedure provides a good rate of deformity correction along with clinical improvement and long-term well-being of the patient.

Submission statement

This manuscript is original and has not been submitted elsewhere in part or in whole.

Provenance and peer review

Not commissioned, externally peer-reviewed.

Funding

None.

Ethical approval

None.

Consent

Written informed consent was obtained from the patient for publication of this case report and accompanying images. A copy of the written consent is available for review by the Editor-in-Chief of this journal on request.

Author Contribution

The roles are distributed as follows:

1. Conception and Design were done by RAD, MF, EAS AHB
2. Supervision was done by EAS AHB
3. Materials and data collection were done by RAD, MF
4. Analysis were done by RAD, MF
5. Literature Review and Editing were done by MF, EAS

Registration of research studies

Not applicable


Guarantor

MF accepts full responsibility for this review manuscript.

Declaration of competing interest

None.

References

 The corrections made in this section will be reviewed and approved by a journal production editor. The newly added/removed references and its citations will be reordered and rearranged by the production team.

- [1] A. Noviyani, T. Nopsopon, K. Pongpirul, Variation of tuberculosis prevalence across diagnostic approaches and geographical areas of Indonesia, *PLoS One* 16 (2021) 1–12, doi:10.1371/journal.pone.0258809.
- [2] T.G. Mahadewa, Management of spinal tuberculosis (TB) in developing country, *Bali Med. J.* 5 (2016) 129, doi:10.15562/bmj.v5i2.245.
- [3] X.H. Yin, B.R. He, Z.K. Liu, D.J. Hao, The clinical outcomes and surgical strategy for cervical spine tuberculosis: a retrospective study in 78 cases, *Med.* 97 (2018) <https://www.ncbi.nlm.nih.gov/pubmed/29979434> <https://www.ncbi.nlm.nih.gov/pubmed/29979434> e11401.
- [4] A.K. Jain, Tuberculosis of the spine, *J. Bone Joint Surg. Br.* 92-B (2010) 905–913, doi:10.1302/0301-620X.92B7.24668.
- [5] A. Albaadani, A.Al Anazi, A case of multifocal musculoskeletal tuberculosis in pregnant woman, *J. Med. Cases* 7 (2016) 368–372, doi:10.14740/jmc2585w.

- [6] R.K. Garg, D.S. Somvanshi, Spinal tuberculosis: a review, *J. Spinal Cord Med.* 34 (2011) 440–454, doi:10.1179/2045772311Y.0000000023.
- [7] S. Rajasekaran, D.C.R. Soundararajan, A.P. Shetty, R.M. Kanna, Spinal tuberculosis: current concepts, *Glob. Spine J.* 8 (2018) 96S–108S, doi:10.1177/2192568218769053.
- [8] X.Y. Wang, C.K. Luo, W.W. Li, P. Wu, X.Y. Pang, Z.Q. Xu, H. Zeng, W. Peng, P.H. Zhang, A practical therapeutic protocol for cervical tuberculosis, *Eur. J. Trauma Emerg. Surg.* 39 (2013) 93–99, doi:10.1007/s00068-012-0243-5.
- [9] S. Srivastava, K. Roy, S. Bhosale, N. Marathe, A. Raj, R. Agarwal, Outcome analysis of subaxial cervical spine tuberculosis operated by the anterior approach: a single-center experience, 15, 2021, pp. 18–25.
- [10] R.A. Agha, T Franchi, C Sohrabi, G Mathew, A Kerwan, The SCARE 2020 Guideline: Updating Consensus Surgical CAse REport (SCARE) Guidelines, *Int. J. Surg* 84 (2020) 226–230, doi:<https://doi.org/10.1016/j.ijsu.2020.10.034>, Submitted for publication.

Highlights

- Q2**
- Cervical TB is rare and could lead to severe neurological symptoms, thus, should be diagnosed and managed with extra care.
 - The anterior approach is considered as a gold standard for cervical spine tuberculosis, since the disease usually involves anterior column, allowing direct access to the focus of the disease, and provide better stabilization
 - Opinions in the literature regarding the management of cervical spondylitis TB have periodically fluctuated from completely conservative to radical surgical management.
 - In this case the use of anterior approach for involvement of 3 levels of cervical vertebrae is to correct the kyphosis of the patient.
 - Treatment of cervical spondylitis TB which involved three-levels of vertebrae using one-stage anterior approach provides a good rate of deformity correction along with clinical improvement **and long-term well-being** of the patient.

Queries and Answers

Q1

Query: Please review the **given names and surnames** to make sure that we have identified them correctly and that they are presented in the desired order. Carefully verify the spelling of all authors' names as well. If changes are needed, please provide the edits in the author section.

Answer: Yes

Query: **Highlights** should only consist of 125 characters per bullet point, including spaces. The highlights provided are too long; please edit them to meet the requirement.

Answer: Done

Corrections received - [IJSCR_107693]

2 pesan

optteam@elsevierproofcentral.com <optteam@elsevierproofcentral.com>
Kepada: mfarisns@fk.unair.ac.id

21 September 2022 pukul 23.04

This is an automatically generated message. Please do not reply because this mailbox is not monitored.

Dear Dr. Muhammad Faris,

Thank you very much for using the Proof Central application for your article "One-stage anterior approach for long-segment subaxial cervical spondylitis tuberculosis: A case report" in the journal "IJSCR"

All your corrections have been saved in our system. The PDF summary of your corrections, generated from Proof Central, can be downloaded from the following site for your reference:

https://pcv3-elsevier-live.s3.amazonaws.com/f96e797622a28b77dd0763a1ca2564/IJSCR_107693_edit_report.pdf

To track the status of your article throughout the publication process, please use our article tracking service:

http://authors.elsevier.com/TrackPaper.html?trk_article=IJSCR107693&trk_surname=

For help with article tracking:

http://support.elsevier.com/app/answers/detail/a_id/90

Kindly note that now we have received your corrections, your article is considered finalised and further amendments are no longer possible.

For further assistance, please visit our customer support site at <http://support.elsevier.com>. Here you can search for solutions on a range of topics. You will also find our 24/7 support contact details should you need any further assistance from one of our customer support representatives.

Yours sincerely,
Elsevier Proof Central team

When you publish in an Elsevier journal your article is widely accessible. All Elsevier journal articles and book chapters are automatically added to Elsevier's SciVerse Science Direct which is used by 16 million researchers. This means that Elsevier helps your research get discovered and ensures that you have the greatest impact with your new article.

www.sciencedirect.com

Track Your Accepted Article

The easiest way to check the publication status of your accepted article

One-stage anterior approach for long-segment subaxial cervical spondylitis tuberculosis: A case report

Article reference	IJSCR_107693
Journal	International Journal of Surgery Case Reports
Corresponding author	Muhammad Faris
First author	Rifqi Aulia Destiansyah
Received at Editorial Office	16 Aug 2022
Article revised	19 Sep 2022
Article accepted for publication	19 Sep 2022
DOI	10.1016/j.ijscr.2022.107693

Last update: 12 Oct 2022

[Share via email](#)



ISSN 2210-2612

Status comment

- The online journal in which your article is compiled is now finalised.

Production events

12 Oct 2022	Online journal finalised	
23 Sep 2022	The Share Link has been sent to you	i
23 Sep 2022	Final version of your article published online	i
22 Sep 2022	Rights & Access form completed by you	
21 Sep 2022	Your proof corrections have been returned to Elsevier	
21 Sep 2022	Proofs available for checking	
21 Sep 2022	Article published online	i
21 Sep 2022	Rights & Access form sent to you for completion	
19 Sep 2022	Received for production	

Bibliographic information

Volume/Issue
99C

Full bibliographic details
International Journal of Surgery Case Reports 99C (2022) 107693

Final article available online
12 Oct 2022

[View your final article](#)

Cited by in Scopus: 0

[Track another article](#)