

# 2023 - Interdisciplinary Neurosurgery - A Technical Note of an Alternative Way for Lumbar Pedicle Screw Insertion

*by M Faris*

---

**Submission date:** 04-Apr-2023 11:19AM (UTC+0800)

**Submission ID:** 2055265042

**File name:** ote\_of\_an\_Alternative\_Way\_for\_Lumbar\_Pedicle\_Screw\_Insertion.pdf (4.94M)

**Word count:** 1826

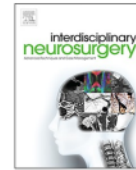**Character count:** 10336



ELSEVIER

Contents lists available at ScienceDirect

# Interdisciplinary Neurosurgery: Advanced Techniques and Case Management

journal homepage: [www.elsevier.com/locate/inat](http://www.elsevier.com/locate/inat)

## A technical note of an alternative way for lumbar pedicle screw insertion

Muhammad Faris<sup>a,\*</sup>, Rizki Meizikri<sup>a</sup>, Wisnu Baskoro<sup>b</sup>, Ismail Muhammad Baselim<sup>d</sup>, Yunus Kuntawi Aji<sup>c</sup>, Pandu Wicaksono<sup>a</sup>, Eko Agus Subagio<sup>a</sup>, Abdul Hafid Bajamal<sup>a</sup>

<sup>a</sup> Neurosurgery Department, Neurospine Division, Faculty of Medicine Universitas Airlangga, Dr. Soetomo Academic General Hospital, Surabaya, Indonesia

<sup>b</sup> Neurosurgery Department, Dr. Soeradji Tirtonegoro Central Public Hospital, Klaten, Indonesia

<sup>c</sup> Neurosurgery Department, Neurospine Division, National Brain Center Hospital, Jakarta, Indonesia

<sup>d</sup> Neurosurgery Department, Lira Medika Hospital, Karawang, Indonesia

### ARTICLE INFO

#### Keywords:

Pedicle screw  
Lumbar spine surgery  
Technique

### ABSTRACT

Posterior stabilization using pedicle screw is a basic procedure in lumbar spine surgery. The success of this procedure requires learning curve, experience as well as knowledge on anatomical landmarks. Breach into vital structures of or around the spine due to mistakes in screw insertion may result in detrimental results. This technical note proposes a technique to insert lumbar pedicle screws in a relatively easier manner and more consistent for each lumbar vertebral level.

### 1. Introduction

Posterior stabilization using pedicle screws is a basic procedure in lumbar spine surgery. Although technological advances are amplifying the accuracy and safety of pedicle screw placement, the success of this procedure requires learning curve, experience as well as knowledge on anatomical landmarks. Misplacement of lumbar pedicle screw would cause deleterious consequences on neural, vascular, or visceral structures. This technical note will describe an alternative pedicle screw entry point and technique to allow easier screw insertion in lumbar surgery.

### 2. Main text

#### 2.1. Proposed technique

Safety and accuracy of spinal instrumentation is something for which surgeons always seek. In our point of view, simplicity of the technique, among other factors, should be considered to ease reproducibility of the procedure despite anatomical differences between lumbar vertebral levels.

Two anatomical landmarks should be identified: the superior articular process and the transverse process. Transverse process needs to be exposed only at its junction to the superior articular process and the pars interarticularis, thus minimizing lateral retraction. Identifying the transverse process in our technique is done to confirm the position of inferolateral part of the facet joint (superior articular process).

Inferolateral part of the facet joint (superior articular process) is then exposed using monopolar. A high speed drill is then used to prepare the entry point at the inferolateral part of the superior articular process (Fig. 1).

A track is made using a straight probe. This location is situated exactly posterior to the pedicle and thus medial angulation might not exceed 5-10° at all level of lumbar vertebrae. No craniocaudal angulation is necessary. This technique would provide a trajectory parallel to the superior end plate (Fig. 2) (see Fig. 3).

Screw entry is then confirmed mainly using anteroposterior view fluoroscopy. The round-shaped pedicle on anteroposterior view is used to determine where the screw should be directed to and how deep it is already in. Appearance of the tip of the screw at medial side of the round shape indicated that the screw has penetrated further into the vertebral body. Anteroposterior plane-guided lumbar pedicle screw placement has been described before [1].

### 3. Discussion

There is a general agreement that the safest area to place pedicle screw is at the meeting point between pars interarticularis, the transverse process, and the inferior margin of superior articular process.[2] However, the exact location of the entry point might vary.

Magerl introduced a pedicle screw entry point at the intersection between vertical line at the lateral border of superior articular process and horizontal line bisecting the transverse process. This point would

\* Corresponding author.

E-mail address: [mfarisns@fk.unair.ac.id](mailto:mfarisns@fk.unair.ac.id) (M. Faris).

<https://doi.org/10.1016/j.inat.2023.101725>

Received 8 October 2022; Received in revised form 5 January 2023; Accepted 15 January 2023

Available online 16 January 2023

2214-7519/© 2023 The Authors. Published by Elsevier B.V. This is an open access article under the CC BY-NC-ND license (<http://creativecommons.org/licenses/by-nc-nd/4.0/>).

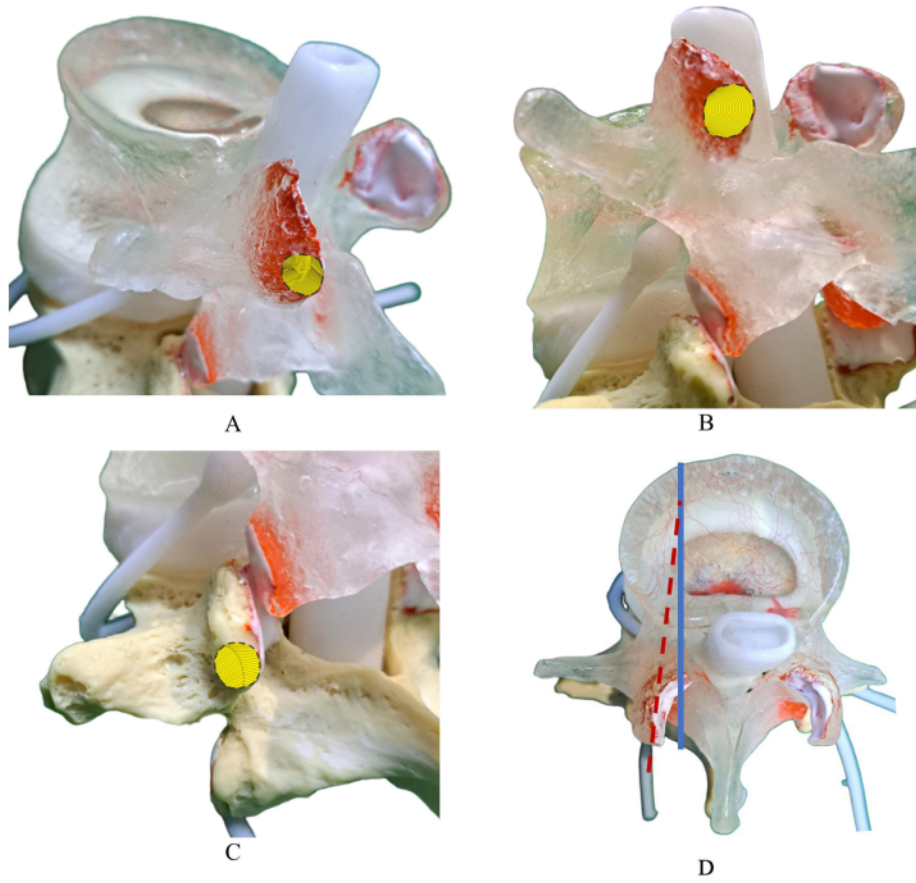
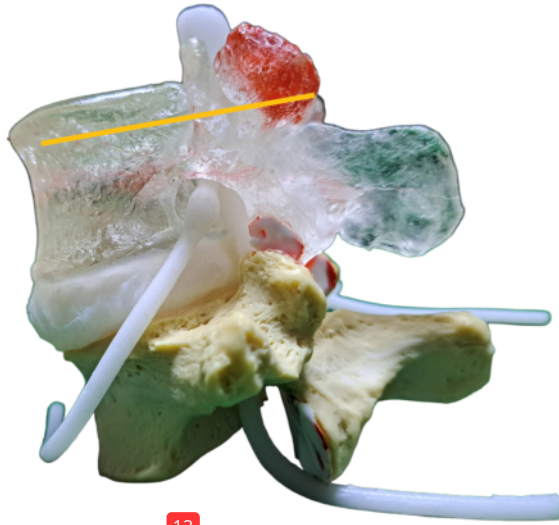


Fig. 1. (A, B and C) Entry point of our technique (marked by yellow zone) at the inferior part of superior articular process; (D) trajectory of pedicle screw in our technique. (For interpretation of the references to colour in this figure legend, the reader is referred to the web version of this article.)



13  
Fig. 2. 13 Lateral view of our technique's entry point. The screw will be situated exactly parallel to the superior end plate. This entry point is exactly posterior to the pedicle, allowing screw's entry at a narrow angle relative to the sagittal plane (Fig. 1D). The angle remains true for all lumbar vertebrae, avoiding the need to justify medial angulation accordingly.

fall at the junction between transverse process, facet joint and the pars interarticularis (Fig. 4A) [3]. On axial view, Magerl's technique require one to incline the screw medially in order to penetrate the pedicle. The angle differs between levels as the trajectory of the pedicle changes by approximately  $5^{\circ}$  per level.[3] We leave the cephalad screw head 2 mm more protruding than the distal screw to avoid abutment of the facet capsule. We also use polyaxial screw to allow more proper positioning of the screw's head.

Cortical bone trajectory (CBT) is a technique which positions the screw to reach superior endplate more posteriorly. Entry point of CBT is the intersection between the midpoint of superior articular process and the horizontal line 1 mm below the inferior border of transverse process. The screw is then pointed laterally  $8-9^{\circ}$  and  $25-26^{\circ}$  cranially (Fig. 4B) [4].

Roy-Camille promoted a technique in which the screw is inserted at the meeting point between midpoint of superior articular process and midtransverse line [5]. Roy-Camille technique would situate the screw more medially than Magerl's, and allow it to penetrate straight into the pedicle without angulation (Fig. 4C).

Weinstein technique was advocated at inferolateral border of superior articular process and is commonly used in the Wiltse approach with paraspinal muscle sparing (Fig. 4D). Weinstein technique's entry point is more lateral but with similar principle of insertion with Magerl's, that is to angulate the screw medially according to the direction of the pedicle [5].

Our technique provides a relatively easier screw insertion due to requiring minimal changes of angulation in all lumbar vertebrae level, is situated more medial to some of the known techniques, and is situated exactly posterior to the pedicle. The differences between our technique

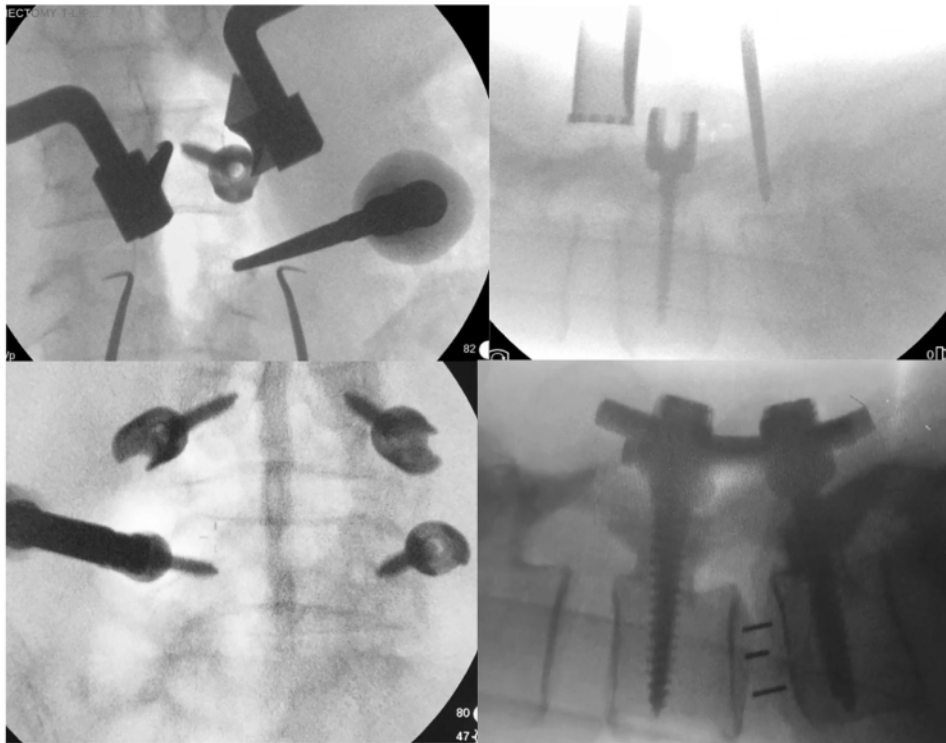


Fig. 3. Top: Fluoroscopic view of a L4-L5 instrumentation. The tip of the screw has reached the medial side of the round shape in anteroposterior view, and is proven to have penetrated at least two-third of the vertebral body on lateral view. The probe at L5 is at lateral border of the round shape, and is proven to have penetrated little into the pedicle on lateral view. Bottom: Screw insertion at L4-L5 with the round-shaped pedicle on fluoroscopy as the guide, final position reconfirmed using lateral view.

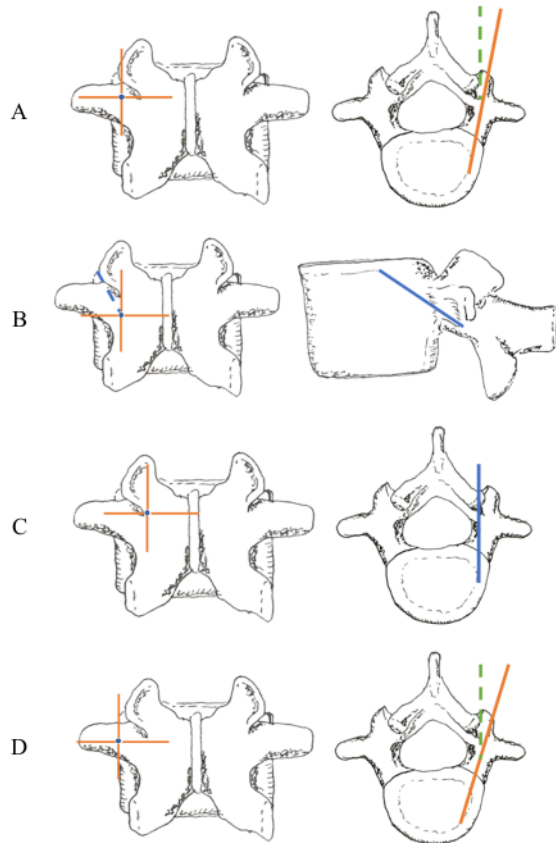


Fig. 4. (A) Magerl technique; (B) Cortical bone trajectory; (C) Roy-Camille technique; (D) Weinstein technique.

and other previously described techniques are summarised in Table 1. Among previously described techniques, our technique is closest to Magerl's. The differing point is that Magerl's require more lateral retraction than ours, in order to appropriately define the midtransverse line (MTL). The entry point of Magerl's technique, as described in the AO ASIF Principles in Spine Surgery, might be at the junction between transverse process, the pars interarticularis, and the lateral border of the superior articular process. This point is situated somewhat more lateral to our technique, although in practice some surgeons might adjust it despite initially doing it as Magerl's. Fig. 5 illustrates the difference of entry point between Magerl's technique and ours.

Table 1 Comparison between our technique and previously described ones.

	Our Technique	Magerl	Roy-Camille	CBT	Weinstein
Entry point	Inferolateral part of SAP	Meeting point of lateral border of SAP and MTL	Meeting point between mid-SAP and MTL	Meeting point of SAP midpoint and the horizontal line 1 mm below the inferior border of TP	Inferolateral border of SAP, more laterally situated than Magerl
Mediolateral angulation	Relatively constant from L1 to L5	Changes according to level	Straight	Shorter, targets superior end plate	Changes according to level
Craniocaudal angulation	None	None	None	Targets superior endplate	None
Structures identification	FJ, TP (medial side only)	FJ, TP	FJ, TP	FJ, TP	FJ, TP (more lateral)

SAP: Superior articular process FJ: Facet joint. TP: Transverse process. MTL: Midtransverse line.

#### 4. Conclusions

Our technique provides easier access to the screw's entry point, avoids further lateral retraction of muscles, and avoids changing screw's angulation between different lumbar levels.

#### CRedit authorship contribution statement

Muhammad Faris: Conceptualization, Investigation, Writing - review & editing, Supervision. Rizki Meizikri: Conceptualization, Visualization, Writing - original draft, Writing - review & editing. Wisnu Baskoro: Investigation. Ismail Muhammad Baselim: Investigation, Supervision. Yunus Kuntawi Aji: Supervision. Pandu Wicaksono: Visualization, Supervision. Eko Agus Subagio: Visualization, Supervision. Abdul Hafid Bajamal: Supervision.

#### Declaration of Competing Interest

The authors declare that they have no known competing financial interests or personal relationships that could have appeared to influence the work reported in this paper.

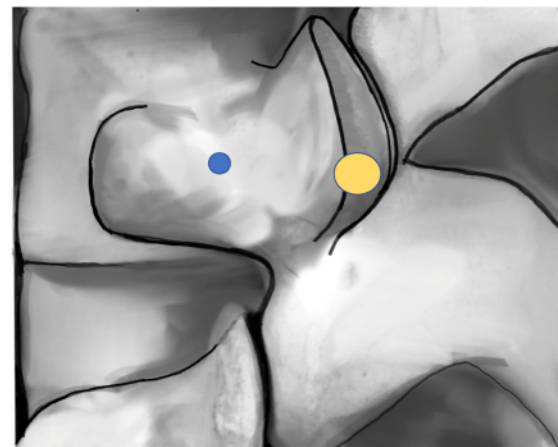


Fig. 5. Comparison of entry point location between Magerl's and our technique. Note that the blue circle (Magerl's) is situated at the junction between lateral border of superior articular process and midtransverse line, while the yellow area is our technique's entry point. (For interpretation of the references to colour in this figure legend, the reader is referred to the web version of this article.)

**Acknowledgement**

None.

**Funding**

None.

**References**

- [1] A. Sethi, A. Lee, R. Vaidya, Lumbar pedicle screw placement: Using only AP plane imaging, *Indian J. Orthop.* 46 (2012) 434–438.

- [2] C.H. Oh, S.H. Yoon, Y.J. Kim, D. Hyun, H.-C. Park, Technical Report of Free Hand Pedicle Screw Placement using the Entry Points with Junction of Proximal Edge of Transverse Process and Lamina in Lumbar Spine: Analysis of 2601 Consecutive Screws, *Korean J. Spine* 10 (2013) 7–13.
- [3] M. Aebi, J.S. Thalgott, J. K. Webb, *AO ASIF Principles in Spine Surgery*. (Springer, 1998). doi: <https://doi.org/10.1007/978-3-642-56680-6>.
- [4] Z.-H. Feng, et al. The technique of cortical bone trajectory screw fixation in spine surgery: a comprehensive literature review. *AME Med. J.* 3, 8–8 (2018).
- [5] W.-X. Xu, et al., Appropriate insertion point for percutaneous pedicle screw placement in the lumbar spine using c-arm fluoroscopy: a cadaveric study, *BMC Musculoskelet. Disord.* 21 (2020) 750.

# 2023 - Interdisciplinary Neurosurgery - A Technical Note of an Alternative Way for Lumbar Pedicle Screw Insertion

## ORIGINALITY REPORT

19%

SIMILARITY INDEX

12%

INTERNET SOURCES

17%

PUBLICATIONS

0%

STUDENT PAPERS

## PRIMARY SOURCES

1	<a href="https://research.tees.ac.uk">research.tees.ac.uk</a> Internet Source	2%
2	<a href="https://journals.lww.com">journals.lww.com</a> Internet Source	2%
3	Yangsean Choi, Min Kyoung Lee. "Neuroimaging findings of brain MRI and CT in patients with COVID-19: A systematic review and meta-analysis", European Journal of Radiology, 2020 Publication	2%
4	<a href="https://kth.diva-portal.org">kth.diva-portal.org</a> Internet Source	2%
5	Shilong Liu, Zhenhai Han, Shikai Liu, Yinhai Li, Zhiyuan Zhou, Baosen Shi. "Efficient 525 nm laser generation in single or double resonant cavity", Optics Communications, 2018 Publication	1%
6	<a href="http://www.politesi.polimi.it">www.politesi.polimi.it</a> Internet Source	1%

7	Suresh Sagili, Jerome Ha. "Lower eyelid retractor (white-line) advancement to correct tarsal ectropion", Canadian Journal of Ophthalmology, 2018 Publication	1 %
8	docplayer.net Internet Source	1 %
9	David A. Provenzano, Samer Narouze. "Sonographically Guided Lumbar Spine Procedures", Journal of Ultrasound in Medicine, 2013 Publication	1 %
10	Wisnu Baskoro, Muhammad Fakhri Raiyan Pratama, Ayu Yoniko Christi, Muhammad Faris et al. "Case of compressive myelopathy due to juvenile xanthogranuloma of cervicothoracic junction in a 28-year-old male", Surgical Neurology International, 2023 Publication	1 %
11	P. Prithvi Raj, Serdar Erdine. "Interventional Pain Procedures in the Lumbar Region", Wiley, 2012 Publication	1 %
12	Surgical Approaches to the Spine, 2003. Publication	1 %
13	H. Bahadir Gokcen, Sinan Erdogan, Sidar Ozturk, Gurkan Gumussuyu, Irem Bayram,	1 %



Cagatay Ozturk. "Sagittal orientation and uniform entry for thoracic pedicle screw placement with free-hand technique: A retrospective study on 382 pedicle screws", *International Journal of Surgery*, 2018

Publication

---

14

[hal-enac.archives-ouvertes.fr](http://hal-enac.archives-ouvertes.fr)

Internet Source

1 %

---

15

Peiqiang Su, Wentong Zhang, Yan Peng, Anjing Liang, Kaili Du, Dongsheng Huang. "Use of computed tomographic reconstruction to establish the ideal entry point for pedicle screws in idiopathic scoliosis", *European Spine Journal*, 2011

Publication

---

1 %

---

Exclude quotes  Off

Exclude matches  < 10 words

Exclude bibliography  On

# 2023 - Interdisciplinary Neurosurgery - A Technical Note of an Alternative Way for Lumbar Pedicle Screw Insertion

---

## GRADEMARK REPORT

---

FINAL GRADE

**/0**

GENERAL COMMENTS

**Instructor**

---

PAGE 1

---

PAGE 2

---

PAGE 3

---

PAGE 4

---

PAGE 5

---