

# 2020 -Widya Medika - Idiopathic Osteoporosis

*by M Faris*

---

**Submission date:** 08-Apr-2023 02:08PM (UTC+0800)

**Submission ID:** 2058891727

**File name:** 2020\_-Widya\_Medika\_-\_Idiopathic\_Osteoporosis.pdf (1.23M)

**Word count:** 3231

**Character count:** 17876

**SEBUAH STUDI KASUS OSTEOPORSIS JUVENIL IDIOPATIK DENGAN  
PROGRESIF KIFOSKOLIOSIS:**

*(Idiopathic Juvenile Osteoporosis with Progressive Kyphoscoliosis: A Case Report)*

Nunung Nugroho<sup>1),2)</sup>, Muhammad Faris<sup>3),4)</sup>, Albert Setiawan<sup>1)</sup>

**ABSTRACT**

**Introduction:** Osteoporosis is a common disease in elderly patients, but rarely found in children. Idiopathic juvenile osteoporosis (IJO) is one of the primary causes of childhood osteoporosis and it is a rare disease. The prevalence and pathogenesis of the disease is still not well-understood. Disease progressions may occur in patient's without treatment causing impairment, disability and handicap to the patient. **Case description:** A ten-year-old boy came to specialist doctor's clinic with pain on his back, had difficulties in wearing his pants, and a humped back posture came for a medical examination. The symptoms appeared 2 months after falling on sitting position. Radiology examinations showed progressive corpus vertebrae compression with kyphoscoliosis, no significant abnormalities in the laboratory findings. **Discussion:** Causes of osteoporosis were excluded through history taking, physical examination, laboratory and radiology results. Treatment of idiopathic juvenile osteoporosis still have controversies. In this case the patient showed significant improvements of symptoms after per oral vitamin D, exercises, and Jewett brace was given as the treatment. **Conclusion:** In this case after 1 year of treatment in physical and rehabilitation department, there is an improvement in kyphotic Cobb's angle from 90° to 40.2°, the patient has no more limitation in doing his activities of daily living and able to do light sport activities.

**Keywords:** *Kyphoscoliosis, Children, Osteoporosis.*

**ABSTRAK**

**Pendahuluan:** Osteoporosis merupakan penyakit yang umum pada pasien lansia, namun jarang pada anak. Osteoporosis juvenil idiopatik merupakan salah satu penyebab primer osteoporosis pada anak dan merupakan sebuah kasus yang langka. Prevalensi dan patogenesis dari penyakit ini masih belum diketahui dengan baik. Progresifitas dapat timbul pada pasien yang tidak mendapatkan tatalaksana dan menyebabkan *impairment, disability, dan handicap*. **Deskripsi Kasus:** Seorang anak laki-laki berusia 10 tahun datang ke klinik dokter spesialis dengan keluhan nyeri pada punggung, kesulitan dalam menggunakan celana dan tubuh tampak membungkuk. Gejala tersebut timbul 2 bulan setelah jatuh pada posisi duduk. Pada pemeriksaan radiologi ditemukan kompresi progresif pada korpus vertebra dengan

kifoskoliosis dan tanpa penemuan hasil laboratorium yang signifikan. **Diskusi:** Penyebab osteoporosis dieksklusi melalui riwayat penyakit, pemeriksaan fisik, hasil laboratorium dan radiologi dari pasien. Masih terdapat kontroversi untuk tatalaksana osteoporosis juvenil idiopatik. Pada kasus ini pasien diberikan terapi vitamin D per oral, latihan fisik, dan *Jewett brace* menunjukkan perbaikan gejala yang signifikan. **Kesimpulan:** Pada kasus ini setelah dilakukan tatalaksana selama 1 tahun di bagian kedokteran fisik dan rehabilitasi, terdapat perbaikan pada derajat *Cobb* kifosis dari 90° menjadi 40.2°, pasien tidak ada lagi hambatan dalam melakukan aktifitas sehari-hari dan pasien dapat melakukan aktifitas olahraga ringan.

**Kata Kunci: Kifoskoliosis, Anak, Osteoporosis.**

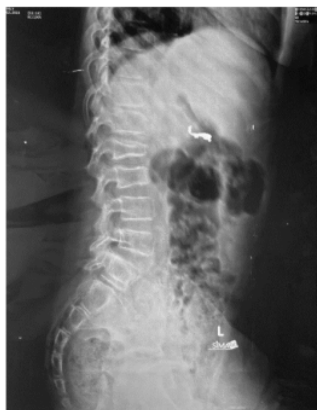1) Department of Physical & Rehabilitation, Faculty of Medicine, Widya Mandala Catholic University of Surabaya, Indonesia. Email: nugroho\_rspnc@yahoo.com/ Phone number: +62811340264. 2) Division of Physical & Rehabilitation, Primasatya Husada Citra Hospital Surabaya, Indonesia. Jl. Prapat Kurung Selatan No. 1, Surabaya, Indonesia. 3) Department of Neurosurgeon, Dr. Soetomo General Hospital/ Faculty of Medicine, Airlangga University of Surabaya. 4) Division of Neurosurgeon, Primasatya Husada Citra Hospital Surabaya, Indonesia. Jl. Prapat Kurung Selatan No. 1, Surabaya, Indonesia.

## INTRODUCTION

Idiopathic Juvenile Osteoporosis (IJO) is a rare case. It manifests in prepubertal period, between 8-15 years old with pain in the back, bones, extremities, and radiological evidence of osteoporosis<sup>1,2,3</sup>. No consistent biochemical abnormality is found and there is a wide range of severity of the disease<sup>1</sup>. The exact prevalence is unknown but several hundreds of cases have been reported in the literature so far.

The etiology of idiopathic juvenile osteoporosis is remaining unknown, the diagnosis is made by exclusion of other causes of osteoporosis<sup>4,5</sup>. It is reported that resolution occurs within 1-4 years after the onset of puberty<sup>1</sup>.

In IJO, the disease process itself can cause osteoporosis. Children with IJO have bone mass that is lower than expected. In other cases, medication used to treat the primary disorder may reduce bone mass. Some behaviours associated with the primary disorder may lead to bone loss or reduction in bone formation.



**Figure 1.** Lateral view of thoracolumbar

In this study we report one case of idiopathic juvenile osteoporosis with the clinical and radiological findings. The purpose of this study is to discuss the symptoms, laboratory and radiology findings and the treatment for idiopathic juvenile osteoporosis.

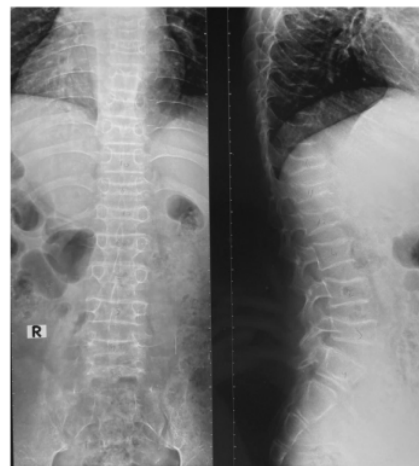
### CASE DESCRIPTION

A 10-year-old boy came to physical & rehabilitation clinic referred from neurosurgeon clinic of Primasatya Husada Citra (PHC) Hospital Surabaya with back pain and kyphotic posture, the patient had suffered pain for about 9 months. There was a history of trauma, the patient fell on sitting position while he was about to play rollerblade (December 2017). Two months after the incident, the patient complained that he felt pain on his back, and his father observed the patient had difficulties in wearing his own pants and a humped back.

After the incident, the father's patient decided to bring the patient for a medical examination. At that time the patient's height and weight was 150 cm and 54 kg, resulting his body mass index (BMI) was 24 kg/m<sup>2</sup> (overweight). Patient complained there was pain on his back, able to ambulate without any assistive devices and no weakness of muscle. The doctor did a radiology examination of the patient's vertebrae, the result showed that there was

a compressed fracture of the 1<sup>st</sup> lumbar spine corpus (Figure 1).

The doctor decided to give a physiotherapy treatment and a thoracolumbosacral corset for the patient to wear. After undergoing 8 months of physiotherapy and wearing the corset, the patient didn't feel any improvement in his back pain. The doctor did another vertebrae radiology examination to evaluate the treatment, no trauma happened in the last 8 months, the result showed compression fracture of 11<sup>th</sup>-12<sup>th</sup> thoracic and 1<sup>st</sup>-4<sup>th</sup> lumbar corpus vertebrae (Figure 2).



**Figure 2.** AP and lateral view of thoracolumbar

The patient was referred from Kediri to Surabaya for further examination and treatment, he was referred to Neurosurgeon clinic of Primasatya Husada Citra Hospital Surabaya.

Laboratory tests were done to find the diagnosis of the disease; kidney function

test, complete blood count, parathyroid hormone, protein electrophoresis, alkaline phosphatase, total calcium, phosphate test were done. Slight difference were found in the results of MCHC (31.0 g/dL, normal: 32-36 g/dL), erythrocyte sedimentation rate (30 mm/hour, normal 0-10 mm/hour), electrophoresis protein total (8.45 g/dL, normal: 6.0-8.0 g/dL), electrophoresis protein albumin (5.37 g/dL, normal: 4.3-5.0 g/dL), alfa 2 (0.84 g/dL, normal: 0.5-0.8 g/dL), and phosphate (4.82 mg/dL, normal: 2.5-4.5 mg/dL), while the other results were within normal limits.

On 31<sup>st</sup> October 2018 another vertebrae x-ray was done, the result showed compression in 5<sup>th</sup>-12<sup>th</sup> thoracic and 1<sup>st</sup>-4<sup>th</sup> lumbar corpus vertebrae, kyphotic cobb's angle was 90°, with biconvex scoliosis of thoracic and lumbar scoliosis (Figure 3).

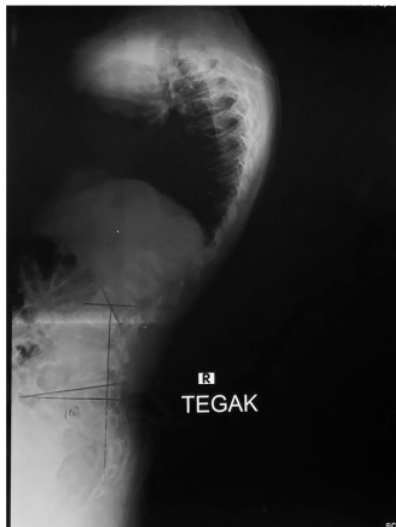

Figure 3. Lateral view of thoracolumbar

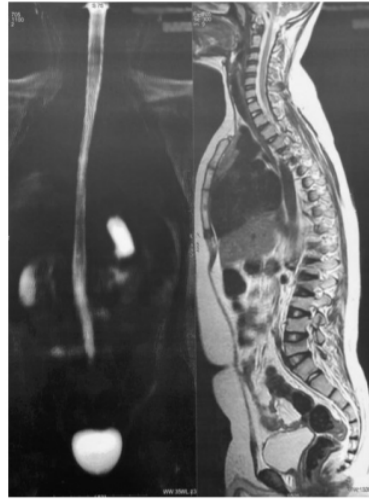
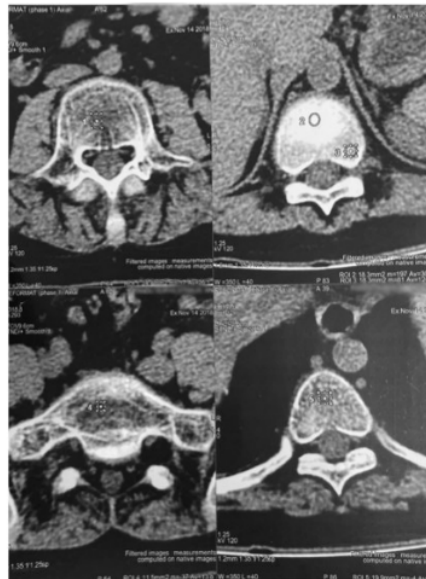


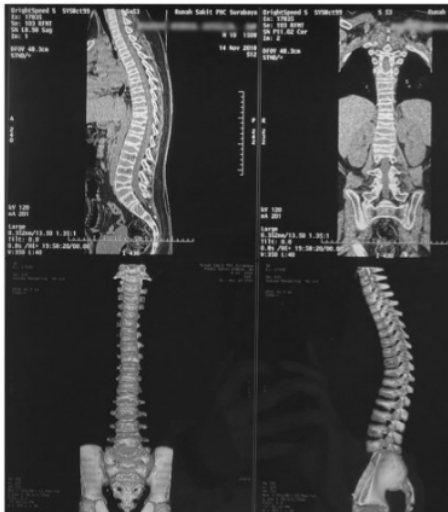Figure 4. MRI and myelography of spine

MRI results showed that bone density on all sequences seemed old fracture, no abnormalities in spinal cord, on myelography there was no cerebrospinal liquor flow blockade (Figure 4), and no abnormal contrast enhancement when contrast was administered.



**Figure 5.** CT-scan of spine, measuring the Hounsfield unit (HU)

CT-scan result showed bones seem porotic, some part 26 HU and some part 244 HU (Figure 5), no intervertebralis foramen narrowing, no osteophyte, and processus articularis transversus and spinosus were normal (Figure 6).



**Figure 6.** CT-scan of spine

The patient was referred to physical and rehabilitation clinic in Primasatya Husada Citra Hospital Surabaya. The manual muscle test (MMT), physiological reflexes & range of motion of upper and lower extremities, bladder and stool were within normal limits. There were no pathological reflexes, visual analog scale (VAS) score of back pain was 6. The pain caused a limitation in doing his activities of daily living (ADL) especially in wearing his

pants and the patient is unable to join sport activities at school.

Standard scoliosis x-ray was done, the result showed 20° Cobb's angle in straight position, 3° Cobb's angle in right bending position, and 39° Cobb's angle in left bending position.

The patient was suggested to swim and did back exercises at home, posture correction while in standing & sitting position, and was given *Jewett* brace. The brace was given for the kyphotic vertebrae correction, the patient should wear the brace every day, especially during activities.

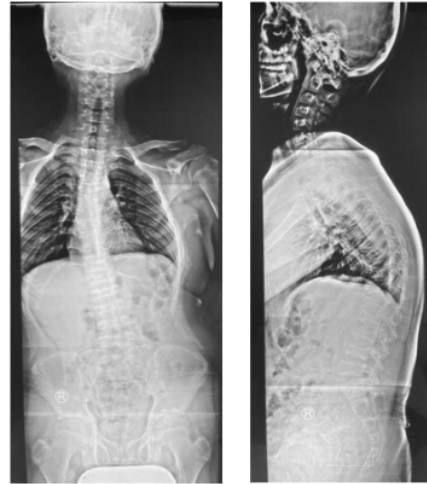
Total vitamin D 25-OH was measured to find out the cause of pain and the progressive corpus vertebrae compression. The result showed insufficiency of vitamin D (24,15 ng/mL, normal: > 30 ng/mL), the patient was referred to Pediatric clinic for further treatment. Per oral vitamin D 1466 IU / day was given and the total vitamin D 25-OH level was monitored. Dose of per oral vitamin D was raised until 4000 IU / day, and the result of total vitamin D 25-OH reached normal (45,7 ng/mL) after 2 months of treatment. Maintenance dose of 1000 IU / day per oral vita (Table 1).

**Table 1.** Total vitamin D 25-OH level and dose of per oral vitamin D treatment.

Date	Total Vitamin D 25-OH level (N: > 30 ng/mL)	Dose of per oral Vitamin D / day
14/01/19	24.15 ng/mL	1466 IU
13/06/19	24.73 ng/mL	2000 IU
01/10/19	23.44 ng/mL	4000 IU
16/12/19	45.7 ng/mL	1000 IU (maintenance)

After per oral vitamin D, exercise and wearing the *Jewett* brace was given for 1 year, the VAS score decreased to the score of 2. The patient had no limitations in doing his ADL including wearing his own pants and able to do light sport activities at school such as jogging and slow walking.

A full spine radiology examination was done on 16 December 2019 to evaluate the vertebrae condition. Results showed diffuse moderate to severe compression almost in all thoracolumbar, scoliosis of 1<sup>st</sup> thoracic to 3<sup>rd</sup> lumbar with right convexity Cobb's angle 24.5°, and kyphotic Cobb's angle 40.2° (Figure 7). The exercise, per oral vitamin D and *Jewett* brace were continued (Table 2).



**Figure 7.** AP and lateral view of the whole spine.

**Table 2.** Kyphotic Cobb's angle progression and treatment.

Date	Kyphotic Cobb's Angle	Treatment
23/02/18	-	Thoracolumbosacral corset, physiotherapy & exercise.
31/10/18	90°	<i>Jewett</i> brace, physiotherapy, exercise, posture correction & swimming.
16/12/19	40.2°	Vitamin D, <i>Jewett</i> brace, physiotherapy, exercise, posture correction & swimming.

One year after treatment, the patient's body height was 158 cm, and body weight 62 kg, resulting his BMI score 24,84 kg/m<sup>2</sup> (overweight). Some laboratory tests were done to exclude other the possible causes of osteoporosis.

Tests of FT4 (1.16 ng/dL), TSHs (1.27 µIU/mL), blood glucose, liver function test, urinalysis were done and all

were within normal limits. Previous CTx and osteocalcin was not tested, recent laboratory test showed CTx (2.99 ng/mL) and osteocalcin (170 ng/mL). The patient didn't complain any pain, no limitations in doing his activities of daily living, and able to do light sport activities such as jogging and slow walking.

## DISCUSSION

The prevalence and pathogenesis of idiopathic juvenile osteoporosis is still not well-understood<sup>4</sup>. It is very difficult to diagnose idiopathic juvenile osteoporosis, factors of; patient's symptoms, patient's history, physical examination, laboratory and radiology findings are considered to make the diagnosis<sup>2</sup>.

In this case, there is no familial history of childhood or adolescence osteoporosis<sup>6</sup>. Other diagnosis such as osteogenesis imperfecta, and other secondary causes of osteoporosis are needed to be excluded before diagnosing the patient as idiopathic juvenile osteoporosis<sup>2,6</sup>.

Osteogenesis imperfecta is excluded in this patient because there is no blue sclera, no deafness and no dental problems<sup>5,7</sup>. While other differential diagnosis are excluded, no anemia rules out thalassemia, no leukopenia & no leukocytosis exclude leukemia, normal value of glucose level exclude diabetes

mellitus, normal renal function and urinalysis exclude chronic renal failure and other metabolic causes.

Normal thyroid and parathyroid hormone levels exclude hyperthyroid and hyper parathyroid, no history of long term drugs consumption (drug types: corticosteroid, anticonvulsant, & immunosuppressive agents), normal calcium & ALP, no significant abnormalities in phosphates & vitamin D levels, no long bones deformity, and absence of rickets characteristics in radiological findings exclude rickets, no gastrointestinal symptoms and stool problems<sup>1-4</sup>.

The patient has normal growth since birth according to the patient's *Kartu Menuju Sehat* (KMS) chart<sup>8</sup>. First sign of puberty appear in mid 2019, with the change of voice and growth of pubic hair at his age of 11 years. According to the pubic hair growth, the patient is included in Tanner stage 2<sup>9</sup>. It shows no sign of growth, development and puberty delay.<sup>8,9</sup>

The patient has history of trauma, fell on sitting position on December 2017. Two months after the incident, the patient complained that he felt pain on his back and had a humped back.

Bone mineral density (BMD) test is defined as osteoporosis by the World Health Organization (WHO) when T-score is less than -2.5<sup>10</sup>. The bone mineral density of the



patient is not able to be done because there is no suitable equipment software to measure children's bone mineral density in Surabaya, Indonesia.

Osteoporosis radiology appearance of this patient is found through vertebrae plain photo, MRI and CT-Scan findings<sup>10</sup>. The patient's bone CT-scan result shows some part 26 HU, it shows osteoporosis<sup>11</sup>.

The result of patient's CTx is above 50<sup>th</sup> centile and osteocalcin is above the 97<sup>th</sup> centile according to Rauchenzauner M, *et al* 2007 research<sup>12</sup>. It shows that the bone resorption is within normal limits, but the bone formation is in a highly active phase<sup>12</sup>. These results correspond to idiopathic juvenile osteoporosis, where the symptoms resolve after the onset of puberty<sup>1</sup>.

In this case, examinations have been done to find the underlying causes of the disease. In fact, the results of physical examination, laboratory and radiology findings didn't lead to any specific syndrome or a disease. Therefore, this case leads to a idiopathic juvenile osteoporosis.

In some severe cases of idiopathic juvenile osteoporosis, kyphoscoliosis and rib deformity can develop<sup>4</sup>. This case may be included in the severe case because the patient suffer kyphoscoliosis with fast progressivity. Vertebrae compression & symptoms are needed to be monitored to see the progress of the disease.

Currently, the treatment of idiopathic juvenile osteoporosis has no evidence-based guidelines<sup>3</sup>. Vitamin D, bisphosphonates, calcium, physical activity, and brace is considered as the treatment<sup>1,6,13,14</sup>. It is suggested to do early detection of vitamin D levels to idiopathic juvenile osteoporosis patients. Treatment of vitamin D may be beneficial if deficiency or insufficiency of vitamin D was found<sup>3</sup>. In this case, exercise, per oral vitamin D, and *Jewett* brace is given. It shows positive results in decreasing pain, enabling the patient's to do his activities of daily living, improving the kyphotic Cobb's angle and the patient's body height.

## CONCLUSION

<sup>2</sup> Idiopathic juvenile osteoporosis (IJO) is a rare disease with an unknown cause. Even the effectiveness of treatment still have controversies, but treatment must be given to prevent further complications or worsening of condition.

In this case, with per oral vitamin D, *Jewett* brace, swimming & back exercises, posture correction while in standing & sitting position relief the patient's pain, improving his kyphotic Cobb's angle from 90° to 40.2°. The patient's body height increases from 150 to 158 cm (within 25 months), able to do activities of daily living independently, and able to do light sport activities.

Further follow up and examination is needed to find out any other possible causes of the patient's condition. Examination of extremities motoric strength, autonomic nervous system, ability to do his activities of daily living, and other neurological deficit signs, need to be observed.

Laboratory tests of calcium, vitamin D, renal function test, CTx and osteocalcin also needed to be monitored to evaluate the treatment outcome. Additional treatment will be considered if laboratory results show abnormal values.

Annual routine of hip x-ray photo is considered to find out the bone maturity (Risser classification) and vertebrae x-ray to monitor the kyphosis and scoliosis Cobb's angle. If the kyphosis or scoliosis Cobb's angle degree worsened, a special brace will be considered for the kyphoscoliosis correction.

When the patient reaches 18 years old, bone mineral density test is considered to evaluate the severity of the osteoporosis and to evaluate the treatment results.

#### INFORMED CONSENT

The informed consent was obtained from the patient's parent for the publication of this case.

#### ACKNOWLEDGEMENT

The authors would like to thank all management and staffs of Primasatya Husada Citra Hospital Surabaya.

#### CONFLICT OF INTEREST

The authors have no conflict of interest.

#### REFERENCES

1. Yam K, Wong, G. Case Report: Idiopathic Juvenile Osteoporosis. Hong Kong Journal of Paediatrics. 2004;9:158-161.
2. Altan H. Idiopathic Juvenile Osteoporosis: A Case Report. Journal of Clinical Diagnosis and Research. 2015;9(8):10-12.
3. Bacchetta, J, Wesseling-Perry, K, Gilsanz, V, Gales, B., Pereira, R. Salusky, I. Idiopathic juvenile osteoporosis: a cross-sectional single-centre experience with bone histomorphometry and quantitative computed tomography. Pediatric Rheumatology. 2013;11(1), 6.
4. Marcucci G, Brandi M. Mini-review: Rare causes of osteoporosis. Clinical cases in mineral and bone metabolism 2015;12(2);151-156.
5. Kulkarni M, Keshavamurthy K. Juvenile Idiopathic Osteoporosis. Indian Pediatrics. 2004;41:737-740.
6. Imerci A, Canbek U, Haghari S, Sürer L, Kocak M. Idiopathic juvenile osteoporosis: A case report

- and review of the literature. *International Journal of Surgery Case Reports*. 2015;9:127-129.
7. Campos L, Liphau B, Silva C, Pereira R. Osteoporosis in childhood and adolescence. *Jornal de Pediatria*. 2003;79(6):481-488.
  8. Ministry of Health of the Republic of Indonesia. Peraturan Menteri Kesehatan Republik Indonesia tentang Penggunaan artu Menuju Sehat (KMS) bagi Balita. Jakarta: Ministry of Health of the Republic of Indonesia; 2010.
  9. Brämwig J, Dübbers A. Disorders of Pubertal Development. *Deutsches Aerzteblatt Online*. 2009;106(17):295-304.
  10. Alqahtani F, Offiah A. Diagnosis of osteoporotic vertebral fractures in children. *Pediatric Radiology*. 2018;49(3):283-296.
  11. Patel S, J. Lee J. Normative Vertebral Hounsfield Unit Values and Correlation with Bone Mineral Density. *Journal of Clinical & Experimental Orthopaedics*. 2016;02(01).
  12. Rauchenzauner M, Schmid A, Heinz-Erian P, Kapelari K, Falkensammer G, Griesmacher A, *et al.* Sex- and Age-Specific Reference Curves for Serum Markers of Bone Turnover in Healthy Children from 2 Months to 18 Years. *The Journal of Clinical Endocrinology & Metabolism*. 2007;92(2):443-449.
  13. Alexandru D. Evaluation and Management of Vertebral Compression Fractures. *The Permanente Journal*. 2012;16(4):46-51.
  14. Saraff V, Högler W. Endocrinology And Adolescence: Osteoporosis in children: diagnosis and management. *European Journal of Endocrinology*. 2015;173(6):185-197.

# 2020 -Widya Medika - Idiopathic Osteoporosis

## ORIGINALITY REPORT

8%

SIMILARITY INDEX

7%

INTERNET SOURCES

3%

PUBLICATIONS

0%

STUDENT PAPERS

## PRIMARY SOURCES

1	<a href="http://www.repository.wima.ac.id">www.repository.wima.ac.id</a> Internet Source	2%
2	<a href="http://www.bones.nih.gov">www.bones.nih.gov</a> Internet Source	2%
3	<a href="http://www.orpha.net">www.orpha.net</a> Internet Source	1%
4	Ignacio Garcia, Vincent Chiodo, Yan Ma, Adele Boskey, Ward L, Kulkarni ML, Uziel Y, Gourion-Arsiquaud S, Spevak L, Eyre DR. "Evidence of altered matrix composition in iliac crest biopsies from patients with idiopathic juvenile osteoporosis", 'Informa UK Limited' Internet Source	1%
5	<a href="http://synapse.koreamed.org">synapse.koreamed.org</a> Internet Source	1%
6	<a href="http://sites.kowsarpub.com">sites.kowsarpub.com</a> Internet Source	1%
7	Ahmed M. Sallam, Walid A. Abdel Ghany, Ali Kotb Ali, Mohamed A. Habib et al. "Short-segment posterior fixation with index level	<1%

screws versus long-segment posterior fixation for thoracolumbar spine fracture: angle of correction and pain", Egyptian Journal of Neurosurgery, 2018

Publication

8

[repository.unair.ac.id](https://repository.unair.ac.id)

Internet Source

<1 %

9

Thomas G. Lightfoot, Laurie Delia VanThof. "New serologic findings in a patient with ulcerative colitis and a warm autoantibody", Immunohematology, 2020

Publication

<1 %

10

[idoc.pub](https://idoc.pub)

Internet Source

<1 %

11

[lesann.tripod.com](https://lesann.tripod.com)

Internet Source

<1 %

Exclude quotes  Off

Exclude matches  < 10 words

Exclude bibliography  On