

# 2023 - MBIO - Differentiation of Spinal Tuberculosis and Metastatic Spinal Tumor

*by M Faris*

---

**Submission date:** 08-Apr-2023 02:09PM (UTC+0800)

**Submission ID:** 2058891939

**File name:** entiation\_of\_Spinal\_Tuberculosis\_and\_Metastatic\_Spinal\_Tumor.pdf (209.73K)

**Word count:** 4129

**Character count:** 23960

## SYSTEMATIC REVIEW

## Differentiation of Spinal Tuberculosis and Metastatic Spinal Tumor using MRI Feature: A Systematic Review

Justicia Izza Tsuroya<sup>1</sup>, Muhammad Faris<sup>2</sup>, Paulus Rahardjo<sup>3\*</sup>

<sup>1</sup>Medical Program, Faculty of Medicine, Universitas Airlangga, Surabaya, Indonesia.

<sup>2</sup>Department of Neurosurgery, Faculty of Medicine, Universitas Airlangga; Dr. Soetomo General Academic Hospital, Surabaya, Indonesia.

<sup>3</sup>Department of Radiology, Faculty of Medicine, Universitas Airlangga; Dr. Soetomo General Academic Hospital, Surabaya, Indonesia.

### Article Info

#### Article history:

Received Aug 8, 2022  
Revised Oct 23, 2022  
Accepted Dec 2, 2022  
Published Jan 10, 2023

#### Keywords:

Metastatic spinal tumor  
MRI  
Pott's disease  
Spinal neoplasms  
Spinal tuberculosis

#### \*Corresponding author:

Paulus Rahardjo  
paulus-r@fk.unair.ac.id

### ABSTRACT

**Background:** Spinal tuberculosis and metastatic tumors are commonly diagnosed lesions in the spine. Tuberculosis spondylitis, also known as Pott's Disease, is the most common extrapulmonary tuberculosis disease. MRI is the gold standard for early diagnosis because there is no significant difference in the results of clinical manifestations and histopathological examination. A biopsy will usually be used for a final exam for diagnosis. **Objective:** To provide information to confirm the diagnosis of TB spondylitis cases and metastatic spinal tumors. **Method:** A literature search was conducted via PubMed, Science Direct, and Scopus by selecting studies according to inclusion and exclusion criteria. The quality and risk of bias assessments were performed using Joanna Briggs Institute (JBI) tools. Overall, 35 spinal tuberculosis and 31 metastatic spinal tumor patients from 2 studies were reviewed. **Result:** Of the 35 patients with tuberculous spondylitis and 31 patients with metastatic spinal tumors from the two studies reviewed. It was found that the thorax was the most common region. The following imaging findings were of statistical significance ( $p < 0.05$ ): skip lesion, solitary lesion, intraspinal lesion, concentric collapse, abscess formation (paraspinal, intraosseous, and epidural lesions), and syrinx formation. **Conclusion:** An MRI imaging protocol and correct medical history will help establish an accurate diagnosis. Skip lesions, abscesses, and modular lesion margins are considered for diagnosis.

### How to cite:

Tsuroya, J.I., Faris, M., Rahardjo, P. 2023. Differentiation of Spinal Tuberculosis and Metastatic Spinal Tumor using MRI Feature: A Systematic Review. *Majalah Biomorfologi*, 33(1): 44-51.

*Majalah Biomorfologi (Biomorphology Journal)* p.ISSN:0215-8833, e.ISSN: 2716-0920

doi: 10.20473/mbiom.v33i1.2023.44-51.



Copyright: © 2023 by the authors. Open access publication under the terms and condition of the Creative Commons Attribution 4.0 International license (CC.BY 4.0).

### Highlights

1. Lesions that are regularly diagnosed in the spine include TB of the spine and tumors that have spread throughout the body.
2. The examined papers included 35 individuals with tuberculous spondylitis and 31 patients with metastatic spinal malignancies.
3. A methodology for MRI imaging and an accurate medical history will aid in establishing an accurate diagnosis.

Journal homepage: <https://e-journal.unair.ac.id/MBIO/>

## BACKGROUND

Tuberculous spondylitis and metastatic tumors are lesions of the spine that are often misdiagnosed (Yu, et al., 2013). Tuberculous spondylitis (TB) is a prevalent benign condition often widespread in underdeveloped nations (Ali, et al., 2019). The incidence of spinal tuberculosis ranks at the top in bone and joint tuberculosis. When the typical signs of TB do not persist, the clinical manifestations can closely resemble those of metastases and cannot be easily distinguished (Held, et al., 2018). Additionally, it might elicit comparable symptoms in individuals, mostly pain. As these two illnesses demand quite different treatments, accurate preoperative diagnostic imaging will be of great assistance in deciding the subsequent surgery to be done and the most effective treatment technique (Lang, et al., 2015).

According to the WHO report 2020, TB cases in 2019 are estimated at 10 million people (Chakaya, et al., 2021). The incidence of extrapulmonary TB is 3%, and 10% are skeletal TB cases. Skeletal infections only occur in 1-5% of all tuberculosis infections and can appear as metastases in the differential diagnosis (Jauhary & Hayati, 2022). TB spondylitis accounts for 50% of cases of skeletal tuberculosis infection (Rajasekaran, et al., 2018). In a study with 1196 patients, 432 patients experienced multilevel spine (Wang, et al., 2019).

Tuberculosis spondylitis, also known as Pott's Disease, is a common extrapulmonary tuberculosis disease (Garg & Somvanshi, 2011). Pott's illness, often referred to as tuberculous spondylitis, is an infection of TB that affects one or more vertebrae (Kusmiati & Narendrani, 2019). Tuberculosis is caused by the bacterium *Mycobacterium tuberculosis*, transmitted to the body through droplets inhaled into the respiratory tract (Mertaniasih, et al., 2019). After COVID-19, tuberculosis (TB) is the world's second-largest cause of mortality. By 2020, an estimated 10 million people will be exposed to tuberculosis (TB) worldwide. TB is present in all countries and age groups. Southeast Asia had the highest number of new TB cases, with 43% of new cases, followed by the African area with 25% of new cases and the West Pacific with 18% of new cases (World Health Organization, 2021).

## OBJECTIVE

A systematic study was made to summarize the results of studies from the available literature on the diagnosis of tuberculous spondylitis and tumor metastases when viewed from MRI imaging to facilitate clinicians, researchers, and policymakers to gain a clearer understanding of the differences between the two.

12

## MATERIAL AND METHOD

This systematic review was conducted according to the Preferred Reporting Items for Systematic Reviews and Meta-Analyses (PRISMA) guidelines.

### Literature search strategy

The literature search was performed to identify original articles using PubMed, Science Direct, and Scopus. Studies reporting the diagnostic performance of MRI for differentiating TB spondylitis and metastatic spinal tumor were included. The search term query was formed using the search terms "Spinal Tuberculosis," "Pott's Disease," "Spinal Neoplasms," "Metastatic Spinal Tumors," and "MRI." Articles on human subjects written in English and published between January 1, 2012, and April 29, 2022, were included. Supplemental Table 1 provides a detailed listing of the literature search keywords.

### Eligibility criteria

After removing duplicate publications, the remaining texts were evaluated to find research that met the inclusion criteria: (a) Population: patients with TB spondylitis and metastatic spinal tumors; (b) Index tests: MRI with or without contrast enhancement; (c) Outcomes: sensitivity and specificity of MRI features for differentiating TB spondylitis and metastatic spinal tumors; (d) Study design: both observational and clinical trials; (e) Reference standard: both clinical and pathological diagnosis. (f) study in English; (g) T1-weighted, T2-weighted, and DWI sequence. Studies were excluded according to the following exclusion criteria (a) studies that used same patient datasets; (b) case reports, review

articles, letters, conference abstracts, and editorials; (c) studies not in the field of interest; (d) no full text.

### Data extraction and risk of bias assessment

The following information was extracted from the included articles: (a) study characteristics (authors, year of publication, study period, study design, study type); (b) Study subject characteristics (age, number of patients for each disease, total number of lesions); (c) MRI technique (magnet field strength, use of contrast-enhanced images, type of contrast agent, use of DCE, and slice thickness); (d) MRI features for differentiating TB spondylitis from metastatic spinal tumors; (e) outcomes (statistical significance of the qualitative and quantitative assessment); (f) reference standard for diagnosis of TB spondylitis and metastatic spinal tumors (pathological diagnosis and clinical diagnosis). The two reviewers performed data extraction independently, and all disagreements were re-evaluated in a consensus meeting with third reviewer.

The two reviewers independently assessed the methodological quality of eligible articles using the Joanna Briggs Institute (JBI) critical appraisal tools to minimize the risk of bias. Third, investigators adjudicated any disagreement between investigators.

## RESULT

### Study Selection

Figure 1 shows the selection process of this study and how the selection process was conducted. We initially obtained 196 relevant titles and abstracts encompassing 38 studies from PubMed, 135 from Science Direct, and 23 from Scopus. Among them, 36 studies were duplicated, and 174 were excluded after title and abstract screening. Furthermore, six full-text studies were further assessed based on the exclusion criteria. Finally, two studies were included and analyzed for qualitative synthesis. The quality assessment of all studies using the Joanna Briggs Institute (JBI) tools showed a low risk of bias.

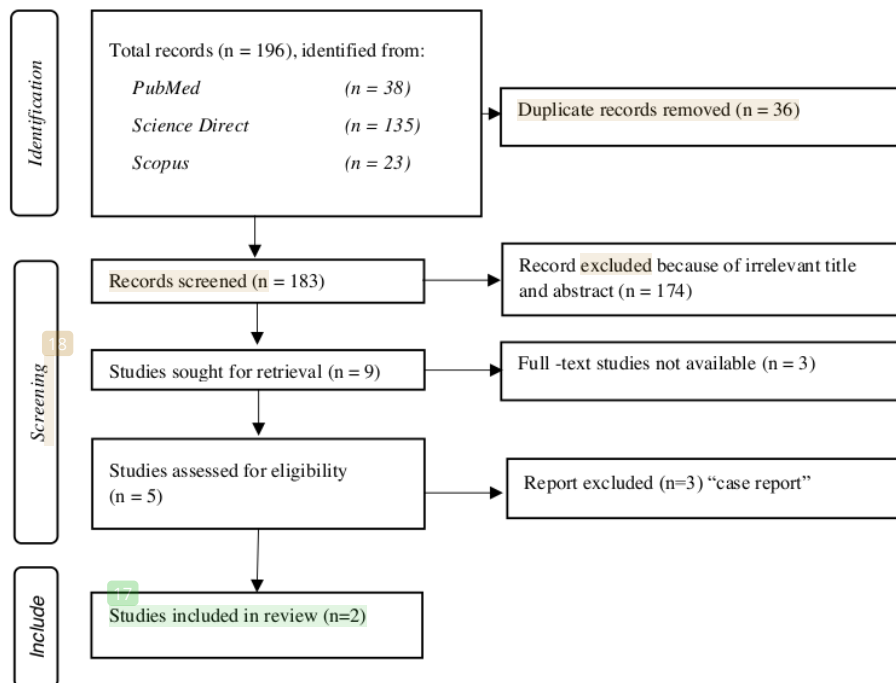


Figure 1. PRISMA diagram

As shown in Table 1, all included studies used a retrospective design and were performed in two locations: one in emerging and developing countries (EDC) and the other in industrialized nations. This comprehensive evaluation covered a total of 66 individuals, including 35 patients with spinal TB and 31 patients with metastatic spinal tumors. The patients were pooled together. Patients with spinal tuberculosis are relatively younger at diagnosis than metastatic spinal tumors. The most prevalent clinical signs are back discomfort and lower extremity weakness. In a study by Garg & Somvanshi (2011), some patients also had bladder and bowel dysfunction, while in a study by Mertaniasih, et al. (2019), patients experienced hypesthesia at the sensory level, and few patients experienced sphincter disorders. In these two studies, most metastases were from the lung and breast, followed by ovarian, renal, nasopharyngeal, glottic, prostate, and unknown primary tumors.

Two studies reported that the thoracic spine was the most common site of involvement in patients with spinal tuberculosis and metastases. A study by Mittal, et al. (2016) found that 13 of 20 patients with spinal TB and 13 of 20 patients with metastases had thoracic involvement (p=0.144). Vertebral involvement has shown several distinguishing characteristics between the two conditions. Vertebral body involvement was seen in 55% of metastasis cases and 65% of spinal tuberculosis cases. This pattern was not significant (p=0.520). Lamina, pedicles, and the spinous process were more commonly seen in metastasis than in the tubercular spine, with 20% in metastasis and 5% in spinal tuberculosis. However, this was not statistically significant, with a p-value of 0.151. Involvement of vertebral body, lamina, pedicles, and spinous was seen more in the metastatic spine (75% of metastasis and 70% of Pott's spine cases) (Garg & Somvanshi, 2011).

Whereas in the study by Li, et al. (2020), it was found that in 5 of 15 spinal tuberculosis patients, the affected side was the thoracic region, in five patients the lumbar and sacral regions, and in five other patients more than two spinal cord regions were involved. Metastasis with each thoracic and lumbar lesion was seen in one of eleven patients, with one instance impacting the whole spinal cord and the other nine affecting more than two locations (Mertaniasih, et al, 2019).

Table 1. Study characteristics

Author (year)	Sample (n)		Duration recruitment of patient	Country	Study Design	Reference Standard
	∑ (n)	Spinal TB (n)				
Mittal et al (2021)	40	20	20	India	Retrospective Study	Histopathology
Li et al (2020)	26	15	11	China	Retrospective Study	Spinal Tuberculosis: AFS dan CSF Analysis

Clinical Manifestation	Mean Age		Age Range		♂:♀	Lesion
	Spinal TB	Tumor Metastasis	Spinal Tuberculosis	Tumor Metastasis		
All patients presented with back pain and weakness in lower limb in both symmetrical and asymmetrical fashion. A few patients also had bladder and	40	56	11-67	43-70	NA	The most common site of involvement was the thoracic spine, seen in 85% of cases of metastasis and 65% of cases of Spinal Tuberculosis (p=0.144).

bowel dysfunction.

All patients experienced progressive neurologic dysfunction of the lower extremities, weakness, followed by pain, hypoesthesia with a sensory level, and eventually astasia. Some Patients also experienced sphincter disturbance.

26.3 years

52.1 years

15-42

38-67

13:13

Most lesions involved subdural extramedullary regions.

For Intraspinal tuberculosis mainly affected the thoracic (5/15), lumbar (5/15), and sacral (5/15), and remaining 5 cases involved two regions of the spinal.

For intraspinal metastasis, no conspicuous location was seen. Nine cases affecting more than two regions (one case involving the entire spinal cord

### MRI characteristics

Table 2. MRI characteristics

Author (year)	Magnet field strength	Contrast Agents	The thickness of dynamic image	Results
Mittal, et.al (2016)	1.5T	Optimark (Gadoversetamide)	3 mm	The most common site is the thoracic region. The following imaging findings showed statistical significance ( $p < 0.05$ ): skip lesions, solitary lesions, intra-spinal lesions, concentric collapse, abscess formation (paraspinal lesions, intraosseous and epidural), and syrinx formation.
Li Q, et.al (2020)	1.5T	Multiple Gadolinium	3.5 mm	Intraspinal tuberculosis lesions had indistinct edges that integrated with each other, most of them exhibiting obvious enhancement on MRI. Conversely, intraspinal metastatic lesions were distinctly separated with precise edges and exhibited lesser enhanced MRI than intraspinal tuberculosis.

The following MRI findings showed statistical significance ( $p < 0.05$ ): skip lesions, solitary lesions, intra-spinal lesions, concentric collapse, abscess formation (paraspinal, intraosseous, and epidural), syrinx formation, and site of distant focus other than the spine. Other than aforementioned, various presentations of lesions included vertebral body changes (anterior, neural arch, and combined), intraspinal, and leptomenigeal patterns.

3

Journal homepage: <https://e-journal.unair.ac.id/MBIO/>

## DISCUSSION

A systematic review of the differences in MRI imaging of patients with tuberculous spondylitis and metastatic spinal tumors has not previously been carried out. It is difficult to distinguish between tuberculous spondylitis and metastatic spinal tumors by relying solely on clinical manifestations, histopathological examination, or CSF analysis. Out of all the modalities, MRI is the best for early detection of tuberculous spondylitis because this disease is often clinically similar to other diseases, especially atypical TB.

In this review, the study by [Mittal, et al. \(2016\)](#) found that MRI imaging results were statistically significant ( $p < 0.05$ ) in differentiating metastatic spinal tumors from tuberculous spondylitis, namely the presence of skip lesions, and solitary lesions, concentric collapse, abscess formation (paraspinal, intrasosseous, epidural), syrinx formation, and the appearance of extra vertebral findings. The nodular lesions' edges are a key factor in seeing the difference. Metastases have well-separated lesion margins and show lower MRI-enhanced ([Li et al., 2020](#))

Sixty-five percent of patients with metastases and twenty percent of individuals with tuberculous spondylitis have skip lesions. The thoracic spine was the most prevalent location for skip lesions, followed by the thoracolumbar and cervical-thoracic regions. A study by [Khattry et al. \(2007\)](#) reported that a case of tuberculous spondylitis in a teenager was misdiagnosed as a neoplastic illness because to several skip lesions affecting the vertebral bodies and pedicles, but sparing the intervertebral discs. The study from [Sivalingam \(2015\)](#) recognized the presence of multiple-level skip lesions in 14 instances (23.7%) without involvement of the intervertebral disc. In cases of metastatic illness, bone metastases most often occur in the spine. Approximately 12% of patients with cancer present with spinal metastases, which are common in middle-aged and elderly patients. Lower thoracic and upper lumbar regions comprise the majority of spinal lesions, comparable to spinal tuberculosis ([Sivalingam, 2015](#)). There have only been a few number of instances with non-contiguous spinal tuberculosis up to this point, and skip lesions are often distinct lesions that affect at least two or three vertebrae at any position along the spine. However, the involvement of extensive hopping lesions at all spinal levels is sporadic. The reported incidence of skip lesions in centers that did not perform routine whole spine MRI was 1.1% and 10% using a combination of regional radiography, CT, and MRI, and 16.3% using bone scintigraphy before starting anti-TB therapy.

In 35% of metastases, solitary spinal lesions were seen, but in 5% of Pott spine cases, just a single lesion without intervertebral disc alterations was observed. Solitary bone cysts presence in the spine in cases of tuberculous spondylitis are very rare. Only a few histologically proven solitary bone cysts affecting the vertebral bodies have been reported. The typical imaging findings of a large osteolytic lesion surrounded by prominent bone sclerosis can help differentiate it from other pathologies ([Fujimoto et al., 2002](#); [Zhen, et al, 2013](#)).

During abscess development, the MRI enhancement helps classify tuberculous spondylitis. Rim enhancement surrounding intra-osseous and paraspinal soft tissue abscesses in spinal infections has not been established. Abscess formation can be seen in the prevertebral, paravertebral, intra-osseous, and epidural spaces. In tuberculous spondylitis, the abscess wall is often thick and irregularly raised on CT and MRI. [Jung et al \(2004\)](#) suggested that tubercular abscesses are more likely to have a thin, modest enhancement of the abscess wall and well-defined aberrant paraspinal signals than neoplasms.

Tuberculosis should be considered in the differential diagnosis of various spinal lesions, including metastases, especially in endemic areas. Both have different treatments and prognoses. Spinal TB is a great mimicker, so often misdiagnosed because it can appear in various typical and atypical patterns. Although the stated prevalence of atypical types of spinal tuberculosis is roughly 7%, researchers anticipated that the incidence would be greater if the whole spine was MRI-scanned ([Rasouli, et al., 2012](#)). [Pandit et al. \(1999\)](#)'s study of 40 patients found that stratified spinal involvement was observed in 25% of patients using bone scintigraphy. The subsequent researcher should perform more study by analyzing additional MRI sequences, so that the information used to create a diagnosis is more exact and correct.

Tuberculous leptomeningitis with intraspinal nodules was considered one of the most common features. In the study by [Li et al. \(2020\)](#) T1-W1-weighted imaging showed thickened meninges. At the same time, [Saxena et al. \(2021\)](#) found no enhancement of leptomeningitis in a few patients. Imaging

findings from patients with tuberculous leptomeningitis include hydrocephalus, intramedullary tuberculoma, spinal arachnoiditis, development of sacral nerve root plaques, focal or diffuse spinal cord edema, and syringomyelia. Contrast-enhanced MRI imaging may not help differentiate tuberculous leptomeningitis from metastatic lesions. It may be due to different scanning protocols, contrast agents, and inclusion criteria for the included patients (Li, et al., 2020).

Intramedullary nodules (single or multiple) surrounded by less edema were observed in patients with metastatic disease, equipotential on T1-WI, and less hyperintensity on T2-WI. When meninges were implicated, a linear rise was found, and nerve root thickening was observed when the cauda equina was applied. Extramedullary lesions, such as intraspinal tuberculosis, manifest as a meningeal thickening but with sharp margins, limited scope, and clear distinction between lesions.

As in other studies, this review also had several limitations. Most of the studies included were still retrospective studies. In addition, the total sample size included in this review was relatively small. Nevertheless, this was the first systematic review to directly assess imaging findings to differentiate between spinal tuberculosis and metastatic spinal tumor. The result of this study was expected to provide valuable additional information in differential diagnosis and as a basis for encouraging further studies in this field of research.

### Strength and limitations

In order for physicians, researchers, and policymakers to acquire a greater knowledge of the distinctions between tuberculous spondylitis and tumor metastases when observed via MRI imaging, a systematic review was conducted to synthesize the findings of studies from the existing literature. There were also numerous limitations to this evaluation. The majority of the included studies were retrospective. In addition, this review comprised a rather limited sample size.

### CONCLUSION

A thorough MRI modality protocol and correct medical history will help ensure an accurate diagnosis and promote an appropriate one. Skip lesions, abscesses, and modular lesion margins should be considered for diagnosis. Endemic in countries such as Indonesia, the management of spine lesions should always consider the potential for tuberculosis infection in the presence of a known malignancy and a malignant soft tissue spinal mass. The imaging function helps to differentiate precisely between atypical and metastatic spinal tuberculosis.

### Acknowledgment

The authors would like to thank the entire staff of the Department of Radiology, Dr. Moewardi Hospital, Surakarta, and the Faculty of Medicine of Sebelas Maret State University, Surakarta.

### Conflict of Interest

All authors have no conflict of interest.

### Funding Disclosure

This research was self-funded by the authors.

### Author Contribution

JIT: Planning and carrying out research, drafting articles; MF: Giving input during the research, correction of draft article to the final; PR: Giving input during the research correction of draft article to the final.

### REFERENCES

- Ali, A., Musbahi, O., White, V.L.C., Montgomery, A.S. 2019. Spinal tuberculosis. *JBJS Reviews*, 7(1): e9–e9. doi: 10.2106/JBJS.RVW.18.00035.
- Chakaya, J., Khan, M., Ntoumi, F., Aklillu, E., Fatima, R., et al. 2021. Global tuberculosis report 2020 – Reflections on the global TB burden, treatment and prevention efforts. *International Journal of Infectious Diseases*, 113: S7–S12. doi: 10.1016/j.ijid.2021.02.107.



- Fujimoto, T., Nakamura, T., Ikeda, T., Koyanagi, E., Takagi, K. 2002. Solitary bone cyst in L-2. *Journal of Neurosurgery: Spine*, 97(1): 151. doi: 10.3171/spi.2002.97.1.0151.
- Garg, R. K., Somvanshi, D. S. 2011. Spinal tuberculosis: A review. *The Journal of Spinal Cord Medicine*, 34(5): 440–454. doi: 10.1179/2045772311Y.0000000023.
- Held, M., Castelein, S., Bruins, M.F., Laubscher, M., Dunn, R., et al. 2018. Most influential literature in spinal tuberculosis: A global disease without global evidence. *Global Spine Journal*, 8(1): 84–94. doi: 10.1177/2192568217707182.
- Jauhary, T., Hayati, F. 2022. Unusual sites of tuberculosis mimicking skeletal metastases: A case report. *Radiology Case Reports*, 17(6): 1931–1937. doi: 10.1016/j.radcr.2022.03.035.
- Jung, N.-Y., Jee, W., Ha, K.Y., Park, C.K., Byun, J.Y. 2004. Discrimination of tuberculous spondylitis from pyogenic spondylitis on MRI. *American Journal of Roentgenology*, 182(6): 1405–1410. doi: 10.2214/ajr.182.6.1821405.
- Khattry, N., Thulkar, S., Das, A., Khan, S.A., Bakhshi, S. 2007. Spinal tuberculosis mimicking malignancy: Atypical imaging features. *The Indian Journal of Pediatrics*, 74(3): 297–298. doi: 10.1007/s12098-007-0049-3.
- Kusmiati, T., Narendrani, H. P. 2019. POTT'S disease. *Jurnal Respirasi*, 2(3): 99. doi: 10.20473/jr.v2-I.3.2016.99-109.
- Lang, N., Su, M., Yu, H.J., Yuan, H. 2015. Differentiation of tuberculosis and metastatic cancer in the spine using dynamic contrast-enhanced MRI. *European Spine Journal*, 24(8): 1729–1737. doi: 10.1007/s00586-015-3851-z.
- Li, Q., Song, J., Li, X., Luo, T., Peng, J., et al. 2020. Differentiation of intraspinal tuberculosis and metastatic cancer using magnetic resonance imaging. *Infection and Drug Resistance*, 13: 341–349. doi: 10.2147/IDR.S224238.
- Mertaniasih, N. M., Koendhori, E. B., Kusumaningrum, D. 2019. *Buku ajar: Tuberkulosis diagnostik mikrobiologis*. Surabaya: Airlangga University Press.
- Mittal, S., Khalid, M., Sabir, A.B., Khalid, S. 2016. Comparison of magnetic resonance imaging findings between pathologically proven cases of atypical tubercular spine and tumour metastasis: A retrospective study in 40 patients. *Asian Spine Journal*, 10(4): 734. doi: 10.4184/asj.2016.10.4.734.
- Pandit, H. G., Sonsale, P.D., Shikare, S.S., Bhojraj, S.Y. 1999. Bone scintigraphy in tuberculous spondylodiscitis. *European Spine Journal*, 8(3): 205–209. doi: 10.1007/s005860050159.
- Rajasekaran, S., Soundararajan, D., Shetty, A.P., Kanna, R.M. 2018. Spinal tuberculosis: Current concepts. *Global Spine Journal*, 8(4\_suppl): 96S–108S. doi: 10.1177/2192568218769053.
- Rasouli, M. R., Mirkoohi, M., Vaccaro, A.R., Yarandi, K.K., Rahimi, V.M. 2012. Spinal tuberculosis: diagnosis and management. *Asian Spine Journal*, 6(4): 294. doi: 10.4184/asj.2012.6.4.294.
- Saxena, D., Pinto, D., Tandon, A.S., Hoisala, R. 2021. MRI findings in tubercular radiculomyelitis. *eNeurologicalSci*, 22: 100316. doi: 10.1016/j.ensci.2021.100316.
- Sivalingam, J. 2015. Spinal tuberculosis resembling neoplastic lesions on MRI. *Journal of Clinical and Diagnostic Research*. doi: 10.7860/JCDR/2015/14030.6719.
- Wang, F., Zhang, H., Yang, L., Yang, X., Zhang, H., Li, J.K. 2019. Epidemiological characteristics of 1196 patients with spinal metastases: A retrospective study. *Orthopaedic Surgery*, 11(6): 1048–1053. doi: 10.1111/os.12552.
- World Health Organization. 2021. *Global tuberculosis report*, World Health Organization.
- Yu, Y., Wang, X., Du, B., Yuan, W., Ni, B., et al. 2013. Isolated atypical spinal tuberculosis mistaken for neoplasia: case report and literature review. *European Spine Journal*, 22(S3): 302–305. doi: 10.1007/s00586-012-2294-z.
- Zhen, P., Li, X., Lu, H. 2013. Single vertebra tuberculosis presenting with solitary localized osteolytic lesion in young adult lumbar spines. *Orthopaedic Surgery*, 5(2): 105–111. doi: 10.1111/os.12037.

# 2023 - M BIO - Differentiation of Spinal Tuberculosis and Metastatic Spinal Tumor

## ORIGINALITY REPORT

17%

SIMILARITY INDEX

13%

INTERNET SOURCES

13%

PUBLICATIONS

2%

STUDENT PAPERS

## PRIMARY SOURCES

1	<a href="https://journals.lww.com">journals.lww.com</a> Internet Source	3%
2	Jiyeon Ha, Sang Hyun Choi, Jae Ho Byun, Kyung Won Kim, So Yeon Kim, Jin Hee Kim, Hyoung Jung Kim. "Meta-analysis of CT and MRI for differentiation of autoimmune pancreatitis from pancreatic adenocarcinoma", European Radiology, 2020 Publication	2%
3	<a href="https://repository.unair.ac.id">repository.unair.ac.id</a> Internet Source	2%
4	<a href="https://link.springer.com">link.springer.com</a> Internet Source	1%
5	<a href="https://pubmed.ncbi.nlm.nih.gov">pubmed.ncbi.nlm.nih.gov</a> Internet Source	1%
6	<a href="https://ojs2.e-journal.unair.ac.id">ojs2.e-journal.unair.ac.id</a> Internet Source	1%
7	<a href="https://notedhealth.com">notedhealth.com</a> Internet Source	1%

8	Zhen, Ping, Xu-sheng Li, and Hao Lu. "Single Vertebra Tuberculosis Presenting with Solitary Localized Osteolytic Lesion in Young Adult Lumbar Spines : Single Vertebra Tuberculosis", Orthopaedic Surgery, 2013. Publication	1 %
9	pesquisa.bvsalud.org Internet Source	1 %
10	MR Imaging and Spectroscopy of Central Nervous System Infection, 2001. Publication	1 %
11	bio-protocol.org Internet Source	1 %
12	www.frontiersin.org Internet Source	1 %
13	Asutosh Dave, Jitendra Kumar Singh, Vishal Patel. "MR Imaging of Intraspinial TB - A Misguide in Disguise", Journal of Evidence Based Medicine and Healthcare, 2020 Publication	<1 %
14	f1000research.com Internet Source	<1 %
15	theicph.com Internet Source	<1 %
16	Thanthawy Jauhary, Fierly Hayati. "Unusual sites of tuberculosis mimicking skeletal	<1 %

# metastases: A case report", Radiology Case Reports, 2022

Publication

17

[ikee.lib.auth.gr](http://ikee.lib.auth.gr)

Internet Source

<1 %

18

[www.preprints.org](http://www.preprints.org)

Internet Source

<1 %

Exclude quotes Off

Exclude matches < 10 words

Exclude bibliography On

# 2023 - MBIO - Differentiation of Spinal Tuberculosis and Metastatic Spinal Tumor

---

GRADEMARK REPORT

---

FINAL GRADE

**/0**

GENERAL COMMENTS

**Instructor**

---

PAGE 1

---

PAGE 2

---

PAGE 3

---

PAGE 4

---

PAGE 5

---

PAGE 6

---

PAGE 7

---

PAGE 8

---