

THE INDIAN VETERINARY JOURNAL

SINCE - 1924

**Journal of the
INDIAN VETERINARY ASSOCIATION**
ESTD - 1922 Regd. No. Sl. No. 96/1967 (CHENNAI)



No. 11, Pasumpon Muthuramalinga Thevar Salai (Chamiers Road),
Nandanam, Chennai - 600 035, Tamil Nadu, India
Tel. : +91 44 2435 1006
Email : ivj83@yahoo.com
ONLINE : www.ivj.org.in

THE INDIAN VETERINARY JOURNAL
(Official Organ of the Indian Veterinary Association)

EDITORIAL COMMITTEE

Dr A.V. KRISHNAN, Chief Editor

B.V.Sc., M.V.Sc (Path.)

Retd. Additional Director of A.H., TN

Dr S. SUKUMAR, Managing Editor

B.V.Sc., M.V.Sc (Vet. Micro), Ph.D. (Biotech)

Retd. Professor of Biotechnology, TANUVAS, TN

Dr V. Titus George, Editor

B.V.Sc., M.V.Sc., Ph.D. (Patho)

Retd. Prof. of Pathology, TANUVAS

Dr I. Ponnu Pandian, Editor

B.V.Sc., PGDAEM

Dr K. Venukopalan, Editor

B.V.Sc., M.V.Sc., Ph.D. (Poul.)

Retd. Prof. of Poultry Science, TANUVAS

EDITORIAL BOARD

CHAIRMAN

Dr. Chirantan Kadian

B.V.Sc & A.H.

President, Indian Veterinary Association

MEMBERS

Prof. Dr C. Balachandran

M.V.Sc, Ph.D., PGDAJ, PGDEVP, DICVP

FAO Fellow, FIAVP, FNAVS, FASAW

Vice-Chancellor

Tamilnadu Veterinary and Animal Sciences University

Madhavaram Milk Colony, Chennai - 600 051.

Dr. P.K. Panwar

BVSc & AH, MVSc,

Department of Animal Husbandry

Uttar Pradesh

Dr. Subhash Chander Ahlawat

BVSc & AH.

Department of Animal Husbandry

Haryana

**MANAGING COMMITTEE OF
INDIAN VETERINARY ASSOCIATION**

President :

Dr. Chirantan Kadian

Secretary General :

Dr. R.S. Patel

Treasurer :

Dr. I. Ponnu Pandian

Joint Secretary :

Dr. M.K. Srikanth

Vice Presidents :

Dr. L. Chandrasekaran, HQ, Tamilnadu

Dr. Arun Sirkeck, Himachal Pradesh

Dr. S.G. Yalagod, Karnataka

Dr. Ilang, Nagaland

Dr. Ramji Lal Meena, Rajasthan

Dr. Sudhir Kumar, Uttar Pradesh

Zonal Secretaries :

Dr. Amit Nain, Punjab

Dr. R. Vasantha Rayalu, Andhra Pradesh

Dr. Bhuban Ch. Sarmah, Assam

Dr. Umesh Balaji Sontakke, Maharashtra

Dr. Pankaj Kumar, Jharkhand

Managing Editor, IVJ :

Dr. S. Sukumar, Tamil Nadu

STATEMENT ABOUT OWNERSHIP AND OTHER PARTICULARS ABOUT NEWSPAPER

Indian Veterinary Journal

Form IV

See Rule 8

1. **Place of Publication** : Chennai
2. **Periodicity of its publication** : Monthly
3. **Printer's Name** : **Ln. N. Sathiyaseelan**
Nationality : Indian
Address : Angel Printing House, 11-Muthaiyal Street
Purasawalkam, Chennai - 600 007.
4. **Publiher's Name** : **Dr. S. Sukumar**
Nationality : Indian
Address : 11/7, Chamiers Road, Nandanam
Chennai – 600035.
5. **Editor Name** : **Dr. S. Sukumar**
Nationality : Indian
Address : 11/7, Chamiers Road, Nandanam
Chennai – 600035.
6. **Name and address of individuals who own the newspaper and partners** : Indian Veterinary Association

I, Dr S. Sukumar hereby declare that the particulars given above are true to the best of my knowledge and belief.

Sd/-

Chennai – 600035.
November 05, 2019

S. SUKUMAR
Publisher and Editor

THE INDIAN VETERINARY JOURNAL

(Official organ of the Indian Veterinary Association)

Vol. 96

November 2019

No. 11

CONTENTS

GENERAL ARTICLES :

Seasonal Variations on the Frequency of Normal Motile and Static Ejaculates and their Discard Rate in Murrah Buffalo Bulls Kanchan	... 09
Performance of Bali Cattle (<i>Bos Sondaicus</i>) Breeding Stock in Maliku District, Pulang Pisau Regency, Central Kalimantan Maria Haryulin Astuti	... 12
Enriching Cow Milk with Selenium through the Use of Selenoorganic Preparations Yuriy Nikolayevich Prytkov and Anna Aleksandrovna Kistina	... 15
Immunological and Morphological Indicators of Nonspecific Resistance in Laying Hens that Received the Vilomix Feed Additive Arman Sabyrzhanov, Orazali Mullakaev, Ildar Zalyalov, Evgeny Kirillov, Kaissar Kushaliyev and Abzal Kereyev	... 19
Identification and Morphological Characteristic of Ornamental Fish in Wongsorejo Beach, Banyuwangi, East Java, Indonesia Mohammad Faizal Ulkhaq, Annur Ahadi Abdillah, Daruti Dinda Nindarwi, Hapsari Kenconoajati, Darmawan Setia Budi, Suciyono and Muhammad Browijoyo Santanumurti	... 24
Antibiotic Resistance to <i>Staphylococcus aureus</i> and Methicillin Resistant <i>Staphylococcus aureus</i> (MRSA) Isolated from Dairy Farms in Surabaya, Indonesia Wiwiek Tyasningsih, Mustofa Helmi Effendi, Budiarto Budiarto and Indra Raja Syahputra	... 27
Detection of <i>Salmonella</i> on Chicken Meat Using Immunomagnetic Separation and Conventional Methods from Traditional Market in Surabaya, East Java, Indonesia Dhandy Koesoemo Wardhana, Muhammad Thohawi Elziyad Purnama, Ooi Hong Kean and Wiwiek Tyasningsih	... 31
Reconstruction of Circular Skin Defect with Single Pedicle Advancement Flap in a Dog M. Madeena Begum and V. Bhuvaneshwari	... 33
Efficiency of W Chromosome- Based Gender Determination in Japanese Quails Tamadhur H. Hussein, Mohammed Baqur S. Al-Shuhaib and Tahreer M. Al-Thuwaini	... 36
Carcass Quality of Broiler Supplemented with <i>Spirulina</i>, Kelor Leaves (<i>Moringa oliefera</i>), and Probiotic Herinda Pertwi, Romziah Sidik, Emy Koestanty Sabdoningrum and Tri Bhawono Dadi	... 39
Diagnosis of Single and Twin Pregnancy, and Early Embryo Mortality Through Progesterone Level Test on Local Does Wurlina, Imam Mustofa, Mas'ud Hariadi, Erma Safitri and Dewa Ketut Meles	... 42

Prevalence Study on Gastrointestinal Motility Disorders in Cattle Brought to Teaching Veterinary Hospital at Namakkal, Tamil Nadu	...	45
B.Sudhakara Reddy, G.Vijayakumar, S.Sivaraman, G.A.Balasubramaniam and S.Kathirvel		
Functional Specialization of Forelimb Muscles of Sloth Bear (<i>Melursus ursinus</i>)	...	47
V.R. Annie, Shruti., K.V. Jamuna., S.A. Arun., R.V. Prasad and V. Girishkumar		
Characterization and Identification of <i>Aeromonas salmonicida</i> subsp. <i>salmonicida</i> Isolated from Fresh Water Fish <i>Clarias batrachus</i>	...	50
Windi Andhini, Sudarno, Rahayu Kusdarwati and Rozi		
Improvement of Pregnancy Rate in Bali Cows with the Combination of Equine Chorionic Gonadotropine (eCG) from Local Pregnant Mare with PGF2α	...	52
Herry A. Hermadi, R.T.S. Adikara, Sunaryo H. Warsito and Erma Safitri		
Micro Anatomical Studies on the Moderator Band of Spotted Deer (<i>Axis axis</i>)	...	55
O.R.Sathyamoorthy, S.Ushakumary and M.Thangapandian		
Nano Spray Inhaler Ashitaba Leaf Extract (<i>Angelica keiskei</i>) on Malondialdehyde, Catalase Enzyme Activity and Lung Tissue Damage in Mice Exposed to Cigarette Smoke	...	58
Akhmad Afifudin Al-Anshori, Diah Ayu Retanti, Indah Trilestari, Lilik Maslachah and Hani Plumeriastuti		
Nematodosis Infection on <i>Monopterus albus</i> (Sybranchiformes: Sybranchidae) from Traditional Market in Banyuwangi, Indonesia	...	62
Dana Icha Bakti, Gunanti Mahasri, Muhammad Amin Alamsjah, Annur Ahadi Abdillah and Mohammad Faizal Ulkhaq		

CLINICAL AND FIELD ARTICLES :

Management of Penile Prolapse in Indian Tent Turtle (<i>Pangshura tentoriacircumdata</i>, Gray, 1834)	...	65
Animesh Talukdar, Gowri Mallapur, Syed Ainul Hussain and Parag Nigam		
Treatment of Generalised Demodicosis in a Dog Using a Single Oral Dose of Afoxolaner	...	66
P. Chansiripornchai and N. Chansiripornchai		
Intralipids for the Management of Ivermectin Toxicity in a Dog	...	68
M.Shiju Simon, A Methai, N. Pazhanivel and K. Krishnakumar		
Surgical Intervention for Perineal Cystocoele in a Cow	...	70
R.Thangadurai and M.Vijayakumar		
Cutaneous Haemangiosarcoma in a Pigeon and its Surgical Treatment	...	72
R. Uma Rani and N. Pazhanivel		
Successful Management of Multiple Infections in a Doe	...	74
P.Abinaya, D.Selvi, A.Abiramy, P.Vijayalakshmi, K.Rajkumar, N.Devadevi and S.Sivaprakash		
Clinical Laboratory Study of Dairy Cattle Infected by Blood Parasites	...	75
Wijaya Agus, Muchammad Yunus and Maylina Leni		

Author and Subject Index		78 & 79
---------------------------------	--	--------------------

Nano Spray Inhaler Ashitaba Leaf Extract (*Angelica keiskei*) on Malondialdehyde, Catalase Enzyme Activity and Lung Tissue Damage in Mice Exposed to Cigarette Smoke

Akhmad Afifudin Al-Anshori, Diah Ayu Retanti, Indah Trilestari, Lilik Maslachah¹ and Hani Plumeriastuti

Department of Basic Veterinary Medicine, Faculty of Veterinary Medicine, Universitas Airlangga, Surabaya, Indonesia 60116.

(Received : July, 2019 251/19 Accepted : July, 2019)

Abstract

A total of 30 mice were divided into 5 treatment groups. K1: control (-) group not exposed to cigarette smoke and not given nanospray inhalers. K2: control (+) group exposed to cigarette smoke and not given nanospray inhalers. P1, P2, and P3 The treatment group exposed to cigarette smoke for 28 days and given nanospray inhaler ashitaba leaf extract (*Angelica keiskei*) at a dose of 50 g / KgBB / day, 200 g / KgBB / day and 500 g / KgBB / day. Day 29 was given nanospray inhalers for 3 weeks, then Malondialdehyde (MDA), enzyme catalase activity were examined from serum and lung organs for pulmonary histopathology. The administration of 200 g / KgBB / day nanospray inhaler can reduce malondialdehyde levels, activation of the enzyme catalase, emphysema, inflammatory cell infiltration and the number of erythrocytes exposed to cigarette smoke.

Key words: Nano Spray Inhaler, Ashitaba Leaf Extract (*Angelica keiskei*), pulmonary histopathology.

Exposure of cigarette smoke can be dangerous for the human body due to increase in dangerous radicals in body thus the endogenous antioxidants were unable to neutralize, then leading to oxidative stress (Kurutas E.B, 2016). One of the biomarkers that most generally used to measure the degree of oxidative stress is Malondialdehyde (MDA), it is end product of lipid peroxidation (Moselhy *et al.*, 2013). Endogenous antioxidant defense systems against these changes do not benefit the body through enzymatic enhancement mechanisms such as

catalase, SOD and glutathione peroxidase) and non-enzymatic (albumin, uric acid). This lack of factors triggers oxidative stress that underlies the development of a number of diseases (Wojcik *M et al*, 2010).

One of the plants that have antioxidant properties is Ashitaba (Chavan *et al.*, 2016). Which contains chalcones, coumarins, flavonoids and polyphenols (Caesar and Cech, 2016). Chemical compounds of Ashitaba leaves have the potential as antioxidants 100 times potent than vitamin C and 25 times that of vitamin E.

Nanospray preparation from leaves of Ashitaba (*Angelica keiskei*) is given by inhalation to assess the influence of inhaler leaves of Ashitaba (*Angelica keiskei*) on Malondialdehyde (MDA), the activity of serum catalase and pulmonary histopathological changes due to cigarette smoke.

Materials and Methods

This study has got approval with certificate No. 1.KE.102.06.2018 by Animal Care and Use Committee on Veterinary Medicine Universitas Airlangga Surabaya Indonesia. Ashitaba (*Angelica keiskei*) is obtained from ashitaba garden in Trawas, Mojokerto, East Java, Indonesia. Ashitaba has got certificate No. 1297 from Overseas Merchandise Inspection CoLTD (OMIC).

The ashitaba leaves shade dried for 7 days by grinding, maceration and dried under shade for 3 days. Ashitaba leaf nanoparticle use comparison that extract: NaTPP: Chitosan is 1:1:6. 10 ml ashitaba leaf extract 5% mixed with 10 ml NaTPP 0,1% and then mixed 60 ml chito-

¹Corresponding author : Email : lilik.maslachah@yahoo.com

Table I. Malondialdehyde and catalase enzyme levels of mice serum exposed to cigarette smoke and treated with asitaba nanospray inhalers (*Angelica keiskei*) (Mean \pm SD)

Groups	Malondialdehyde counts	Catalase Enzyme
K1	37.50 ^b \pm 0.50	32.83 ^a \pm 10.50
K2	59.00 ^c \pm 2.00	110.34 ^b \pm 40.34
P1	72.75 ^d \pm 8.75	71.17 ^{ab} \pm 31.50
P2	12.00 ^a \pm 2.00	13.67 ^a \pm 1.00
P3	68.25 ^{cd} \pm 23.59	42.50 ^a \pm 5.50

Different superscript in the same column indicated very significantly different (P<0.05)

Table II. The pulmonary histopathological changes of mice exposed to cigarette smoke treated with asitaba leaf nanospray inhaler (*Angelica keiskei*)

Groups	Mean scoring of emphysema	Mean scoring of Inflammatory cell infiltration	Mean scoring of Erythrocyte Amount
K1	3.80 ^d	11.40 ^{ab}	17.10 ^{ab}
K2	17.70 ^{ab}	20.50 ^{ab}	17.80 ^{ab}
P1	21.70 ^a	11.70 ^{ab}	11.00 ^{ab}
P2	10.70 ^c	6.50 ^c	7.80 ^{cd}
P3	11.10 ^{bc}	14.90 ^{ab}	7.88 ^{cd}

Different superscript in the same column indicated very significantly different (P<0.05)

san 0,2%. The material mixed and sonication with sonicator machine for 60 min at frequency 20 kHz and freeze dried (Stoica *et al.*,2013).

The mice were exposed to commercial smoke is Marlboro® cigarettes (13 mg tar and 1,0 mg nicotine) per day for 28 days using a smoking box. A smoking box has a size 30 cm long, 20 cm wide, and 15 high with 8 holes. The animals were maintained in this smoke-filled air condition (\pm 3%) for 6 min, this procedure was repeated daily (Triana *et al.*,2013).

A total of 30 animals were divided into 5 treatment groups, namely K1: the (-) control group that was not exposed to cigarette smoke and not given the nanospray inhaler. K2: (+) control group exposed to cigarette smoke and not given nanospray inhalers. P1, P2, and P3 are the treatment groups exposed to cigarette smoke for 28 days and given nanospray inhalers asitaba leaf extract (*Angelica keiskei*) with a dose P1. 50 g / KgBB /day, P2 = 200 g / KgBB / day, P.3 = 500 g / KgBB / day. On day 29 was given a nanospray inhaler for 3 minutes. Then intra-peritoneally treated with 0.1 ml of ketamine

injection, heart blood is collected to assess. Thiobarbituric acid reactive substance (TBARS) examination of Malondialdehyde (MDA) (Reilly, *et al* 1991; Konig, *et al loc. cit*) and catalase by the assay enzyme activity based on the rate of hydrogen peroxide / ammonium molybdate complex formation and pulmonary organs for histopathology with stained examination under a light microscope with 1000 times magnification to see changes in alveolar emphysema, inflammatory cell infiltration, and erythrocyte infiltration (Yang *et al*, 2008). Data on the results of the study were analyzed by one-way ANOVA. If there is a difference, continue with the test using SPSS® 22.

Results and Discussion

The results of malondialdehyde levels in mice exposed to cigarette smoke and without given Ashitaba leaf nanospray inhaler (K2) showed an increase compared to the control group without cigarette exposure treatment. Cigarette smoke contains free radicals that can oxidize lipids, proteins and carbohydrate molecules, damage cell membranes and DNA that affect

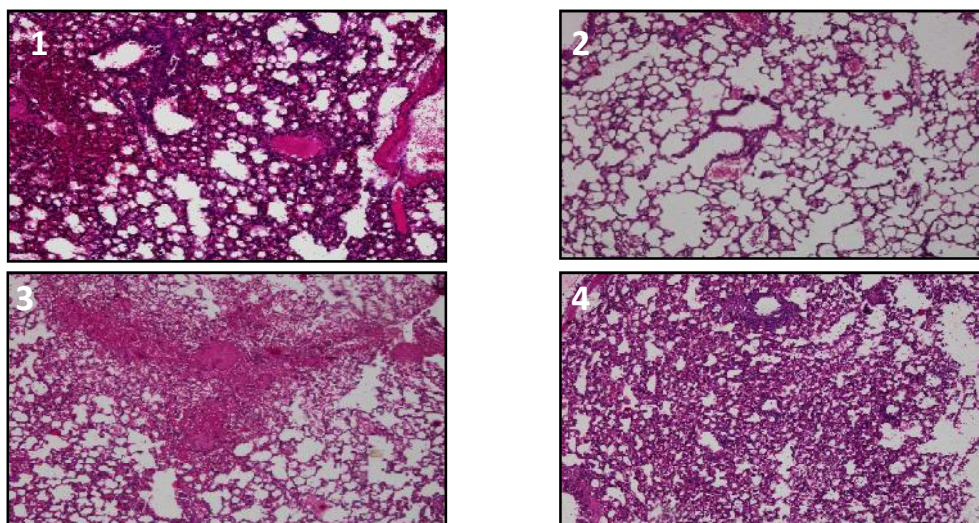


Fig 1. Results of lung organ histopathology changes of mice exposed to cigarette smoke 1) pneumonia, 2) emphysema, 3) hemorrhage, 4) atelectasis.

cell structure and function. Membrane cells rich in sources of polyunsaturated fatty acids that are easily oxidized by free radicals cause lipid peroxidation (Khushdeep *et al.*, 2013). MDA is the final product of lipid peroxidation by free radicals, the increase in MDA concentration shows an increase in free radicals in the body, so an increase in MDA levels as an oxidative stress marker in groups exposed to cigarette smoke (Kahnamoei *et al.*, 2014 and Safyudin and Subandrate, 2016). who were exposed to cigarette smoke and were given the Ashitaba leaf nanospray inhaler dose of 200 g / KgBB / day, showed a decrease in the level of malondialdehyde compared with all groups treated with exposure to cigarette smoke (P1, P2, P3). (Table I). Ashitaba leaves contain flavonoids, polyphenols, and carotenoids that can improve antioxidant status in humans, so as to reduce free radicals due to exposure to cigarette smoke.

The average results of catalase enzyme activity in the control group exposed to cigarette smoke that were not given Ashitaba leaf nanospray inhaler showed an increase compared to the treatment group exposed to cigarette smoke and given nanospray inhaler ashitaba leaf extract, while in the control group that was not exposed to cigarette smoke and not given nanospray inhaler ashitaba leaf extract (K1) with the treatment group exposed to cigarette

smoke and given nanospray inhaler ashitaba leaf extract dose of 200 g / KgBB / day, and 500 g / KgBB / day (P2, P3) showed a decrease (Table I). This result is consistent with the research of Ignatowicz *et al.*, 2013. Catalase is an important element in the antioxidant defense system and oxidative reaction reducer. Increased catalase activity is a parameter that shows organ reactivity in xenobiotics such as cigarette smoke.

The average score of histopathological changes in pulmonary emphysema, inflammatory cell infiltration and the number of erythrocytes showed a decrease in the K1 control group and the treatment was given nanospray inhaler ashitaba leaf extract dose of 200 g / KgBB / day. (Fig 1 and Table II) These results indicate that exposure to cigarette smoke causes oxidative stress that affects the cellular antioxidant defense system which can induce lung tissue apoptosis, inflammation and tissue damage that can be prevented by giving antioxidants (Al-Awaida *et al.*, 2014 and Nagaraj *et al.*, 2014).

Summary

The administration of a 200 g / KgBB / day nanospray inhaler can reduce malondialdehyde levels, the activity of the catalase enzyme also decreases emphysema, and infiltrates the lung inflammation cells of mice exposed to cigarette smoke.

References

- Al-Awaida W, Akash M, Aburubaiha Z, Talib WH, and Shehadeh H. (2014) Chinese Green Tea (Lung Chen) Consumption Reduces Oxidative Stress, Inflammation And Tissues Damage In Smoke Exposed Rats. *Iran J Basic Med Sci Vol* **17**:740-746.
- Caesar L.K. and Cech N.B., (2016) A review of the medicinal uses and pharmacology of Ashitaba, *Planta Medica*, **82** (14) : 1236–1245.
- Camila R and Correa, C-Y. (2014) Oliver Chen, Giancarlo Aldini, Helen Rasmussen, Carlos F Ronchi, Carolina Berchieri-Ronchi¹, Soo-Muk Cho, Jeffrey B Blumberg, and Kyung-Jin Yeum. Bioavailability of plant pigment phytochemicals in Angelicakeiskei in older adults: A pilot absorption kinetic study. *Nutrition Res. and Practice* **8**(5):550-557.
- Chavan B.B., Gadekar A.S., Mehta P.P., Vawhal P.K., Kolsure A.K., and Chabukswar A.R., (2016) Synthesis and Medicinal Significance of Chalcones. *Asian J. of Biomedical and Pharmaceutical Sci.*, 2015 : 6-7.
- Kahnamoei, J.R., F. Maleki, M.R. Nasirzadeh, and F. Kishizadeh. (2014) The Effects of Cigarette Smoking on Plasma MDA And TAC in Univesity Students. *Bulletin of Environ., Pharma. and Life Sci.* 3:95-98
- Khushdeep SA, Naveenta G, Ruchika G and Harpreet K. (2013) Comparative study of oxidative stress in cigarette and bidi smokers. *International J. of Basic an Applied Medical Sci.* **3**(1):147-151.
- Konig D, and Berg A. (2002) Exercise and Oxidative Stress: is there a need for additional antioxidant. *Osterreichisches J Fur Sportmedizin.* **3**: 6-15.
- Moselhy HF, Reid RG, Yousef S, and Boyle Sp. (2013) A specific, accurate, and sensitive measure of total plasma malondialdehyde by HPLC. *J. of lipid Research* **54**(3):852-858.
- Nagaraj, Satish Kumar D, and Prashant V Paunipagar. (2002) Study of serum malondialdehyde and vitamin c in smokers. *J.of Sci. and Innovative Res.* **3**(6): 569-571.
- Reilly PM, Schiller HJ, and Bulkley GB. (1991) Pharmacologic Approach to Tissue Injury Mediated By Free Radical And Other Reactive Oxygen Metabolites. *Am J Surg* **161**:488-502.
- Reiser J and Warner JO. (1986) Inhalation Treatment for Asthma. *Arch Dis Child.* **61**:88-94.
- Safyudin and Subandrate. (2016) Smoking Tends to Decrease Glutathione and Increase Malondialdehyde Levels in Medical Students. *Universa Medicina.* **35**(2): 89-95.
- Stoica R., omoghi R., and Ion R.M. Preparation of chitosan-tripolyphosphate nanoparticles the encapsulation of polyphenols extracted from rose hips. *Dig. J. Nanomater. Biostruct.* **8**:955–963
- Triana N, dkk. (2013) Gambaran Histologis Pulmo Mencit Jantan (Mus Musculus L.) Setelah Dipapari Asap Rokok Elektrik. Skripsi : Universitas Sumatera Utara.
- Wojcik M, Burzynska-Pedziwiatr I. and Wozniak LA (2010) A review of natural and synthetic antioxidants important for health and longevity. *Curried Chem*, **17** : 3262–3288.
- Yang Y. L., Tang G. J., Wu Y. L., dan Yien W. H., Lee T.S., and Kou Y. R. (2008) Exacerbation of wood smoke-induced acute lung injury by mechanical ventilation using moderately high tidal volume in mice. *Respiratory Physiology & Neurobiology* **160** : 99–108.

AUTHOR INDEX

Abinaya, P.	74	Darmawan Setia Budi,	24	Rahayu Kusdarwati,	50
Abiramy, A.	74	Herinda Pertiwi,	39	Rajkumar, K.	74
Abzal Kereyev,	19	Herry A. Hermadi,	52	Romziah Sidik,	39
Adikara, R.T.S.	52	Ildar Zalyalov,	19	Rozi,	50
Akhmad Afifudin Al-Anshori,	58	Imam Mustofa,	42	Sathyamoorthy,O.R.	55
Animesh Talukdar,	65	Indah Trilestari,	58	Selvi, D.	74
Anna Aleksandrovna Kistina,	15	Indra Raja Syahputra,	27	Shiju Simon, M.	68
Annie,V.R.	47	Jamuna, K.V.	47	Shruti,	47
Annur Ahadi Abdillah,	24, 62	Kanchan,	09	Sivaprakash, S.	74
Arman Sabyrzhanov,	19	Kathirvel, S.	45	Sivaraman, S.	45
Arun, S.A.	47	Krishnakumar,K.	68	Suciyono,	24
Balasubramaniam,G.A.	45	Lilik Maslachah,	58	Sudarno,	50
Bhuvaneshwari,V.	33	Madeena Begum,M.	33	Sudhakara Reddy, B.	45
Budiarto Budiarto,	27	Maria Haryulin Astuti,	12	Sunaryo H. Warsito,	52
Chansiripornchai,N.	66	Mas'ud Hariadi,	42	Syed Ainul Hussain,	65
Chansiripornchai,P.	66	Maylina Leni,	75	Tahreer M. Al-Thuwaini,	36
Dana Icha Bakti,	62	Methai, A.	68	Tamadhur H. Hussein,	36
Daruti Dinda Nindarwi,	24	Mohammad Faizal Ulkhaq,	24,62	Thangadurai,R.	70
Devadevi, N.	74	Mohammed Baqur S.		Thangapandian, M.	55
Dewa Ketut Meles,	42	Al-Shuhaib,	36	Tri Bhawono Dadi,	39
Dhandy Koesoemo Wardhana,	31	Muchammad Yunus,	75	Uma Rani,R.	72
Diah Ayu Retanti,	58	Muhammad Amin Alamsjah,	62	Ushakumary, S.	55
Emy Koestanty		Muhammad Browijoyo		Vijayakumar,G.	45
Sabdoningrum,	39	Santanumurti,	24	Vijayakumar,M.	70
Erma Safitri,	42, 52	Muhammad Thohawi Elziyad		Vijayalakshmi, P.	74
Evgeny Kirillov,	19	Purnama,	31	Wijaya Agus,	75
Kaissar Kushaliyev,	19	Mustofa Helmi Effendi,	27	Windi Andhini,	50
Girishkumar, V.	47	Ooi Hong Kean,	31	Wiwiek Tyasningsih,	27, 31
Gowri Mallapur,	65	Orazali Mullakaev,	19	Wurlina,	42
Gunanti Mahasri,	62	Parag Nigam,	65	Yuriy Nikolayevich Prytkov,	15
Hani Plumeriastuti,	58	Pazhanivel,N.	68, 72		
Hapsari Kenconoajati,	24	Prasad, R.V.	47		

THE INDIAN VETERINARY JOURNAL

Vol. 96

November 2019

No. 11

SUBJECT INDEX

Anatomy and Histology		Vilomix in Feed and Nonspecific Resistance in Layers...	19
Forelimb Muscles of Sloth Bear...	47	Carcass Quality of Broiler Supplemented with Spirulina...	39
Moderator Band of Spotted Deer...	55		
Bacteriology and Microbiology		Pathology and Parasitology	
Vilomix in Feed and Nonspecific Resistance in Layers...	19	<i>Salmonella</i> on Chicken Meat...	31
Antibiotic Resistance to <i>Staphylococcus aureus</i> ...	27	Nematodosis Infection on <i>Monopterus albus</i> ...	62
<i>Salmonella</i> on Chicken Meat...	31	Dairy Cattle Infected by Blood Parasites...	75
Isolation of <i>salmonicida</i> from Fresh Water Fish...	50		
Cattle and Buffaloes		Pharmacology and Toxicology	
Normal and Static Ejaculates - Buffalo Bulls...	9	Intralipids for Ivermectin Toxicity in a Dog...	68
Performance of Bali Cattle...	12		
Enriching Cow Milk with Selenium...	15	Piggery and Poultry Science	
Antibiotic Resistance to <i>Staphylococcus aureus</i> ...	27	Gender Determination in Japanese Quails...	36
Gastrointestinal Motility Disorders in Cattle...	45	Carcass Quality of Broiler Supplemented with Spirulina...	39
Improvement of Pregnancy Rate in Bali Cows...	52	Haemangiosarcoma in a Pigeon...	72
Perineal Cystocoele in a Cow...	70		
Dairy Cattle Infected by Blood Parasites...	75	Surgery and Clinical	
Fisheries		Reconstruction of Circular Skin Defect in dog...	33
Morphology of Ornamental Fish...	24	Single and Twin Pregnancy and Embryo Mortality in Does...	42
Nematodosis Infection on <i>Monopterus albus</i> ...	62	Gastrointestinal Motility Disorders in Cattle...	45
		Improvement of Pregnancy Rate in Bali Cows...	52
Goats and Sheep		Ashitaba Leaf Extract Tissue Damage due to Cigarette Smoke...	58
Single and Twin Pregnancy and Embryo Mortality in Does...	42	Nematodosis Infection on <i>Monopterus albus</i> ...	62
Multiple Infections in a Doe...	74	Afoxolaner for Demodicosis in Dog...	66
		Intralipids for Ivermectin Toxicity in a Dog...	68
Laboratory Animals		Perineal Cystocoele in a Cow...	70
Ashitaba Leaf Extract Tissue Damage due to Cigarette Smoke...	58	Haemangiosarcoma in a Pigeon...	72
		Multiple Infections in a Doe...	74
Nutrition		Wildlife Science	
Enriching Cow Milk with Selenium...	15	Forelimb Muscles of Sloth Bear...	47

**FIRST TIME IN THE WORLD, INCREASE THE IMMUNITY WITHIN
15 DAYS OF TREATMENT**

KIT:- Introduced to the Nation and Abroad as a KAYAKALP and to REJUVANTE YOU YOURSELF PART 1,2,3 (without money and medicine) + 20 URINE TEST STRIPS + TONIC BHASMA.

Prevent entry of disease into the body, and if already present shall cure it.

DISEASE : Useful in Skin disease, Allergy, Rheumatism, Diabetics, Cholesterol, Blood Pressure, Vein blockage, Urinary diseases, Cancer, AIDS etc.

Transfer a sum of Rs. 300/- and SMS your Name & Address (with pin code) to,

SARLA PANDIT, DENA BANK, CANAL ROAD BRANCH, RAJKOT.

A/c. No. 019610002161

IFC:BKDNO310196

There were about 300 printed copies of lectures delivered to the Nation and world over. Please get the advantage of it.

We will provide the Health Kit to all the health workers in every districts at a discounted cost. The amount collected will be utilized for the Nation Building on health grounds.

Note : The above said medication in the kit was used by about 44 patients suffering from AIDS and 29 of them responded that they feel better after taking these medicine.

With Health, Mind, Wealth
Life as National Devotee for Health Care.

Dr. Harshad Pandit, (M.V.Sc, Medicine)

Mobile # 94282 99637
Email : drharshadpandit@gmail.com