



Source details

Bali Medical Journal

Scopus coverage years: from 2019 to 2022

Publisher: Sanglah General Hospital

ISSN: 2089-1180 E-ISSN: 2302-2914

Subject area: Medicine: General Medicine

Source type: Journal

CiteScore 2021

0.1



SJR 2021

0.109



SNIP 2021

0.139



[View all documents >](#) [Set document alert](#) [Save to source list](#) [Source Homepage](#)

[CiteScore](#) [CiteScore rank & trend](#) [Scopus content coverage](#)

i Improved CiteScore methodology ✕

CiteScore 2021 counts the citations received in 2018-2021 to articles, reviews, conference papers, book chapters and data papers published in 2018-2021, and divides this by the number of publications published in 2018-2021. [Learn more >](#)

CiteScore 2021 ▼

0.1 = $\frac{33 \text{ Citations 2018 - 2021}}{441 \text{ Documents 2018 - 2021}}$

Calculated on 05 May, 2022

CiteScoreTracker 2022 ⓘ

0.2 = $\frac{176 \text{ Citations to date}}{889 \text{ Documents to date}}$

Last updated on 05 April, 2023 • Updated monthly

CiteScore rank 2021 ⓘ

Category	Rank	Percentile
Medicine		
General Medicine	#791/826	4th

[View CiteScore methodology >](#) [CiteScore FAQ >](#) [Add CiteScore to your site](#)



Bali Medical Journal

COUNTRY

Indonesia



Universities and research institutions in Indonesia



Media Ranking in Indonesia

SUBJECT AREA AND CATEGORY

Medicine
Medicine (miscellaneous)

PUBLISHER

Sanglah General Hospital

H-INDEX

4

PUBLICATION TYPE

Journals

ISSN

20891180, 23022914

COVERAGE

2020-2022

INFORMATION

[Homepage](#)

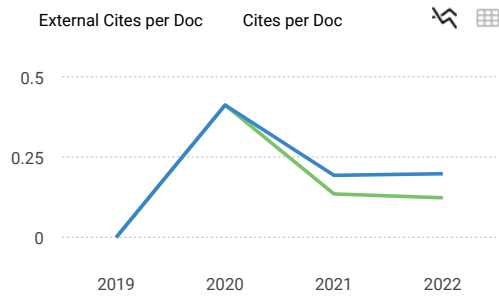
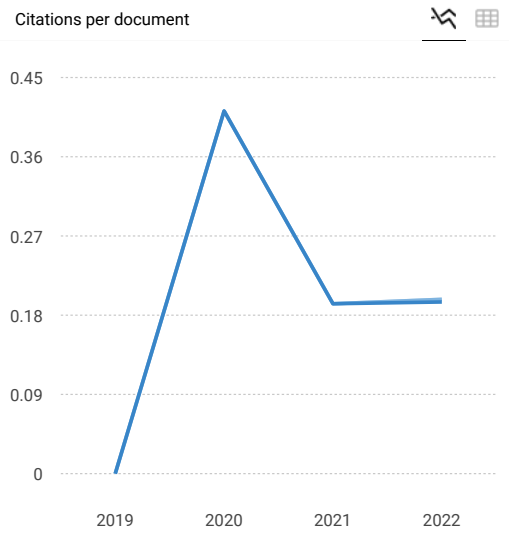
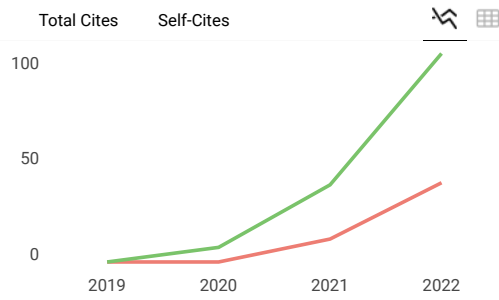
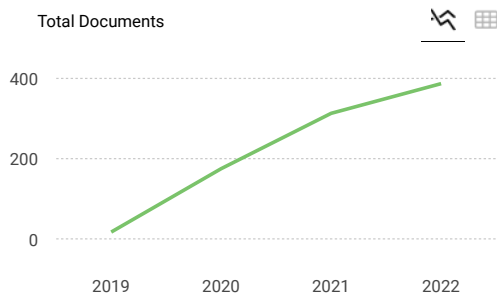
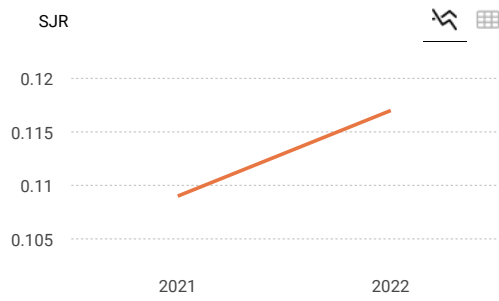
[How to publish in this journal](#)

srimaliawan@unud.ac.id

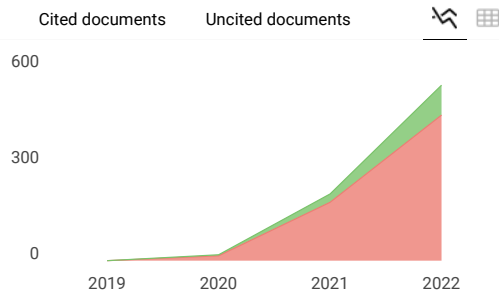
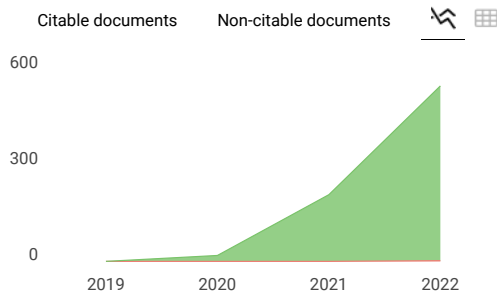
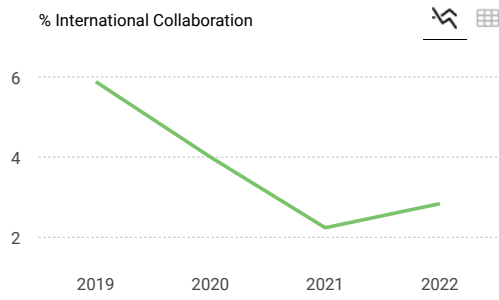
SCOPE

Bali Med. J. is open access, peer-reviewed journal aiming to communicate high-quality research articles, reviews, and general articles in the field. Bali Med. J. publish articles that encompass all aspects of basic research/clinical studies related to medical sciences. The Journal aims to bridge and integrate the intellectual, methodological, and substantive medical scholarship diversity and encourage a vigorous dialogue between medical scholars and practitioners.

 [Join the conversation about this journal](#)



- Cites / Doc. (4 years)
- Cites / Doc. (3 years)
- Cites / Doc. (2 years)



Bali Medical Journal ← Show this widget in your own website

Q4

Medicine (miscellaneous)

best quartile

SJR 2022
0.12

powered by scimagojr.com

Just copy the code below and paste within your html code:
 <a href="https://www.scimagojr.com"

SCImago Graphica

Explore, visually communicate and make sense of data with our [new data visualization tool](#).



Home (<https://www.balimedicaljournal.org/index.php/bmj/index>) > Archives (<https://www.balimedicaljournal.org/index.php/bmj/issue/archive>) > Vol. 11 No. 3 (2022): (Available online : 1 December 2022)

Vol. 11 No. 3 (2022): (Available online : 1 December 2022)

ORIGINAL ARTICLE

Transcortical selective amygdalohippocampectomy for intractable mesial temporal lobe epilepsy: a review of outcomes in a single center (<https://www.balimedicaljournal.org/index.php/bmj/article/view/3475>)

Aris Catur Bintoro, Muhamad Thohar Arifin, Harsono, Amin Husni, Surya Pratama Brilliantika, Yuriz Bakhtiar, Novita Ikbar Khairunnisa, Rofat Askoro, Jacob Bunyamin, Soeharyo Hadisapurto, Zainal Muttaqin

Online First: Nov 1, 2022 |

 Abstract

 pdf (<https://www.balimedicaljournal.org/index.php/bmj/article/view/3475/2293>)

ORIGINAL ARTICLE

The effect of syzygium polyanthum (wight) extract in histological changes of kidney in diabetic mice model (<https://www.balimedicaljournal.org/index.php/bmj/article/view/3545>)

David Sajid Muhammad, Hotimah Masdan Salim, Cici Dita Virlliana, Adyan Donastin, Agus Aan Adriansyah

Online First: Sep 28, 2022 |

 Abstract

 pdf (<https://www.balimedicaljournal.org/index.php/bmj/article/view/3545/2253>)



ORIGINAL ARTICLE

Physical fitness assessment for lower limb disability: rationale and design to develop a new formula
(<https://www.balimedicaljournal.org/index.php/bmj/article/view/3520>)

Endang Ernandini, Trevino Aristarkus Pakasi, Dewi Irawati Soeria Santoso, Damayanti Tinduh, Listya Tresnanti Mirtha, Sally Aman Nasution, Anita, Nury Nudwinuringtyas

Online First: Sep 23, 2022 |

 Abstract

 pdf (<https://www.balimedicaljournal.org/index.php/bmj/article/view/3520/2267>)

ORIGINAL ARTICLE

Transcatheter aortic valve implantation: A review article (<https://www.balimedicaljournal.org/index.php/bmj/article/view/3571>)

Starry Homenta Rampengan, Jansen Chitrahadinata

Online First: Sep 5, 2022 |

 Abstract

 pdf (<https://www.balimedicaljournal.org/index.php/bmj/article/view/3571/2192>)

ORIGINAL ARTICLE

Histopathology of colorectal cancer in Cut Meutia Hospital, Aceh-Indonesia from 2017-2020 (<https://www.balimedicaljournal.org/index.php/bmj/article/view/3750>)

Muhammad Sayuti, Muhammad Syahriza, Ghisca Chairiyah Ami

Online First: Nov 28, 2022 |

 Abstract

 pdf (<https://www.balimedicaljournal.org/index.php/bmj/article/view/3750/2353>)

ORIGINAL ARTICLE

Correlation of S100B level and postoperative cognitive dysfunction (POCD) events among patients with ear, nose and throat (ENT) surgeries with controlled hypotension (<https://www.balimedicaljournal.org/index.php/bmj/article/view/3847>)

Boby Abdul Rahman, Prananda Surya Airlangga, Andy Nauman Saputra, Prihatma Kriswidyatomo, Agustina Salinding, Hamzah, Maulidya, Muhtarum Yusuf

Online First: Dec 1, 2022 |

 Abstract

 pdf (<https://www.balimedicaljournal.org/index.php/bmj/article/view/3847/2374>)

ORIGINAL ARTICLE

Granulocyte colony-stimulating factor therapy as a bridging treatment for pediatric decompensated liver cirrhosis prior to liver transplantation: an open-label randomized clinical trial (<https://www.balimedicaljournal.org/index.php/bmj/article/view/3527>)

Tri Hening Rahayatri, Alida Harahap, Aryono Hendarto, Hanifah Oswari, Rianto Setiabudy, Akmal Taher

Online First: Sep 23, 2022 |

 Abstract

 pdf (<https://www.balimedicaljournal.org/index.php/bmj/article/view/3527/2236>)



ORIGINAL ARTICLE

Brazilian propolis wax as an anti-type-IV-hypersensitivity agent in metal bracket orthodontic treatment (<https://www.balimedicaljournal.org/index.php/bmj/article/view/3583>)

Grahita Aditya, Oedijani Santoso, Lisyani Budipradigdo Suromo

Online First: Dec 30, 2022 |

 Abstract

 pdf (<https://www.balimedicaljournal.org/index.php/bmj/article/view/3583/2592>)

ORIGINAL ARTICLE

Fibrin glue as a novel therapy for contracted socket in comparison to mitomycin-c and triamcinolone acetonide at Dr. Soetomo General Academic Hospital, Surabaya, Indonesia (<https://www.balimedicaljournal.org/index.php/bmj/article/view/3687>)

Firda Ayu Muthie, Evelyn Komaratih, Sutjipto, Dyah Fauziah, Budi Utomo

Online First: Nov 7, 2022 |

 Abstract

 pdf (<https://www.balimedicaljournal.org/index.php/bmj/article/view/3687/2303>)

ORIGINAL ARTICLE

The sensitivity pattern of ciprofloxacin and amoxicillin in chronic suppurative otitis media (<https://www.balimedicaljournal.org/index.php/bmj/article/view/3756>)

Lilis Suryani, Asti Widuri, Muhammad Kurniawan, Bombong Nurpagino

Online First: Nov 15, 2022 |

 Abstract

 pdf (<https://www.balimedicaljournal.org/index.php/bmj/article/view/3756/2332>)

ORIGINAL ARTICLE

The relationship of psychosocial problems to the severity of psoriasis vulgaris (<https://www.balimedicaljournal.org/index.php/bmj/article/view/3855>)

Flora Marlita Lubis, Riana Miranda Sinaga

Online First: Dec 31, 2022 |

 Abstract

 pdf (<https://www.balimedicaljournal.org/index.php/bmj/article/view/3855/2594>)


ORIGINAL ARTICLE

Clinical and laboratory comparison between End-Stage Kidney Disease patients with and without COVID-19: a cross-sectional study in a top referred hospital of West Nusa Tenggara (<https://www.balimedicaljournal.org/index.php/bmj/article/view/3440>)

I Gede Yasa Asmara, I Gusti Ngurah Ommy Agustriadi, I Made Sujaya, Salim Said Thalib, Rina Lestari, Suryani Padua Fatrullah, Komang Sri Rahayu Widiarsari, Indana Eva Ajmala, Metta Octora

Online First: Sep 5, 2022 |

 Abstract

 pdf (<https://www.balimedicaljournal.org/index.php/bmj/article/view/3440/2268>)



ORIGINAL ARTICLE

Anti-inflammatory effects and potential mechanisms of *Mitragyna speciosa* methanol extract on λ -karagenan-induced inflammation model (<https://www.balimedicaljournal.org/index.php/bmj/article/view/3535>)

Hotimah Masdan Salim, Choirotussanijjah, Evi Sylvia Awwalia, Ilham Putera Alam

Online First: Sep 13, 2022 |

 Abstract

 pdf (<https://www.balimedicaljournal.org/index.php/bmj/article/view/3535/2255>)

ORIGINAL ARTICLE

Calming effect of Javanese Handwriting Calligraphy, preliminary study based on neuroaesthetics (<https://www.balimedicaljournal.org/index.php/bmj/article/view/3598>)

Arman Yurisdadi Saleh, Miky Miky Endro Santoso, Wawan Murwantara, Retno Yulianti, Imam Prabowo

Online First: Dec 19, 2022 |

 Abstract

 pdf (<https://www.balimedicaljournal.org/index.php/bmj/article/view/3598/2424>)

ORIGINAL ARTICLE

High maternal homocysteine (Hcy) levels as a risk factor of preterm labor: a case-control study (<https://www.balimedicaljournal.org/index.php/bmj/article/view/3701>)

Anak Agung Gede Putra Wiradnyana, Anak Agung Ngurah Jaya Kusuma, Tjokorda Gde Agung Suwardewa, Anom Suardika, Made Bagus Dwi Aryana, Nyoman Gede Budiana, Putu Doster Mahayasa, IP Popy Kusuardiyanto

Online First: Dec 31, 2022 |

 Abstract

 pdf (<https://www.balimedicaljournal.org/index.php/bmj/article/view/3701/2593>)

ORIGINAL ARTICLE

Body image and the level of stress in cervical cancer patients (<https://www.balimedicaljournal.org/index.php/bmj/article/view/3769>)

Sri Rejeki, Eka Agustyaningrum, Macmudah, Nikmatul Khayati, Tri Hartiti, Dwi Nur Rahmantika Puji Safitri, Yanuan Ben Olina

Online First: Nov 26, 2022 |

 Abstract

 pdf (<https://www.balimedicaljournal.org/index.php/bmj/article/view/3769/2347>)

ORIGINAL ARTICLE

Regenerative alveolar bone in dental sockets of diabetic wistar rats post tooth extraction (<https://www.balimedicaljournal.org/index.php/bmj/article/view/3874>)

Nanik Zubaidah, Muhammad Luthfi, Wisnu Setyari, Retno Palupi, Nur Imamatul Ummah, Ardyta Lintang Maheswari, Arif Rahman Nurdianto, Fathillah Abdul Razak

Online First: Nov 25, 2022 |

 Abstract

 pdf (<https://www.balimedicaljournal.org/index.php/bmj/article/view/3874/2331>)



EDITORIAL

The 1st Airlangga International Endodontic Symposium 2022 (<https://www.balimedicaljournal.org/index.php/bmj/article/view/3879>)

Dian Agustin Wahjuningrum

Online First: Nov 8, 2022 |

 Abstract

 pdf (<https://www.balimedicaljournal.org/index.php/bmj/article/view/3879/2296>)



WEB OF SCIENCE™

(https://mjl.clarivate.com/search-results?issn=2089-1180&hide_exact_match_fl=true&utm_source=mjl&utm_medium=share-by-link&utm_campaign=search-results-share-this-journal)



ELSEVIER
Scopus

(<https://www.scopus.com/sourceid/21101024217>)

DOAJ
DIRECTORY OF
OPEN ACCESS
JOURNALS

(<https://doaj.org/toc/2302-2914>)




(<https://sinta3.kemdikbud.go.id/journals/profile/2513>)

Full Indexing List (<https://balimedicaljournal.org/index.php/bmj/pages/view/indexing>)

In Press (<https://balimedicaljournal.org/index.php/bmj/issue/view/30>)

Submit An Article (<https://balimedicaljournal.org/index.php/bmj/login>)

Scopus Citedness (<https://balimedicaljournal.org/index.php/bmj/pages/view/scopus>)




(http://clustrmaps.com/site/1a4xh?utm_source=globe)





(<https://balimedicaljournal.org/index.php/bmj/>)



 Bali Medical Journal, Bali-Indonesia

 62 (0369) 225206

 62 (0369) 225206

 administrator@balimedicaljournal.org (mailto:administrator@balimedicaljournal.org)

Contact (/index.php/bmj/pages/view/contact)

Journal Information (/index.php/bmj/pages/view/journalinfo)

Editorial Board (/index.php/bmj/pages/view/editorialboard)

Abstracting & Indexing (/index.php/bmj/pages/view/indexing)

Privacy Statement (<http://discoversys.ca/privacy.html>)

Home (/index.php/bmj/index)

Last Issue (/index.php/bmj/issue/current)

Archive (/index.php/bmj/issue/archive)

Author Guidelines (/index.php/bmj/pages/view/authorguidelines)

Open-Access Licence (/index.php/bmj/pages/view/OALicence)

Copyright © 2008-2022 DiscoverSys Inc (<http://discoversys.ca/>). All rights reserved.

 (<http://creativecommons.org/licenses/by-nc-nd/4.0/>)  (<http://www.crossref.org/citedby/index.html>)  (<http://www.crossref.org/>)  Open Access
(<http://discoversys.ca/privacy.html>)  No Fee (<http://discoversys.ca/privacy.html>)  **ROME**O (<http://www.sherpa.ac.uk/romeo/pub/1931/>)  **OCLC** (<https://oclc.org/>)
 **W3C HTML 4.1** (<http://jigsaw.w3.org/css-validator/validator>)  **W3C CSS** (<http://the-acap.org/acap-enabled.php>)  **ACAP ENABLED** (<http://the-acap.org/acap-enabled.php>)

[Home \(https://www.balimedicaljournal.org/index.php/bmj/index\)](https://www.balimedicaljournal.org/index.php/bmj/index) > Editorial Board & Reviewer

Editor-in-Chief

Prof. Dr. Sri Maliawan, SpBS (http://www.baliroyalhospital.co.id/halaman_staff.php?detail=229)

(Scopus ID (<https://www.scopus.com/authid/detail.uri?authorId=15738530400>)), (Google scholar (<https://scholar.google.co.id/citations?user=qVJ57aYAAA&hl=id>))

srimaliawan@unud.ac.id / maliawans@yahoo.com

Department of Neuro Surgery, Udayana University

Sanglah General Hospital

Bali - Indonesia

Associate Editor

Prof. Putra Manuaba, M.Phil (<http://profpuma.weebly.com/>)

(Scopus ID (<https://www.scopus.com/authid/detail.uri?authorId=8412278400>)), (Google Scholar (<https://scholar.google.com/citations?user=jnmT14kPWN&hl=en>))

putramanuaba@unud.ac.id / putramanuaba28@yahoo.com

Biomedicine Postgraduate Program, Udayana University

Bali - Indonesia

Prof. Ketut Suwiyoga, SpOG (<http://www.scopus.com/results/authorNamesList.url?sort=count-f&src=al&sid=01CAC4E9A2FB056A0A90221C03EC65FE.FZg2ODcjC9ArCe8WOZPvA%3a360&sot=al&sdt=al&sl=34&s=AUTH--LAST--NAME%28EQUALS%28Suwiyoga%29%29&st1=Suwiyoga&orcidId=&selectionPageSearch=anl&reselectAuthor=false&activeFlag=false&showDocument=false&resultsPerPage=20&offset=1&jtp=false¤tPage=1&previousSelectionCount=0&tooManySelections=false&previousResultCount=0&authSubject=LFSC&authSubject=HLSC&authSubject=PHSC&authSubject=SOSC&exactAuthorSearch=true&showFullList=false&authorPreferredName=&origin=searchauthorfreelookup&affiliationId=&txGid=01CAC4E9A2FB056A0A90221C03EC65FE.FZg2ODcjC9ArCe8WOZPvA%3a36>)

(Scopus ID (<https://www.scopus.com/authid/detail.uri?authorId=54080784800>))

suwiyoga@unud.ac.id

Faculty of Medicine, Udayana University, Sanglah Hospital Denpasar, Bali-Indonesia

Editorial Board for Regional America

Ankit Sakhuja, M.B.B.S., F.A.C.P., F.A.S.N. (http://www.med.umich.edu/intmed/nephrology/STAFF/sakhuja_a1.htm)

(Scopus ID (<http://www.scopus.com/authid/detail.uri?authorId=16744977200>))

asakhuja@med.umich.edu

Nephrology and Hypertension Cleveland Clinic (United States)

Editorial Board for Regional Australia

Professor John Svigos, AM

MBBS; DRCOG; CBioEth; FRCOG; FRANZCOG

(<http://www.womenshealthspecialists.com.au/jsvigos.html>)

(Scopus ID) (<https://www.scopus.com/authid/detail.uri?authorId=6603773825>)

john@svigos.com.au (mailto:john@svigos.com.au)

Discipline of Obstetrics & Gynaecology

Faculty of Health & Medical Sciences

University of Adelaide, South Australia

dr Deasy Ayuningtyas Tandio MPH-MBA (<http://orcid.org/0000-0001-7847-2831>).

(OrcidID) (<https://orcid.org/0000-0001-7847-2831>)

deasytandio@yahoo.com

James Cook University Australia Master of Public Health Master Of Business Administration, Indonesia

Editorial Board for Regional Europa

Prof. Harald Hoekstra

(Scopus ID) (<https://www.scopus.com/authid/detail.uri?authorId=36038081900>)

jsvigos@iprimus.com.au

Universitair Medisch Centrum Groningen, Division of Surgical Oncology, Groningen the Netherland

Editorial Board for Regional Asia

Prof Huang Qin (<http://accu.cqu.edu.cn/web/eallprof/559.jhtml>)

(Scopus ID) (<https://www.scopus.com/authid/detail.uri?authorId=7409535321>)

qhuanq@cqu.edu.cn

Chairman Dept. of Neurosurgery, Guangdong 999 Hospital Guangzhou China

Assoc. Prof. Mohammad Amin Bahrami

(Scopus ID) (<https://www.scopus.com/authid/detail.uri?authorId=55524082200>)

aminbahrami1359@gmail.com

Head of healthcare management department, Shahid Sadoughi University of Medical Sciences, Yazd,Iran

Dr. Tanveer Beg, PhD

(Scopus ID) (<https://www.scopus.com/authid/detail.uri?authorId=6505772852>)

tvmirza@jazanu.edu.sa

Assistant Professor, Department of Biology, Faculty of Science, Jazan University, Jazan, Saudi Arabia.

Editorial Board Members

Prof. Andi Asadul Islam

(Scopus ID) (<https://www.scopus.com/authid/detail.uri?authorId=55504893500>), (Google Scholar) (<https://scholar.google.co.id/citations?user=vWs1RdMAAAJ&hl=id&oi=sra>)

undee@med.unhas.ac.id

Faculty of Medicine Hasanudin University, Makasar-Indonesia

Prof. Dr. dr. Abdul Hafid Bajamal, Sp.BS

(Scopus ID) (<https://www.scopus.com/authid/detail.uri?authorId=57192378862>)

hfbajamal@gmail.com

Faculty of Medicine Airlangga University, Surabaya-Indonesia

Dr. dr. I Wayan Sudarsa, Sp.B(K) Onk, FINACS, FICS.

(Scopus ID (<https://www.scopus.com/authid/detail.uri?authorId=57205145862>)), (Google Scholar (<https://scholar.google.co.id/citations?hl=id&user=SdInHKwAAAJ>)),

(Researchgate (https://www.researchgate.net/scientific-contributions/2157636099_I_Wayan_Sudarsa))

dr. I.B. Amertha P. Manuaba, SKed, MBIomed. (<https://scholar.google.co.id/citations?user=KzCQgA0AAAAJ&hl=en>)

(Scopus ID) (<https://www.scopus.com/authid/detail.uri?authorId=57195520004>), (Google Scholar) (<https://scholar.google.co.id/citations?user=KzCQgA0AAAAJ&hl=en>),

(ORCID) (<http://orcid.org/0000-0001-6647-9497>), (Researcher ID (<http://www.researcherid.com/rid/P-9169-2016>)) (Researchgate) (https://www.researchgate.net/profile/Amertha_Manuaba)

/profile/Amertha_Manuaba)

AmerthaManuaba@gmail.com / Amertha_Manuaba@unud.ac.id

Faculty of Medicine, Universitas Udayana, Indonesia

Editorial inquiries to be addressed to:

email 1: editorbalimedicaljournal@gmail.com (mailto:editor@balimedicaljournal.org)

email 2: editor@balimedicaljournal.org (mailto:editor@balimedicaljournal.org)



WEB OF SCIENCE™

(https://mjl.clarivate.com/search-results?issn=2089-1180&hide_exact_match_fl=true&utm_source=mjl&utm_medium=share-by-link&utm_campaign=search-results-share-this-journal)



ELSEVIER
Scopus

(<https://www.scopus.com/sourceid/21101024217>)

DOAJ
DIRECTORY OF
OPEN ACCESS
JOURNALS

(<https://doaj.org/toc/2302-2914>)



(<https://sinta3.kemdikbud.go.id/journals/profile/2513>)

Full Indexing List (<https://balimedicaljournal.org/index.php/bmj/pages/view/indexing>)

In Press (<https://balimedicaljournal.org/index.php/bmj/issue/view/30>)

Submit An Article (<https://balimedicaljournal.org/index.php/bmj/login>)

Scopus Citedness (<https://balimedicaljournal.org/index.php/bmj/pages/view/scopus>)

(http://clustrmaps.com/site/1a4xh?utm_source=globe)



(<https://balimedicaljournal.org/index.php/bmj/>)

Published by:
(<http://www.discoverysys.ca/>)

For Indonesian Physician Forum and Indonesia College of Surgeons, Indonesia

📍 Bali Medical Journal, Bali-Indonesia

📞 62 (0369) 225206

Fibrin glue as a novel therapy for contracted socket in comparison to mitomycin-c and triamcinolone acetonide at Dr. Soetomo General Academic Hospital, Surabaya, Indonesia

Firda Ayu Muthie¹, Evelyn Komaratih^{1*}, Sutjipto¹, Dyah Fauziah², Budi Utomo³

ABSTRACT

Background: Contracted socket is still a major problem for patients with anophthalmia. The main factor for this condition is inflammation and fibrosis, which result in conjunctival shortening. Myofibroblasts that express α -SMA are the primary mediators of anophthalmic socket contraction.

Methods: One healthy eye of a New Zealand white rabbit were randomly selected for evisceration and divided into four treatment groups, each with five rabbits. Each rabbit in the group received a single subconjunctival injection of a different agent. Group I was the control group that received no injection, Group II received MMC 0.4 mg/ml, Group III received TCA 40 mg/ml, and Group 4 received fibrin glue. After 14 days, the animals were euthanized, and conjunctival samples were submitted for histopathological analysis. A monoclonal α -SMA antibody was applied, and pathologists provided the IRS score for each sample. The differences in α -SMA expression were statistically analyzed with a significant level of $p < 0.05$.

Result: All groups displayed a statistically significant decrease in α -SMA expression compared to the control group ($p < 0.05$) as sorting as MMC group with $p = 0.007$, TCA group with $p = 0.007$, and fibrin glue with $p = 0.009$. MMC was the most effective at reducing α -SMA ($p = 0.004$). Surprisingly, there were no statistically significant differences between MMC, TCA, and fibrin glue when they were evaluated independently.

Conclusion: A single subconjunctival injection of fibrin glue may be used as a novel treatment to prevent socket contracture in actively healing sockets.

Keywords: α -SMA, contracted socket, fibrin glue, fibrosis, MMC, TCA.

Cite This Article: Muthie, F.A., Komaratih, E., Sutjipto., Fauziah, D., Utomo, B. 2022. Fibrin glue as a novel therapy for contracted socket in comparison to mitomycin-c and triamcinolone acetonide at Dr. Soetomo General Academic Hospital, Surabaya, Indonesia. *Bali Medical Journal* 11(3): 1485-1488. DOI: 10.15562/bmj.v11i3.3687

¹Department of Ophthalmology, Faculty of Medicine, Universitas Airlangga, Dr. Soetomo General Academic Hospital, Surabaya, Indonesia;

²Department of Pathology Anatomy, Faculty of Medicine, Universitas Airlangga, Dr. Soetomo General Academic Hospital, Surabaya, Indonesia;

³Department of Public Health Sciences, Faculty of Public Health, Universitas Airlangga, Surabaya, Indonesia;

*Corresponding author:

Evelyn Komaratih;
Department of Ophthalmology, Faculty of Medicine, Universitas Airlangga, Dr. Soetomo General Academic Hospital, Surabaya, Indonesia;
risetpublikasi@gmail.com

Received: 2022-09-03

Accepted: 2022-10-12

Published: 2022-11-07

INTRODUCTION

Anophthalmia is the absence of the eyeball and its surrounding tissue from the orbital cavity.^{1,2} The majority of cases are caused by destructive eye surgery, such as evisceration.² Inadequate wound healing (following evisceration) might result in conjunctival and subconjunctival scarring that leads to socket contractures.³ Contracted socket is still a major problem for anophthalmic patients because the prosthetic eye cannot be properly attached, resulting in cosmetic eyelid issues such as entropion, ectropion, infection, and ptosis.⁴ A prospective study showed that contracted sockets occurred in 7.7% of 1739 anophthalmic sockets⁵, and currently, there is no specific treatment

available to prevent socket contractures.

Myofibroblasts are uniquely differentiated fibroblasts and become an essential component in forming scar tissue. Persisting myofibroblasts were found in a contracted socket, and they express alpha-smooth muscle actin (α -SMA).⁶ Mitomycin-c (MMC) is commonly used for reducing the degree of postoperative scarring by suppressing fibroblast proliferation. However, MMC's efficacy is very dose-dependent, and it has side effects such as chemosis, inhibition of conjunctival healing, conjunctival granulomas, and thinning of the sclera leading to scleral melting.^{7,8} Triamcinolone acetonide (TCA) is a glucocorticoid agent which acts to inhibit fibroblast proliferation by preventing migration

and activation of inflammatory cells and myofibroblasts.^{9,10} Subconjunctival injection of TCA has potential side effects such as delayed wound healing.¹⁰

Fibrin glue (FG) is another treatment to reduce scar tissue formation by inhibiting inflammation, reducing excessive inflammatory reactions, reducing fibroblast proliferation and differentiation, and reducing myofibroblast cellular responses to deposited collagen.^{11,12} FG provides the advantages of the fact that it is biocompatible, biodegradable, non-toxic on the surface of the eyeball, simple to produce, and can be isolated autologously.¹³⁻¹⁵ FG has been widely used in the practice of ophthalmological surgery.¹⁶ However, there is still no scientific literature that mentions the

efficacy of FG in anophthalmic surgery or socket surgery. The aim of this study was to determine the fibrin glue as a novel therapy for contracted sockets in comparison to mitomycin-c and triamcinolone acetonide at Dr. Soetomo General Academic Hospital, Surabaya, Indonesia.

METHODS

Fibrin Glue Preparation

A sterile syringe with CPDA in a 9:1 ratio was used to puncture the rabbit's ear vein, and 40 ml of peripheral blood total was obtained. In order to concentrate the plasma, the blood was placed in a sterile 10 mL centrifuge tube and centrifuged for 15 minutes at 3000 rpm. The plasma portion was stored in a sterile centrifuge tube at -20°C for 24 hours. Then the second centrifugation was performed at 4°C , 3000 rpm for 15 minutes. After the second centrifugation, the upper 2/3 of the plasma was stored for as much as 10 ml to prepare the fibrinogen component. The lower 1/3 (PRP) was stored in sterile micro-tubes to be prepared as a material for thrombin production. The upper 2/3 of the plasma was added with 95% ethanol, as much as 1 ml and then incubated at 4°C for 30 minutes. Then third centrifugation was carried out at 4°C at 3000 rpm for 15 minutes. The sediment was used as a fibrinogen component, while the supernatant was discarded. To create thrombin, 0.05ml of 10% CaCl_2 was added to the PRP component. FG was made by mixing fibrinogen and thrombin in a ratio of 1:1.^{17,18}

Study design and subject recruitment

This true experimental study was done in February-July 2022 at the Universitas Airlangga Faculty of Veterinary Medicine. A healthy New Zealand white rabbit (*Oryctolagus cuniculus*) with a body weight of 2.5–3.5 kg and an age range of 4–6 months served as the sample. In this study, there were four treatment groups, each with five samples, for a total of 20 eyes from 20 rabbits. Animals diagnosed by a veterinarian as having a disease or the potential to transmit disease were excluded from this study. The dropout criteria are when the rabbits become ill, die, and have complications such as scleral perforation, infection, and bleeding during and after

surgery.

One eye of each rabbit was selected randomly. A combination of 5 mg/kg xylazine (Xylazine 20, Pantex, Holland) and 30 mg/kg to 50 mg/kg ketamine-HCL (Keta-A-100, Agrovvet Market S.A., Peru) was used to anesthetize the animals; booster doses were administered as needed. Evisceration surgery was carried out in a sterile condition. The procedure involved a 360° peritomy, excision of the corneal button, scooping out the intraocular tissues, and suturing the sclera and the conjunctiva using 6.0 polyglactin (Vicryl™, Ethicon, US). The sort of injection administered was not masked by the operating surgeon. Each group of four rabbits underwent a single subconjunctival injection of a different substance. The injection was performed at the mid-superior bulbar conjunctiva close to the vertical meridian at the inferior fornix. Group, I did not receive injection as a control group, Group II received 0.1 ml of mitomycin-C (Mito*10, NEON, India) 0.4 mg/ml, Group III received 0.1 ml of Triamcinolone Acetonide (Flamicort, DexaMedica, Indonesia) 40 mg/ml, and Group 4 received 0,1ml of fibrin. Chloramphenicol eye ointment (Erlamycetin, Erela, Indonesia) was applied three times daily, and Tylenol solution was mixed with their drinking water to alleviate the pain. On day 14, after surgery, all the rabbits were euthanized. Conjunctiva and Tenon capsule samples were carefully harvested and cut uniformly approximately 10mmx10mm as near as feasible to the original site injection. The samples were carefully transferred to a vial containing freshly made fixative solution for further processing after being placed epithelial side up on a thin sheet of cardboard (surgical suture packaging) to flatten it and prevent wrinkling. The study pathologist was present during sample collection, rapidly processing the samples. H&E staining was done on each serial section sample.⁶

Immunohistochemistry

Conjunctival samples that had been formalin-fixed and paraffin-embedded were cut into four-micrometer slices. Alpha Smooth Muscle Actin antibody [1A4] (FITC) (GeneTex, Inc., North

America) was prediluted to 1:1000 dilution for immunohistochemical staining, and a Leica Bond Max - Fully Automated IHC/ISH Staining equipment was used. The expression of α -SMA was located in the cytoplasm.

Quantification of cell

α -SMA+ cells were stained as light brownish to chocolate brown under a light microscope. A semi-quantitative method using an immunoreactivity score (IRS) was used to analyze the α -SMA+ cells. IRS is a product of multiplication between positive cells proportion score and staining intensity score. The intensity of the immunoreactive products was scored under a light microscope as follows: no expression= 0; minimal intensity= 1; moderate reaction= 2; and strong reaction= 3. The positive ratio was scored as follows: no positive cells= 0; positive cells <10%= 1; positive cells 11–50%= 2; positive cells 51–80%= 3; positive cells >80%= 4.¹⁹

The pathologist conducted this at $\times 400$ magnification. There is only one pathologist to analyze the α -SMA+ cells. In order to reduce bias, this technique was carried out by a pathologist on serially numbered slides in a blinded manner using an Olympus microscope (Cx51) equipped with an Olympus camera using SIS software (Japan, Tokyo).

Statistical Analysis

The pathologist provided the data in an Excel spreadsheet (Excel 2010, Microsoft Corporation, Redmond, WA, United States), and statistical analysis was carried out using SPSS software version 26 for Windows (IBM Corporation, New York, NY, U.S.A.). Statistical comparison was performed using Kruskal-Wallis test and Mann-Whitney test.

RESULT

Postoperative clinical evaluations in all groups revealed a deep fornix, both superior and inferior. A qualitative analysis of the H&E sections showed that the conjunctival epithelium was intact in all groups. In the control groups, there was an incredibly dense inflammatory cell, but there was a decrease in other groups, particularly in the MMC group. The

Table 1. IRS score of α -SMA between group.

Group	Total (N=20)	IRS Score of α -SMA					p Kruskal-Wallis
		Mean	Median	IQD	Minimum	Maximum	
Control*	5	11.4	12	2	9	12	0.005
MMC*	5	3.6	4	3	2	6	
TCA	5	4.6	4	3	3	6	
FG	5	5.8	6	4	4	9	

*The same superscript letter in one column indicates that the statistics are the most significantly different using Post-Hoc Dun

Table 2. IRS score of α -SMA between injected group.

Group		p Mann-Whitney
MMC	TCA	0.324
MMC	FG	0.100
TCA	FG	0.316

detection of α -SMA expression was done by immunohistochemical staining, and the IRS score was employed as a method for quantification.

The control group had the highest median myofibroblast count (12), followed by FG (6), TCA (4), and MMC, with the lowest median value of 4. All groups displayed a statistically significant decrease in α -SMA expression compared to the control group ($p < 0.05$) as sorting as MMC group with $p = 0.007$, TCA group with $p = 0.007$, and FG with $p = 0.009$. Surprisingly, there were no statistically significant differences between MMC, TCA, and FG when they were evaluated independently ($p > 0.005$) (Tables 1 and 2).

DISCUSSION

The contracted socket is still a major problem for anophthalmic patients because it causes cosmetic eyelid issues and psychological problems in the patient.⁴ Mostly, it needs more than one surgery to fix the socket, so oculoplastic surgeons have continuously investigated ways to improve the conjunctival wound healing process. In this study, the Inferior conjunctival fornix was chosen as the site for injection because fornix shortening first occurred in the inferior area. This is related to the inflammatory process caused by friction of the eye prosthesis, which is mainly supported by inferior fornix.²⁰

All groups displayed a statistically significant decrease in α -SMA expression compared to the control group, and MMC had the lowest score of α -SMA. This result was in line with Tawfik *et al.*, who revealed

that a single injection of MMC 0.4mg/ml got the lowest count of myofibroblast compared to 5-FU, TCA, and Bevacizumab. The same dose of MMC was also used to reduce the TGF- β and α -SMA expression in human tenon fibroblast of glaucomatous patient²¹ and suppresses the rate of fibroblast migration.¹⁸ As in this study, a single subconjunctival injection of 40mg/ml of TCA has proven to reduce the myofibroblast count.⁶ TCA can also be adjuvant therapy for patients with non-inflammatory glaucoma. Sub tenon injection in the bleb area after trabeculectomy can improve the final outcome of trabeculectomy surgery.²² The administration of TCA can reduce inflammation, hence decreasing collagen and glycosaminoglycan synthesis, fibroblast proliferation, and increasing hypoxia.²³ Sakarya *et al.* hypothesized that the application of fibrin glue to the subconjunctival tenon area could reduce the formation of post-trabeculectomy scar tissue.¹³ Komaratih *et al.* reported that the application of subconjunctival fibrin glue after trabeculectomy in rabbits was able to reduce the area of bleb fibrosis by modulating the remodeling phase.¹⁴ Self-made FG in this study successfully suppresses α -SMA expression. As mentioned in other studies, FG added to Tenon's fibroblast cell culture will express lower TGF- β and α -SMA.²¹

Fibroblasts have a crucial role in wound healing prior to socket contractures.⁶ The profibrotic cytokine TGF- β will stimulate fibroblasts to differentiate into myofibroblasts. The differentiation is complete only when α -SMA is acquired.

Thus α -SMA is the reliable marker for myofibroblast. Myofibroblasts are essential to tissue repair because they provide extracellular matrix material and mechanical strength for wound closure.^{6,24-25} MMC, TCA, and FG are agents that can modify the wound healing process to reduce scar tissue formation. MMC affects almost all profibrotic processes in conjunctival fibroblasts, as indicated by decreased fibroblast proliferation and collagen secretion, and induces apoptosis through a signaling-dependent mechanism of c-Jun N-terminal kinase 1 (JNK1).²⁶ Administration of TCA is used to prevent fibrosis by slowing the initial phase of wound healing and decreasing the production of proinflammatory cytokines (VEGF, TGF- β , and IL-1).²³ FG is a biological tissue adhesive that mimics the final stages of the coagulation cascade by activating human fibrinogen with thrombin. FG releases a variety of growth factors IGF-1, HGF, and HGF- that play important in the proliferation phase by activating tenon fibroblast proliferation and migration. FG provides the advantages of the fact that it is biocompatible, biodegradable, and non-toxic. The biodegradability takes 14-21 days from subconjunctival bleb space.¹³⁻¹⁵

Currently, commercial fibrin glue preparations are seemed to be used more frequently. Moreover, fibrin glue can be prepared at a blood transfusion center or from a patient's own blood. The remarkable benefit of self-made FG, compared to synthetic glues and other biomaterials, is to be made autologous with low cost and ease of preparation. Autologous FG eliminates the possible risks of foreign body reactions and viral infection. Although MMC is still superior in reducing the fibrosis process, the findings of this study suggest that FG could be used as an adjuvant or treatment to reduce the risk of socket contracture through its safety ness, promoting

better wound healing and reducing the inflammatory response. The primary limitation of this study is the relatively brief duration of the observations, which only evaluated the α -SMA expression at one time (day 14) and did not evaluate the other profibrotic marker such as TGF- β , MMP, and collagen. It is hoped that longer-term research can be conducted so that the entire wound-healing process can be completed (day 7, day 14, and day 21). Further studies must figure out which agent can maintain the fornix depth by evaluating the fornix depth preoperatively and postoperatively. Based on the findings of this study, a clinical trial of using fibrin glue in human socket surgery or anophthalmia surgery to prevent a contracted socket could be conducted.

CONCLUSION

A single dose of autologous FG, mitomycin-C, and triamcinolone acetonide can significantly reduce the number of α -SMA expressions in actively healing sockets. Most importantly, FG may be used as adjuvant therapy and a novel treatment to prevent socket contracture. However, MMC remains the best agent to inhibit fibrosis in this study.

ETHICAL CLEARANCE

Ethics approval has been received prior to the study being conducted, and also already following cope and ICJME guidelines.

CONFLICT OF INTEREST

There is no conflict of interest regarding the manuscript.

FUNDING

Self-funding.

AUTHOR CONTRIBUTIONS

All authors equally contribute to the study from the conceptual framework, data acquisition, and data analysis until reporting the study results through publication.

REFERENCES

1. Serin D, Karshoğlu Ş, Akbaba M. Clinical evaluation of 188 patients with contracted

- socket. *Surgery Curr Res.* 2014;(4)6. p1-6. DOI:10.4172/2161-1076.1000203.
2. Dhillon HK, Raj A, Dhasmana R, and Badahur H. Anophthalmic socket-a cosmetic dilemma. *IJOOO.* 2018;(4)1. p6-11. DOI:10.18231/2455-8478.2018.0004.
3. Hsu WC, Spilker MH, Yannas IV, Rubin PA. Inhibition of conjunctival scarring and contraction by a porous collagen-glycosaminoglycan implant. *Invest Ophthalmol Vis Sci.* 2000;41(9):2404-2411.
4. Peseyie R, Raut AA. Contracted Socket. In: StatPearls. Treasure Island (FL): StatPearls Publishing; September 25, 2022.
5. Adhikari RK, Khazai H, Usha KD. Prospective evaluation of contracted sockets. *Kathmandu Univ Med J (KUMJ).* 2007;5(3):391-395.
6. Tawfik HA, Abdulhafez MH, Fouad YA, Rashed HO, Osman WM. Revisiting the Role of the Myofibroblast in Socket Surgery: An Immunohistochemical Study. *Ophthalmic Plast Reconstr Surg.* 2016;32(4):292-295. doi:10.1097/IOP.0000000000000510.
7. Solomon A, Kaiserman I, Raikup FD, Landau D, Frucht-Pery J. Long-term effects of mitomycin C in pterygium surgery on scleral thickness and the conjunctival epithelium. *Ophthalmology.* 2004;111(8):1522-1527. doi:10.1016/j.ophtha.2004.02.007.
8. Mandour SS, Elmazar HM, Marey HM, Rahman AK, Sakr RA. Mucous Membrane Grafting Augmented with Topical Mitomycin C Application in Contracted Socket Repair Surgeries. *J Ocul Pharmacol Ther.* 2016;32(10):691-694. doi:10.1089/jop.2016.0041.
9. Nakajima N, Hashimoto S, Sato H, et al. Efficacy of gelatin hydrogels incorporating triamcinolone acetonide for prevention of fibrosis in a mouse model. *Regen Ther.* 2019;11:41-46. Published 2019 May 10. doi:10.1016/j.reth.2019.04.001.
10. Athanasiadis Y, Tsatsos M, Sharma A, Hossain P. Subconjunctival triamcinolone acetonide in the management of ocular inflammatory disease. *J Ocul Pharmacol Ther.* 2013;29(6):516-522. doi:10.1089/jop.2012.0208.
11. Jacob S and Nath S. Fibrin sealant: A review of its applications in periodontal surgery. *Int J Experiment Dent Sci.* 2015;(4)1. p40-46. DOI:10.5005/jp-journals-10029-1093.
12. Cavichiolo JB, Buschle M, Carvalho B. Comparison of fibrin adhesives prepared by 3 different methods. *Int Arch Otorhinolaryngol.* 2013;17(1):62-65. doi:10.7162/S1809-97772013000100011.
13. Sakarya Y, Sakarya R, Kara S, Soylu T. Fibrin glue coating of the surgical surfaces may facilitate formation of a successful bleb in trabeculectomy surgery. *Med Hypotheses.* 2011;77(2):263-265. doi:10.1016/j.mehy.2011.04.030.
14. Komarath E, Rindiatuti Y, Susilowati H, Hendrianto E, Suhendro G, and Rantam FA. Fibrin glue (FG) encapsulated limbal mesenchymal stem cells (LMSCS) decrease bleb fibrosis area after trabeculectomy through TGF- β and MMP-9 modulation. *AMBES.* 2018;20. p66-73.
15. Rindiatuti Y, Komarath E, Susilowati H, Soebagio HD, and Rantam FA. Fibrin glue (FG) attenuates fibrosis on human tenon's fibroblasts (HYFS) of glaucomatous eyes: comparison with mitomycin-c. *Biochem. Cell. Arch.* 2019;(19)2. p4713-4720. DOI:10.35124/bca.2019.19.52.4713.
16. Panda A, Kumar S, Kumar A, Bansal R, Bhartiya S. Fibrin glue in ophthalmology. *Indian J Ophthalmol.* 2009;57(5):371-379. doi:10.4103/0301-4738.55079.
17. Abdurrauf M, Ramadhan F, Nurwasis, Zuhria I, Tambunan BA, Notobroto HB, Surahman B, and Komarath E. Mitomycin C, curcumin, and fibrin glue inhibit the cell proliferation and expression of TGF- β in human pterygium fibroblast. *Bali Medical Journal.* 2022;11(1). p228-233. <https://doi.org/10.15562/bmj.v11i1.3315>.
18. Ramadhan F, Jamaluddin J, Zuhria I, Indriaswati L, Komarath E. Matrix Metalloproteinase-3 Down Regulation and Cell Migration Inhibition in Human Pterygium Fibroblasts by Mitomycin-C, Curcumin and Fibrin Glue. *The Indonesian Biomedical Journal.* 2022;28(14). p172-9. DOI: 10.18585/inabj.v14i2.1825.
19. Fedchenko N, Reifenrath J. Different approaches for interpretation and reporting of immunohistochemistry analysis results in the bone tissue - a review. *Diagn Pathol.* 2014;9:221. Published 2014 Nov 29. doi:10.1186/s13000-014-0221-9.
20. Neuhaus RW and Hawes MJ. Inadequate inferior cul-de-sac in the anophthalmic socket. 1992. *Ophthalmology.* 1992;99(1). p153-157.
21. Taqryanka SD, Komarath E, Rindiatuti Y, Susilowati H, Wijayanti NT, and Rantam FA. Antifibrosis Effect of Fibrin Glue on TGF- β and α -SMA Expression in Human Tenon Fibroblast, as Wound Healing Model After Trabeculectomy: An In Vitro Study. 2019. *Biochemical and Cellular Archives.* 2019;19(2). p4777-4781.
22. Dias DT, Almeida I, Ushida M, et al. Subtenon triamcinolone as an adjuvant in mitomycin-C-enhanced trabeculectomy in non-inflammatory glaucomas: A randomized clinical trial. *PLoS One.* 2022;17(5):e0268623. Published 2022 May 26. doi:10.1371/journal.pone.0268623.
23. Fung AT, Tran T, Lim LL, et al. Local delivery of corticosteroids in clinical ophthalmology: A review. *Clin Exp Ophthalmol.* 2020;48(3):366-401. doi:10.1111/ceo.13702.
24. Zada M, Pattamatta U, White A. Modulation of Fibroblasts in Conjunctival Wound Healing. *Ophthalmology.* 2018;125(2):179-192. doi:10.1016/j.ophtha.2017.08.028.
25. Darby IA, Laverdet B, Bonté F, Desmoulière A. Fibroblasts and myofibroblasts in wound healing. *Clin Cosmet Investig Dermatol.* 2014;7:301-311. Published 2014 Nov 6. doi:10.2147/CCID.S50046.
26. Guo Q, Li X, Cui MN, et al. Low-Dose Mitomycin C Decreases the Postoperative Recurrence Rate of Pterygium by Perturbing NLRP3 Inflammatory Signalling Pathway and Suppressing the Expression of Inflammatory Factors. *J Ophthalmol.* 2019;2019:9472782. Published 2019 Nov 15. doi:10.1155/2019/9472782.



This work is licensed under a Creative Commons Attribution