

# 17. The Difficulties of Trabeculectomy in a Primary Angle-Closure

*by* Herdina Ramadhani

---

**Submission date:** 16-May-2023 02:24PM (UTC+0800)

**Submission ID:** 2094420102

**File name:** he\_Difficulties\_of\_Trabeculectomy\_in\_a\_Primary\_Angle-Closure.pdf (4.85M)

**Word count:** 3043

**Character count:** 17186

## CASE REPORT

## The Difficulties of Trabeculectomy in a Primary Angle-Closure Glaucoma Patient

**Authors:**

Herdina Ramadhani<sup>1</sup>  
Nurwasis\*<sup>2</sup>  
Yulia Primitasari<sup>3</sup>  
Evelyn Komarath<sup>4</sup>

**Affiliations:**

Department of Ophthalmology,  
Faculty of Medicine, Universitas  
Airlangga–RSUD Dr. Soetomo  
Surabaya, Indonesia.

**Corresponding author:**

Nurwasis  
nurwasis@fk.unair.ac.id

**Dates:**

Received: 28 July 2021  
Revised: 06 March 2022  
Accepted: 07 March 2022  
Published: 21 March 2022

**DOI:**

<https://doi.org/10.20473/vsehj.v1i2.2022.38-44>

**Copyright:**

© 2022 Author(s). Open access under Creative Commons Attribution-Share Alike 4.0 International Licence (CC-BY-SA).

**Abstract**

**Introduction:** Trabeculectomy is an incisional surgery for glaucoma patient. Performing trabeculectomy in primary angle-closure glaucoma (PACG) is quite difficult. Caution is needed for the occurrence of flat anterior chamber (FAC) and malignant glaucoma. We present a case management of trabeculectomy in a PACG patient. **Case presentation:** A 52-year-old male had blurred vision in his left eye since one year ago. The patient felt left visual field narrowing since eight months ago. Patient had type 2 diabetes mellitus. Visual acuity on the left eye was 5/7.5. Intraocular pressure (IOP) increased (29 mmHg). Gonioscopy showed closed angle and peripheral anterior synechiae. Glaucomatous optic neuropathy was found with C/D ratio value of 0.9 and superior-inferior RNFL thinning on optical coherence tomography (OCT). Anterior segment OCT revealed shallow anterior chamber depth (ACD) 2.54 mm. The right eye visual acuity was 5/5, normal IOP, and shallow ACD (2.66 mm). Patient was underwent left eye trabeculectomy. Postoperatively, left eye anterior chamber and bleb were formed. He had normal IOP without glaucoma medications. **Conclusions:** Trabeculectomy is a surgical procedure for glaucoma. Close monitoring is required to avoid the risk of postoperative FAC and malignant glaucoma in PACG. **Keywords:** glaucoma; primary angle-closure glaucoma; trabeculectomy; intraocular pressure

**Introduction**

Glaucoma is a leading cause of permanent vision loss in the world's population. It is a group of diseases defined by optic neuropathies that is consistent with remodeling of the connective tissue elements of the optic disc and loss of neural tissue associated with eventual development of distinctive patterns of visual dysfunction. Intraocular pressure (IOP) level is one of the primary risk factors for development of glaucoma. Iridotrabecular contact greater than or equal to 180 degrees with peripheral anterior synechiae (PAS) or increased IOP and glaucomatous optic neuropathy is the hallmark of primary angle-closure glaucoma (PACG).<sup>[1]</sup>

PACG's global population is expected to reach 17.14 million in 2020, 20.73 million in 2030, 23.73 million in 2040, and 26.26 million in 2050 for the population over the age of 40.<sup>[2]</sup> In 2020, Asia has the largest PACG population among all continents, with 12.30 million people, and it will continue to account for more than 70% of the global PACG population in the coming decades. Due to its larger propensity for bilateral blindness compared to primary open-angle glaucoma, the most prevalent form of the disease worldwide, PACG places an enormous burden on families and society as a whole.<sup>[2]</sup> Medication and/or laser surgery are the initial options recommended by the American Academy of Ophthalmology for PACG. Surgery can be hastened in patients with advanced visual field loss.<sup>[1]</sup>

Trabeculectomy is incisional surgery for glaucoma. It creates a new pathway (fistula) that allows aqueous humour to flow out of the anterior chamber through a surgical corneoscleral opening into the subconjunctival and the sub-tenon space. The procedure is referred to as filtering surgery.<sup>[1]</sup> It is vital to examine the

patient's postoperative state following trabeculectomy surgery by evaluating IOP, anterior chamber depth (ACD), and bleb formation. An anterior chamber that is too shallow or flat may develop in the early, middle, or late stages of recovery from surgery. There are numerous risks associated with trabeculectomy in patients with PACG, which is the standard surgery for glaucoma. Malignant glaucoma is the most severe complication.<sup>[3][11]</sup>

A flat anterior chamber and malignant glaucoma can occur in postoperative period of trabeculectomy in PACG, hence vigilance is needed. For the purpose of this study, we are reporting a patient's care of trabeculectomy. It is quite difficult when performing trabeculectomy in PACG, caution is needed for the occurrence of flat anterior chamber and malignant glaucoma. The aim of this study is to report a case management of trabeculectomy in a PACG patient.

**Case presentation**

A 52-year-old man complained of blurred vision in his left eye since one year ago. The patient felt left visual field narrowing since eight months ago and gradually worsening. There was no ocular pain, red eyes, seeing halos around light, floaters, curtain-like shadow over his visual field, nausea, or vomiting. He was treated as a glaucoma patient in Balikpapan City for three months, and then he was referred to Dr. Soetomo General Hospital, Surabaya.

He had type 2 diabetes mellitus for ten years. He was on diabetic medical therapies, metformin and glibenclamide orally, in controlling his glucose level. Medications which had been given previously were Latanoprost eye drop every 24 hours OU, Timol 0.5% eye drop every 12 hour OU, Acetazolamide 250 mg every six hours orally and kalium slow release (KSR) 600 mg every 24 hours orally.

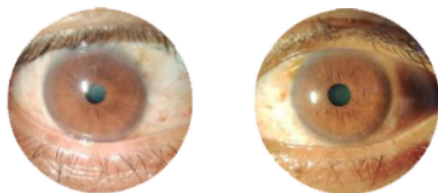


Figure 1. Preoperative patient's pictures.

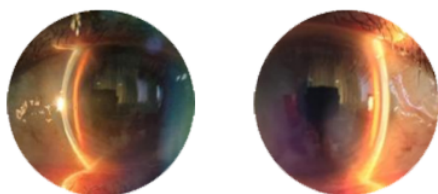


Figure 2. Preoperative patient's pictures with slit illumination showing Van Herick I-II OU.

On ophthalmology examination, the visual acuity in left eye was 5/7.5. There was elevated IOP with 29

mmHg. Slit lamp examination revealed shallow anterior chamber with Van Herick I-II, and mid-dilated pupil with 4 mm in diameter (Figure 1-2). Gonioscopy showed closed anterior chamber angle and PAS (Figure 3).

Funduscopy examination in the left eye found glaucomatous optic neuropathy with C/D ratio value of 0.9. Superior-inferior retinal nerve fiber layer (RNFL) thinning was found in optical coherence tomography (OCT) (Figure 4) Anterior segment OCT revealed shallow ACD of 2.54 mm (Figure 5). Perimetry result on the left eye showed tunnel vision glaucomatous field loss (Figure 6).

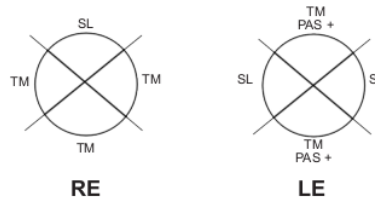


Figure 3. Gonioscopy examination showed closed angle.

The visual acuity of the right eye was 5/5. Slit lamp examination indicated a shallow anterior chamber with Van Herick grading of I-II and IOP of 17.3 mmHg. A funduscopy examination of the right eye revealed glaucomatous optic neuropathy with a CD ratio of 0.7. OCT examination revealed shallow ACD and inferior retinal nerve fiber layer (RNFL) thinning of 2.66 mm.

The visual acuity of the right eye was 5/5. Slit lamp examination indicated a shallow anterior chamber with Van Herick grading of I-II and IOP of 17.3 mmHg. A funduscopy examination of the right eye revealed glaucomatous optic neuropathy with a CD ratio of 0.7. OCT examination revealed shallow ACD and inferior retinal nerve fiber layer (RNFL) thinning of 2.66 mm.

PACG was found in both eyes of the patient. He was underwent trabeculectomy on the left eye. Corneal traction suture was performed using 8-0 vicryl. It was invented the fornix-based conjunctival flap. A trapezoid scleral flap was incised and deepened into 2/3 scleral thickness. The dissection was carried out with a crescent knife until clear cornea. To avoid any rapid decompression of the eyeball, paracentesis was performed at this time. Scleral fistula was excised using punch. Peripheral iridectomy was performed at 12 o'clock position. The scleral flap was sutured using 10-0 nylon, one suture at the apex of the trapezoid and two tight releasable sutures were positioned on each side. Conjunctiva was closed using 10-0 nylon suture. Horizontal mattress sutures were placed on each side of the conjunctival incision, and running sutures were placed at the flap's edge. Cefuroxime was injected intracamerally. At the end of the surgery corneal hydration and corneal traction suture releasing were performed (Figure 7).

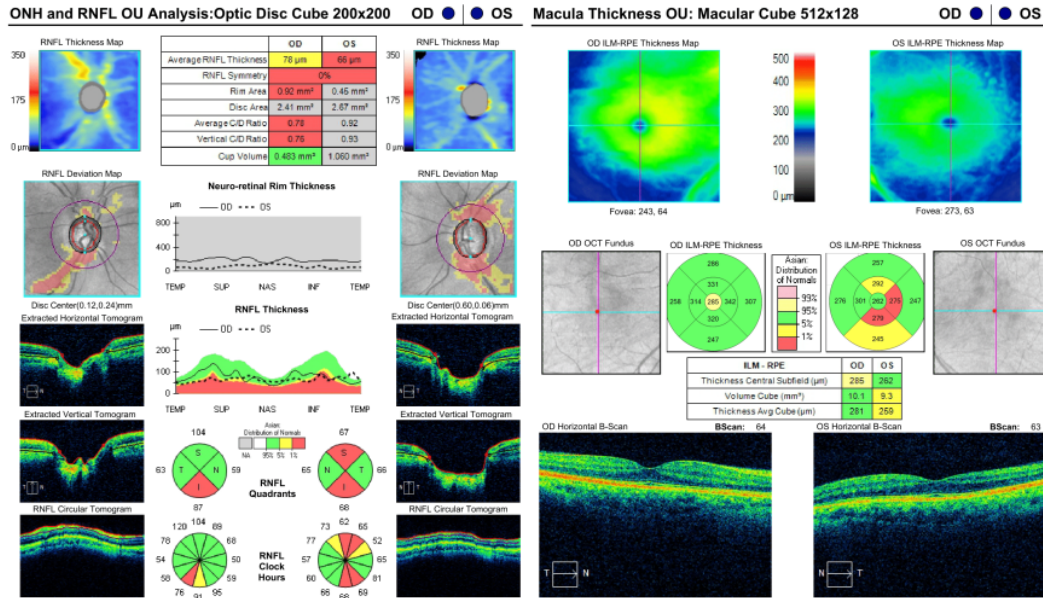


Figure 4. Optical Coherence Tomography showed RNFL thinning.

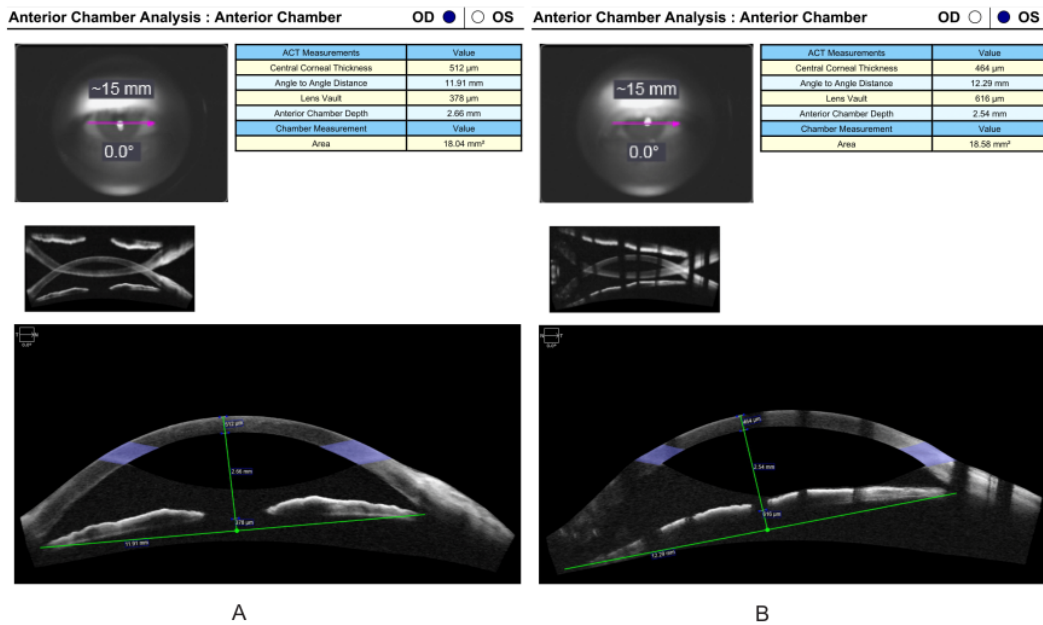


Figure 5. Anterior segment OCT showed shallow anterior chamber; (A) Right eye; (B) Left eye.

Postoperatively, topical tobramycin and fluorometholone eye drops were used every four hours in the left eye. Oral glaucoma medications were stopped. Topical glaucoma medications eye drops (Latanoprost and Timol 0.5%) were only used in the right eye. Oral 4 mg methylprednisolone and 500 mg mefenamic acid were also given every eight hours. The use of diabetic medications was continued.

We examined the patient one day after the surgery. Postoperatively, slit lamp examination revealed left eye conjunctival hyperemia, anterior chamber and bleb formations were formed, iridectomy at 12 o'clock position, normal IOP (12.2 mmHg) without glaucoma medications. Visual acuity was 5/7.5 (Figure 8).

The patient was allowed to discharge from hospital two days after surgery. The medications prescribed for

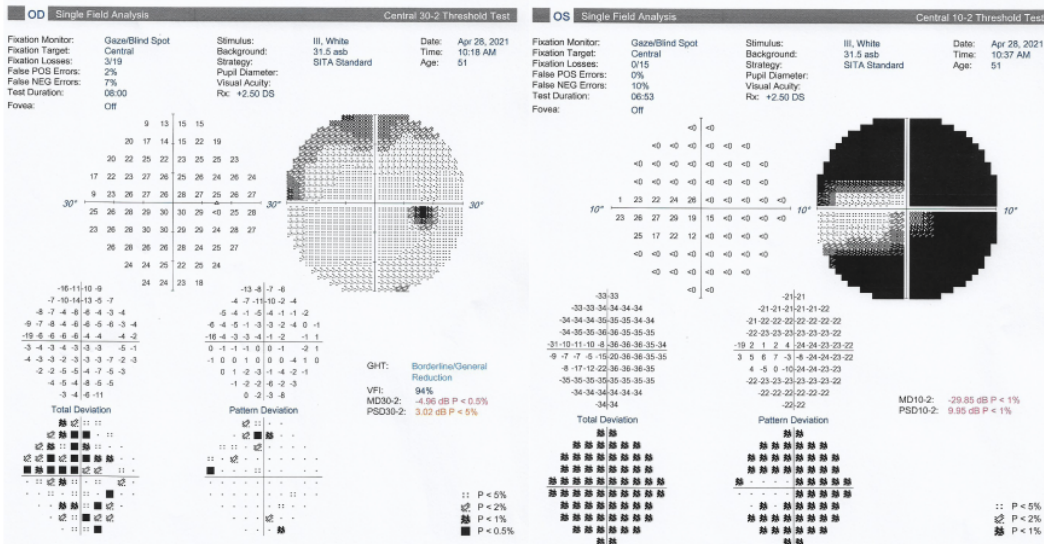


Figure 6. Visual field analyses showed glaucomatous field loss in left eye.

this patient were the same as postoperative medications. Seventh day postoperatively, patient was followed-up in outpatient clinic. On ophthalmology examination, left eye anterior chamber and bleb were formed with normal IOP (12.2 mmHg) without glaucoma medications. Postoperative anterior segment OCT showed anterior chamber formation shallow ACD of 2.49 mm (Figure 9-10).

Patient's right eye was planned for laser peripheral iridotomy (LPI) on the next follow up, however, patient and his family want to go back to their hometown in Balikpapan City. Therefore the patient was scheduled to follow-up one month later and planned for right eye LPI.

Two months postoperatively, the patient was followed-up in outpatient clinic. On ophthalmology examination, left eye anterior chamber and bleb were formed, IOP was 22.4 mmHg without glaucoma medications, and pulled out conjunctival sutures. Right eye IOP was 17 mmHg. The patient was underwent right eye LPI (Figure 11-12).

One week afterwards, the patient was underwent removable sutures removal due to the pulled out conjunctival sutures. He complained of discomfort sensation in the left eye (Figure 13).

One week after left eye removal removable sutures, the patient was followed-up in outpatient clinic. On ophthalmology examination, left eye anterior chamber and bleb were formed, IOP was 14.6 mmHg without glaucoma medications. Right eye IOP was 14.6 mmHg.

**Discussion and conclusions**

People with primary angle-closure may experience an acute attack or chronic progression, which are typically

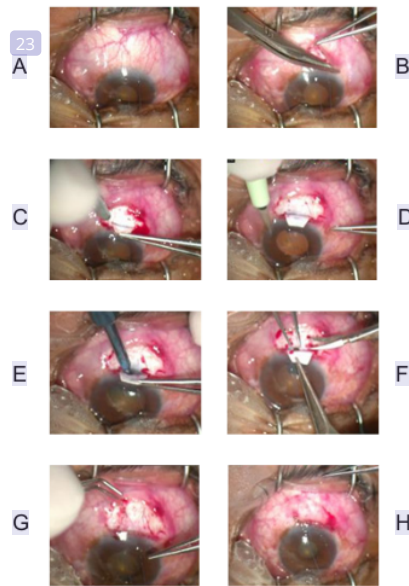


Figure 7. Clinical photographs showing steps of trabeculectomy procedures; (A) Corneal traction Suture; (B) Fornix-based conjunctival-tenon flap; (C) Scleral flap; (D) Paracentesis; (E) Scleral fistule (F) Iridectomy; (G) Closure of scleral flap using releasable sutures; (H) Closure of conjunctival flap.

characterized based on the presence of symptoms and the duration of increased IOP. Traditionally, either condition is treated by lowering IOP with medication, followed by LPI. However, some eyes are refracted by these treatments, necessitating surgical intervention. In the treatment of primary angle-closure glaucoma,

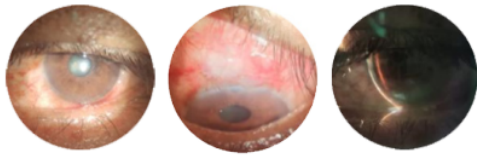


Figure 8. Left eye postoperative patient's pictures day-1.

surgical procedures such as anterior chamber paracentesis, surgical iridectomy, simple lens extraction, trabeculectomy, or a combination of lens extraction and trabeculectomy might be chosen. In different scenarios, each technique has been shown to be effective in treating primary angle-closure glaucoma.<sup>[4]</sup>

The most common incisional surgery for the treatment of glaucoma is trabeculectomy, often known as filtering surgery. Because the treatments provide a channel that bypasses the eye's natural outflow pathways, they can considerably reduce IOP. Trabeculectomy is recommended when alternative treatments are unable to keep the IOP at a level considered low enough to avoid further disease progression.<sup>[1]</sup> We performed trabeculectomy since the patient had received maximal pharmacological therapy, but he still had advanced vision field loss in his left eye and his IOP was uncontrolled. Meanwhile, medical treatment and LPI were used to keep the right eye's IOP under control.

Following trabeculectomy surgery; IOP, ACD, and bleb formation are important parameters during assessment of the postoperative status of the patient. The biggest risk of the filtering surgery for PACG was the shallow or flat




Figure 9. Left eye postoperative patient's pictures day-7.

anterior chamber (FAC) postoperatively. It is related to prolonged ocular hypertension and abrupt drop in IOP during surgery. Flat anterior chamber with hypertension is malignant glaucoma, which is special complication with PACG surgery. Malignant glaucoma (aqueous misdirection or ciliary block glaucoma) is a potentially devastating form of glaucoma that presents following ocular surgery in patients with history of angle closure or PAS. It presents with uniform flattening of both central and peripheral anterior chamber. A persistent FAC can lead to lenticular corneal touch, corneal oedema, cataract, hypotony and its related complications like maculopathy and choroidal detachment.<sup>[1],[3],[5]</sup> Trabeculectomy is a surgical treatment that is often performed for glaucoma patient, however it is quite difficult to performed trabeculectomy in PACG patients. Caution is required for the risks of postoperative.

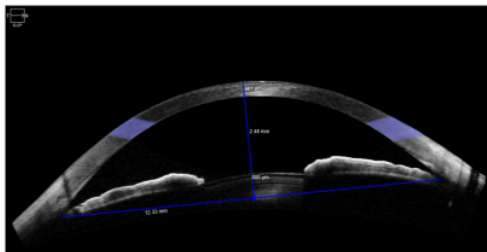
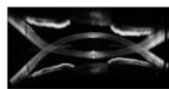
One of the factors driving the development of "nonpenetrating" surgeries for glaucoma, such as deep sclerectomy, has been the desire to eliminate FAC. Surgical revision of the scleral flap with additional sutures, or tightening preexisting sutures to increase resistance to aqueous outflow is also an option.<sup>[6]</sup> On trabeculectomy that we performed, the scleral flap was

Anterior Chamber Analysis : Anterior Chamber

OD ● ○ OS



ACT Measurements	Value
Central Corneal Thickness	481 μm
Angle to Angle Distance	12.33 mm
Lens Vault	800 μm
Anterior Chamber Depth	2.48 mm
Chamber Measurement	Value
Area	18.53 mm <sup>2</sup>



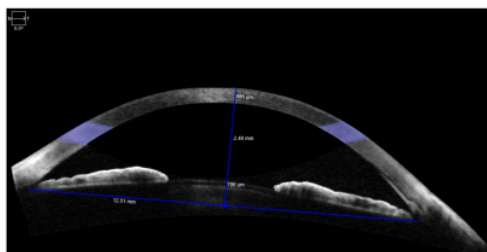
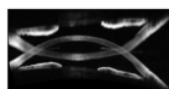
A

Anterior Chamber Analysis : Anterior Chamber

OD ○ ● OS



ACT Measurements	Value
Central Corneal Thickness	495 μm
Angle to Angle Distance	12.51 mm
Lens Vault	786 μm
Anterior Chamber Depth	2.49 mm
Chamber Measurement	Value
Area	19.30 mm <sup>2</sup>



B

Figure 10. Postoperative anterior segment OCT showed shallow anterior chamber; (A) Right eye; (B) Left eye.

thicker and removable sutures were tighter to avoid flattening of anterior chamber.

Every effort should be made to avoid extreme intraoperative and postoperative IOP fluctuations, including maintaining a deep anterior chamber with balanced saline solution or viscoelastic agent, multiple tight sutures, preplacement of sutures, discreet laser suture lysis, and cycloplegic therapy.<sup>[7]</sup> The ultimate purpose of performing a filtration procedure, such as trabeculectomy in a person with glaucoma, is to preserve vision. The ultimate purpose of treatment is preservation of vision, and the way this is accomplished in patients with glaucoma is by lowering IOP.<sup>[6]</sup>

When IOP below 21 mmHg was achieved without medications with good bleb, it was considered as complete success; if with medications then as qualified success and if uncontrolled then as failure.<sup>[3][4]</sup> Our patient's left eye examination showed anterior chamber and bleb formed formations, normal IOP of 12.2 mmHg without glaucoma medications. Some research have been conducted to investigate the effect of trabeculectomy on the eyes of people with diabetes mellitus (DM), however, the results are conflicting. According to several research, diabetes was linked to poorer trabeculectomy outcomes. The fluorouracil filtering surgery study, on the other hand, found that diabetes condition was not related with poorer trabeculectomy outcomes.<sup>[8],[9][10]</sup>

The results of a study to explore the outcome of trabeculectomy with MMC in diabetic PACG patients without retinopathy revealed that long-term IOP was less

managed in diabetic PACG patients without retinopathy's eyes than in eyes without DM. An inflammatory response in the conjunctival dermis and Tenon's capsule characterizes the majority of trabeculectomy failure. Excessive damage to the blood-aqueous barrier after cataract surgery has been linked to diabetes, as has an increase in postoperative inflammation. Similar outcomes should be expected in diabetic patients following trabeculectomy. Long-term IOP variability may play a significant effect in visual field degradation in glaucoma patients who maintain constant IOP control.<sup>7,8</sup> Long-term follow-up is essential to maintain successful trabeculectomy results, which include regulated IOP, patent fistula, structural repair, and glucose levels under control.

The limitation of our study is its short follow-up period long-term follow up is needed to make sure that the benefits of trabeculectomy that were demonstrated one and a half month after surgery will be long term sustained.

Trabeculectomy is a surgical procedure for severe cases of glaucoma. However, it is quite difficult to perform trabeculectomy in primary angle-closure glaucoma (PACG) patients. Close monitoring is required to avoid the risk of postoperative flat anterior chamber and malignant glaucoma in PACG eyes. Long-term follow-up is required to maintain successful trabeculectomy outcomes that are controlled IOP and patent scleral fistula.

## References

- [1] Girkin CA, Bhorade AM, Crowston JG, Giaconi JA, Medeiros FA, Sit AJ, et al., editors. Glaucoma: 2019-2020 Basic and Clinical Science Course, Section 10. San Francisco: American Academy of Ophthalmology; 2019.
- [2] Zhang N, Wang J, Chen B, Li Y, Jiang B. Prevalence of primary angle closure glaucoma in the last 20 Years: A meta-analysis and systematic review. *Front Med* 2021;7:1–10. <https://doi.org/10.3389/fmed.2020.624179>.
- [3] Khairnar AS, Agrawal A, Jadhav VR, Gokhale E, Khobragade V, Nicholson AD. Analysis of shallow anterior chamber following trabeculectomy surgery: A prospective study of 32 eyes. *Int J Contemporary Med Res* 2016;3:2503–2506.
- [4] Chen Y-H, Lu D-W, Cheng J-H, Chen J-T, Chen C-L. Trabeculectomy in patients with primary angle-closure glaucoma. *J Glaucoma* 2009;18:679–683. <https://doi.org/10.1097/IJG.0b013e31819c4a07>.
- [5] Zhu J-D, Xie L-L, Li Z-Y, Lu X-H. The prognosis of trabeculectomy in primary angle-closure glaucoma patients. *Int J Ophthalmol* 2019;12:66–72. <https://doi.org/10.18240/ijo.2019.01.10>.
- [6] de Barros DSM, Navarro JBVK, Mantravadi A V, Siam GA, Gheith ME, Tittler EH, et al. The early flat anterior chamber after trabeculectomy: A randomized, prospective study of

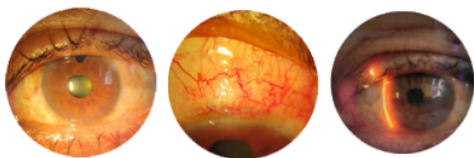


Figure 11. Two months postoperative followed-up left eye patient's pictures

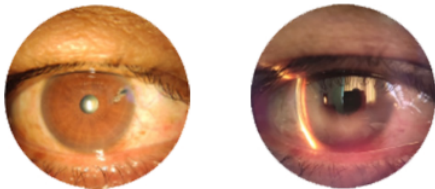


Figure 12. Right eye patient's pictures with slit illumination showing LPI at 2 o'clock and Van Herick I-II OU.

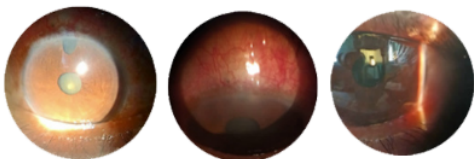


Figure 13. One week after left eye removal removable sutures patient's pictures.

- 3 methods of management. *J Glaucoma* 2009;18:13–20. <https://doi.org/10.1097/IJG.0b013e31816f7647>.
- [7] Salim S. Filtration surgery and primary angle-closure glaucoma. *Glaucoma Today* 2015. <https://glaucomatoday.com/articles/2015-mar-apr/filtration-surgery-and-primary-angle-closure-glaucoma> (accessed November 11, 2021).
- [8] Liu J, Zhang M, Li B, Wang J. Long-term outcomes of primary trabeculectomy in diabetic patients without retinopathy with primary angle-closure glaucoma. *J Ophthalmol* 2017;2017:1–6. <https://doi.org/10.1155/2017/7947854>.
- [9] Hugkulstone CE, Smith LF, Vernon SA. Trabeculectomy in diabetic patients with glaucoma. *Eye* 1993;7:502–506. <https://doi.org/10.1038/eye.1993.109>.
- [10] Jue A. Angiogenesis: Trabeculectomy and bevacizumab. *Semin Ophthalmol* 2009;24:122–125. <https://doi.org/10.1080/08820530902801015>.



# 17. The Difficulties of Trabeculectomy in a Primary Angle-Closure

## ORIGINALITY REPORT

15%

SIMILARITY INDEX

8%

INTERNET SOURCES

12%

PUBLICATIONS

0%

STUDENT PAPERS

## PRIMARY SOURCES

- 1 Xinghuai Sun, Yi Dai, Yuhong Chen, Dao-Yi Yu, Stephen J. Cringle, Junyi Chen, Xiangmei Kong, Xiaolei Wang, Chunhui Jiang. "Primary angle closure glaucoma: What we know and what we don't know", Progress in Retinal and Eye Research, 2017  
Publication 1%
- 2 [www.ncbi.nlm.nih.gov](http://www.ncbi.nlm.nih.gov)  
Internet Source 1%
- 3 Charles E Hugkulstone. "Trabeculectomy in diabetic patients with glaucoma", Eye, 07/1993  
Publication 1%
- 4 M. Reza Razeghinejad, Jonathan S. Myers. "Contemporary Approach to the Diagnosis and Management of Primary Angle-Closure Disease", Survey of Ophthalmology, 2018  
Publication 1%
- 5 Srijana Thapa Godar, KR Kaini. "Study of Retinal Nerve Fiber Layer Thickness by Optical 1%

Coherence Tomography in Primary Open Angle Glaucoma, Glaucoma Suspect and Normal Nepalese Population", Nepal Medical College Journal, 2020

Publication

6

Silvia Sanchez Di Martino. "Asia-Pacific Glaucoma Congress 2021 Abstract Book", Asian Journal of Ophthalmology, 2021

Publication

1 %

7

[www.ijo.in](http://www.ijo.in)

Internet Source

1 %

8

[link.springer.com](http://link.springer.com)

Internet Source

1 %

9

[redcatstudio.ru](http://redcatstudio.ru)

Internet Source

1 %

10

"From the 8th European Neuro-Ophthalmology Society (EUNOS) Meeting", Neuro-Ophthalmology, 2007.

Publication

1 %

11

[dokumen.pub](http://dokumen.pub)

Internet Source

1 %

12

Samin Hong, Chan Yun Kim, Gong Je Seong. "Long-Term Intraocular Pressure Fluctuation and Visual Field Progression in Glaucoma Patients with Low Intraocular Pressure After Post-Trabeculectomy Phacoemulsification",

1 %

# Journal of Ocular Pharmacology and Therapeutics, 2007

Publication

13

[mts.intechopen.com](http://mts.intechopen.com)

Internet Source

<1 %

14

[www.gmcs.edu.in](http://www.gmcs.edu.in)

Internet Source

<1 %

15

[www.uni-erfurt.de](http://www.uni-erfurt.de)

Internet Source

<1 %

16

"Comparison of encirclage and cryotherapy with argon laser in the management of traumatic cyclodialysis cleft", International Journal of Ophthalmology, 2019

Publication

<1 %

17

Titiek Ernawati, Gatut Suhendro, I Ketut Suidiana, Suhartono Taat Putra et al. "Hypoxic Preconditioning Improved Neuroprotective Effect of Bone Marrow-Mesenchymal Stem Cells Transplantation in Acute Glaucoma Models", Journal of Biomedical Science and Engineering, 2016

Publication

<1 %

18

[mail.indonesianjournalofcancer.or.id](http://mail.indonesianjournalofcancer.or.id)

Internet Source

<1 %

19

[www.frontiersin.org](http://www.frontiersin.org)

Internet Source

<1 %

20

"Differences in intraocular lens power calculation in patients with sub-foveal choroidal neovascularization", International Journal of Ophthalmology, 2019

Publication

<1 %

21

S Duman. "Success of trabeculotomy in patients with congenital glaucoma operated on within 3 months of birth", Eye, 01/06/2006

Publication

<1 %

22

Steven J. Gedde, Philip P. Chen, Kelly W. Muir, Kateki Vinod, John T. Lind, Martha M. Wright, Tianjing Li, Steven L. Mansberger. "Primary Angle-Closure Disease Preferred Practice Pattern®", Ophthalmology, 2021

Publication

<1 %

23

[mospace.umsystem.edu](http://mospace.umsystem.edu)

Internet Source

<1 %

24

Marlene R. Moster. "Incisional Therapies: Complications of Glaucoma Surgery", The Glaucoma Book, 2010

Publication

<1 %

25

Nan Zhang, Jiaying Wang, Biyue Chen, Ying Li, Bing Jiang. "Prevalence of Primary Angle Closure Glaucoma in the Last 20 Years: A Meta-Analysis and Systematic Review", Frontiers in Medicine, 2021

Publication

<1 %

26 crimsonpublishers.com  
Internet Source

<1 %

27 ies.ijo.cn  
Internet Source

<1 %

28 journal.unnes.ac.id  
Internet Source

<1 %

Exclude quotes On

Exclude matches Off

Exclude bibliography On

# 17. The Difficulties of Trabeculectomy in a Primary Angle-Closure

---

GRADEMARK REPORT

---

FINAL GRADE

**/100**

GENERAL COMMENTS

**Instructor**

---

PAGE 1

---

PAGE 2

---

PAGE 3

---

PAGE 4

---

PAGE 5

---

PAGE 6

---

PAGE 7

---