

The effectiveness of platelet rich fibrin (PRF) graft to expression of IL-1 and TNF- α in cornea post NaOH exposure: an experimental study

by Hani Plumeriastuti

Submission date: 07-Jun-2023 02:19PM (UTC+0800)

Submission ID: 2110840106

File name: d_TNF-_in_cornea_post_NaOH_exposure_an_experimental_study_1.pdf (614.6K)

Word count: 4824

Character count: 25753

The effectiveness of platelet rich fibrin (PRF) graft to expression of IL-1 and TNF- α in cornea post NaOH exposure: an experimental study



Marisa Surya Airlangga¹, Reni Prastyani^{2*}, Nurwasis²,
Hani Plumeriastuti³, Budi Utomo⁴

¹Study Program of Ophthalmology, Faculty of Medicine, Universitas Airlangga, Dr. Soetomo General Academic Hospital, Surabaya, Indonesia;
²Department of Ophthalmology Faculty of Medicine, Universitas Airlangga, Dr. Soetomo General Academic Hospital Surabaya, Indonesia;
³Department of Anatomical Pathology, Faculty of Veterinary Medicine, Universitas Airlangga, Dr. Soetomo General Academic Hospital, Surabaya, Indonesia;
⁴Department of Public Health Science-Preventive Medicine, Faculty of Medicine, Universitas Airlangga, Surabaya, Indonesia;

*Corresponding author:
Reni Prastyani;
Department of Ophthalmology Faculty of Medicine, Universitas Airlangga, Dr. Soetomo General Academic Hospital Surabaya, Indonesia;
reni-p@fk.unair.ac.id

Received: 2023-02-26
Accepted: 2023-04-02
Published: 2023-04-28

ABSTRACT

Background: Alkaline trauma of cornea often causes irreversible vision loss, even though it is quickly treated. The effectiveness of anti-inflammatory therapy as a main treatment is still limited clinically, as well as has dangerous side effects. Platelet-rich fibrin (PRF) is quite safe and effective in the treatment of descemetocoele and also important in wound healing process. PRF membrane also provides a mechanical function as a framework for cell proliferation, differentiation and migration which is important for tissue regeneration. This study aimed to analyse the effectiveness of PRF grafts on expression of interleukin-1 (IL-1) and tumor necrosis factor- α (TNF- α) in cornea post NaOH exposure.

Methods: An experimental study was conducted on *Oryctolagus cuniculus* which was exposed to 1 N NaOH for 30 seconds. The study subjects were 14 rabbits consisting of 7 PRF graft rabbits and 7 control rabbits. The rabbit's right eye was then irrigated, dripped with 1% levofloxacin 1 drop and a PRF graft was placed. The effectiveness of PRF graft was analysed by percentage of expression of IL-1 and TNF- α in cornea post NaOH exposure.

Results: No significant differences were found in expression of IL-1 ($p>0.05$) and expression of TNF- α ($p>0.05$) in cornea post NaOH exposure. There was a decrease in the expression of IL-1 between control and PRF graft groups. The combination of the mechanical and chemotactic functions of PRF membranes makes them suitable as an autologous biomaterial for reconstruction, repair, and maintenance of ocular surfaces.

Conclusion: PRF plays a significant role in wound healing and preventing excessive fibrosis, therefore it has the enormous potential to reduce the expression of IL-1 in corneal alkaline damage.

Keywords: Platelet-rich fibrin (PRF), IL-1, TNF- α , NaOH.

Cite This Article: Airlangga, M.S., Prastyani, R., Nurwasis, Plumeriastuti, H., Utomo, B. 2023. The effectiveness of platelet rich fibrin (PRF) graft to expression of IL-1 and TNF- α in cornea post NaOH exposure: an experimental study. *Bali Medical Journal* 12(2): 1347-1352. DOI: 10.15562/bmj.v12i2.4389

INTRODUCTION

Ocular alkaline trauma is a common and severe complication in ophthalmology emergency cases, because it often results irreversible vision loss, even if treated quickly.^{1,2,3} The World Health Organization (WHO) report states that the incidence of ocular trauma due to chemicals is 11.5% -22.1% and about 70% is alkaline trauma. Only 15% of severely alkaline trauma patients can experience good functional rehabilitation.^{2,4,5} The effectiveness of anti-inflammatory therapy as a main treatment is still limited clinically, as well as has dangerous side effects.⁶ Platelet-rich fibrin (PRF) is quite safe and effective in the treatment of descemetocoele and also important in wound healing process.^{7,8} PRF graft also provides a mechanical function

as a framework for cell proliferation, differentiation and migration which is important for tissue regeneration.^{4,7} The combination of the mechanical and chemotactic functions of PRF membranes makes them suitable as an autologous biomaterial for reconstruction, repair, and maintenance of ocular surfaces.⁹ This study aimed to analyse the effectiveness of platelet-rich PRF graft to expression of interleukin-1 (IL-1) and tumor necrosis factor- α (TNF- α) in cornea post NaOH exposure.

Various study results were also obtained in studies that focused on analysing the effectiveness of PRF graft to expression of IL-1 and TNF- α .^{4,7,9-11} No available studies about effectiveness of PRF graft to expression of IL-1 and TNF- α in cornea post NaOH exposure. Based on this

background, this study aims to analyse the effectiveness of PRF grafts on expression of IL-1 and TNF- α in cornea post NaOH exposure.

METHODS

The study was an experimental study with post-test only control group design. The study was carried out at the Central Laboratory of Research and Development in the Faculty of Veterinary Medicine, Universitas Airlangga, Surabaya, Indonesia in February 2023. Total of 14 rabbits were submitted in study by random allocation. The samples were divided into a test group that have been PRF graft placement and a control group that haven't. The study subject was male New Zealand white rabbits (*Oryctolagus cuniculus*) aged 4-6

months and weighing 2,500-3,500 grams.

Ocular alkaline trauma was induced by NaOH exposure to the right eye of *Oryctolagus cuniculus*. NaOH exposure was carried out by soaking 7 mm diameter filter paper in NaOH 1N solution for 2 minutes. Filter paper containing NaOH 1N solution was placed on the central corneal area for 30 seconds. Corneal surface then has been irrigated by balanced salt solution (BSS) 20 ml for 30 seconds as well as dropped by levofloxacin 1% 1 drop for minimising secondary infection risk. The test group has been PRF graft placement.

The production of PRF was carried out according to the procedure of Choukroun et al, 2006, which did not require the addition of anticoagulants.¹² Blood specimens were taken from the auricular vein of the rabbit as much as 5 mL and stored in a glass tube. Furthermore, the blood specimen underwent a centrifugation process at 2700 rpm for 12 minutes until three separate layers were formed. The bottom dark red layer was erythrocyte, the middle layer contains fibrin clots, and the top yellow layer was the platelet-poor plasma (PPP) layer. The PPP layer was taken first using a pipette, then the fibrin clot was separated from the erythrocyte layer using scissors and then the fibrin layer was taken by forceps and compressed by a PRF box. PRF box is a membrane-shaped device made specifically to drain excess fluid from the PRF. The PRF membrane was cut to suit the needs of the application on the cornea and then positioned in an overlay covering the entire surface of the cornea. The animals were nucleated on the 4th day for histopathology examination by hematoxylin and eosin staining and immunohistochemical technique with anti-IL-1 and anti TNF- α antibodies.

The enucleated rabbit eyes were fixed in 10% buffered formalin to prevent autolysis and decay for 24 hours at room temperature and embedded in paraffin. The isolated corneal tissue was fixed in 10% neutral buffered formalin (NBF) solution for 48 hours at room temperature. The fixed tissue is 20 mm x 30 mm with a thickness of 2-4 mm in size and every 100 mg of tissue is given 2 ml of formalin so that the fixation process is effective. The paraffin block was cut with a microtome with a thickness of 4 μ m.

The stained tissue was observed using a light microscope with a magnification of 100x as well as documented. The expression levels of IL-1 and TNF- α were analysed using the modified Remmele Scale (Immuno Reactive Score / IRS) (Table 1).¹² It is the multiplying the percentage score of cells or areas that are immunoreactive positive for chromogen brown with the colour intensity score on the cells. The data for each sample is the IRS value average that is observed in 5 (five) fields of view at 400x magnification.

RESULTS

The examination of the ocular anterior segment before study was carried out using a biomicroscope and conditions were found to be within normal limits. During the observation period, each

rabbit received the same treatment. The food provided is in the form of pallets and drinks in the form of mineral water which have been adjusted to the same portion. Levofloxacin was given postoperatively to each rabbit daily for 4 days to prevent secondary infection. Postoperative evaluation using biomicroscope to determine the condition of anterior segment and cornea after exposure to NaOH. Prior to surgery, 5 cc of blood was taken from all rabbits to be processed into PRF membranes. The PRF membrane formed is transparent, not brittle, slightly thicker than the conjunctiva and stable during suturing to the cornea.

During the observation period, on the 12th postoperative day, the condition of rabbits during the treatment period was very good, active movements and stable body weight. The examination by

Table 1. Modified Remmele scale (Immuno Reactive Score / IRS).¹²

Percentage of positive cell	Score	Colour intensity reaction	Score	IRS (0 - 12)
None	0	No colour reaction	0	0 - 1 = Negative
< 10%	1	Weak colour intensity	1	2 - 3 = Weak positive
11-50%	2	Moderate colour intensity	2	4 - 8 = Moderate positive
51-80%	3	Strong colour intensity	3	9 - 12 = Strong positive
> 80%	4			

Data was recorded and analysed by ANOVA test and continued by post hoc test. The results were considered statistically significant if the p-value <0.05.

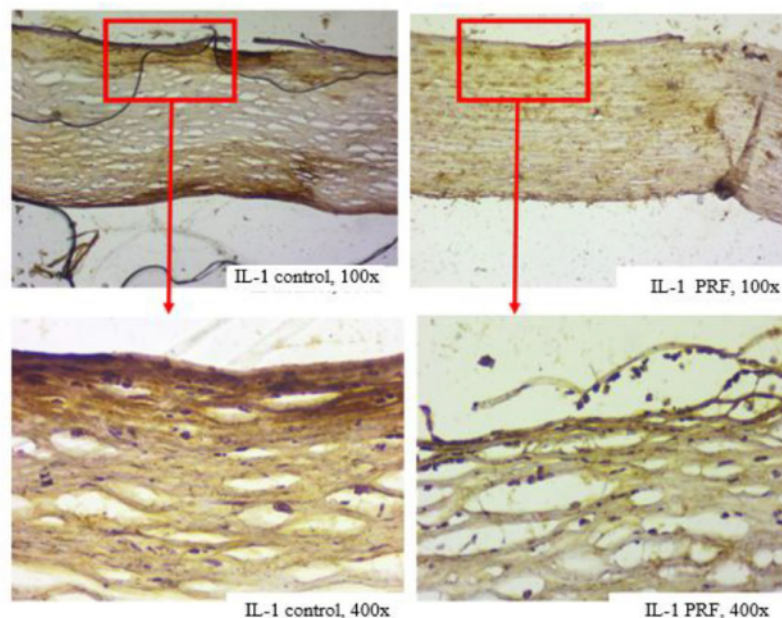


Figure 1. The expression of IL-1 in corneal alkaline trauma.

biomicroscope was found in the PRF graft group, nylon thread sutures were still visible on the 12th day. There is a smooth, non-jagged transition at the edges of the PRF membrane. In both groups, smooth tissue appeared in the defect area which almost resembling corneal tissue. During the observation period, there was no secondary infection.

The IL-1 and TNF- α expression was calculated based on the number of cells expressing IL-1 from 100 corneal cells around the corneal defect with a light microscope magnification of 400 times. The results of immunohistochemical examination with hematoxylin and eosin staining labelled with anti-IL-1 and anti-TNF- α antibodies showed that the comparison of IL-1 and TNF- α expression in the corneal alkaline trauma area between the PRF graft group and the control group. Cells that express IL-1 and

TNF- α have brown cytoplasm (Figure 1 and 2).

The mean of IL-1 expression score in control group was 4.86 ± 3.01 (the highest and lowest IL-1 expression scores were 9.6 and 1.8 respectively), while in with PRF graft group it was 5.46 ± 3.05 (the highest and lowest IL-1 expression scores were 10.2 and 2.0 respectively). When compared between control and PRF graft groups, there was a decrease in the expression of IL-1. The results of the Independent T-test showed that there was no significant difference between control group and PRF graft group $P > 0.05$ ($P = 0.718$). Mean of TNF- α expression score in control group was 5.37 ± 2.81 , while in PRF graft group was 6.80 ± 1.08 . The mean TNF- α expression score in the PRF membrane group was lower than the control group. The Independent T-Test test showed no significant difference between control

group and PRF graft group $P > 0.05$ ($p = 0.234$).

DISCUSSION

Corneal alkaline trauma is an emergency ophthalmology problem because alkaline substances are more damaging than acidic substances due to their inherent ability to penetrate ocular structures due to their hydrophilic and lipophilic properties.¹³ The adverse caustic effect depend on the nature and type of substance involved, as well as the length of time in contact with the eyes. The degree of damage to the ocular surface is one of the most important prognostic factors for visual outcomes.⁷

Previous studies have shown the expression of IL-1a, IL-1b, IL-6, IL-10, and TNF- α mRNA in the corneas of experimental animals after NaOH exposure. The levels of IL-1a and IL-6 correlate with the severity of alkaline burn, and the cellular sources of IL-1a and IL-6 are largely derived from the cornea itself, not from infiltrating inflammatory cells.¹⁵ It happens because the wound healing process on the cornea is a unique and complicated process. Unlike other organs, the cornea is an avascular and transparent organ according to its function. This transparency is a status that is maintained as much as possible in wound healing and against excessive fibrotic processes.^{16,17}

PRF has been known as the agent for wound healing process.⁸ PRF is also useful in the process of healing soft tissue and hard tissue and helps the body's immunity because the fibrin matrix can be properly organized in the process of healing and migration of stem cells directly.¹⁸ PRF, a second-generation platelet concentrate, was created to address the shortcomings of platelet-rich plasma (PRP). PRF has the ability to produce a greater cumulative release of growth factors than PRP. Furthermore, PRF release is slow and

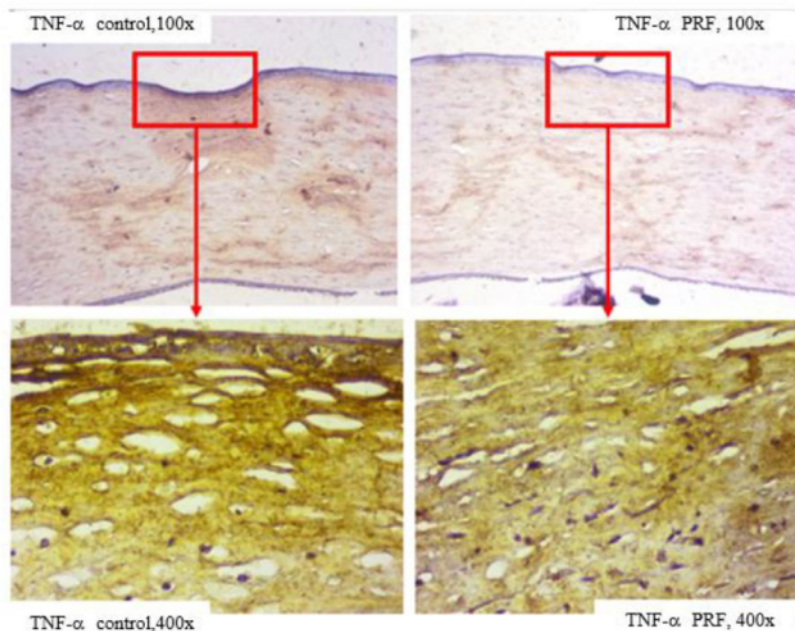


Figure 2. The expression of TNF- α in corneal alkaline trauma.

Table 2. Comparison of IL-1 and TNF- α expression score.

Group	N	Median	Mean	SD	Minimal	Maximal	p-value
IL-1 expression score							0.718
Control	7	5.60	4.86	3.01	1.8	9.6	
PRF	7	4.20	5.46	3.05	2.0	10.2	
TNF-α expression score							0.234
Control	7	4.80	5.37	2.81	2.2	9.2	
PRF	7	7.20	6.80	1.08	5.2	8.0	

IL-1: interleukin-1; TNF- α : tumor necrosis factor- α ; PRF: platelet-rich fibrin

prolonged, so that it is ideal for tissue regeneration and growth stimulation.¹⁹ Separation of blood layers prior to clotting in PRF requires a quick and brief centrifugation procedure. A fibrin matrix forms in the platelet-rich layer, encasing platelets and leukocytes.²⁰ Platelet-rich fibrin can release growth factors slowly with high amounts including TGFβ-1, PDGF and VEGF within one to two weeks. It happens because PRP undergoes polymerization which will cause active platelets to get trapped in fibrin nets so that most of the growth factors are released in the first hours.²¹⁻²³

PRF membrane that was produced in this study was stored in a glass tube without anticoagulant. The absence of anticoagulants, platelets would be activated within minutes when the blood sample contacts the tube wall and the coagulation cascade is released. Fibrinogen is initially concentrated in the upper part of the tube before thrombin converts it to fibrin. In theory, many platelets are trapped in the fibrin network.^{4,20}

Platelet degradation results in the release of cytokines that can stimulate cell migration and proliferation in the fibrin matrix, triggering the initial stages of the healing process.²³ Clinical studies have shown that this biomaterial would be a good matrix for healing without excessive inflammation. This new biomaterial is neither like fibrin glue nor classic platelet concentrates.^{9,11,24} The results of the examination on the 8th day by biomicroscope, in PRF graft group, re-epithelialization was seen in the form of a smooth transition area without jagged between the edges of the graft and the glasses around it. This is in line with the study of Guérin et al, 2021 that the PRF membrane in rabbit eyes have re-epithelialized in the first postoperative week.²⁵ Examination on the 12th day found in both soft tissue groups with vascularization in the defect area that almost resembled the surrounding re-epithelialized tissue.

Effect of PRF graft on corneal IL-1 expression

Epithelial cell death because of alkaline trauma will release IL-1 into keratocytes and it will undergo apoptosis. The wider

the corneal damage, the wider the process of apoptotic keratocytes.²⁶ The keratocyte apoptosis occurs as a defence response to reduce the spread of foreign substances.¹⁶ Keratocytes that do not undergo apoptosis (depending on the concentration of IL-1 exposure) will be activated to become fibroblasts. Fibroblasts help trigger cell differentiation, migration and proliferation to close wounds.²³ In addition to apoptosis processes in keratocytes, tissue damage also causes the release of inflammatory cells that trigger corneal stromal necrosis and corneal melting. Many cytokines and chemokines are involved in healing corneal scar tissue, one of the earliest and most important is IL-1. IL-1 in the cornea is produced by epithelial tissue and corneal stroma, it is also produced by macrophages and monocytes.²² IL-1 will bind to the IL-1 receptor (IL-1R) and produce biological activity, which mainly play a role in the corneal ulcers.²⁸

The histopathological results of study showed IL-1 expression in the cornea of the control group rabbits showing an area around the corneal defect with cells expressing IL-1 showing brown cytoplasm, whereas in the PRF membrane test group there was a reduced defect area marked by reduced brown cytoplasmic features. These results are in line with the study of Sánchez-Ávila et al, 2021 which stated that the control group had areas infiltrated with inflammatory cells which were characterized by the presence of goblet cells. Abnormal epithelium with multiple layers of epithelial cells, stromal blood vessels, as well as inflammatory cell infiltration was observed in all the histopathological features of the control group. The PRF graft group had normal corneas with multilayered peripheral and central epithelium with 3-5 layers of epithelial cells, with slight infiltration of inflammatory cells in the matrix and limbal areas. It also has showed normal morphology in the absence of goblet cells.²⁹

This study also showed that there was a difference between the control group and the PRF membrane test group, where IL-1 expression in the PRF membrane group was lower than the control group, although the difference was not statistically significant. These results are in

line with the study of Sánchez-Ávila et al, 2021 which stated that the fibrin-plasma rich in growth factors (PRGF) membrane repaired chemically induced lesions. However only the fibrin-PRGF membrane cultured with rabbit limbal epithelial progenitor cells (LEPC) was able to restore the corneal surface.²⁹

Effect of PRF membrane on corneal TNF-α expression

TNF-α, as a strong pro-inflammatory cytokine plays an important role in the immune system during inflammation, cell proliferation, differentiation, and apoptosis in alkaline trauma as well as mediates the neovascularization and scarring.³⁰ TNF-α also has a role in the inflammation that induces vasodilation, edema and leukocyte extravasation.^{31,32} Decreased expression of TNF-α will indicate that the inflammatory process can be suppressed so that it can reduce the potential fibrosis and promote better wound healing. TNF-α is usually produced together with interleukins which have the potential to change vascular and cellular pro-inflammation.³¹⁻³³ TNF-α inhibition is required when neovascularization occurs thereby reducing the possibility of corneal fibrosis.^{31,32}

A bidirectional interaction between the epithelium and the corneal stroma will occur and IL-1 and TNF-α will be released by epithelial cells causing keratocyte apoptosis. Apoptosis of keratocytes in cells under the corneal injury appears a 32 minutes after the injury occurs.^{16,26} The results of this study indicate that PRF cannot reduce TNF-α expression. This can be seen from the median average of TNF-α value in the PRF graft group was higher than the control group. The results are not in line with the several studies which stated that platelet rich plasma (PRP) reduced TNF-α concentrations when compared to the control group, so that corneal ulcers significantly improved. Platelet rich plasma also shows suppression of inflammatory mediator concentrations such as TNF-α gene expression and IL-1 synthesis that is mediated by TNF-α, interferon (IFN) α, β, γ, as well as bacterial endotoxins. Its main activity stimulates helper T lymphocytes and TNF-α.³⁴⁻³⁸

Pezzotta et al, 2012 suggested that

plasma rich growth factor (PRGF) should not be used for large ulcers where neovascularization (due to the natural repair mechanisms of the corneal stroma) has occurred, because it enhances the formation of a new reservoir of subsequent corneal opacities, so that it increases the loss vision rates.³⁹ The limitations of this study were that the observation period was relatively short, only 4 days, it was only done at one time, and it was not carried out serially for a longer time so that it was not possible to evaluate the effect of the PRF graft on each phase of corneal wound healing. In addition, only IL-1 and TNF- α examined immunohistochemical parameters, while other pro-inflammatory cytokines that played a role in the healing phase of the cornea were not studied. Measurement of IL-1 and TNF- α expression was not carried out before surgery so that the results of the examination could not be known before PRF graft was given. Based on statistics, the sample size is not much, whereas the larger the number of samples, the better able to represent the population.

CONCLUSION

PRF graft has the great potency to decrease the expression of IL-1 in corneal alkaline trauma, because it has an important role in wound healing and preventing excessive fibrosis. However, advanced study must be done to get the optimal technique preparation and setting-up of PRF graft, so that they can give the better anti-inflammatory effect

CONFLICT OF INTEREST

The authors affirmed that there were no conflicts of interest in this study.

FUNDING

The authors were responsible for all research funding without obtaining financial support.

ETHICAL CLEARANCE

This study has obtained ethical clearance from the Research Ethics Committee of Faculty of Veterinary Medicine, Universitas Airlangga, Surabaya with reference letter number 2.KEH.007.01.2023.

AUTHOR CONTRIBUTION

All authors contributed equally in this research and publication of this manuscript.

REFERENCES

- Nababan AR, Suryowati DI, Komarath E, Primitasari Y, Legowo D, Notopuro PB, Notobroto HB. Platelet-rich fibrin (PRF) graft and amniotic membrane graft on transforming growth factor- β (TGF- β) and type 1 collagen post conjunctival excision. *Bali Medical Journal*. 2022;11(3):1744-1750.
- Singh P, Tyagi M, Kumar Y, Gupta KK, Sharma PD. 2013. Ocular chemical injuries and their management. *Oman J. Ophthalmol*. 2013;6:83.
- Choi SY, Kim S, Park KM. Initial healing effects of platelet-rich plasma (PRP) gel and platelet-rich fibrin (PRF) in the deep corneal wound in rabbits. *Bioengineering (Basel)*. 2022;9(8):405.
- Eslani MA, Baradaran-Rafii A, Movahedan. 2014. Review article the ocular surface chemical burns. *J Ophthalmol*. 2014;1-7.
- Camacho C, Rojas E. Platelet-rich fibrin membrane for pterygium surgery: Literature review and feasibility assessment. *Cureus*. 2021;13(9):e17884.
- Mirabelli P, Peebo BB, Xeroudaki M, Koulikovska M, Lagali N. Early effects of dexamethasone and anti-VEGF therapy in an inflammatory corneal neovascularization model. *Exp Eye Res*. 2014;125:118-127.
- Şentürk E, Bahadır O, Aktaş O, Büyük AF, Ercan E. Effects of titanium prepared platelet rich fibrin on facial nerve regeneration: an experimental study. *Braz J Otorhinolaryngol*. 2022;88(6):867-874.
- Demir A, Erdikmen DO, Altundag Y, Sevim ZT. Evaluation of surgical treatment using PRF membrane in deep corneal ulcers accompanied by a descemetocele in cats: retrospective study (2019-2021). *Kafkas Universitesi Veteriner Fakültesi Dergisi*. 2022;28.
- Ghanaati S, Booms P, Orłowska A, Kubesch A, Lorenz J, Rutkowski J, Landes C, Sader R, Kirkpatrick CJ, Choukroun J. Advanced platelet-rich fibrin: a new concept for cell-based tissue engineering by means of inflammatory cells. *Journal of Oral Implantology*. 2014;40: 679-689.
- Dohan DM, Choukroun J, Diss A, Dohan SL, Dohan AJJ, Mouhyo J, Gogly B. Platelet-rich fibrin (PRF): A second-generation platelet concentrate. Part I: Technological concepts and evolution. *Oral Surg Oral Med Oral Pathol Oral Radiol Endod*. 2006;101:37-44.
- Miron RJ, Fujioka-Kobayashi M, Bishara M, Zhang Y, Hernandez M, Choukroun J. Platelet-rich fibrin and soft tissue wound healing: a systematic review. *Tissue Engineering & Regenerative Medicine International Society*. 2017;23(1):83-99.
- Choukroun J, Diss A, Simonpieri A, Girard MO, Schoeffler C, Dohan SL, Dohan AJ, Mouhyi J, Dohan DM. Platelet-rich fibrin (PRF): a second-generation platelet concentrate. Part IV: clinical effects on tissue healing. *Oral Surg Oral Med Oral Pathol Oral Radiol Endod*. 2006;101(3):e56-60.
- Bunker DJL, George RJ, Kleinschmidt A, Kumar RJ, Maitz P. Alkali-related ocular burns: a case series and review. *J Burn Care Res*. 2014;35:261-268.
- Moreno-Arrones J, Merayo-Llodes J, Varilla D. Ocular chemical burns in the workplace: epidemiological characteristics. *Burns*. 2020;46:1212-1218.
- Gustianty E, Yandi N, Rifada RM, Prahasta A. Successful rate of glaucoma surgery in uveitis glaucoma. *Bali Medical Journal*. 2022;11(2): 614-618.
- Sánchez-Ávila RM, Vázquez N, Chacón M, et al. Fibrin-plasma rich in growth factors membrane for the treatment of a rabbit alkali-burn lesion. *Int J Mol Sci*. 2021;22(11):5564.
- Wedari NLPH, Budayanti NNS, Sukrama IDM, Mayura IPB. Implementation of antinuclear antibodies in autoimmune diagnostic tests: a literature review from immunological aspects. *Journal of Clinical Microbiology and Infectious Diseases*. 2022;2(2):27-30.
- de Carvalho CKL, Fernandes BL, de Souza MA. Autologous Matrix of Platelet-Rich Fibrin in Wound Care Settings: a systematic review of randomized clinical trials. *J Funct Biomater*. 2020;11(2):31.
- Arnalich F, Rodriguez AE, Luque-Rio A, Alio JL. Solid platelet rich plasma in corneal surgery. *Ophthalmol Ther*. 2016;5(1):31-45.
- Ehrenfest DM, Rasmusson L, Albrektsson T. Classification of platelet concentrates: from pure platelet-rich plasma (P-PRP) to leucocyte- and platelet-rich fibrin (L-PRF). *Trends Biotechnol*. 2009;27(3):158-167.
- Naik, B, Karunakar P, Jayadev M, Rahul MV. 2013. Role of platelet rich fibrin in wound healing: a critical review. *J Conserv Dent*. 2013;16, 284-293.
- Vahabi S, Vaziri S, Torshabi M, Esfahrood ZR. Effects of plasma rich in growth factors and platelet-rich fibrin on proliferation and viability of human gingival fibroblasts. *J Dent Tehran Univ Med Sci*. 2015;12:504-512.
- Medeiros CS, Marino GK, Santhiago MR, Wilson SE. The corneal basement membranes and stromal fibrosis. *Investigative Ophthalmology & Visual Science*. 2018;59(10), 4044-4053.
- Sanchez-Avila RM, Merayo-Llodes J, Riestra AC, et al. Plasma rich in growth factors membrane as adjuvant treatment in the surgery of ocular surface disorders. *Medicine (Baltimore)*. 2018;97(17):e0242.
- Guérin LP, Le-Bel G, Desjardins P, et al. The human tissue-engineered cornea (hTEC): Recent Progress. *Int J Mol Sci*. 2021;22(3):1291.
- Kamil S, Mohan RR. Corneal stromal wound healing: major regulators and therapeutic targets. *Ocular Surface*. 2021; 290-306.
- Rudner XL, Kernacki KA, Barrett RP, Hazlett LD. Prolonged elevation of IL-1 in *Pseudomonas aeruginosa* ocular infection regulates macrophage-inflammatory protein-2 production, polymorphonuclear neutrophil persistence, and corneal perforation. *Journal of Immunology*. 2000;164(12), 6576-6582.

28. Nishida T, Saika S, Morishige N. Cornea and sclera: anatomy and physiology. *Cornea*. 2017;1:1–22.
29. Sánchez-Ávila R, Vázquez N, Chacón M, Persinal-Medina M, Brea-Pastor A, Berisa-Prado S, Fernández-Vega-Cueto L, Anitua E, Meana Á, Merayo-Llodes J. Fibrin-plasma rich in growth factors membrane for the treatment of a rabbit alkali-burn lesion. *Int J Mol Sci*. 2021;22, 5564.
30. Cade F, Paschalis EI, Regatieri CV, Vavvas DG, Dana R, Dohlman CH. Alkali burn to the eye: protection using TNF- α inhibition. *Cornea*. 2014;33, 382–389.
31. Silva LB, dos Santos Neto AP, Maia SMAS, dos Santos Guimarães C, Quidute IL, Carvalho A, de AT, Júnior SA, Leão JC. The role of TNF- α as a proinflammatory cytokine in pathological processes. *Open Dent J*. 2019;13, 332–338.
32. Ferrari G, Bignami F, Rama P. Tumor necrosis factor- α inhibitors as a treatment of corneal hemangiogenesis and lymphangiogenesis. *Eye Contact Lens Sci Clin Pract*. 2015;41:72–76.
33. Hu X, Xu MX, Zhou H, Cheng S, Li F, Miao Y, Wang Z. Tumor necrosis factor- α aggravates gliosis and inflammation of activated retinal Müller cells. *Biochem Biophys Res Commun*. 2020;531, 383–389.
34. Siska, Memed FK, Musa IR. Factors influence bullous keratopathy post cataract surgery at National Eye Center of Cicendo Eye Hospital (PMN RSMC), West Java, Indonesia. *Bali Medical Journal*. 2020;9(3):840-843.
35. Alio JL, Rodriguez AE, Martinez LM, Rio AL. Autologous fibrin membrane combined with solid platelet-rich plasma in the management of perforated corneal ulcers: a pilot study. *JAMA Ophthalmol*. 2013; 131(6):745-51.
36. Kim KM, Shin YT, Kim HK. Effect of autologous platelet rich plasma on persistent corneal epithelial defect after infectious keratitis. *Jpn Ophthalmol*. 2012; 56(6): 544-50.
37. López-Plandolit S, Morales MC, Freire V, Etxebarria J, Durán JA. Plasma rich in growth factors as a therapeutic agent for persistent corneal epithelial defects. *Cornea*. 2010;29(8):843-8.
38. Rezende MS, Silva CA, Antunes VC, Ribeiro LE, Tatsui N, Cvintal T. Uso do concentrado de plaquetas em doença da superfície ocular. *Rev Bras Oftalmol*. 2007; 66(4):257-61.
39. Pezzotta S, Del Fante C, Scudeller L, Cervio M, Antoniazzi ER, Perotti C. Autologous platelet lysate for treatment of refractory ocular GVHD. *Bone Marrow Transplant*. 2012;47(12):1558-63.



This work is licensed under a Creative Commons Attribution

The effectiveness of platelet rich fibrin (PRF) graftto expression of IL-1 and TNF- α in cornea postNaOH exposure: an experimental study

ORIGINALITY REPORT

16%

SIMILARITY INDEX

14%

INTERNET SOURCES

10%

PUBLICATIONS

0%

STUDENT PAPERS

PRIMARY SOURCES

1	www.ncbi.nlm.nih.gov Internet Source	3%
2	www.mdpi.com Internet Source	1%
3	ejournal.iainpalopo.ac.id Internet Source	1%
4	Nagwa Ali Fahmy Diab, Al-shimaa M. Ibrahim, Aya Mohamed Abdallah. "Fluid Platelet-Rich Fibrin (PRF) Versus Platelet-Rich Plasma (PRP) in the Treatment of Atrophic Acne Scars: A Comparative Study", Archives of Dermatological Research, 2022 Publication	1%
5	www.rbojournal.org Internet Source	1%
6	journals.plos.org Internet Source	1%

7	Internet Source	1 %
8	"Platelet-Rich Fibrin Natural and Biologic Blood Concentrate", Horizontal Alveolar Ridge Augmentation in Implant Dentistry A Surgical Manual, 2016. Publication	<1 %
9	www.scitepress.org Internet Source	<1 %
10	bsdwebstorage.blob.core.windows.net Internet Source	<1 %
11	link.springer.com Internet Source	<1 %
12	www.scielo.br Internet Source	<1 %
13	bbrc.in Internet Source	<1 %
14	Dohan, D.M.. "Platelet-rich fibrin (PRF): A second-generation platelet concentrate. Part III: Leucocyte activation: A new feature for platelet concentrates?", Oral Surgery, Oral Medicine, Oral Pathology, Oral Radiology and Endodontology, 200603 Publication	<1 %
15	etd.uwc.ac.za Internet Source	<1 %

16	repository.unair.ac.id Internet Source	<1 %
17	academic.oup.com Internet Source	<1 %
18	assets.researchsquare.com Internet Source	<1 %
19	doaj.org Internet Source	<1 %
20	hygeiadesenv.fsp.usp.br Internet Source	<1 %
21	ia601806.us.archive.org Internet Source	<1 %
22	progressinorthodontics.springeropen.com Internet Source	<1 %
23	www.ejomr.org Internet Source	<1 %
24	www.researchsquare.com Internet Source	<1 %
25	Luigi Fabrizio Rodella. "Growth factors, CD34 positive cells, and fibrin network analysis in concentrated growth factors fraction", Microscopy Research and Technique, 08/2011 Publication	<1 %
26	knapublishing.com Internet Source	<1 %

27 Diamantis Almaliotis, Georgios Koliakos, Eleni Papakonstantinou, Anastasia Komnenou et al. "Mesenchymal stem cells improve healing of the cornea after alkali injury", Graefe's Archive for Clinical and Experimental Ophthalmology, 2015
Publication <1 %

28 Necdet Özçay, Handan Özdemir, Hasan Besim. "Role of platelet-rich fibrin on intestinal anastomosis wound healing in a rat", Biomedical Materials, 2018
Publication <1 %

29 Rajiv R. Mohan, Duraisamy Kempuraj, Sharon D'Souza, Arkasubhra Ghosh. "Corneal stromal repair and regeneration", Progress in Retinal and Eye Research, 2022
Publication <1 %

30 Ujjal Didar Singh Sekhon, Anirban Sen Gupta. "Platelets and Platelet-Inspired Biomaterials Technologies in Wound Healing Applications", ACS Biomaterials Science & Engineering, 2017
Publication <1 %

31 dx.doi.org
Internet Source <1 %

32 medind.nic.in
Internet Source <1 %

33 open.library.ubc.ca

Internet Source

<1 %

34

synapse.koreamed.org

Internet Source

<1 %

35

www.hindawi.com

Internet Source

<1 %

36

www.osapublishing.org

Internet Source

<1 %

37

www.revsalus.com

Internet Source

<1 %

38

jurnal.uinsu.ac.id

Internet Source

<1 %

39

Renjith P. Nair, A. Priyanka, A.S. Safeena, Ranjith S. Kartha, V. Anilkumar, P. Lekshmi, Anugya Bhatt. "Blood-derived products in wound healing and repair", Elsevier BV, 2022

Publication

<1 %

40

Richard J. Miron, Jihua Chai, Shihang Zheng, Mengge Feng, Anton Sculean, Yufeng Zhang. "A novel method for evaluating and quantifying cell types in platelet rich fibrin and an introduction to horizontal centrifugation", Journal of Biomedical Materials Research Part A, 2019

Publication

<1 %

Exclude quotes Off

Exclude matches Off

Exclude bibliography On

The effectiveness of platelet rich fibrin (PRF) graftto expression of IL-1 and TNF- α in cornea postNaOH exposure: an experimental study

GRADEMARK REPORT

FINAL GRADE

/0

GENERAL COMMENTS

Instructor

PAGE 1

PAGE 2

PAGE 3

PAGE 4

PAGE 5

PAGE 6
