

Effect of Moringa oleifera leaf extract on the Histopathological Features of Testicular Seminiferous Tubules of Mice (*Mus musculus*) Exposed to Methyl mercury

by Hani Plumeriastuti

Submission date: 12-Jun-2023 02:02PM (UTC+0800)

Submission ID: 2114259405

File name: us_Tubules_of_Mice_Mus_musculus_Exposed_to_Methyl_mercury_1.pdf (1.3M)

Word count: 3052

Character count: 16442

Effect of *Moringa oleifera* leaf extract on the Histopathological Features of Testicular Seminiferous Tubules of Mice (*Mus musculus*) Exposed to Methyl mercury

Annise Proboningrat, Hani Plumeriastuti, Suzanita Utama, Sri Agus Sudjarwo, Djoko Legowo, Epy Muhammad Luqman and Widjiati

Department of Veterinary Science, Faculty of Veterinary Medicine, Universitas Airlangga, Jalan Mulyorejo, Surabaya 601 15 Indonesia

(Received 22 March, 2021; Accepted 19 September, 2021)

18

ABSTRACT

This study aims to prove the effect of *Moringa oleifera* leaf extract on the histopathological features of seminiferous tubules of mice (*Mus musculus*) exposed to methylmercury. A total of 20 male mice were divided into five groups (C-, C+, T1, T2, T3) and treated for 21 days. C- given 0.01 ml of aquadest, C+ was given 0.4 mg/kg of methyl mercury, T1 was given 200 mg/Kg of *Moringa oleifera* leaf extract + 0.4 mg/Kg of methyl mercury, T2 was given 400 mg/Kg of *Moringa oleifera* leaf extract + 0.4 mg/Kg bw of methylmercury, and T3 were given 800 mg/Kg of *Moringa oleifera* leaf extract + 0.4 mg/Kg of methylmercury. The histopathological features of the seminiferous tubules were examined using the Modified Johnsen Scoring method. The data obtained were analyzed using the Kruskal-Wallis and Mann-Whitney tests. The results showed that *Moringa oleifera* leaf extract reduced the level of damage to the testicular seminiferous tubules of mice (*Mus musculus*) exposed to methylmercury. *Moringa oleifera* leaf extract at a dose of 400 mg/Kg bw gave the best protective effect compared to the doses of 200 and 800 mg/Kg bw.

Key words: *Moringa oleifera*, Methylmercury, Seminiferous tubules, *Mus musculus*, Reproductive health

Introduction

Increased progress of industry in Indonesia from year to year, besides have a positive impact in the form of increased employment, improved transportation and communications as well as rising standards of living, it also being a great potential as a source of environmental pollution (Rianto, 2010) in the form of industrial waste. One of the industrial waste that has become a source of the most dangerous environmental pollutants is heavy metals, such as mercury (Agustina, 2010).

Mercury consists of three main forms, elemental mercury, organic mercury, and inorganic mercury. Methylmercury is one of the most popular form of organomercury and is the most toxic mercury compounds. Methylmercury poisoning case ever been a big news after the second world war in Japan in the 1950s, known as Minamata Disease. This involved 700 cases of poisoning and over 70 deaths (Timbrell, 2002).

In Indonesia, Mercury content in some rivers especially in East Java has exceeded the threshold set by the government (0.001 ppm) (Achmad, 2012).

Research conducted by Shovitri *et al.* (2010) in Zulaika *et al.* (2011), showed levels of mercury in 2009 in the central part of the sediment in Kalimas Surabaya is 0.105 ppm and increase in 2011 in the downstream of sediments in Kalimas of 6.3 ppm.

The main route of methylmercury exposure was through marine organisms which are often consumed by humans and animals (Beyrouthy *et al.*, 2006). Methylmercury is very easily absorbed by the body through the digestive tract, go into circulation and quickly distributed to all organ systems (Inswiasri, 2008) including reproductive system (Dava, 2012). Mercury had been proven to cause damage to the male reproductive system and may result in high rate of infertility to the population (Asomugha *et al.*, 2015). El-Desoky *et al.* (2013) referred that methylmercury causes changes in the morphology of the seminiferous tubules, degeneration and dissociation of spermatogenic cells.

Moringa oleifera known for its many pharmacological activities such as antimicrobial, anti-inflammatory, anti-cancer, antihepatotoxic, antioxidant, cardiovascular, antiepileptic, antiasthmatic, anti-diabetic, antiurolithiatic, diuretic, anthelmintic, antiulcer, wound healing, analgesic, CNS depressant, and anti cancer activities (Ganatra *et al.*, 2012).

Previous study indicated that *Moringa oleifera* leaf extract could prevent testicular toxicity from alcohol (Basseyy *et al.*, 2013) and chromium exposure (Akunna *et al.*, 2012). The administration of *Moringa oleifera* leaf extract also showed normal arrangement of germinal cells, Sertoli cells, Leydig cells with enhanced spermatid cells on mercury chloride exposure (Asomugha *et al.*, 2015).

The aim of this research was to investigate the effect of *Moringa oleifera* leaf extract in reducing the damage of the testicular seminiferous tubules of mice (*Mus musculus*) exposed to methylmercury.

Materials and Methods

Materials used in this research include methylmercury in the form of Methylmercury(II)chloride with chemical formula (CH_3ClHg) (Sigma-Aldrich, 44253, Singapore), sterile aquadest, *Moringa oleifera* leaves, ethanol 96 %, broiler feed, 0.5 % Na CMC, and 10 % of Neutral Buffered Formalin, 70, 80, 90 and 96 % alcohol, xylol, paraffin, entellan and Hematoxylin Eosin.

The equipments used in this research include: mice cage, rotavapor, analytical scale, intu-

bation needle for mice, 1 ml tuberculin syringes, surgical scissors, forceps, scalpel, plastic pots, object glass, cover glass, microscope, camera, a series of dehydration apparatus, microtome, water bath and hot plate.

Animals

The experimental animals used in this study were healthy male mice (*Mus musculus*) strain BALB/C with an average weight of 20-40 grams, 16 weeks old. Mice were then adapted for a week, provided them with balanced diet and water *ad libitum* daily.

Preparation of *Moringa oleifera* Leaf Extract

Fresh leaves of *Moringa oleifera* were collected, shade dried and pounded into powder before extraction. Ethanolic extract of *Moringa oleifera* leaf was obtained by means of maceration method. *Moringa* leaf powder (500 g) soaked in 3750 ml of 96 % ethanol for five days, and the ultrasonic was done for 10 minutes. Filtration was done to separate the dregs from the solution. Then the dregs soaked again in 96 % ethanol (remacerated), maceration was performed three times and the pooled macerate was then evaporated using a rotavapor at 50 °C for 4-5 hours to obtain a viscous extract.

Experimental Design

This research included experimental design with Completely Randomized Design. Twenty male mice (*Mus musculus*) were divided into five groups. C " were administered 0.01 ml/g bwaquadest, C + were administered 0.4 mg/kg bw methylmercury, T 1 were administered 200 mg/kg bw *Moringa oleifera* leaf extract + 0.4 mg/kg bw of methylmercury, T 2 were administered 400 mg/kg bw *Moringa oleifera* leaf extract + 0.4 mg/kg bw methylmercury, T 3 were administered 800 mg/kg bw *Moringa oleifera* leaf extract + 0.4 mg/kg bw methylmercury. Treatment was done by means of intragastric gavage for 21 days. At the end of the experimental period, mice from all groups were sacrificed by cervicalis dislocation method.

Tissue Processing for Histology

The organs were processed for histological work as follows: one testis from each animal was fixed in 10 % of Neutral Buffered Formalin. The fixed tissues were transferred to a graded series of alcohol and then cleared in xylol. Once cleared, the tissues were infiltrated in molten paraffin at 56-60 °C. serial sec-

tions of 3 µm thickness were obtained from a solid block of tissue, cleared, fixed in clean slides, stained with Hematoxylin and Eosin stains.

Microscopic Examination

Tissues were examined using microscopic magnification of 100 times. The histopathological patterns of testicular seminiferous tubules were evaluated and categorizing according to Modified Johnson's scoring.

Data Analysis

Data on histopathological features of testes in each group were analyzed statistically using Kruskal-Wallis followed by Mann-Whitney test to compare the treatment effect of each group. Statistical analysis was performed using SPSS20.0 for Windows software (SPSS, Chicago, IL, USA).

Results and Discussion

Kruskal-Wallis analysis showed a highly significant difference ($p < 0.01$) among the groups. Subsequently continued with Mann-Whitney test to determine the differences between two groups.

The result indicated significant difference between groups C - and C + ($p < 0.05$). It exhibited the

Table 1. Mean and Standard Deviation of Testicular Seminiferous Tubules Score Post Treatment

Groups	Mean ± SD
C -	9.78 ^a ± 0.17
C +	7.38 ^a ± 1.80
T 1	7.98 ^c ± 0.32
T 2	9.78 ^a ± 0.10
T 2	9.35 ^b ± 0.17

Different superscript in the same column refers to significant difference ($p < 0.05$). C - = mice received only 0.2 ml aquadest; C + = mice received 0.4 mg/kg bw methylmercury; T 1 = mice received 200 mg/kg bw *Moringa oleifera* leaf extract + 0.4 mg/kg bw of methylmercury; T 2 = mice received 400 mg/kg bw *Moringa oleifera* leaf extract + 0.4 mg/kg bw of methylmercury; T 3 = mice received 800 mg/kg bw *Moringa oleifera* leaf extract + 0.4 mg/kg bw of methylmercury.

evidence of seminiferous tubules epithelial cells damage with methylmercury poisoning. Lee and Dixon (1975) and Homma-Takeda *et al.* (2001) in Da Silva *et al.* (2012) reported that methylmercury could pass through the blood-testis barrier, affecting di-

rectly on developing germ cell and inhibit spermatogenesis.

Methylmercury had been found to react with macromolecules (lipids, proteins, DNA, RNA) within the cell, inducing lipid peroxidation (12). Methylmercury was known to induces reactive oxygen species (ROS) and disrupts the mitochondrion. The damaged mitochondrion causing the impairment of ATP production, depletion of glutathione (GSH) increasing the production of ROS and nuclear damage (Do Nascimento *et al.*, 2008; Kaur, 2008).

Methylmercury also bound to intracellular GSH, disrupted the GSH synthesis by inhibition of glutamate uptake as well as a number of amino acids that were associated with cell's GSH-synthesis (Do Nascimento *et al.*, 2008), and bound to selenium in the active sites of selenium-dependent enzymes (selenoenzymes), inhibiting their activity (Ralston *et al.*, 2008).

Previous studies of mercury chloride exposure in rats indicated the marked testicular spermatogenic degeneration at the spermatocyte level, decrease of luminal spermatozoa, irregular basement membrane, disorganization and degeneration of spermatogenic cells, hemorrhage in interstitial tissues and congestion of blood vessels (Muthu and Krishnamoorthy, 2012; El-Desoky *et al.*, 2013).

This research showed significant differences between groups C +, T 1, and T 3, it exhibited the reduction in seminiferous tubules epithelial cells damaged with *Moringa oleifera* leaf extract administration ($p < 0.05$). However, there was no significant difference between groups C + and T 1 ($p > 0.05$), it might be due to the dose of 200 mg/kg bw of the *Moringa oleifera* leaf extract was not sufficient to provide a protective effect against testicular exposed to methylmercury.

There was no significant difference ($p > 0.05$) between groups C - and T 2, but there was significant difference ($p < 0.05$) between groups C - and T 3. It might be due to that dose of 400 mg/kg bw was the maximum dose that could protect the testes from damage caused by methylmercury and the dose of 800 mg/kg bw exceeded the maximum dosage of the *Moringa* leaves, so that the content of antioxidants in *Moringa* was not able to work effectively in counteracting the methylmercury, otherwise, could cause toxic effects from the excessive antioxidant contents.

Moringa oleifera had been proven to improve

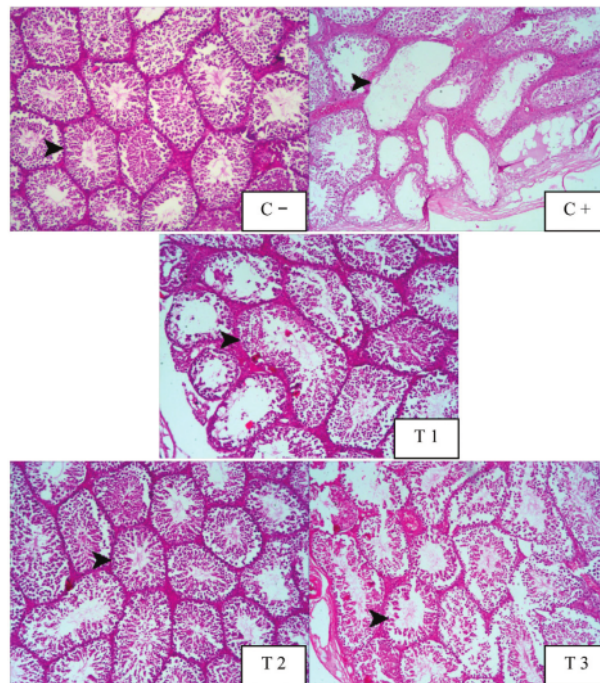


Fig. 1. Comparison of histopathological features on testicular seminiferous tubules of mice (*Mus musculus*) of each group. C - (showed normal seminiferous tubules with full spermatogenesis), C + (showed the abnormality in seminiferous tubules with presence of spermatogonia only), T 1 (showed many early spermatids but no late spermatids), T 2 (showed full spermatogenesis), and T 3 (showed incomplete spermatogenesis with many late spermatids) (Stain: H.E.; 100 × magnification).

tive effect on the letrozole (Selim *et al.*, 2013), alcohol (Bassey *et al.*, 2013), chromium (Akunna *et al.*, 2012), and mercury chloride-induced testicular toxicity (Asomugha *et al.*, 2015). Other study also indicated that *Moringa oleifera* leaf extract reverse the low level of testosterone, Follicle Stimulating Hormone (FSH), and Luteinizing Hormone (LH) in diabetic animals towards normal (Ebong *et al.*, 2014).

Moringa oleifera leaf was rich in phenolic compounds like quercetin, chlorogenic acid, and quinic acid which scavenged free radicals by electron transfer, protected cell membrane from lipid peroxidation by blocking ROS production, encountered DNA damage, and induced antioxidant enzymes activities (Chen *et al.*, 2007; Li *et al.*, 2008; Pero *et al.*, 2008; Ansari *et al.*, 2009; Barcelos *et al.*, 2011; Paliwal *et al.*, 2011). Selenium (Se), which also was highly contained in *Moringa oleifera* leaf known to be very active in counteracting mercury toxicity (Ralston *et al.*, 2008; Moyo *et al.*, 2011).

Vitamin E and vitamin C contained in *Moringa*

oleifera leaf also known to be free radical scavenger, preventing lipid peroxidation, protecting against DNA damage by hydrogen peroxide radical, and also enhancing antioxidant enzymes like superoxide dismutase (SOD), reduced glutathione (GSH), and catalase (CAT) on mercuric chloride-induced reproductive toxicity (Muthu and Krishnamoorthy, 2012).

Based on this research, it could be concluded that *Moringa oleifera* leaf extract reduced the damage of the testicular seminiferous tubules of mice (*Mus musculus*) exposed to methylmercury. The dose of 400 mg/kg bw *Moringa oleifera* leaf extract could provide the best protective effect compared to dose of 200 mg/kg bw and 800 mg/kg bw.

References

- Achmad, A.B. 2012. Histopathological Picture of Protoplasmic Astrocyte Cells Cerebrum White Rat (*Rattus norvegicus*) due to Methylmercury Poisoning by Giving CDP-Choline as Neuroprotectant [Thesis].

- Fakultas Kedokteran Hewan. Universitas Airlangga. 2012
- Agustina, T. 2010. Heavy Metal Contamination of Food and Its Impact on Health. *Teknubuga*. 2: 53-65.
- Akunna, G.G., Ogunmodede, O.S., Saalu, C.L., Ogunlade, B., Bello A.J. and Salawu, E.O. 2012. Ameliorative Effect of *Moringa oleifera* (Drumstick) Leaf Extracts on Chromium Induced Testicular Toxicity in Rat Testes. *World J. Life Sci. Med. Res.* 2: 20-26.
- Ansari, M.A., Abdul, M.A., Joshi, G., Opiia, W.O., Butterfield, D.A. 2009. Protective Effect of Quercetin in Primary Neurons Against A β (1-42): Relevance to Alzheimer's Disease. *J. Nutr. Bio.* 20: 269-275.
- Asomugha, A.L., Ezejindu, D.N. and Nwabekee, P.O. 2015. The Protective Effect of *Moringa oleifera* Leaf Extract on Mercury Induced Testicular Toxicity in Adult Wistar Rats. *Int. J. Preclin. Pharm. Res.* 6 : 1-6.
- Barcelos, G.R.M., Grotto, D., Serpeloni, J.M., Angeli, J.P.F., Rocha, B.A., de Oliveira Souza, V.C., Vicentini, J.T., Emanuelli, T., Bastos, J.K., Antunes, L.M.G., Knasmüller, S. and Barbosa Jr. F. P. 2011. Protective Properties of Quercetin Against DNA Damage and Oxidative Stress Induced by Methylmercury in Rats. *Arch. Toxicol.* 85 : 1151-1157.
- Bassey, R.B., Bala, D.N., Edagha, I.A. and Peter, A.I. 2013. The Effect of Ethanolic Extract of *Moringa oleifera* on Alcohol-Induced Testicular Histopathologies in Pre-Pubertal Albino Wistar Rats. *Bio Med.* 5 : 40-45.
- Beyrouthy, P., Stamler, C.J., Jiun-Ni, L., Loua, K.M., Kubow S. and Hing, M.C. 2006. Effects of Prenatal Methylmercury Exposure on Brain Monoamine Oxidase Activity and Neurobehaviour of Rats. *Neu. Tera.* 28: 251-259.
- Chen-Chih, C., Bai-Luh, W., Soy-Hwee, L., Wen-Fei, C. 2007. 3,4-Di-O-Caffeoyl Quinic Acid Protects Endothelial Cells Against Oxidative Stress and Restores Endothelium Dependent Vasodilatation. *J. Chin. Med.* 18: 89-100.
- Da Silva, D.A.F., Barbosa, Jr F. and Scarano, W.R. 2012. Oral Exposure to Methylmercury Modifies the Prostatic Microenvironment in Adult Rats. *Int. J. Exp. Pathol.* 93: 354-360.
- Do Nascimento, J.L.M., Oliveira, K.R.M., Crespo-Lopez M.E., Macchi, B.M., Maues, L.A.L., da Conceicao, M. Pinheiro, N., Silveira, L.C.L. and Herculano, A.M. 2008. Methylmercury Neurotoxicity and Antioxidant Defenses. *Indian J. Med. Res.* 128 : 373-382.
- Ebong, P.E., Efiang, E.E., Mgbeje, B.I.A., Igile, G.O. and Itam, E.H. 2014. Combined Therapy of *Moringa oleifera* and *Ocimum gratissimum* Reversed Testicular Damage in Diabetic Rats. *Brit. J. Med. Med. Res.* 4 : 2277-2290.
- El-Desoky, G.E., Bashandy, S.A., Alhazza, I.M., Al-Othman Z.A., Aboul-Soud, M.A.M. and Yusuf, K.I. 2013. Improvement of Mercuric Chloride-Induced Testis Injuries and Sperm Quality Deteriorations by *Spirulina platensis* in Rats. *PLoS ONE.* 8 : 1-9.
- Ganatra, T.H., Joshi, U.H., Bhalodia, P.N., Desai, T.R. and Targar, P.R. 2012. A Panoramic View on Pharmacognostic, Pharmacological, Nutritional, Therapeutic and Prophylactic Values of *Moringa oleifera* Lam. *Int. Res. J. Pharm.* 3 : 1-7.
- Inswiasri. Paradigm of Incidence of Mercury (Hg) Exposure Disease. *J. Ekol. Kes.* 2008; 7: 775-785.
- Kaur, P. 2008. *Cellular and Molecular Mechanisms Behind Methylmercury-Induced Neurotoxicity* [Thesis]. Faculty of Medicine. Norwegian University of Science and Technology.
- Moyo, B., Masika, P.J, Hugo, A. and Muchenje, V. 2011. Nutritional Characterization of Moringa (*Moringa oleifera* Lam.) Leaves. *Afr. J. Biotechnol.* 10 : 12925-12933.
- Muthu, K. and Krishnamoorthy, P. 2012. Effect of Vitamin C and Vitamin E on Mercuric Chloride-Induced Reproductive Toxicity in Male Rats. *Biochem. Pharmacol.* 1: 1-5.
- Paliwal, R., Sharma, V., Pracheta, S., Sharma, S., Yadav, S. and Sharma, S. 2011. Anti-Nephrotoxic Effect of Administration of *Moringa oleifera* Lam in Amelioration of DMBA-Induced Renal Carcinogenesis in Swiss Albino Mice. *Biol. Med.* 3 : 27-35.
- Pero, R.W., Lund, H. and Leanderson, T. 2008. Antioxidant Metabolism Induced by Quinic Acid. Increased Urinary Excretion of Tryptophan and Nicotinamide. *Phytother. Res.* 1-12.
- Ralston, N.V.C., Ralston, C.R., Blackwell, III J.L. and Raymond L.J. 2008. Dietary and Tissue Selenium in Relation to Methylmercury Toxicity. *J. Neuro. Tox.* 1-10.
- Rianto, S. 2010. Analysis of Factors Associated with Mercury Poisoning in Traditional Gold Miners in Jendi Village, Selogiri District, Wonogiri Regency. [Tesis]. Program Pascasarjana. Universitas Diponegoro.
- Selim, M.E, Aleisa, N.A. and Daghestani, M.H. 2013. Evaluation of the Possible Protective Role of Quercetin on Letrozole-Induced Testicular Injury in Male Albino Rats. *Ultrastruct. Pathol.* 37: 204-217.
- Timbrell J. *Introduction to Toxicology*. 2002. 3rd ed. Taylor & Francis. London. 137-140.
- Yongjin, L., Wei, S., Yindong, L., Yong, Z., Xuefeng, H., Chunmei, S., Hongbo, M., Changwen, W. and Yong, L. 2008. Neuroprotective Effects of Chlorogenic Acid Against Apoptosis of PC12 Cells Induced by Methylmercury. *Env. Toxicol. Pharm.* 26: 13-21.
- Zulaika, E., Widiyanti, A. and Shovitri M. 2011. Endogenic Mercury Resistant Bacteria in Lower Kalimas Surabaya. *National Seminar on Theory and Application of Marine Technology. 15-16 Desember-2011*. Surabaya. 2011: 1-5.

Effect of Moringa oleifera leaf extract on the Histopathological Features of Testicular Seminiferous Tubules of Mice (*Mus musculus*) Exposed to Methyl mercury

ORIGINALITY REPORT

17%

SIMILARITY INDEX

12%

INTERNET SOURCES

14%

PUBLICATIONS

0%

STUDENT PAPERS

PRIMARY SOURCES

- 1 **Gaber E. El-Desoky, Samir A. Bashandy, Ibrahim M. Alhazza, Zeid A. Al-Othman, Mourad A. M. Aboul-Soud, Kareem Yusuf. "Improvement of Mercuric Chloride-Induced Testis Injuries and Sperm Quality Deteriorations by *Spirulina platensis* in Rats", PLoS ONE, 2013** 1%

Publication
- 2 **www.freepatentsonline.com** 1%

Internet Source
- 3 **www.omicsonline.org** 1%

Internet Source
- 4 **krishikosh.egranth.ac.in** 1%

Internet Source
- 5 **ejurnal-analiskesehatan.web.id** 1%

Internet Source
- 6 **K. A. Iteire, A. T. Sowole, B. Ogunlade. "Exposure to pyrethroids induces behavioral** 1%

impairments, neurofibrillary tangles and tau pathology in Alzheimer's type neurodegeneration in adult Wistar rats", Drug and Chemical Toxicology, 2020

Publication

7

halibutassociation.com

Internet Source

1 %

8

Ehab Tousson, Ezar Hafez, Ahmed Masoud, Reem Ashour, Omer Ershidot. "Modulation of boldenone induced hepatic and renal toxicity by Moringa oleiferaas in albino rats.", Journal of Bioscience and Applied Research, 2016

Publication

1 %

9

Kathrin A Schmohl, Yang Han, Mariella Tutter, Nathalie Schwenk et al. "Integrin $\alpha\beta3$ -dependent thyroid hormone effects on tumour proliferation and vascularisation", Endocrine-Related Cancer, 2020

Publication

1 %

10

Nilanjan Das, Kunal Sikder, Surajit Bhattacharjee, Suchandra Bhattacharya Majumdar et al. "Quercetin alleviates inflammation after short-term treatment in high-fat-fed mice", Food & Function, 2013

Publication

1 %

11

Shabnum Nabi. "Toxic Effects of Mercury", Springer Nature, 2014

Publication

1 %

12	Systems Biology of Free Radicals and Antioxidants, 2014. Publication	1 %
13	pdfs.semanticscholar.org Internet Source	1 %
14	Mahmoud Salem. "Toxic effects of mancozeb containing formulations and neemix pesticides on kidney function and ultrastructure of albino rats", Egyptian Academic Journal of Biological Sciences. C, Physiology and Molecular Biology, 2011 Publication	<1 %
15	jurnal.akfarsam.ac.id Internet Source	<1 %
16	download.e-pubs.nl Internet Source	<1 %
17	garuda.kemdikbud.go.id Internet Source	<1 %
18	ocs.unud.ac.id Internet Source	<1 %
19	precedings.nature.com Internet Source	<1 %
20	www.science.gov Internet Source	<1 %

21 Berzas Nevado, J.J.. "Mercury exposure and mechanism of response in large game using the Almaden mercury mining area (Spain) as a case study", Environmental Research, 201201
Publication <1 %

22 Hakan Fidan, Ozer Calis, Esin Ari, Aydin Atasayar, Pelin Sarikaya, Mumin Ibrahim Tek, Ahmet Izmirli, Yasemin Oz, Gulsah Firat. "Knockout of eIF4E using CRISPR/Cas9 for large-scale production of resistant cucumber cultivar against WMV, ZYMV, and PRSV", Frontiers in Plant Science, 2023
Publication <1 %

23 Ikokide Emmanuel Joseph, Ishmael Festus Jaja, Adamu Hamman Boyi, Oyeyemi Mathew Olugbenga. "Comparative effects of methanol and oil extracts of Ocimum gratissimum on testicular morphology and epididymal sperm reserve of adult male albino rats (Wistar strain)", Toxicology Reports, 2019
Publication <1 %

24 phcogj.com
Internet Source <1 %

25 test.dovepress.com
Internet Source <1 %

26 ruor.uottawa.ca
Internet Source <1 %

27

vital.seals.ac.za:8080

Internet Source

<1 %

28

www.tandfonline.com

Internet Source

<1 %

29

Firman Alamsyah, Nisrina Firdausi, Subekti Evi
Dwi Nugraheni, Ahmad GhithaFadhlurrahman et al. "Effects of non-contact
electric fields on kidney and liver histology in
tumour-induced rats", F1000Research, 2023

Publication

<1 %

30

Soudeh Ghafouri-Fard, Hamed Shoorei, Mahdi
Mohaqqiq, Moloud Tahmasebi, Mohammad
Seify, Mohammad Taheri. "Counteracting
effects of heavy metals and antioxidants on
male fertility", BioMetals, 2021

Publication

<1 %

31

Evelin Fabjan, Etje Hulzebos, W. Mennes, A. H.
Piersma. "A Category Approach for
Reproductive Effects of Phthalates", Critical
Reviews in Toxicology, 2008

Publication

<1 %

32

Gbenga S. Ogunleye, Oladapo F. Fagbohun,
Olubunmi O. Babalola. "Chenopodium
ambrosioides var. ambrosioides leaf extracts
possess regenerative and ameliorative effects
against mercury-induced hepatotoxicity and

<1 %

nephrotoxicity", Industrial Crops and Products, 2020

Publication

33

Rizzetti, Danize Aparecida, Caroline Silveira Martinez, Alyne Goular Escobar, Taiz Martins da Silva, José Antonio Uranga-Ocio, Franck Maciel Peçanha, Dalton Valentim Vassallo, Marta Miguel Castro, and Giulia Alessandra Wiggers. "Egg white-derived peptides prevent male reproductive dysfunction induced by mercury in rats", Food and Chemical Toxicology, 2016.

Publication

<1 %

Exclude quotes Off

Exclude matches Off

Exclude bibliography On

Effect of Moringa oleifera leaf extract on the Histopathological Features of Testicular Seminiferous Tubules of Mice (Mus musculus) Exposed to Methyl mercury

GRADEMARK REPORT

FINAL GRADE

/0

GENERAL COMMENTS

Instructor

PAGE 1

PAGE 2

PAGE 3

PAGE 4

PAGE 5
