

05. Doxorubicin and

by Ahmad Fathira Fitra

Submission date: 14-May-2023 12:51PM (UTC+0800)

Submission ID: 2092460980

File name: 05._Doxorubicin_and.pdf (2.66M)

Word count: 2595

Character count: 13983



ELSEVIER

Contents lists available at ScienceDirect

International Journal of Surgery Case Reports

journal homepage: www.elsevier.com/locate/ijscr

Case report

Doxorubicin and ifosfamide for recurrent renal synovial sarcoma: The first case report in Indonesia

Ahmad Fathira Fitra^{a,b}, Yudhistira Pradnyan Klopings^{a,b}, Wahjoe Djatisoesanto^{a,b},
Lukman Hakim^{a,c,*}^a Department of Urology, Faculty of Medicine, Universitas Airlangga, Surabaya, East Java, Indonesia^b Dr. Soetomo General-Academic Hospital, Surabaya, East Java, Indonesia^c Universitas Airlangga Teaching Hospital, Surabaya, East Java, Indonesia

ARTICLE INFO

Keywords:

Synovial sarcoma
Renal synovial sarcoma
Doxorubicin
Ifosfamide
T chemotherapy
cancer

ABSTRACT

Introduction and importance: Synovial sarcoma (SS) is the fourth most common soft tissue sarcoma. The primary treatment for renal SS is radical surgical resection of the tumor. However, there are several stages of SS that need systemic treatment. The consensus regarding systemic treatment remains unclear. Therefore, we reported a case of an 18-year-old male with recurrent renal SS treated with doxorubicin and ifosfamide as systemic chemotherapy.

Case presentation: An 18-year-old male was admitted with a chief complaint of right flank pain for three months. He had a history of radical nephrectomy due to a suspicion of Wilms tumor. The histopathological and immunohistochemistry results showed a SS of the kidney. One year after the surgery, the patient came with a sign of a residual tumor. The diagnosis of recurrent renal SS was established after the physical examination, and Second-line chemotherapy was not administered because the patient refused any further treatment. However, the patient showed a partial response after the first chemotherapy session, indicating the benefit of the treatment.

Clinical discussion: The chemotherapy regimen is generally considered safe and can be widely used in clinical practice. Partial response was shown after six courses of treatment. Ifosfamide-based chemotherapy was also used in some reported cases. Most of the cases reported in the current literature were only managed by surgery without using chemotherapy. These cases had various RFS, ranging from 5 to 25 months.

Conclusion: Doxorubicin and ifosfamide are useful as first-line chemotherapy for recurrent renal synovial sarcoma.

1. Introduction

Synovial sarcoma (SS) is a rare tumor and the fourth (5–10%) most commonly soft tissue sarcoma. Primary renal SS was first reported by Faria et al. in 1999 [1]. They often develop in para-articular regions of the extremities. The tumor may also involve other regions of the body, such as the pleura, lungs, prostate, mediastinum, and kidneys [2–4]. This tumor often causes diagnostic dilemmas because of its similarity with adult Wilms Tumor, sarcomatoid renal cell carcinoma, and hemangiopericytoma based on its clinical and histological features [4,5]. Primary renal SS rarely occurs in the kidney, with only about 50 cases reported in the literature [6]. The tumor grows slowly and mimics

a benign lesion, leading to a possible misdiagnosis and improper treatment [4]. SS of the kidney occurs in patients with a relatively wide age range, from 15 to 60 years old. SS are commonly associated with extensive cystic changes, they are sometimes mistaken as cystic nephromas. Differentiating the tumor from other renal tumors with similar histological features, but different clinical prognoses, are essential [7].

Most renal SS are associated with a specific chromosome translocation t(X;18)(p11.2; q11.2), resulting in fusion of the SS18 gene on chromosome 18 with the SSX gene on chromosome X [8,9]. There are five variants of the SSX that have been identified, but only SSX1 and SSX2 have been shown to fuse with the SS18 gene [8]. These chromosome translocations are considered the best markers for the diagnosis of

* Corresponding author at: Department of Urology, Faculty of Medicine, Universitas Airlangga/Universitas Airlangga Teaching Hospital, Surabaya, East Java, Indonesia.

E-mail address: lukman-h@fk.unair.ac.id (L. Hakim).

¹ Present address: Jl. Mayjen Prof. Dr. Moestopo No.47, Surabaya, East Java, Indonesia, 60132.

<https://doi.org/10.1016/j.ijscr.2022.106895>

Received 16 January 2022; Received in revised form 24 February 2022; Accepted 26 February 2022

Available online 1 March 2022

2210-2612/© 2022 The Authors. Published by Elsevier Ltd on behalf of IJS Publishing Group Ltd. This is an open access article under the CC BY-NC-ND license

<http://creativecommons.org/licenses/by-nc-nd/4.0/>.

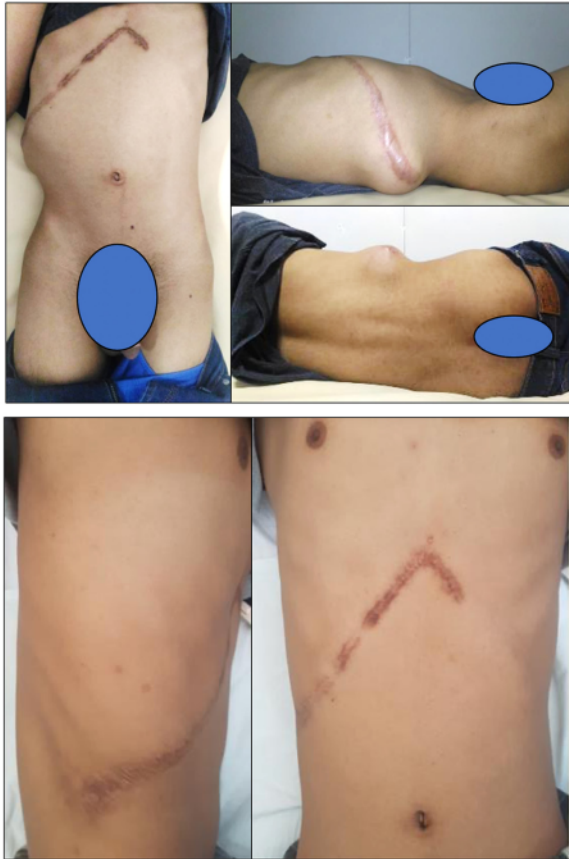

Fig. 1. Clinical appearance of the patients before and after the treatment.

SS [7]. SS can also be diagnosed by immunohistochemistry [10]. The standard primary treatment for renal SS is a radical surgical resection. Several cases of SS may require systemic treatment. However, no consensus has been reached regarding the systemic treatment as of the writing of this report. Currently, the literature discussing the treatment only consists of case reports [3]. We aimed to report an 18-year-old male with renal SS, who was previously managed surgically. The patient was then referred to our tertiary health center due to a possibility of recurrence. This case was reported according to the surgery consensus-based surgical case report guidelines (SCARE) criteria checklist [11].

2. Presentation of case

An 18-year-old male was referred to our hospital with a chief complaint of right flank pain for three months. He had no familial history of kidney cancer and smoked a pack of cigarettes a day for three years. He underwent a radical nephrectomy due to a suspicion of adult Wilms Tumor 15 months before his current admission. The referring doctor did not administer chemotherapy because the patient was asymptomatic after the surgery. The patient was eventually referred after apparent symptoms and signs of recurrence. The histopathological examination resulted in a sarcomatoid tumor, with a suspicion toward Wilms Tumor, Mesoblastic Nephroma, or Renal SS. Further immunohistochemistry examination indicated a SS. Vascular endothelium showed positive staining of vimentin, BCL-2, CD99, EMA, and CD3, whereas MCK, SMA, Desmin, S100, CD34, and CD31 staining of the tumor cells were negative. During the physical examination, a 15×10 cm fixed mass with a tender-hard consistency was found, as shown in Fig. 1. There were no abnormalities in the laboratory results. The abdominal ultrasonography (USG) examination Fig. 2 showed a solid irregular echoic mass, 20×12 cm in size, in the right renal fossa with multiple conglomerated para-aortic lymph nodes. There was no evidence of metastasis shown in the chest X-ray. The abdominal Computed Tomography (CT)-Scan showed a solid mass (35 HU), $13 \times 12.7 \times 20$ cm in size, with irregular borders, necrotic area (23 HU), and sub-centimeter aorto-cava, para-aortic, and para-iliac lymph nodes, as shown in Fig. 3. The patient was administered 6 cycles of systemic chemotherapy, consisting of doxorubicin and ifosfamide. There was no dose modification as the laboratory results were within normal limits.

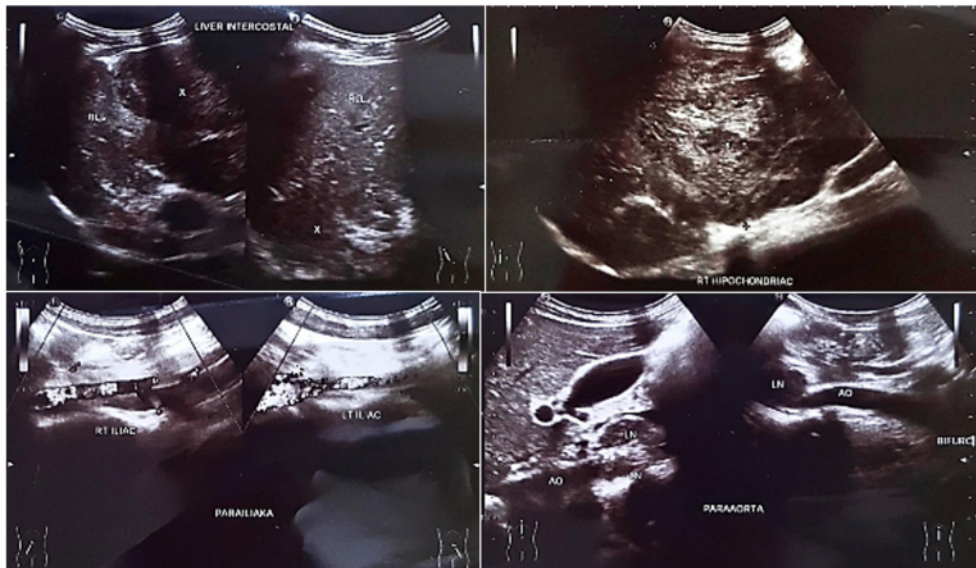


Fig. 2. Abdominal ultrasound before chemotherapy.

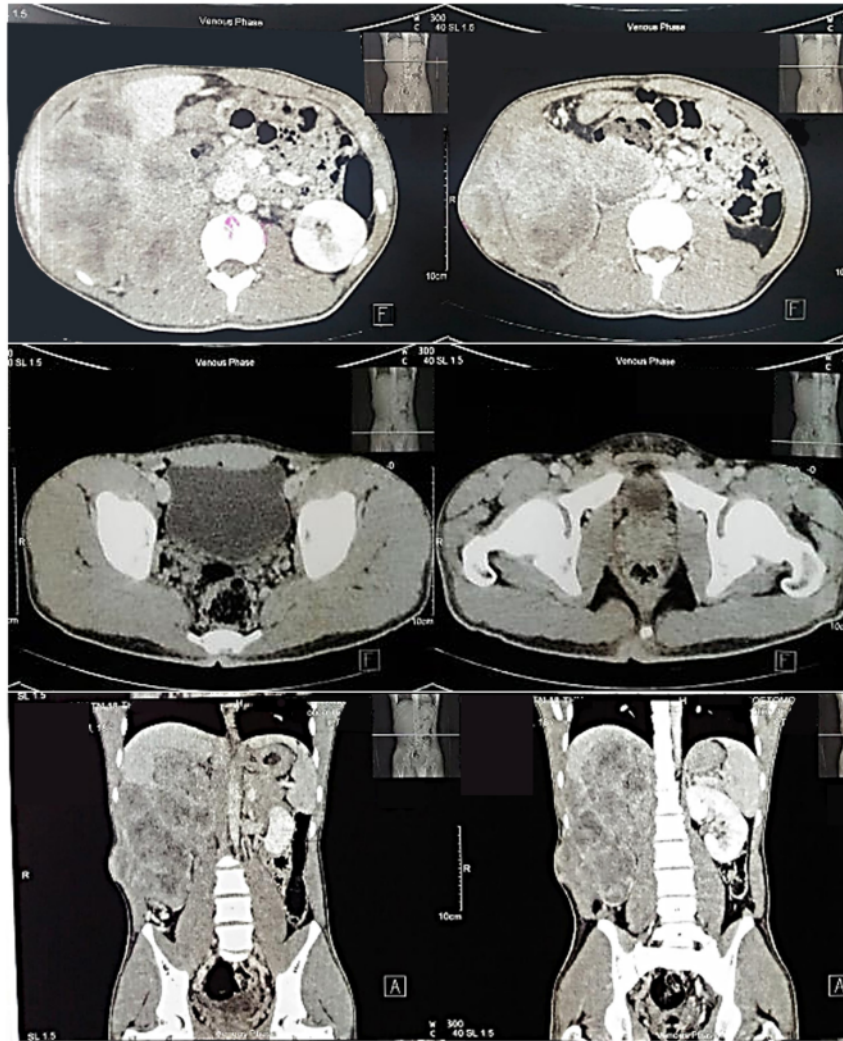


Fig. 3. Abdominal computed tomography (R1) before chemotherapy.

Doxorubicin 30 mg/m^2 was administered on the first and second day. Ifosfamide 3 g/m^2 was administered from day one to day three. On the second day, we administered Mesna 3 g/m^2 and a single dose of 1 g/m^2 on day one and day three. Six consecutive courses were completed with an interval of 21 days. Chemotherapy side effects, patient's vital signs, and laboratory findings were monitored during administration. There were no adverse events or complications during the sessions.

After six consecutive courses, treatment response was evaluated. The clinical appearance of the patient showed no flank mass upon inspection. However, the mass was palpable, as shown in Fig. 4. Abdominal CT-Scan in Fig. 5 showed a partial response with an enhancing solid mass and a necrotic area, $3,8 \times 4,95 \times 15,5 \text{ cm}$ in size, in the right renal fossa extending to the upper and lateral perihepatic regions, with a regular hepatic line, which did not infiltrate the external oblique muscles and subcutaneous fat. A reduced mass size was apparent compared to the size based on the pre-chemotherapy CT-Scan results. There was no evidence of metastasis shown in the Chest X-ray. The patient was scheduled to receive a second-line chemotherapy session. However, the patient refused treatment and died 42 months after the radical

nephrectomy.

3. Discussion

Even though the patient refused the second-line treatment, this report has reached its objective of evaluating the chemotherapy adverse event and response using doxorubicin and ifosfamide in recurrent renal SS after radical nephrectomy. The chemotherapy regimen is generally considered safe and can be widely used in clinical practice. Partial response was shown after six courses of treatment. Chediak et al. reported a case where the patient had a complete pathological response after being given adjuvant doxorubicin and ifosfamide [12]. Park et al. also reported a patient who was given six courses of this chemotherapy regimen with complete remission [13]. Ozkan et al. reported a patient that did not have tumor recurrence in one year after receiving 4 cycles of doxorubicin and ifosfamide [14].

Ifosfamide-based chemotherapy was also used in some reported cases. Chen et al. reported one patient receiving adjuvant ifosfamide and etoposide who died one month after surgery due to sepsis [15].

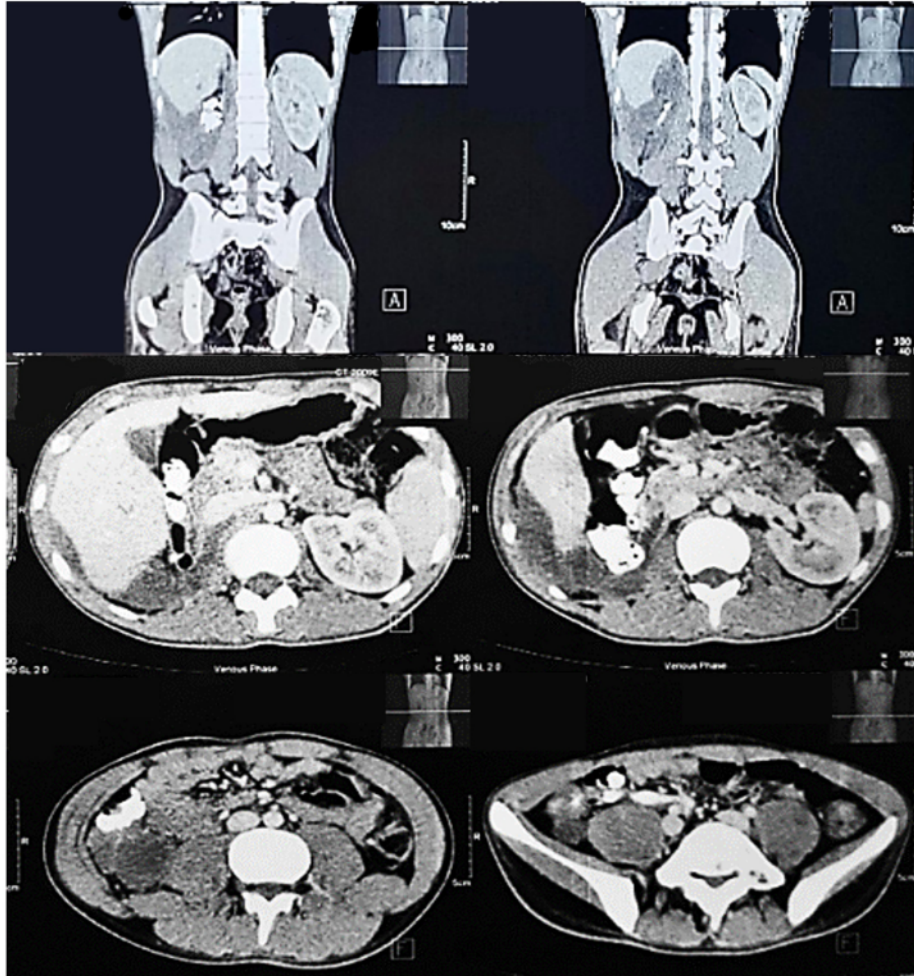


Fig. 4. Abdominal CT-scan six months after 6 cycles of chemotherapy (R1).

Ifosfamide and adriamycin administration in a neoadjuvant setting was also used in a case reported by Schaal et al., which resulted in no recurrence after a year [16]. Kageyama et al. reported a patient being administered ifosfamide and etoposide regimen with a 33-months recurrence-free survival (RFS) [8].

Another chemotherapy regimen, such as neoadjuvant vincristine has also been reported by Romero-Rojas et al. with less than two years of patient survival [17]. Lopes et al. administered 5 cycles of adjuvant doxorubicin, resulting in a lung metastasis several months after the surgery [18]. Bella AJ et al. reported a patient who was given adjuvant actinomycin and vincristine, which resulted in RFS, 18 months after surgery [19]. Most of the cases reported in the current literature were only managed by surgery, without using chemotherapy. These cases had various RFS, ranging from 5 to 25 months [19,20].

Several studies reported the use of systemic treatment while other studies demonstrated the use of adjuvant regimens [12,15,16]. In this case, the patient was not given neoadjuvant chemotherapy due to the lack of a specific consensus regarding systemic therapy in renal cancer, especially SS.

4. Conclusion

Doxorubicin and ifosfamide administration show promise as a systemic treatment for renal SS. However, more studies and clinical trials are required before they can be used regularly in clinical practice.

Abbreviations

| | |
|--------|--|
| CT | computer tomography |
| HU | Hounsfield unit |
| IVC | inferior vena cava |
| KUB | kidney ureter bladder |
| RECIST | response evaluation criteria in solid tumors |
| RFS | recurrence free survival |
| SS | synovial sarcoma |

Source of funding

No funding received.

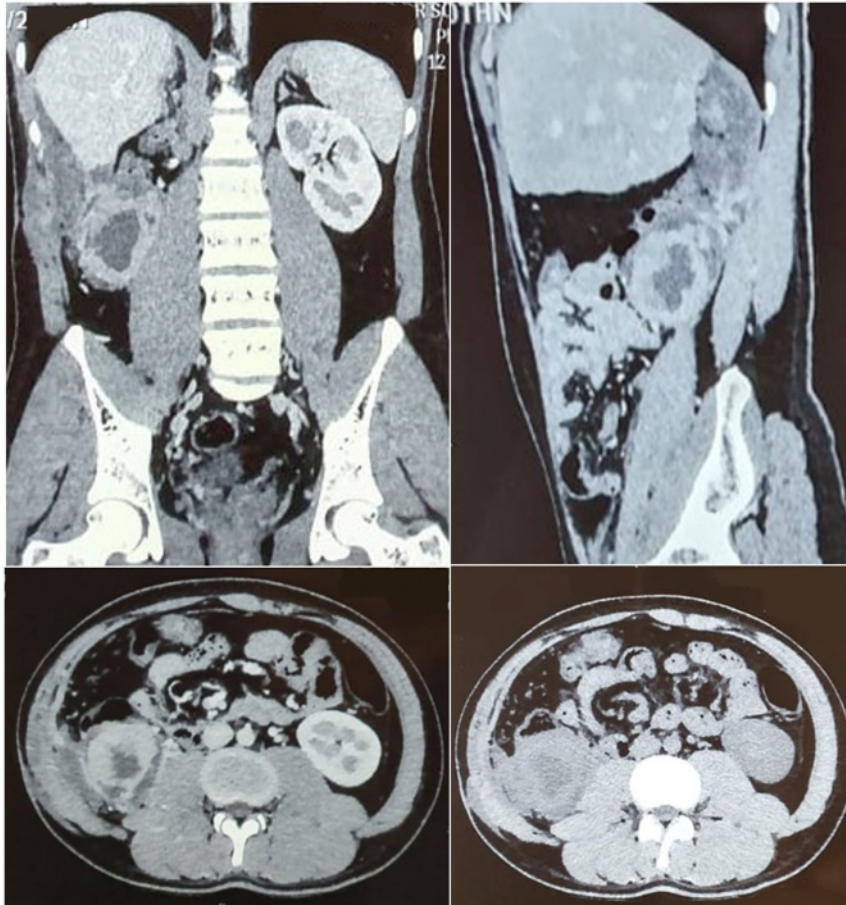


Fig. 5. Abdominal CT-scan twelve months after 6 cycles of chemotherapy (R2).

Ethical approval

We have received ethical approval from the institutional board review of Dr. Soetomo-General Academic Hospital (Ref. No. 0151/LOE/301.4.2/X/2020).

Consent

Written informed consent was obtained from the patient for publication of this case report and accompanying images. A copy of the written consent is available for review by the Editor-in-Chief of this journal on request.

Author contribution

AFF: Conceptualization, Design, Resources, Data Collection, Literature Search, Writing Manuscript, Critical Review.

YPK: Design, Resources, Data Collection, Literature Search.

WD: Conceptualization, Writing Manuscript, Critical Review.

LHA: Conceptualization, Design, Writing Manuscript, Critical Review, Supervision.

Research registration

None declared.

Guarantor

Lukman Hakim.

22

Provenance and peer review

Not commissioned, externally peer-reviewed.

14

Declaration of competing interest

The authors declare no conflict of interest.

Acknowledgment

None.

References

- [1] P. Argani, P.A. Faria, J.I. Epstein, V.E. Reuter, E.J. Perlman, J.B. Beckwith, et al., Primary renal synovial sarcoma: molecular and morphologic delineation of an entity previously included among embryonal sarcomas of the kidney, *Am. J. Surg. Pathol.* 24 (8) (2000) 1087–1096.
- [2] Y. Huang, D. Liu, J. Luo, W. Chen, in: *Primary renal synovial sarcoma: a case report and literature review*, 2018, pp. 2016–2018.
- [3] Z. Wang, Z. Zhong, L. Zhu, W. Xiong, C. Pan, X. Wang, et al., Primary synovial sarcoma of the kidney: a case report, *Oncol. Lett.* 10 (6) (2015) 3542–3544.

- [4] M. Gulum, E. Yeni, M. Savas, I. Ozardali, I. Ozdemir, D. Mil, et al., Primary renal synovial sarcoma, *Case Rep. Urol.* 2011 (2) (2011), 810184.
- [5] S. Misra, A. Chaturvedi, N.C. Misra, Penile carcinoma: a challenge for the developing world, *Lancet Oncol.* 5 (4) (2004) 240–247.
- [6] H.K. Moorthy, B.S. Pillai, J. Varghese, Primary renal synovial sarcoma: an oncologic surprise, *Urol. Case Rep.* 2 (5) (2014) 152–153.
- [7] B. Chang, L. Lu, X. Yang, L. Xiao, C. Wang, Primary synovial sarcoma of the kidney: a rare and easily misinterpreted renal entity, *Int. J. Clin. Exp. Pathol.* 9 (7) (2016) 7411–7419.
- [8] S. Kageyama, T. Tsuru, K. Okamoto, M. Narita, Y. Okada, Primary synovial sarcoma arising from a crossed ectopic kidney with fusion: case report, *Int. J. Urol.* 17 (1) (2010) 96–98.
- [9] A.J. Crew, J. Clark, C. Fisher, S. Gill, R. Grimer, A. Chand, et al., Fusion of SYT to two genes, SXX1 and SXX2, encoding proteins with homology to the Kruppel-associated box in human synovial sarcoma, *EMBO J.* 14 (10) (1995) 2333–2340.
- [10] G.D. Bakhshi, A.S. Khan, A.S. Shaikh, M.A. Khan, M.A. Khan, N.M. Jamadar, Primary renal synovial sarcoma, *Clin. Pract.* 2 (2) (2012) e44.
- [11] R.A. Agha, T. Franchi, C. Sohrabi, G. Mathew, A. Kerwan, A. Thoma, et al., The SCARE 2020 guideline: updating consensus Surgical Case Report (SCARE) guidelines, *Int. J. Surg.* 84 (2020) 226–230.
- [12] A. El Chediak, D. Mukherji, S. Temraz, S. Nassif, S. Sinno, R. Mahfouz, et al., Primary synovial sarcoma of the kidney: a case report of complete pathological response at a Lebanese tertiary care center, *BMC Urol.* 18 (1) (2018) 1–9.
- [13] Soo-Jin Park, Hyun-Kun Kim, Chan-Kyu Kim, Sung-Kyu Park, Eun-Suk Go, Min-Eui Kim, A case of renal synovial sarcoma: complete remission was induced by chemotherapy with doxorubicin and ifosfamide, 2004.
- [14] E.E. Ozkan, H. Mertsoylu, H.I. Ozardali, A case of renal synovial sarcoma treated with adjuvant ifosfamide and doxorubicin, *Intern. Med.* 50 (15) (2011) 1575–1580.
- [15] P.C.H. Chen, Y.H. Chang, C.C. Yen, C.C. Pan, H. Chiang, Primary renal synovial sarcoma with inferior vena cava and right atrium invasion, *Int. J. Urol.* 10 (12) (2003) 657–660.
- [16] C.H. Schaal, F.C. Navarro, F.A. Moraes Neto, Primary renal sarcoma with morphologic and immunohistochemical aspects compatible with synovial sarcoma, *Int. Braz. J. Urol.* 30 (3) (2004) 210–213.
- [17] A.E. Romero-Rojas, J.A. Diaz-Perez, O.A. Messa-Botero, F.E. Neira-Mejia, Sarcoma sinovial renal en edad temprana, *Arch. Esp. Urol.* 63 (6) (2010) 464–471.
- [18] H. Lopes, C.A.D. Pereira, L.E.R. Zucca, S.V. Serrano, S.R.M. Silva, M.L. Camparoto, et al., Primary monophasic synovial sarcoma of the kidney: a case report and review of literature, *Clin. Med. Insights Oncol.* 7 (2013) 257–262.
- [19] A.J. Bella, E.W. Winquist, E.J. Perlman, Primary synovial sarcoma of the kidney diagnosed by molecular detection of SYT-SSX fusion transcripts, *J. Urol.* 168 (3) (2002) 1092–1103.
- [20] V.U. Grampurohit, A. Myageri, R.V. Rao, Primary renal synovial sarcoma, *Urol. Ann.* 3 (2) (2011) 110–113.

05. Doxorubicin and

ORIGINALITY REPORT

18%

SIMILARITY INDEX

16%

INTERNET SOURCES

12%

PUBLICATIONS

0%

STUDENT PAPERS

PRIMARY SOURCES

| | | |
|---|---|----|
| 1 | afju.springeropen.com Internet Source | 1% |
| 2 | urologyannals.com Internet Source | 1% |
| 3 | ddf.v.ufv.es Internet Source | 1% |
| 4 | Matsuno, Yukihiro, Narihiro Ishida, Yukiomi Fukumoto, Katsuya Shimabukuro, and Hirofumi Takemura. "Simultaneous Endovascular Aneurysm Repair and Distal Gastrectomy in a Patient with Concomitant Abdominal Aortic Aneurysm and Advanced Gastric Cancer", <i>Annals of Vascular Diseases</i> , 2012. Publication | 1% |
| 5 | www.hindawi.com Internet Source | 1% |
| 6 | pubmed.ncbi.nlm.nih.gov Internet Source | 1% |

| | | |
|----|---|-----|
| 7 | Duck-Hwan Kim. "Primary Synovial Sarcoma of the Kidney :", American Journal of Surgical Pathology, 08/2000 Publication | 1 % |
| 8 | jpad.com.pk Internet Source | 1 % |
| 9 | Yasutomo Sekido. "Sarcomatoid carcinoma of the renal pelvis: A case report", Pathology International, 7/2000 Publication | 1 % |
| 10 | diagnosticpathology.biomedcentral.com Internet Source | 1 % |
| 11 | ebooks.au.dk Internet Source | 1 % |
| 12 | lib.bioinfo.pl Internet Source | 1 % |
| 13 | jurnal.ugm.ac.id Internet Source | 1 % |
| 14 | www.biorxiv.org Internet Source | 1 % |
| 15 | hrcak.srce.hr Internet Source | 1 % |
| 16 | repository.uin-malang.ac.id Internet Source | 1 % |

| | | |
|----|--|------|
| 17 | Hongqiang Zhang, Wending Huang, Qi Feng, Wei Sun et al. "Clinical Significance and Risk Factors of Local Recurrence in Synovial Sarcoma: A Retrospective Analysis of 171 Cases", <i>Frontiers in Surgery</i> , 2022 Publication | 1 % |
| 18 | e-journal.unair.ac.id Internet Source | 1 % |
| 19 | www.researchgate.net Internet Source | 1 % |
| 20 | rcastoragev2.blob.core.windows.net Internet Source | <1 % |
| 21 | Yong-Ki Ma, M. Mohan Raja, V. Vijayakumar, Anurag Shukla, Wedad Albalawi, Kottakkaran Sooppy Nisar. " Existence and continuous dependence results for fractional evolution integrodifferential equations of order ", <i>Alexandria Engineering Journal</i> , 2022 Publication | <1 % |
| 22 | jitc.bmj.com Internet Source | <1 % |
| 23 | wjso.biomedcentral.com Internet Source | <1 % |
| 24 | www.jstage.jst.go.jp Internet Source | <1 % |

www.pathologica.it

25

Internet Source

<1 %

26

www.wjgnet.com

Internet Source

<1 %

27

www.worldwidejournals.com

Internet Source

<1 %

28

"1-A1: Lung Cancer 1 : Poster Sessions",
Respirology, 2013.

Publication

<1 %

29

Soilia Fertilita, Willy Sandhika, Desak Gede Agung Suprabawati. "The Cytotoxic Activity of Annona muricata Linn Leaves Ethanolic Extract (AMEE) on T47D Breast Cancer Cell Line", Medical Laboratory Technology Journal, 2020

Publication

<1 %

Exclude quotes On

Exclude matches Off

Exclude bibliography On

05. Doxorubicin and

GRADEMARK REPORT

FINAL GRADE

/100

GENERAL COMMENTS

Instructor

PAGE 1

PAGE 2

PAGE 3

PAGE 4

PAGE 5

PAGE 6
