



Source details

International Journal of Surgery Case Reports

Scopus coverage years: from 2010 to Present

Publisher: Elsevier

ISSN: 2210-2612

Subject area: Medicine: Surgery

Source type: Journal

- [View all documents >](#)
- [Set document alert](#)
- [Save to source list](#)
- [Source Homepage](#)

CiteScore 2021
0.9



SJR 2021
0.198



SNIP 2021
0.691



[CiteScore](#) [CiteScore rank & trend](#) [Scopus content coverage](#)

i Improved CiteScore methodology



CiteScore 2021 counts the citations received in 2018-2021 to articles, reviews, conference papers, book chapters and data papers published in 2018-2021, and divides this by the number of publications published in 2018-2021. [Learn more >](#)

CiteScore 2021 ▼

$$0.9 = \frac{3,130 \text{ Citations 2018 - 2021}}{3,573 \text{ Documents 2018 - 2021}}$$

Calculated on 05 May, 2022

CiteScoreTracker 2022 ⓘ

$$0.9 = \frac{3,820 \text{ Citations to date}}{4,033 \text{ Documents to date}}$$

Last updated on 05 April, 2023 • Updated monthly

CiteScore rank 2021 ⓘ

| Category | Rank | Percentile |
|-----------|----------|------------|
| Medicine | | |
| └ Surgery | #316/469 | 32nd |

[View CiteScore methodology >](#) [CiteScore FAQ >](#) [Add CiteScore to your site](#)

About Scopus

[What is Scopus](#)

[Content coverage](#)

[Scopus blog](#)

[Scopus API](#)

[Privacy matters](#)

Language

[日本語版を表示する](#)

[查看简体中文版本](#)

[查看繁體中文版本](#)

[Просмотр версии на русском языке](#)

Customer Service

[Help](#)

[Tutorials](#)

[Contact us](#)

ELSEVIER

[Terms and conditions](#) ↗ [Privacy policy](#) ↗

Copyright © Elsevier B.V. ↗. All rights reserved. Scopus® is a registered trademark of Elsevier B.V.

We use cookies to help provide and enhance our service and tailor content. By continuing, you agree to the use of cookies ↗.



McAfee Total Protection
McAfee Official Store

International Journal of Surgery Case Reports

| COUNTRY | SUBJECT AREA AND CATEGORY | PUBLISHER | H-INDEX |
|--|-----------------------------|-------------|---|
| <p>Netherlands</p> <ul style="list-style-type: none"> Universities and research institutions in Netherlands Media Ranking in Netherlands | <p>Medicine Surgery</p> | Elsevier BV | 23 |
| PUBLICATION TYPE | ISSN | COVERAGE | INFORMATION |
| Journals | 22102612 | 2010-2021 | <p>Homepage</p> <p>How to publish in this journal</p> |
| <p>vivo V27 Ultimate Portrait</p> <p>vivo Indonesia Open ></p> | | | |

SCOPE

International Journal of Surgery Case Reports is an open access, broad scope journal covering all surgical specialities. It is dedicated to publishing case reports and case series. Articles must be authentic, ethical, educational and clinically interesting to an international audience of surgeons, trainees and researchers in all surgical subspecialties, as well as clinicians in related fields. All case reports and case series submitted need to comply with the relevant reporting criteria. The journal is published monthly and focuses on rapid submission to decision times. [...] The journal covers the following areas of surgery: -Cardiothoracic surgery- General surgery- Neurosurgery- Oral and maxillofacial surgery- Otolaryngology (ENT)- Paediatric surgery- Plastic surgery- Trauma and orthopaedic surgery- Urology- Vascular surgery

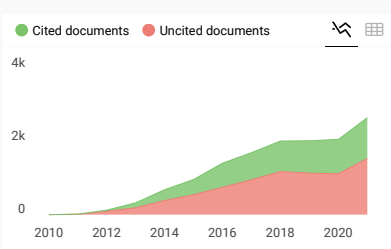
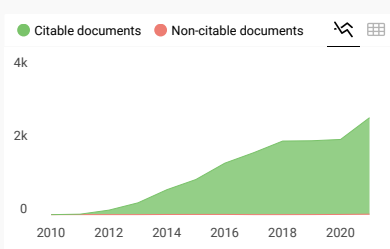
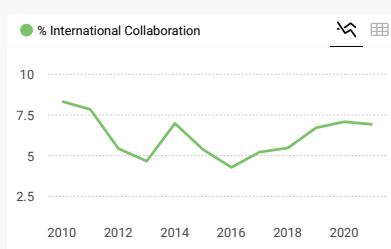
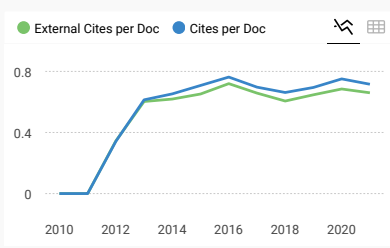
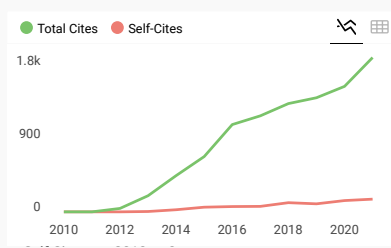
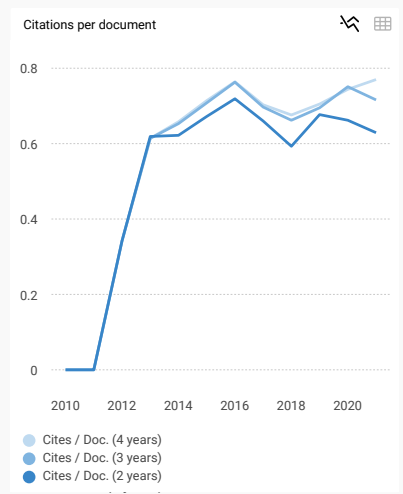
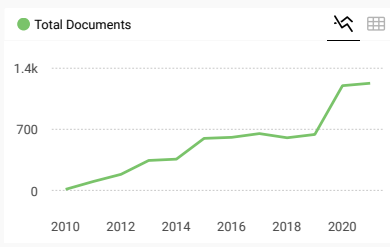
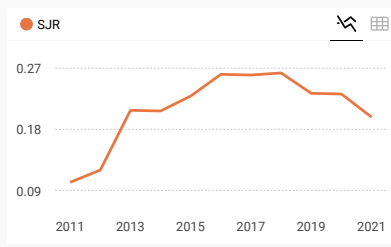
Join the conversation about this journal

Protect Your Devices Today
McAfee Official Store

FIND SIMILAR JOURNALS ?

options :

| | | | | |
|---|---|--|--|--|
| <p>1 Annals of Medicine and Surgery NLD</p> <p>67% similarity</p> | <p>2 International Journal of Surgery NLD</p> <p>55% similarity</p> | <p>3 International Journal of Surgery Open GBR</p> <p>50% similarity</p> | <p>4 BMC Surgery GBR</p> <p>34% similarity</p> | <p>5 Indian Journal of Surgery IND</p> <p>33% similarity</p> |
|---|---|--|--|--|



International Journal of Surgery Case Reports

← Show this widget in your own website

Just copy the code below and paste within your html code:

``

powered by scimagojr.com

SCImago Graphica

Explore, visually communicate and make sense of data with our **new data visualization tool**.

D Dharmendra 3 years ago

Want to publish a case report i this journal, si please tell me about the process.
Thanks

← reply



Melanie Ortiz 3 years ago

SCImago Team

Dear Dharmendra, thank you very much for your comment, we suggest you look for author's instructions/submission guidelines in the journal's website. Best Regards, SCImago Team

J Jayalakshmi 3 years ago

I would like to know the charge for publishing the report

← reply



Melanie Ortiz 3 years ago

SCImago Team

Dear Jayalakshmi,
thank you for contacting us.
We are sorry to tell you that SCImago Journal & Country Rank is not a journal. SJR is a portal with scientometric indicators of journals indexed in Elsevier/Scopus.
Unfortunately, we cannot help you with your request, we suggest you visit the journal's homepage (See fees/charges, if there are any) or contact the journal's editorial staff , so they could inform you more deeply.
Best Regards, SCImago Team

Leave a comment

Name

Email

(will not be published)

Submit

The users of Scimago Journal & Country Rank have the possibility to dialogue through comments linked to a specific journal. The purpose is to have a forum in which general doubts about the processes of publication in the journal, experiences and other issues derived from the publication of papers are resolved. For topics on particular articles, maintain the dialogue through the usual channels with your editor.

Developed by:



Powered by:



Follow us on @ScimagoJR

[Cookie settings](#)

[Cookie policy](#)

Submit your article [↗](#)

Guide for authors [↗](#)

☰ Menu

🔍 Search in this journal

Volume 96

July 2022

📄 Download full issue

[← Previous vol/issue](#)

[Next vol/issue >](#)

Receive an update when the latest issues in this journal are published

[🔔 Sign in to set up alerts](#)

● Open access

Editorial Board

Article 107404

[📄 View PDF](#)

Correspondence

Correspondence ● Open access

Comment on “Orbital Actinomycetoma with cranial extension: A rare case report”

FEEDBACK [💬](#)

Case report ● Open access

Retrorectal schwannoma in a middle-aged female: A case report

Diptee Poudel, Suraj Shrestha, Elisha Poddar, Prarthana Pacchai, ... Paleswan Joshi Lakhey

Article 107270



[View PDF](#)

Article preview [▼](#)

Case report ● Open access

Epidural phlegmon and iliopsoas abscess caused by *Salmonella enterica* bacteremia: A case report

Michael Mousselli, Emerald Chiang, Petros Frousiakis

Article 107287



[View PDF](#)

Article preview [▼](#)

Case report ● Open access

An unusual cluster of Waugh syndrome as a cause of intestinal obstruction in children - A case series

Ibrahim S. Elkeir, Walaa Balla, Helen Jagurru, Moh Fatih, ... Mohamed Abdulkarim

Article 107269



[View PDF](#)

Article preview [▼](#)

Case report ● Open access

Thigh and iliopsoas abscess as a rare presentation of perforated mucinous appendix carcinoma. A case report

Pedro Osácar, Darío Ramallo, Luisina Elizalde

Article 107293



[View PDF](#)

Article preview [▼](#)

Case report ● Open access

Case report ● Open access

Duodenal transection following a seat belt injury: A case report

Hassan Shah, Belal Nedal Sabbah, Badr Ahmed Elwy, Tarek Ziad Arabi, ... Syed Yousaf Shah

Article 107272



[View PDF](#)

Article preview [▼](#)

Case report ● Open access

Case of metachronous clear cell bladder metastasis on low risk localized renal cell carcinoma patient

Mahdy Alief Adhiguna, Sawkar Vijay Pramod, Bambang Sasongko Noegroho, Ferry Safriadi, Bethy Suryawathy Hernowo

Article 107158



[View PDF](#)

Article preview [▼](#)

Case report ● Open access

Successful aortic root enlargement procedure in low resource setting: Two rare cases

Lyndon Darwin, Oky Revianto Sediono Pribadi

Article 107294



[View PDF](#)

Article preview [▼](#)

Case report ● Open access

A giant adenomatoid odontogenic tumor of the mandible: A case report and literature review

Nguyen Quang Duc, Vu Ngoc Lam, Nguyen Phuong Tien, Ngo Thi Minh Hanh, Vu Dang Hai Dang

Article 107295



[View PDF](#)

Article preview [▼](#)

Case report ● Open access

Case report ● Open access

Knee tuberculosis: A misleading clinical entity (case report)

Ahmed Zendeoui, Achraf Oueslati, Ahmed Tounsi, Saber Saadi, ... Lotfi Nouisri

Article 107236



[View PDF](#)

Article preview [▼](#)

Case report ● Open access

Osteosarcoma of the distal fibula and reconstruction of the ankle using inverted fibula, a case report

Hassan Mohammed Hassan Elbahri, Hozifa Mohammed Ali Abd-Elmaged, Mohamed Abdulkarim

Article 107310



[View PDF](#)

Article preview [▼](#)

Case report ● Open access

Combined laparoscopic Roux-en-Y gastric bypass reversal and gastric banding to treat severe hyperinsulinemic hypoglycemia: A case report and surgical video

F.-X. Terryn, B. Majerus

Article 107271



[View PDF](#)

Article preview [▼](#)

Case report ● Open access

A deep giant aggressive angiomyxoma of the labia majora: A case report

Elnaz Ayati, Maryam Deldar Pesikhani, Maryam Karamali, Armin Borhan, Leila Pourali

Article 107313



[View PDF](#)

Article preview [▼](#)

Case report ● Open access

An unusual single paraglottic space neurofibroma: A case report and literature review

following pelvic resection of malignant bone tumour: A case report

Yogi Prabowo, Sammy Saleh Alhuraiby, Guntur Utama Putera, Anissa Feby Canintika

Article 107267



[View PDF](#)

Article preview [✓](#)

Case report ● *Open access*

Case report: Nasopharyngeal mucormycosis, atypical presentation in a seventy-year-old diabetic lady

Bashayer Salem Alsaeedi, Hussein Ali Alzamel, Ahmad Rasheed Alrasheedi, Imtiyaz Nawaz Bhat

Article 107297



[View PDF](#)

Article preview [✓](#)

Case report ● *Open access*

Ruptured granulosa cell tumor of the ovary presenting with catastrophic intra-abdominal hemorrhage: A case report

Alexa D. Smith, Mojdeh S. Kappus, Wilfrido D. Mojica, Martin J. Caliendo, ... Peter Muscarella

Article 107317



[View PDF](#)

Article preview [✓](#)

Case report ● *Open access*

Ileal lactobezoar in extreme premature infant complicated by intestinal perforation: A case report

Mohamed Elkhoul, Farid Aleali, Ayah Alzamrooni, Priscilla Chiu, Estelle Gauda

Article 107303



[View PDF](#)

Article preview [✓](#)

Case report ● *Open access*

Management of the association of otosclerosis and cholesteatoma: Which pathology to treat first?

TAPP) – A case report

C.D. Narayanan, Miloni More, Sayak Chattopadhyay, Revathy Kubendran, Dharanipriya Ravichandran
Article 107308



[View PDF](#)

Article preview [✓](#)

Case report ● *Open access*

Odontogenic fibromyxoma: A case report in myasthenia gravis patient and review of the literature

Bedriye Gizem Çelebioğlu Genç, Kaan Orhan
Article 107306



[View PDF](#)

Article preview [✓](#)

Case report ● *Open access*

Spontaneous acalculous gallbladder perforation mimicking duodenal stump leak after gastrectomy for gastric cancer: A case report

Woo Yong Lee
Article 107304



[View PDF](#)

Article preview [✓](#)

Case report ● *Open access*

Acro-callous syndrome: A case report

A. Lamrissi, F.E. Madri, M. Charkaoui, M. Mourabbih, ... S. Bouhya
Article 107210



[View PDF](#)

Article preview [✓](#)

Case report ● *Open access*

Aggressive juvenile ossifying fibroma of the ethmoid sinus with orbital and intracranial extension: A case report

Dalia Al Arfaj, Ali Almomen, Musab Bakri, Haifa Lafi Alenzi

Aryadi Kurniawan, Anissa Feby Canintika

Article 107298



[View PDF](#)

Article preview [▼](#)

Case report ● Open access

Interval laparoscopic appendectomy after laparotomy drainage for acute appendicitis with abscess: A case report

Toshiyuki Suzuki, Akiyo Matsumoto, Takahiko Akao, Seiji Kobayashi, Hiroshi Matsumoto

Article 107319



[View PDF](#)

Article preview [▼](#)

Case report ● Open access

Usefulness of customized titanium plates for midface contouring surgery

Tadaaki Morotomi, Tomomi Iuchi, Narihiko Hirano, Mitsugu Fujita, Koji Niwa

Article 107324



[View PDF](#)

Article preview [▼](#)

Case report ● Open access

Methotrexate for management of twin pregnancy with complete hydatidiform mole and co-existing live fetus: A case report

MHD Moamen Al Mouallem, Nazih Tawashi, IEMAN ALAWAD, FATIMA ALAWAD, Majd Hanna

Article 107320



[View PDF](#)

Article preview [▼](#)

Case report ● Open access

The uncommon diagnosis of hiatal hernia associated pancreatitis: A case report

Atef Mejri, Khaoula Arfaoui, Jasser Yaacoubi, Mohamed Firas Ayadi

Article 107328



[View PDF](#)

Article preview [▼](#)

Case report ● Open access

Pyo pneumothorax revealing splenic tuberculosis abscess in a COVID-19 femal: A case report

Imen Bouassida, Mariem Hadj Dahmane, Hazem Zribi, Amina Abdelkbir, ... Adel Marghli

Article 107312



[View PDF](#)

Article preview [▼](#)

Case report ● Open access

Cyclopia baby: Congenital lethal malformation: Rare case report

Hamza Kiram, Maryem Bouab, Mohamed Jalal, Amine Lamrissi, Said Bouhya

Article 107309



[View PDF](#)

Article preview [▼](#)

Case report ● Open access

Rare case of pelvic schwannoma mimicking intra-ligamenter uterine fibroid: A case report

Mila Maidarti, Yohanes Satria Wibawa, Prini Diandara Garinasih, Tantri Hellyanti, ... Kartiwa Hadi Nuryanto

Article 107327



[View PDF](#)

Article preview [▼](#)

Case report ● Open access

Extensor mechanism reconstruction and joint preservation surgery following a tibial tuberosity fracture in giant cell tumor of bone: A case report

Marlon M. Mencia, Reena Moonsie

Article 107326



[View PDF](#)

Article preview [▼](#)

Case report ● Open access

Case report ● Open access

Endoscopic endonasal retrieval of air gun pellet retained in the frontal sinus: A case report

Hassan Yousaf Shah, Rawan Emad Elshaer, Tarek Ziad Arabi, Belal Nedal Sabbah, Ghassan Alokby

Article 107280



[View PDF](#)

Article preview [▼](#)

Case report ● Open access

Acute patellar tendon rupture with tibial tubercle avulsion repair using suture anchors: Tiny avulsed fragment which affects the strength of construction-a case report

Andri Maruli Tua Lubis, Ido Prabowo

Article 107283



[View PDF](#)

Article preview [▼](#)

Case report ● Open access

Extent of craniofacial fungal osteomyelitis in a ketoacidotic patient may predict optic nerve involvement: A case report

Jennifer Adams, Khalid N. Sheikh, Adam Bender-Heine

Article 107299



[View PDF](#)

Article preview [▼](#)

Case report ● Open access

A fatal perforation of the distal ileum from an ingested fish bone: A case report

B.M. Munasinghe, C.T. Karunatileke, R.A.R.M.L.N. Rajakaruna, P.S.M.B. Senevirathne, D.C. Dhanuksha

Article 107331



[View PDF](#)

Article preview [▼](#)

Case report ● Open access

Case report ● Open access

A novel laparoscopic non-resective technique for the management of strangulated Richter's hernia

Marleny Carmona, Eduardo Smith Singares

Article 107335



[View PDF](#)

[Article preview](#) [▼](#)

Case report ● Open access

A hybrid lesion of intralobar sequestration with mixed features of CPAM type I and type II unmasked following SARS-CoV-2 infection: Case report and literature review

Dehua Wang, William B. Wheeler

Article 107336



[View PDF](#)

[Article preview](#) [▼](#)

Case report ● Open access

A case report of Actinomyces-associated vulvar necrotizing soft tissue infection: Aspects of multidisciplinary care

Bruce Lee, Peter Mroz

Article 107314



[View PDF](#)

[Article preview](#) [▼](#)

Case report ● Open access

An unusual association between pancreatic cancer and Purtscher-like retinopathy: Presentation of a unique case

Eva Intagliata, Salvatore Giugno, Clarissa Vizzini, Rossella Rosaria Cacciola, ... Veronica Vecchio

Article 107338



[View PDF](#)

[Article preview](#) [▼](#)

Case report ● Open access

Case report ● Open access

Transvaginal small bowel evisceration: Case report and review of literature

Raef Alfraidi, Nourah Abdulaaly, Ashwag Alharbi, Helayal Almodhaiberi, ... Hassan Sabagh
Article 107322



[View PDF](#)

[Article preview](#) ✓

Case report ● Open access

Appendiceal mucocele presenting as a leading point in ileocolic intussusceptions: “Case report”

Gosa Bejiga
Article 107307



[View PDF](#)

[Article preview](#) ✓

Case report ● Open access

Remote extradural hematoma as a complication of endoscopic transsphenoidal surgery: A case report with literature review

Rifqi Aulia Destiansyah, Camilia Metadea Aji Savitri, I. Wayan Weda Wisnawa, Rahadian Indarto Susilo, ...
Irwan Barlian Immadoel Haq
Article 107341



[View PDF](#)

[Article preview](#) ✓

Case report ● Open access

Colorectal carcinoma presenting as spontaneous colocutaneous fistula - A rare case report and review of literature

Sunil Basukala, Yugant Khand, Soumya Pahari, Priya Mainali, ... Suman Gurung
Article 107346



[View PDF](#)

[Article preview](#) ✓

Case report ● Open access

Case report ● Open access

Double epidural catheter technique in a patient with severe COPD undergoing major abdominal surgery: A case report

Christian Compagnone, Valentina Bellini, Alberto Calabrese, Mario Taddei, Elena Bignami

Article 107350



[View PDF](#)

Article preview [▼](#)

Case report ● Open access

Surgical and multitreatment approach in a case of primary cardiac angiosarcoma: A case report

Akihiro Kobayashi, Yoshimori Araki, Takafumi Terada, Sachie Terazawa, Osamu Kawaguchi

Article 107349



[View PDF](#)

Article preview [▼](#)

Case report ● Open access

Tuberculosis of the breast neoplastic-like about two report cases: A rare often unrecognized diagnosis

A. Lamrissi, F. Madri, M. Bouab, M. Bensouda, ... S. Bouhya

Article 107242



[View PDF](#)

Article preview [▼](#)

Case report ● Open access

Successful surgical repair of an eminently rare case of an incidental idiopathic Common Femoral Artery Pseudoaneurysm in a 6-year-old female child - A Case Report

Omar Al Laham, Ahmad Shahrou, Okab Yahya, Hisham Hamzeh

Article 107362



[View PDF](#)

Article preview [▼](#)

Case report ● Open access

Case report ● Open access

Felicitous surgical management of a ponderously rare diagnosis of a Vascular Hamartoma in the neck of an adolescent female - A Case Report

Omar Al Laham, Jack Shaheen, Jeer Abdul Aziz, Anas Abou Azan, ... Alaa Alhanwt

Article 107359



[View PDF](#)

Article preview [▼](#)

Case report ● Open access

Thoracic spinal arachnoid web and syringomyelia with rostral expansion to the first cervical spinal cord level: Case report

Christian Nieves-Ríos, Josué G. Layuno-Matos, Gerardo Olivella, Norman Ramírez, ... Jorge Lastra-Power

Article 107360



[View PDF](#)

Article preview [▼](#)

Case report ● Open access

Percutaneous endoscopic gastrostomy tube replacement after head and neck surgery: A case report

Aria C. Attia, William Kurtis Childers

Article 107323



[View PDF](#)

Article preview [▼](#)

Case report ● Open access

Struma ovarii: A case report and review the literature

Fatemeh Zamani, Aghdas Abdolrazaghnejad, Fereshteh Ameli, Sanaz GHashghaee, ... Narges Zamani

Article 107318



[View PDF](#)

Article preview [▼](#)

Case report ● Open access

Case report ● Open access

Dry beriberi after sleeve gastrectomy: An undiagnosed case report

Foolad Eghbali, Mansour Bhahdoust, Hamid Sarafraz, Mobin Naghshbandi, ... Hamidreza Movahedi
Article 107357



[View PDF](#)

Article preview [▼](#)

Case report ● Open access

Congenital absence of the cystic duct: Case report of a rare anomaly and review of the literature

Reem Boushehry, Fatemah Husain, Athary Saleem, Mohammed Alshamali, ... Khaleel Mohammad
Article 107353



[View PDF](#)

Article preview [▼](#)

Case report ● Open access

Intestine perforation by an accidental ingested SARS-CoV-2 nasopharyngeal swab; a case report

Yvonne Versluijs, Niels Keekstra, Fabian A. Holman
Article 107378



[View PDF](#)

Article preview [▼](#)

Case report ● Open access

Lesser omental hernia without intestinal gangrene – Case report

Arnas Ugianskis
Article 107361



[View PDF](#)

Article preview [▼](#)

Case report ● Open access

Case report ● Open access

Severe penile fracture with bilateral corpus cavernosum rupture, complete urethral rupture and scrotal haematoma associated with sexual intercourse: A case report

Made Adi Wiratama, Wahjoe Djatisoesanto, Lukman Hakim

Article 107377



[View PDF](#)

Article preview [▼](#)

Case report ● Open access

Adjuvant Denosumab therapy following curettage and external fixator for a giant cell tumor of the distal radius presenting with a pathological fracture: A case report

Arulanantham Arulprashanth, Aadil Faleel, Chamikara Palkumbura, Umesh Jayarajah, Rukshan Sooriyarachchi

Article 107342



[View PDF](#)

Article preview [▼](#)

Case report ● Open access

An exceedingly rare simultaneous incidental occurrence of synchronous primary malignancies; Invasive Ductal Carcinoma and Renal Cell Carcinoma in a male - A Case Report

Omar Al Laham, Fareed Atia, Dana Ibrahim, Jack Shaheen, Bashir Hokouk

Article 107367



[View PDF](#)

Article preview [▼](#)

Case report ● Open access

Giant uterus in a patient with Klippel-Trenaunay syndrome. Report of a case

Giuseppe Di Buono, Federica Ricupati, Roberta Vella, Marta Saverino, ... Antonino Agrusa

Article 107376





[View PDF](#)

Article preview [▼](#)

Case report ● Open access

Subacute (De Quervain's) thyroiditis presenting as painful thyroid nodule suspicious of papillary thyroid carcinoma: Case report


Mohamed S. Al Hassan, Walid El Ansari, Mahir Petkar, Sabir A. Al Sharani, Abdelrahman Abdelaal
Article 107329

 [View PDF](#) [Article preview](#) 

Case report ● Open access

Primary intra-testicular rhabdomyosarcoma: Case report

Elouarith Ihssan, Elmajoudi Salma, Mamad Ayoub, Slaoui Amine, ... Znati Kaoutar
Article 107340

 [View PDF](#) [Article preview](#) 

Case report ● Open access

Ovarian small cell carcinoma by ovarian torsion feature: A cytopathology challenging case

Fatemeh Keikha, Alireza Hadizadeh, Setareh Akhavan, Fatemeh Nili, ... Marjan Ghaemi
Article 107337

 [View PDF](#) [Article preview](#) 

Case report ● Open access

Left sided Amyand hernia – A case report

Jayateertha Joshi, Esha Mallik, Talha Ahmed, Rahul Bhat, George M. Varghese
Article 107374

 [View PDF](#) [Article preview](#) 

Case report ● Open access

Case report ● Open access

Upper thoracic spondylitis tuberculosis treated by posterior approach only: A case report

Iman Solichin, Muhammad Dedy Alkarni

Article 107321



[View PDF](#)

Article preview [▼](#)

Case report ● Open access

An unusual cause of tarsal tunnel syndrome: Schwannoma of the posterior tibial nerve; a rare cause and rare localization

Naoufal Elghoul, Kamal Elmokhtari, Salim Ahmed Bouabid

Article 107348



[View PDF](#)

Article preview [▼](#)

Case report ● Open access

Vesicovaginal fistula with bladder and vaginal stone

Ahmad Agil, Aninditho Dimas Kurniawana

Article 107311



[View PDF](#)

Article preview [▼](#)

Case report ● Open access

Bilateral palsy of the hypoglossal nerve following general anesthesia for emergency surgery. A case report

Panagiota Brattou, Konstantinos Iliakopoulos, Evangelos Anagnostou, Thomas Zambelis, ... Kassiani Theodoraki

Article 107387



[View PDF](#)

Article preview [▼](#)

Case report ● Open access

Case report ● Open access

Epithelioid myofibroblastoma of the breast: A case report and review of the literature

Takahiro Inaishi, Takahiko Sakuma, Tomoki Fukuoka, Shu Ichihara

Article 107382



[View PDF](#)

[Article preview](#) [▼](#)

Case report ● Open access

Gunshot injury to the chest wall with an unusual bullet trajectory: A rare case report

Jijo Anto, Anil Kumar, Anurag Kumar, Majid Anwer, ... Deepak Kumar

Article 107343



[View PDF](#)

[Article preview](#) [▼](#)

Case report ● Open access

Idiopathic megacolon complicated by life-threatening giant megacolon and respiratory failure due to diaphragmatic eventration: A case report

Masataka Fujiwara, Ai Sadatomo, Hiroyoshi Tsubochi, Hisanaga Horie, ... Naohiro Sata

Article 107372



[View PDF](#)

[Article preview](#) [▼](#)

Case report ● Open access

Management of ruptured hepatocellular carcinoma invading the gastrointestinal tract: A case report

Bassel Hafez, Bassam Osman, Joelle Chami, Jana Haidar Ahmad, ... Mohamad Jawad Khalife

Article 107330



[View PDF](#)

[Article preview](#) [▼](#)

Case report ● Open access

Case report ● Open access

Double right coronary artery with fistula to the right atrium and mitral insufficiency: A case report

Mohammad Nour Aldeen Koukash, Marah Hamad, Adeb Makhlouf, Ameer Kakaje, Bayan Alsaid

Article 107386



[View PDF](#)

Article preview [▼](#)

Case report ● Open access

Ciliated hepatic foregut cyst: A case report and review of literature

Cláudio Silva, Luísa Ferreira, Cláudio Branco, Vítor Simões, ... José Davide

Article 107356



[View PDF](#)

Article preview [▼](#)

Case report ● Open access

Primary squamous cell carcinoma of the colon: A rare case report

Hussein Nassar, Karim Ataya, Bassel Hafez, Ayman El Bsat, ... Walid Faraj

Article 107383



[View PDF](#)

Article preview [▼](#)

Case Series

Mini review ● Open access

Atypical parathyroid adenoma: Series of two consecutive cases from a tertiary care hospital in Qatar

Mohamed S. AL Hassan, Walid El Ansari, Adham Darweesh, Mahir Petkar, Abdelrahman Abdelaal

Article 107296



[View PDF](#)

Article preview [▼](#)

Submit your article [↗](#)

Guide for authors [↗](#)

Menu



[View PDF](#) [Article preview](#)

Mini review ● *Open access*

Mini-mesohepatectomy for tumours at the hepatocaval confluence: A cases series and review of the literature

Pranav H. Patel, Vasileios Mavroeidis, Joseph Doyle, Sacheen Kumar, Ricky H. Bhogal

Article 107345



ELSEVIER

Copyright © 2023 Elsevier B.V. or its licensors or contributors.
ScienceDirect® is a registered trademark of Elsevier B.V.

RELX™

SARCOMA. CASE SERIES

Erwin Danil Yulian, Hana Qonita, Evelina Kodrat, Kevin Varian Marcevianto

Article 107345



[View PDF](#)

[Article preview](#)

[← Previous vol/issue](#)

[Next vol/issue >](#)

ISSN: 2210-2612

Copyright © 2023 IJS Publishing Group Ltd. Published by Elsevier Ltd. All rights reserved



International Journal of Surgery Case Reports

Editor-in-Chief

Professor David Rosin, Barbados, West Indies

Managing and Executive Editor

Dr Riaz Agha, London, UK

Assistant Managing Editor

Maliha Agha, London, UK

Senior Editors

Professor Hasan Alam, Michigan, USA
Professor Raafat Afifi, Cairo, Egypt
Dr Juan Barret, Barcelona, Spain
Mr Ben Challacombe, London, UK
Dr Xiaoping Chen, Wuhan, China

Dr Burcin Eksker, Indianapolis, USA
Professor Joseph W Y Lau, Shatin, Hong Kong
Dr Oliver Muensterer, New York, USA
Dr Selwyn Rogers, Galveston, Texas
Professor Jamsheer Talati, Karachi, Pakistan

Dr Mangesh Thorat, London, UK
Professor Fu Chan Wei, Taipei, Taiwan
Professor Rudy Leon De Wilde, Oldenburg, Germany

Associate Editors

Professor Roberto Coppola, Rome, Italy
Dr Veerappan Kasivisvanathan, London, UK
Dr Richard Keijzer, Winnipeg, Canada, USA
Dr Boris Kirshtein, Beer Sheva, Israel

Professor James McCaul, London, UK
Miss Emma McGlone, London, UK
Dr Dattatraya Muzumdar, Mumbai, India
Professor Andy Petroianu, Minas Gerais, Brazil

Mr Shahzad Raja, London, UK
Dr Kandiah Raveedran, Ipoh, Malaysia
Dr Daniel Yeh, Boston, USA

Assistant Editors

Dr Rafid Al-Mahfoudh, Oxford, UK
Dr Hussein Atta, Boston, USA
Dr Mohammad Bashashati, Texas, USA
Professor Somprakash Basu, Varanasi, India
Mr Andrew Beamish, Cardiff, UK
Dr Anthony Charles, North Carolina, USA
Dr Amitava Das, Hyderabad, India
Dr Brian Davis, Texas, USA
Dr Susana Adriana Esquivel, Córdoba, Mexico
Professor Sheng Feng, Shanghai, China

Dr Juan Gomez Rivas, Madrid, Spain
Dr Satoshi Ieiri, Kagoshima City, Japan
Dr Haytham Kaafarani, Massachusetts, USA
Dr Yogeesh Kamat, Karnataka, India
Mr Omar Khan, London, UK
Prof. Tsuyoshi Konishi, Osaka, Japan
Dr Vito A Mannacio, Naples, Italy
Dr Todd Manning, Oxford, UK
Dr Zubing Mei, Shanghai, China
Dr Umesh Metkar, Beth, Israel

Dr Indraneil Mukherjee, Staten Island, USA
Dr Enyi Ofo, Adelaide, South Australia
Dr Lena Perger, Albuquerque, USA
Professor Prathamesh S Pai, Mumbai, India
Dr Alfredas Smailys, Kaunas, Lithuania
Prof. Peter Hyunsuk Suh, Seoul, South Korea
Dr Dieter Weber, Perth, Australia
Dr John Wee, Boston, USA
Dr Hongyi Zhu, Shanghai, China

Statistical Editors

Dr Derek Cooper, London, UK
Professor Nora Donaldson, London, UK
Professor Mary W Gray, Washington DC, USA

Society Representative

Deniz Balci, Representative of the International Society of Liver Surgeons
Rhiannon Harries, President, Association of Surgeons in Training
Gene F. Coppa, President of the New York Surgical Society
Xiao-ping Chen, President of the Chinese Chapter of International Hepato-Pancreato-Biliary Association

Social Media Editor

Dr Riaz Agha, London, UK

Assistant Commissioning Editors

Ahmed Al-Jabir, London, UK
Zaid Alsafi, London, UK
Thomas Franchi, Sheffield, UK
Christos Iosifides, London, UK

Ahmed Kerwan, London, UK
Mehdi Khan, London, UK
Ginimol Matthew, London, UK
Maria Nicola, London, UK

Niamh O'Neill, London, UK
Catrin Sohrabi, London, UK

Executive Committee

Professor David Albala, New York, USA
Sir Graeme Catto, London, UK
Professor David Cooper, Pittsburgh, USA
Lord Ara Darzi, London, UK
Professor Harold Ellis, London, UK
Ather Enam, Karachi, Pakistan

Sir Barry Jackson, London, UK
Professor Arthur Li Kwok-Cheung, Wanchai, Hong Kong
Professor C H Leong, Central, Hong Kong
Lord Ian McColl, London, UK

John Norcini, Philadelphia, USA
Professor Susan Standing, London, UK
Lord Robert Winston, London, UK
Sir Magdi Yacoub, London, UK

Editorial Board

Raj Badwe
Mumbai, India
Michael Boscoe
Middlesex, UK
Rapheal Bueno
Boston, USA
Kris Chatamra
Bangkok, Thailand
Paul Coulthard
Manchester, UK
Anil d'Cruz
Mumbai, India
Mahesh Desai
Mumbai, India
Juan Gomez Rivas
Spain, Madrid

David W. Green
London, UK
Iraj Harirchi
Tehran, Iran
Doris Henne-Bruns
Ulm, Germany
Delawir Kahn
Cape Town, South Africa
Xiaoxi Lin
Shanghai, China
Ashok Mahapatra
New Delhi, India
Todd Manning
Melbourne, Australia
Indraneel Mittra
Mumbai, India

Vijay Naraynsingh
West Indies
Fabio Nicoli
London, UK
Anibal R. Núñez De Pierro
Buenos Aires, Argentina
Reuben Orda
Tel Aviv, Israel
Vladimir Semiglazov
St. Petersburg, Russia
Tejinder Singh
Ludhiana, India
Barbara L. Smith
Boston, USA
James Tatum
California, USA

Tehemton Udhwadia
Mumbai, India
Martin R. Weiser
New York, USA
Yixin Zhang
Shanghai, China
Jun Zhong
Shanghai, China
Zhao-Fan Xia
Shanghai, China

Elsevier

Executive Publisher

Ash Allan, Oxford, UK

Administrative Editor

Josie Hutchins, Oxford, UK

Marketing Manager

Jayne Dawkins, Philadelphia, USA

Journal Manager

Tamsyn Hopkins, Exeter, UK

Senior Business Development Executive (Reprints)

Emma Steel, London, UK

Advertising Sales Manager

Robert Bayliss, London, UK

Account Manager (Supplements)

Evelina Euren, Amsterdam, the Netherlands

Project Manager Supplements & E-business

Mónica Hernández-Sesma, Amsterdam, the Netherlands

Processed at Thomson Digital, Gangtok (India)



Case report

Severe penile fracture with bilateral corpus cavernosum rupture, complete urethral rupture and scrotal haematoma associated with sexual intercourse: A case report



Made Adi Wiratama^{a,b}, Wahjoe Djatisoesanto^{a,b}, Lukman Hakim^{a,c,*}

^a Department of Urology, Faculty of Medicine, Universitas Airlangga, Surabaya, East Java, Indonesia

^b Dr. Soetomo General-Academic Hospital, Surabaya, East Java, Indonesia

^c Universitas Airlangga Teaching Hospital, Surabaya, East Java, Indonesia

ARTICLE INFO

Keywords:

Penile fracture
Urethral rupture
Sexual health
Immediate repair
Case report

ABSTRACT

Introduction and importance: Despite the fact that a penile fracture is a rare emergency, it can cause morbidity in the patient, especially in terms of sexual life. If cases are not properly managed, irregularities in the penis will emerge, leading to more complicated problems. We present a case report of severe penile fracture associated with sexual intercourse.

Case presentation: A 50-year-old man complained of soreness in his penis during sexual intercourse. The patient also has urethrorrhagia and is unable to urinate. Physical examination reveals the "Eggplant Deformity" in the penis. The operation was carried out and revealed bilateral corpus cavernosum rupture, complete urethral rupture, and ruptured Buck's fascia. The corpus cavernosum and other structures were repaired primarily, followed by an end-to-end anastomosis of the urethra. Four months later, the patient had no serious complaints, only a minor penis deviation. He can easily void and having intercourse.

Clinical discussion: In most situations, the penile fracture can be determined nearly entirely based on the patient's medical history and physical examination. In dubious circumstances, further tests such as ultrasonography and MRI can be conducted. If a penile fracture is discovered, surgery should be undertaken. Ruptures of the corpus cavernosum, tunica albuginea and Buck's fascia can be sutured primarily. The urethral can be reconstructed using an end-to-end anastomosis. Scrotal haematomas should be evacuated and drained to prevent persistent scrotal haematomas.

Conclusion: Immediate surgery in cases of severe penile fracture provides good outcomes for erectile function, micturition and sexual intercourse with minimal complications.

1. Introduction

A laceration of the corpus cavernosum or a penile fracture caused by trauma to the erect penis is considered an emergency in urology [1]. Penile fracture is one of the less common injuries during sexual activity. The majority of lacerations are unilateral, with bilateral lacerations occurring in approximately 2 to 10 % of cases. Urethral injuries are uncommon, accounting for 9 to 20 % of penile fractures [2].

Due to vigorous sexual intercourse, the erect penis detaches from the vagina and collides with the perineum or pubic bone, resulting in a fracture. The penile structures are lacerated when intracavernosal pressure rises stronger than the tunica albuginea's elastic strength.

Many studies have found that immediate surgical exploration is superior to conservative treatment. Immediate surgery produces minimal complications and better long-term results, particularly in erectile function and penile curvature [3–5]. However, no publication exists on treating a severe penile fracture with bilateral corpus cavernosum rupture, urinary retention due to complete urethral rupture and scrotal haematoma. This case was reported in accordance with the SCARE guidelines [6].

2. Presentation of case

A man in his 50s arrived at our facility on his own, complaining of a

* Corresponding author at: Department of Urology, Faculty of Medicine, Universitas Airlangga, Universitas Airlangga Teaching Hospital, Jl. Mayjen Prof. Dr. Moestopo No.47, Surabaya, East Java 60132, Indonesia.

E-mail address: lukman-h@fk.unair.ac.id (L. Hakim).

<https://doi.org/10.1016/j.ijscr.2022.107377>

Received 2 June 2022; Received in revised form 27 June 2022; Accepted 27 June 2022

Available online 30 June 2022

2210-2612/© 2022 Published by Elsevier Ltd on behalf of IJS Publishing Group Ltd. This is an open access article under the CC BY-NC-ND license (<http://creativecommons.org/licenses/by-nc-nd/4.0/>).

swollen penis for 4 h before admission. The patient was having intercourse with his wife when he felt a “crack” feeling, followed by detumescence of the penis, extreme discomfort, urethrorrhagia and unable to void. The patient has no previous medication or allergy history. There was no history of metabolic disease.

A characteristic eggplant deformity on the penis was discovered during a physical examination (Fig. 1). The penis was swollen and deviated to the right, with significant haematoma running from the proximal penis to the scrotum.

The results of all laboratory tests were typical. The involvement of the urethra was assessed by retrograde urethrography (RUG). RUG showed there was a rupture of the pendular urethra and a rupture of the right corpus cavernosum as shown in Fig. 2.

The operation was performed on an emergency basis, 2 h after patient came, by the chief resident with 4.5 years of urology training. The penile skin was degloved to the proximal healthy tissue after a circumferential incision in the subcoronal. The anterior urethra was entirely ruptured, and also the corpus cavernosum was ruptured bilaterally (Fig. 3). Buck's fascia is also torn, which causes haematoma to spread all the way to the scrotum. No disrupted vasculature was found.

Polyglactin 4.0 sutures were used to provide a tension-free end-to-end urethral anastomosis. Polyglactin 3.0 sutures are used to suture the corpus cavernosum. After the corpus cavernosum was repaired, an artificial erection test was performed. Fluid leakage and penile curvature were not present. The second suture layer was dartos fascia, and the skin was closed with plain catgut 3.0 (Fig. 4). The Penrose drain was used to drain the scrotal haematoma through multiple scrotal incisions. The haematoma and edema were then handled with scrotal support.

He was discharged on the fifth postoperative day after Penrose drain production was reduced. He was discharged with a 16 Fr catheter that he was supposed to keep for 21 days.

The patient returned for outpatient visits on the seventh postoperative day. The surgical wound appeared to be in good shape. The patient was seen again on the 21st postoperative day, and the urethral catheter was withdrawn. Uroflowmetry and post-void residual (PVR) tests were employed to assess the operation's success. Uroflowmetry revealed a Qmax of 21 ml/s, an average flow rate of 14.4 ml/s, and voided volume of 197 ml with a minimum PVR of 18.7 cm³. The outcome was considered satisfactory.

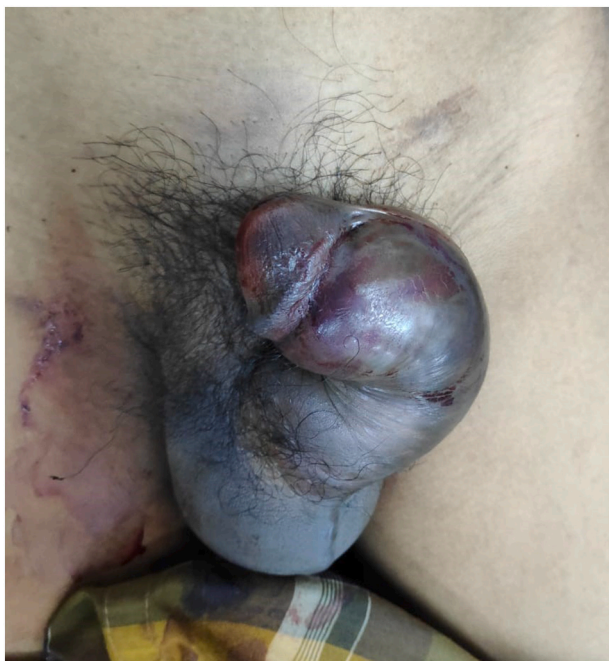

Fig. 1. Eggplant deformity of the penis.

Four months later, the patient was re-evaluated. Because of his isolated location and inadequate transportation, the patient refused to come. Phone and internet follow-up were employed in telemedicine. The patient was delighted with the outcome. The patient can now void and interact sexually with his wife without experiencing any discomfort. In the clinical image taken four months after surgery (Fig. 5), the penis was slightly deviated to the left.

3. Discussion

Penile fracture, caused by blunt trauma to the erect penis, is a urological emergency. The majority of these penile fractures occur during sexual activity, with a minor percentage occurring during masturbation, falling out of bed with an erect penis, and other penile trauma [7,8]. Meanwhile in the Middle Eastern countries, the practice of “taghaandan” or self-bending of erect penis to achieve detumescence, contribute to high incidence of penile fracture at that region [9,10].

Bilateral corpus cavernosum rupture with urethral involvement is a rare occurrence. In one study by Panella et al., found only two cases of penile fracture with bilateral corpus cavernosum rupture with urethral involvement [7] and the study by Barros et al. reported finding 15 out of 288 (5.2 %) overall penile fracture cases involving bilateral corpus cavernosum rupture and complete urethral rupture from his 20-year experience in Brazil [8]. Cases of penile fracture accompanied by scrotal haematoma have so far only been reported in one publication [11], however, bilateral corpus cavernosum and complete urethral rupture were not present.

The majority of penile fractures are straightforward to identify. A key diagnostic finding in the initial evaluation is the classic triad of haematoma, detumescence, and snapping sound [8]. The integrity of the penis fascia determines haematoma distribution. Blood extravasation is limited to the penis if Buck's fascia is intact, if Buck's fascia is lacerated, a butterfly haematoma develops, extending to the scrotum, perineum, and pubis [1]. In cases of penile trauma with a scrotal haematoma, a differential diagnosis should be made by rupture of deep dorsal penile vessels with haematoma extravasation outside Buck's fascia, rupture of superficial dorsal penile vein or non-specific dartos bleeding. Imaging studies of the penis, such as ultrasonography and MRI, can be done in doubtful case.

The most typical approach for exploring the anatomical location of the injury is a circumferential subcoronal incision with degloving to the proximal region of the penis. Because the location of the ruptured tissue was doubtful due to the presence of a massive haematoma across the penile structure up to the scrotum, a circumferential subcoronal incision was performed in this case. This incision allows a thorough examination of the corporal body, which can aid in the discovery of a contralateral corporal body or urethral lesions and make repair easier [12]. If the exact position of the injury was known prior to surgery, it would be advantageous to perform the exploration through the midline penis incision. This incision has the advantage of minimizing tissue exploration, which reduces postoperative adverse effects such penile curvature and erectile dysfunction [13].

The corpus cavernosum is repaired utilizing the watertight closure principle, which is subsequently demonstrated via an artificial erection test. The management for urethral rupture in penile fractures is the same as for male anterior urethral injuries, namely urethral surgical exploration and reconstruction with or without a suprapubic catheter. It's difficult to define the boundaries of healthy urethral tissue for repair because of contusions and haematomas in the spongiosum tissue. According to certain experts and the literature, suprapubic catheterization should be done first, followed by urethroplasty once the contusion and haematoma have subsided [14]. There is no substantial difference in outcome between immediate and delayed urethral reconstruction, according to several studies.

In this case, we performed an immediate urethral exploration and reconstruction because we were concerned that a suprapubic catheter

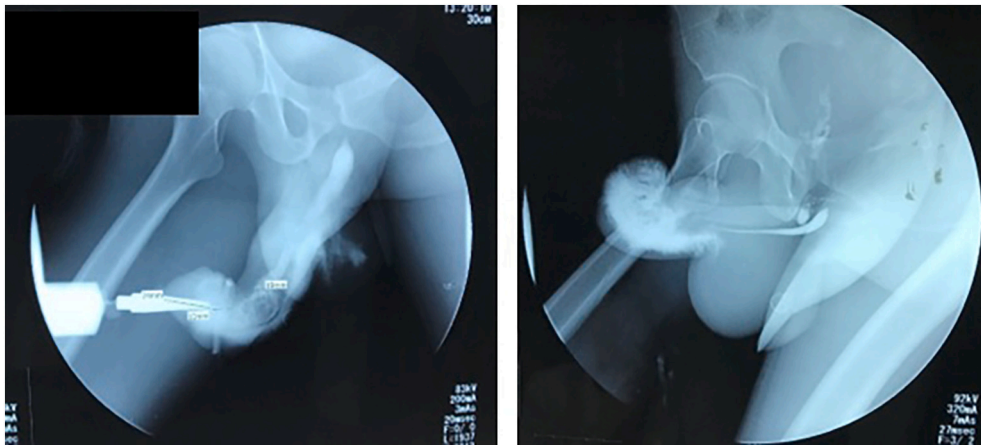


Fig. 2. Pre-operative RUG.

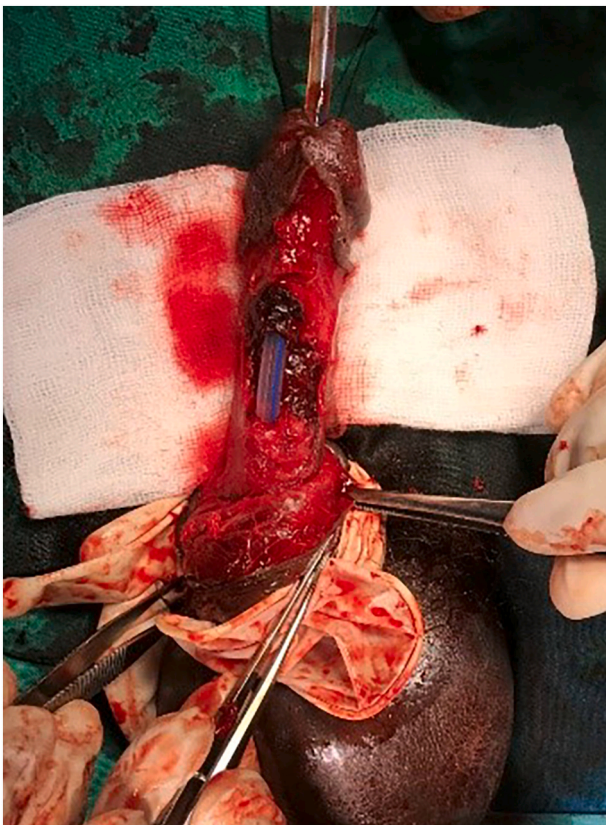


Fig. 3. Bilateral corpus cavernosum rupture and complete urethral rupture.

would result in additional morbidities like surgical site infection, urinary tract infection, bladder stones, urine leakage upon catheter release, and patient discomfort. EAU guideline also recommends to do the immediate exploration and reconstruction for anterior urethral injury in case of penile fracture [15]. Barros also stated that in his 11 years of experience, primary urethral reconstruction associated with penile fracture yields good results with minor sequelae [8]. The urethra was reconstructed with polyglactin 4.0 sutures. The tunica albuginea and Buck's fascia were repaired primarily. To prevent blood from clotting in the scrotum, we made multiple incisions in the scrotum and inserted a penrose drain. It's also crucial to provide scrotal support.

After four months of follow-up, normal uroflowmetry revealed that immediate repair and reconstruction of the urethra resulted in

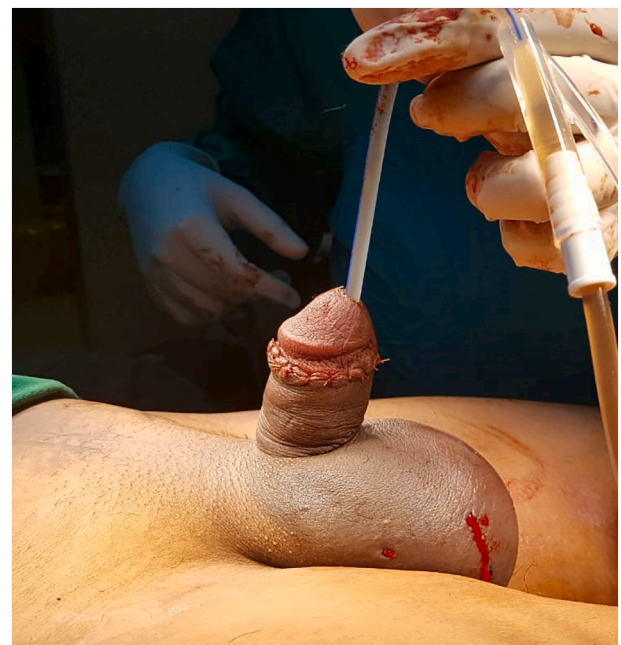

Fig. 4. Post-operative appearance of the penis.

satisfactory results with no complaints during micturition. This patient had a minor penile curvature to the left when the penis was erect, but no pain was reported, and the condition did not interfere with sexual intercourse. Overall, the patient expressed contentment and satisfaction with the outcome of his procedure. The limitation of this case is that the patient declined to visit the hospital due to his remote location, therefore we were unable to perform the radiological follow-up, i.e. RUG.

4. Conclusion

Penile fracture is a rare urological emergency, especially when there is a urethral injury. Penile fracture can be diagnosed with a clinical examination and a medical history. Surgical investigation and repair of defects associated with penile fractures should be done as soon as possible within 24 h to avoid complications. In a patient with a severe penile fracture caused by bilateral corpus cavernosum rupture compounded by complete urethral rupture, this case report indicates that early surgery can result in a favorable outcome with few sequelae.



Fig. 5. Four months after surgery. Penis looks deviated to the left.

Provenance and peer review

Not commissioned, externally peer-reviewed.

Sources of funding

No financial funding was provided for the research, writing, or publication of this article.

Ethical approval

The ethical clearance for this research was issued by The Hospital Research Ethics Committee of “Rumah Sakit Umum Daerah Dr. Soetomo” where the patient was admitted (Ethical Clearance number: 0031/LOE/301.4.2/VI/2020).

Consent

Written informed consent was obtained from the patient for publication of this case report and accompanying images. A copy of the written consent is available for review by the Editor-in-Chief of this journal on request.

Author contribution

- Made Adi Wiratama: Conceptualization, Design, Resources, Data Collection, Writing Manuscript

- Wahjoe Djatisoesanto: Investigation, Resources, Supervision, Critical Review
- Lukman Hakim: Conceptualization, Resources, Supervision, Review and Editing

Registration of research studies

Not applicable.

Guarantor

Lukman Hakim.

Declaration of competing interest

The authors declare no conflict of interest.

References

- [1] J. Mathew, K. Parmar, A. Chandna, S. Kumar, Penile fracture associated with complete urethra and bilateral corpora cavernosa transection, *Ann. R. Coll. Surg. Engl.* 103 (3) (2021) E88–E90.
- [2] N.A. Hoag, K. Hennesse, A. So, Penile fracture with bilateral corporeal rupture and complete urethral disruption: case report and literature review, *J. Can. Urol. Assoc.* 5 (2) (2011) 23–26.
- [3] T. Yapanoglu, Y. Aksoy, S. Adanur, B. Kabadayi, G. Ozturk, I. Ozbey, Seventeen years' experience of penile fracture: conservative vs. Surgical treatment, *J. Sex. Med.* 6 (7) (2009) 2058–2063.
- [4] W.M. Gamal, M.M. Osman, A. Hammady, M.Z. Aldahshoury, M.M. Hussein, M. Saleem, Penile fracture: long-term results of surgical and conservative management, *J. Trauma* 71 (2) (2011) 491–493.
- [5] K.G.R. Yamaçake, A. Tavares, G.P. Padovani, G.B. Guglielmetti, J. Cury, M. Srougi, Long-term treatment outcomes between surgical correction and conservative management for penile fracture: retrospective analysis, *Korean J. Urol.* 54 (7) (2013) 472–476.
- [6] R.A. Agha, T. Franchi, C. Sohrabi, G. Mathew, A. Kerwan, A. Thoma, et al., The SCARE 2020 guideline: updating consensus surgical CAse REport (SCARE) guidelines, *Int. J. Surg.* 84 (2020) 226–230.
- [7] P. Panella, P. Pepe, M. Pennisi, Diagnosis and treatment of penile injury: ten years experience of an emergency department, *Arch. Ital. Urol. Androl.* 92 (3) (2020) 192–195.
- [8] R. Barros, D. Hampl, A.G. Cavalcanti, L.A. Favorito, L. Koifman, Lessons learned after 20 years' experience with penile fracture, *Int. Braz. J. Urol.* 46 (3) (2020) 409–416.
- [9] C. Bastianpillai, A. Wang, J. Kumaradevan, S. Chitale, Accidental, non-masturbatory, non-intercourse related, self-inflicted penile fracture: case report and review of literature, *Urol. Case Rep.* 12 (2017) 45–46, <https://doi.org/10.1016/j.eucr.2017.02.008>. Available from:.
- [10] J. Zargooshi, Penile fracture in Kermanshah, Iran: the long-term results of surgical treatment, *BJU Int.* 89 (9) (2002) 890–894.
- [11] F. Hajji, A. Ameer, Butterfly hematoma after traumatic intercourse, *Pan. Afr. Med. J.* 20 (2015) 317.
- [12] H. Kominsky, S. Beebe, N. Shah, L.C. Jenkins, Surgical reconstruction for penile fracture: a systematic review, *Int. J. Impot. Res.* 32 (1) (2020) 75–80, <https://doi.org/10.1038/s41443-019-0212-1>. Available from:.
- [13] G. Ge, H. Wang, Y. Chen, G. Li, L. Ma, Complete urethral injury in the penile fracture: a case report and literature review, *Transl. Androl. Urol.* 10 (2) (2021) 669–675.
- [14] S. Brandes, Initial management of anterior and posterior urethral injuries, *Urol. Clin. N. Am.* 33 (1) (2006) 87–95.
- [15] N. Kitrey, F. Campos-Juanatey, P. Hallscheidt, E. Serafetinidis, D. Sharma, M. Waterloos, EAU Guidelines on Urological Trauma, 2022nd ed., EAU Guidelines Office, Arnhem, the Netherlands, 2022, 23–24 p.