

# Diagnostic and Management Problems of Hyperthyroidism in A Patient with Testicular Seminoma

*by* Hermina Novida

---

**Submission date:** 18-Mar-2022 10:10AM (UTC+0800)

**Submission ID:** 1786783497

**File name:** DIAGNO\_1.PDF (403.13K)

**Word count:** 4828

**Character count:** 27379

## CASE REPORT

# Diagnostic and Management Problems of Hyperthyroidism in A Patient with Testicular Seminoma

Dicky Febrianto\*, Hermina Novida<sup>1b</sup>, Agung Pranoto<sup>1b</sup>

<sup>6</sup> Division of Endocrinology, Metabolism, and Diabetes; Department of Internal Medicine, Faculty of Medicine, Universitas Airlangga, Surabaya, Indonesia – Dr. Soetomo General Hospital Surabaya, Indonesia <sup>24</sup>

## ABSTRACT

<sup>4</sup> Patients with thyroid dysfunction are well represented in the general population. Hyperthyroidism can develop as a paraneoplastic syndrome in germ cell tumors. As a form of germ cell tumors, Testicular seminoma can express human chorionic gonadotropin (hCG). Beta-hCG strongly resembles TSH. A 26-year-old male with a history of cryptorchidism came to Dr. Soetomo Hospital with complaints of palpitation, diarrhea, weight loss, fatigue, nervousness, excessive sweating, and heat intolerance. He also complained of enlarged breasts and a palpable mass in the lower abdomen for four months. The TSH and FT4 examinations showed that the patient's symptoms were following thyrotoxicosis. Anti-TPO and thyroid USG examinations were within normal limits. The patient was treated with beta-blocker and thiamazole. Histopathology of the abdominal mass showed a testicular seminoma. After surgery and chemotherapy, the clinical symptoms of hyperthyroidism gradually improved. Administration of beta-blocker and thiamazole was stopped in 4 months after surgery. We reported a patient with symptoms of thyrotoxicosis. Thyrotoxicosis was then related to his abdominal mass, a testicular seminoma. Hyperthyroidism was treated with beta-blocker and thiamazole. The clinical symptoms of hyperthyroidism gradually improved after surgery and chemotherapy.

**Keywords:** Hyperthyroidism, Thyrotoxicosis, Beta-hCG, Testicular Seminoma

**Correspondence:** Dicky Febrianto  
E-mail: dickyfebrianto88@gmail.com

<sup>23</sup> *Article history:* •Received 27 August 2021 •Received in revised form 15 October 2021 •Accepted 1 November 2021 •Available online 31 January 2022

## INTRODUCTION

<sup>4</sup> Patients with thyroid dysfunction are well represented in the general population. Studies report the prevalence of abnormal thyroid function as high as 21% in women and 3% in men. Thyroid hormones play a crucial role in homeostasis due to their effects on the cardiovascular, respiratory, renal, gastrointestinal, hematologic, and central nervous systems (Palace, 2017). The term "hyperthyroidism" refers to an increase of biosynthesis and secretion of thyroid hormone by the thyroid hormone. In contrast, the term "thyrotoxicosis" refers to clinical syndromes of hypermetabolism and hyperactivity, which happens when the concentration of free thyroxine (FT4), free triiodothyronine (FT3), or both increase (Sutjahjo & Tjokropawiro, 2015).

Hyperthyroidism can develop as a paraneoplastic syndrome in germ cell tumors. Tumor cell germinativum can express alpha-fetoprotein (AFP) and human chorionic gonadotropin (hCG). The hCG molecule has a high level of homology with thyroid-stimulating hormone (TSH) to bind to the TSH receptors and cause the clinical symptoms of hyperthyroidism (Baagar et al., 2013).

Symptomatic management of hyperthyroidism induced by germ cell tumors is not different from hyperthyroidism in general, namely administration of beta-adrenergic receptor antagonists (beta-blockers) and anti-thyroid drugs. However, definitive therapy for hyperthyroidism in malignancies that secrete hCG is the management of malignancy. The main treatment of germ cell tumors is surgery, continued by chemotherapy (Hussain & Eck, 2012).

<sup>3</sup> In this report, we present a case of a young man with a history of undescended testicles who had hyperthyroidism suspected of being related to the intraabdominal tumor. The notion that hyperthyroidism was a paraneoplastic syndrome arose because there was no prior history of thyroid disorders and thyroid ultrasound examination was within normal limits. The patient underwent an open biopsy, and it was proven that the intraabdominal tumor was testicular seminoma which was one type of germ cell tumor. Clinical symptoms of thyrotoxicosis were managed with beta-blocker and anti-thyroid drugs. The clinical manifestation of hyperthyroidism improved after surgery and chemotherapy.

## CASE REPORT

A 26-year-old man, Mr. MIM, having his address at Surabaya, East Java, ethnic Javanese, married, came to the Endocrinology Clinic of Dr. Soetomo Hospital on April 14, 2017, with complaints of palpitation, diarrhea, weight loss, fatigue, heat intolerance, and sleeping difficulty since the last one month. The patient also complained of nausea, abdominal discomfort, enlarged breast, and a palpable mass in the lower abdomen for four months—no complaints of fever, tightness, and coughing. The patient had been married for almost two years and has no children. The patient only has one testicle from birth.

Physical examination of the patient showed the awareness was compos mentis, GCS of 456, and visual analog scale (VAS) of 0. Vital signs: blood pressure of



130/80 mmHg, pulse rate of 105 times/minute, respiratory rate of 20 times/minute, temperature 37.8°C. On examination of the head and neck, no exophthalmos was found, and no thyroid gland enlargement was obtained. On examination of the abdomen, mild ascites and mass were found in the suprapubic region with a diameter of approximately 10 cm, painless in palpation. Examination of the thorax and the extremities were within normal limits.

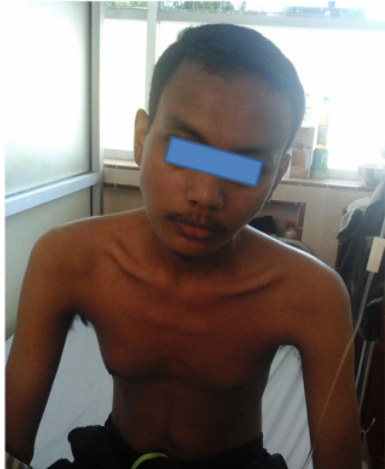

Figure 1. Patient Mr. MIM, 26 years old.

Automated blood count on April 17th, 2017, demonstrated hemoglobin of 9.5 g/dL, leukocyte count of 4,510/ $\mu$ L with neutrophils of 65.1%, platelet count of 187,000/ $\mu$ L, MCV of 85 fl, MCH of 30 pg, HBsAg of non-reactive, anti-HCV of non-reactive, ALT of 74 U/L, AST of 56 U/L, albumin of 4.0 g/dL, direct bilirubin of 0.69 mg/dL, total bilirubin of 1.40 mg/dL, BUN of 9 mg/dL, serum creatinine of 0.71 mg/dL, potassium of 4.1 mmol/L, sodium of 140 mmol/L, chloride of 119 mmol/L, PPT of 9.6 seconds (normal: 9-12), APTT of 25.1 seconds (normal: 23-33), total quantitative beta-HCG of >150,000 IU/mL (normal: <3), total T3 of 1.23 pg/mL (normal: 0.60-1.81), total T4 of 18.7 ng/mL (normal: 4.50-10.9), TSH of 0.017 mIU/mL (normal: 0.55-4.78), FT3 of 4.0 pg/mL (normal: 2.3-4.2), and FT4 of 4.18 ng/dL (normal: 0.89-1.76).

Abdominal ultrasound showed a solid lesion with cystic lesions in it. The boundary was less firm with a lobulated edge, 10.52x8.43x9.02 cm in the suprapubic region, with differential diagnosis of gastrointestinal stromal tumor and intralesional vascularization (+). Thyroid ultrasound examination was within the standard limit. On April 25th, 2017, an abdominal CT scan showed a suprapubic solid mass sized 14x10 cm with cystic lesions in it. The group absorbed contrast with the differential diagnoses of teratoma and suprapubic abscess. Chest X-ray showed that the heart and lungs were within normal limits and that no metastatic process was seen.

The patient returned to Endocrinology Clinic on April 27th, 2017, and was diagnosed with thyrotoxicosis, intraabdominal mass with differential diagnoses of teratoma and suprapubic abscess, and normochromic normocytic anemia. The patient has been treated with thiamazole 10 mg twice daily and propranolol 10 mg three times daily. An anti-TPO lab check was done to investigate the autoimmune cause of thyrotoxicosis conditions. The patient was also consulted to Oncology Clinic for consideration of open

biopsy to establish the diagnosis of intra-abdominal mass.

On May 15th, 2017, a laparotomy and open biopsy of the abdominal tumor were performed. Towards the operation, thiamazole and propranolol therapy were continued. From histopathological examination of abdominal tumor tissue, malignant germ cell tumors with seminoma dominance and choriocarcinoma were found.

On May 29th, 2017, patient was hospitalized in Internal Medicine ward and planned for chemotherapy. Complaints of abdominal discomfort, palpitations, and fatigue had improved. Vital signs: blood pressure of 110/80 mmHg, pulse rate of 90 times/minute, respiratory rate of 20 times/minute, temperature of 37.0°C. Laboratory examination demonstrated hemoglobin of 9.7 g/dL, MCV of 86 fl, MCH of 31 pg, leukocyte count of 6.890/ $\mu$ L with neutrophils of 67.0%, platelet count of 340,000/ $\mu$ L, blood glucose of 91 mg/dL, ALT of 23 U/L, AST of 40 U/L, BUN of 10 mg/dL, serum creatinine of 0.74 mg/dL, total quantitative beta-HCG of 72,000 IU/mL (normal: <3), total T3 of 1.13 pg/mL (normal: 0.60-1.81), total T4 of 15.7 ng/mL (normal: 4.50-10.9), TSH of 0.1 mIU/mL (normal: 0.55-4.78), FT3 of 3.9 pg/mL (normal: 2.3-4.2), FT4 of 2.18 ng/dL (normal: 0.89-1.76), and anti-TPO of 10.8 IU/mL (normal: <35).

The patient was diagnosed with hyperthyroidism, testicular seminoma, and normochromic normocytic anemia. The patient received a blood transfusion to fulfill the chemotherapy requirement, i.e., hemoglobin >10 g/dL. The patient received chemotherapy with the BEP regimen, namely Bleomycin 30 mg (days 2, 9, and 16), Etoposide 100 mg (days 1-5), and Cisplatin 20 mg (days 1-5). Treatment for hyperthyroidism was continued with dose adjustment: thiamazole 10 mg once daily and propranolol 10 mg twice daily.

Chemotherapy with the BEP regimen was given in 3 cycles at 21 days intervals. The patient came to Endocrinology Clinic once a month. One month after surgery (June 2017), abdominal complaints, palpitation, and fatigue were improved. Laboratory examination showed total quantitative beta-HCG of 12,000 IU/mL (normal: <3), TSH of 0.1 mIU/mL (normal: 0.55-4.78), FT3 of 3.5 pg/mL (normal: 2.3-4.2), FT4 of 2.02 ng/dL (normal: 0.89-1.76). Treatment of hyperthyroidism was adjusted in dose: thiamazole 5 mg once daily and propranolol 10 mg once daily.

In the fourth month post-surgery (September 2017), the patient had no complaints. Laboratory examination showed total quantitative beta-HCG of 320 IU/mL (normal: <3), TSH of 0.60 mIU/mL (normal: 0.55-4.78), FT3 of 3.9 pg/mL (normal: 2.3-4.2), FT4 of 1.72 ng/dL (normal: 0.89-1.76). Treatment for hyperthyroidism was stopped as the patient had reached the euthyroid condition.

## DISCUSSION

The paraneoplastic syndrome was first described in the 1940s when it was recognized that certain neoplasms might cause various symptoms that are not solely attributable to direct tumor invasion, compression, and the development of metastases. Such neoplasms present or acquire in time the ability to secrete various biologically-active substances that can lead to the development of distinctive clinical syndromes. Paraneoplastic syndromes can be the product of tumor-secreted peptides, amines or cytokines, or immune cross-reactivity between neoplastic and normal tissues. They can originate from either endocrine or non-endocrine neoplasms (Pelosof & Gerber, 2010). Endocrinology's most

common paraneoplastic syndromes are hypercalcemia, SIADH, Cushing syndrome, hypoglycemia, acromegaly, ectopic beta-hCG production, ectopic gonadotropin production, and hypoaldosteronism (Dimitriadis et al., 2013).

Testicular neoplasms comprise the most common solid malignancy affecting men between 15 and 35, but they only represent almost 1% of all solid tumors in males. Approximately two to three new cases per 100,000 males are reported in the United States each year, and 95 percent of all primary testicular tumors are germ cell tumors (Baagar et al., 2013). Germ cell tumors are divided into seminomatous or non-seminomatous types (Hussain & Eck, 2012). About 10% of all testicular cancers are associated with cryptorchidism, with the highest risk with abdominal testis. Other than infertility, associated inguinal hernia and torsion, malignant change in the undescended testicle is a common complication (Bose et al., 2017). The cryptorchidism results from abnormalities in the formation and testicular descent during the embryonic period. The most common malignant transformation of an undescended testicle is testicular seminoma (Carlotto et al., 2015).

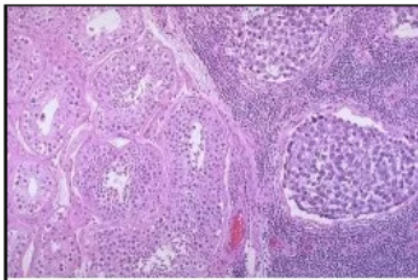


Figure 2. Illustration of normal testicular tissue (left) adjacent to seminoma (right) (The Testicular Cancer Research Center, 2018).

Testicular tumors usually present as a nodule or painless swelling of one testicle, which may be noted incidentally by the patient. Approximately 30 to 40 percent of patients complain of a dull ache or heavy sensation in the lower abdomen, perianal area, or scrotum, while acute pain is the presenting symptom in 10 percent. The presenting manifestations of testicular cancer are attributable to metastatic disease in approximately 10 percent of patients. Symptoms vary with the site of metastasis, such as anorexia, nausea, vomiting, or abdominal pain due to retroperitoneal metastasis. The paraneoplastic syndromes of testicular tumors are hyperthyroidism and gynecomastia (Taslimi, 2011).

In this patient, there was a history of cryptorchidism. The patient had only one testicle from birth. The patient complained of abdominal discomfort, palpable mass in the lower abdomen, and enlarged breasts for the last four months. From histopathological examination of abdominal tumor tissue, malignant germ cell tumors with seminoma dominance and choriocarcinoma were found. Germ cell tumors express either alpha-fetoprotein (AFP) or human chorionic gonadotropin (hCG). Intact hCG consists of two subunits, i.e., alpha and beta subunits. Beta-hCG levels are an important tool in diagnosing and monitoring the treatment of germ cell tumors (Hussain & Eck, 2012).

Hyperthyroidism is a manifestation of the paraneoplastic syndrome in germ cell tumors. The clinical symptoms may vary from an absence of symptoms, thyrotoxicosis,

to thyroid storm. Hyperthyroidism presents clinically as a physiological state dominated by an increased metabolic rate: myocardial contractility, heart rate, stroke volume, and ventricular size increase. Peripheral vascular resistance decreases in skin and muscle. Typical clinical findings include fatigue, weight loss, nervousness, excessive sweating, heat intolerance, hyperactivity, tremor, weakness, hyperdynamic precordium, diarrhea, increased appetite, muscle weakness, and tachycardia, minimal or without enlargement of the thyroid gland (Kurdi, 2014). Hyperthyroidism which manifests as thyrotoxicosis, can usually be seen in patients with very high hCG levels. It presents in 3.5% of the patients with germ cell tumors and 50% of the patients with hCG above 50,000 IU/L (Baagar et al., 2013).

In this patient, there were symptoms of palpitation, abdominal discomfort, weight loss, fatigue, sleeping difficulty, and heat resistance, which were in accordance with thyrotoxicosis. Increased hCG expression occurs in germ cell tumors and pregnancy and hydatiform moles. hCG is a glycoprotein with structural similarities with TSH (Meister et al., 2005). hCG is a heterodimer composed of an alpha-subunit and beta-subunit. hCG alpha-subunit is common to all the glycoprotein hormones (follicle-stimulating hormone/FSH, luteinizing hormone/LH, TSH). hCG and TSH beta-subunits are highly homologous, and both contain 12 half-cysteine residues and one N-linked oligosaccharide. Three disulfide bonds from a cysteine knot structure are identical in both hormones (Sotello et al., 2016).

Several data indicate that hCG is a weak human thyrotropin. Due to its homology, it also activates the TSH receptor. But the relative potency of hCG for the TSH receptor is 4000 times less than TSH. High circulating hCG levels with their TSH-like activity may result in a slightly low TSH and an increase in FT4 concentration. It is estimated that an increment of hCG of 10,000 IU/mL results in a decrease in TSH of 0.1 mU/L and an increase of FT4 of 0.6 pmol/L. The level of hCG largely influences the development of hyperthyroidism due to hCG. Clinically measurable changes in thyroid hormone concentration are only likely if hCG levels are around 50,000-70,000 IU/mL or more (Kurdi, 2014). More than 40% of patients with beta-hCG over 50,000 IU/mL have biochemical hyperthyroidism (Hussain & Eck, 2012). Serum levels of hCG of >100,000 IU/mL are usually needed to produce clinical evidence of thyrotoxicosis (Kurdi, 2014).

Not all patients with significantly elevated hCG levels develop hyperthyroidism and thyrotoxicosis. This is thought to be related to hCG variants with different isoforms having different thyroid-stimulating activity and the presence of polymorphisms of the TSH receptor genes (Hussain & Eck, 2012). Secondary modifications of hCG such as sialylation or glycosylation can affect hCG bioactivity and the sensitivity of the TSH receptor to hCG (Sotello et al., 2016).

Elevated thyroid hormone levels may affect the pituitary-gonadal axis, the metabolism of sex steroid hormones, and the estrogen/androgen action at the breast tissue level. A British case study suggests an association between hyperthyroidism, hypogonadism, and gynecomastia, hypothesizing that the male breast may be more susceptible to a subtle change in estrogen/androgen balance in the presence of both hypogonadism and hyperthyroidism. Hyperthyroid men are reported to have increased FSH and LH and decreased free testosterone. Gynecomastia is observed in 20-40% of men with hyperthyroidism, and thyroid hormones are elevated in ~2% of newly

referred patients with gynecomastia (Mieritz et al., 2014).

In this patient, there was an increase in beta-hCG levels, which reached >150,000 IU/mL at the early time of diagnosis. This beta-hCG hormone was produced by a germ cell tumor (testicular seminoma). High levels of beta-hCG hormone affected the balance of estrogen/androgen, so the patient developed gynecomastia. High levels of beta-hCG are also bound to the TSH receptor causing symptoms of hyperthyroidism.

Serum TSH measurement has the highest sensitivity and specificity of any single blood test used in the elevation of suspected thyrotoxicosis and should be used as an initial screening test. Diagnostic accuracy improves when serum TSH and FT4 are assessed at initial evaluation. The relationship between FT4 and TSH when the pituitary-thyroid axis is intact is an inverse log-linear relationship; therefore, small changes in FT4 result in significant changes in serum TSH concentrations (Ross et al., 2016). Thyrotoxicosis is diagnosed when FT4 is higher than usual, but TSH is suppressed. When FT4 is normal, but TSH is low, it is valuable to measure FT3; when the latter is abnormally high, the diagnosis is T3-toxicosis. When both FT4 and FT3 are normal, but TSH is low, "subclinical thyrotoxicosis" can be applied (Mittra et al., 2008).

To exclude the suspicion of Graves' disease as a cause, and anti-TPO examination also needs to be performed. Anti-TPO (TPO-Ab) is a common autoantibody against Thyroid Peroxidase (TPO). Historically, anti-TPO were detected as thyroid microsomal antibodies using agglutination or immunofluorescence methods. In 1985, TPO was recognized as the target antigen of thyroid autoantibodies. Eighty percent of Graves' disease patients have high anti-TPO antibodies, while positive anti-TPO Ab is detected in over 90% of patients with autoimmune thyroid disease. In the community, the prevalence of TPO-Ab is 11-12% euthyroid subjects (Tan & Aw, 2018).

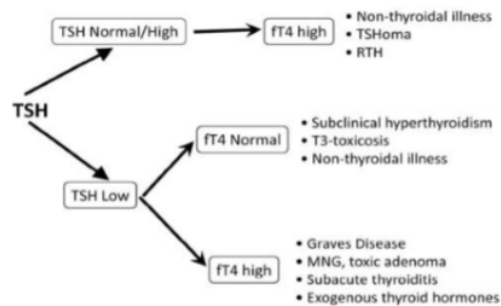


Figure 3. Diagnostic Algorithm in Patients with Clinical Symptoms of Hyperthyroidism (Tan & Aw, 2018).

Most commonly, the hCG-induced alteration of thyroid function results in suppression of TSH and elevation of FT4. T3 levels are usually within the normal range, but hyperthyroidism may occur (Meister et al., 2005). In patients with germ cell tumors and hCG levels greater than 50,000 IU/mL, screening for thyroid dysfunction should be undertaken given the high prevalence of hyperthyroidism related to paraneoplastic syndromes (Hussain & Eck, 2012).

In this patient, the diagnosis of thyrotoxicosis was based on clinical symptoms and supported by investigations. The lab examination at the beginning of diagnosis was found to have a very low TSH value (0.017 mIU/mL) with high FT4 (4.18 ng / mL) and normal FT3 (4.0 pg / mL).

Thyroid ultrasound was performed to see if there was a lump or nodule in the thyroid gland, which could cause hyperthyroidism. However, the thyroid ultrasound showed the thyroid gland was normal. Patients also underwent an additional examination of anti-TPO to exclude the autoimmune cause of thyrotoxicosis, but anti-TPO was also found to be normal, at 10.8 IU/mL (normal: <35). Thus, according to the very high result of beta-hCG levels, the normal result of thyroid ultrasound, and the normal results of anti-TPO, thyrotoxicosis in this patient was related to beta-hCG-induced hyperthyroidism due to germ cell tumor (testicular seminoma).

Standardized recommendations for treating hCG-induced hyperthyroidism in patients with testicular cancer do not exist. Patients with symptomatic hyperthyroidism are treated with beta-adrenergic receptor antagonist therapy and/or anti-thyroid drugs. Anti-thyroid medications are an efficacious adjuvant treatment in hCG-induced hyperthyroidism since hormone synthesis occurs within the thyroid gland. However, hyperthyroidism in hCG-secreting malignant disease represents a paraneoplastic syndrome. Therefore, the definitive treatment is the treatment of cancer (Hussain & Eck, 2012).

Surgical removal of the tumor in the case of germ cell tumors rapidly cures hyperthyroidism and should be performed as soon as possible. Therapy of hyperthyroidism is not indicated in most cases since the evacuation of the tumor or chemotherapy, removing high levels of hCG, cures the hyperthyroidism. Therapy of hyperthyroidism is only indicated in thyrotoxicosis or over hyperthyroidism. In those cases of severe symptoms, Lugol's solution, intravenous iodine, and beta-blocking agents are indicated. Therapy with potassium iodide given orally or sodium iodide given intravenously will rapidly reduce serum-free T4 and T3 levels. Propranolol and other beta-adrenergic antagonist drugs are helpful to control tachycardia and other symptoms of sympathetic activation. Supportive measures such as fluid and electrolyte replacement should be done as needed (Taslami, 2011).

Preoperative evaluation of these patients should be based on history, physical examination, and laboratory testing. The patient must be admitted to an intensive care unit pre-operatively. Blood count, electrolytes, blood gases, thyroid, hepatic, renal functions,  $\beta$ -hCG, and chest radiogram should be carefully evaluated. Treatment has to be individualized. The patient can be prepared for the surgery with oral propylthiouracil (50-100 mg qid), propranolol (20 mg tid), intravenous glucocorticoids, and sodium iodide. Some cases may require only beta-blockers, whereas others may require additional anti-thyroid drugs. Some may not require any treatment if the hyperthyroidism is only biochemical and asymptomatic (Kurdi, 2014).

In patients in whom the diagnosis of thyrotoxicosis is strongly suspected or confirmed, treatment with propranolol, atenolol, sotalol, or other beta-blockers leads to a decrease in heart rate, systolic blood pressure, muscle weakness, and tremor, as well as improvement in the degree of irritability, emotional lability, and exercise intolerance. Since there is insufficient beta-1 selectivity of the available beta-blockers at the recommended doses, these drugs are generally contraindicated in patients with bronchospastic asthma. However, in patients with quiescent bronchospastic asthma in whom heart rate control is essential, a nonselective beta-blocker such as nadolol can be used cautiously, with careful monitoring of pulmonary status (Ross et al., 2016).

In this patient, the thyrotoxicosis condition was managed symptomatically with the administration of beta-blocker, i.e., propranolol and anti-thyroid (26), i.e., thiamazole. The patient received thiamazole 10 mg twice daily and propranolol 10 mg three times daily orally. The treatment for hyperthyroidism aimed to relieve the complaints and minimize the risk of the emergence of a perioperative thyroid crisis.

In patients with germ cell tumors, therapy mainly consists of tumor removal and chemotherapy (Meister et al., 2005). In stage III seminoma, chemotherapy with the BEP regimen (bleomycin, etoposide and cisplatin) is standard treatment; three cycles for good prognosis patients according to the International Germ Cell Cancer Collaborative Group/IGCCCG (alternatively four cycles of EP) and four cycles for intermediate prognosis patients according to IGCCCG (or four cycles of etoposide, ifosfamide, and cisplatin (VIP)), if there are arguments against Bleomycin). Chemotherapy is repeated every 21 days. One cycle of chemotherapy consisted of cisplatin 20 mg/m<sup>2</sup> intravenously (days 1-5), etoposide 100 mg/m<sup>2</sup> IV (days 1-5), and bleomycin 30 mg (days 2, 9, and 16) intravenously. Bleomycin can be replaced by ifosfamide so that the VIP regimen (VP-16/etoposide, ifosfamide, platinum) is used (Oldenburg et al., 2013; Handayani, 2015).

Chemotherapy may produce an initial HCG surge, and patients should be monitored for signs of thyrotoxicosis or thyroid storm, but it is usually followed by normalization of thyroid function if the underlying disease is responsive to treatment (Sotello et al., 2016). This patient was treated with BEP regimen chemotherapy, namely Bleomycin 30 mg (days 2, 9, and 16), Etoposide 100 mg (days 1-5), and Cisplatin 20 mg (days 1-5). During chemotherapy, therapy for hyperthyroidism continued with dose adjustments as the clinical symptoms of hyperthyroidism have improved. Patients received thiamazole 10 mg once daily and propranolol 10 mg twice daily. BEP chemotherapy was administered in 3 cycles at 21 days intervals. In germ cell tumors, almost all of which respond well to effective tumor chemotherapy, beta-hCG-induced hyperthyroidism in germ cell tumors. Tumor relapse can also be associated with recurrence of thyrotoxicosis (Gama, 2001). Seminoma is one of the curable cancers, with cure rates nearing 100% even in stage II disease with surgery and radiotherapy (Bose et al., 2017). Serum TSH may remain suppressed for several months after therapy begins. Therefore TSH is not a suitable parameter for early monitoring of treatment. When thyroid levels have stabilized, a reduction in the dose of 30-50% is recommended, while examinations are repeated within 4-6 weeks (Ross et al., 2016). Most patients with symptomatic paraneoplastic hyperthyroidism will respond quickly after therapy, although some patients require postoperative intensive care due to the emergence of a thyroid crisis (Walkington et al., 2011).

After undergoing surgery and chemotherapy for three cycles, the clinical symptoms of hyperthyroidism in patients significantly improved. Laboratory parameters, including beta-hCG, TSH, FT4, and FT3, gradually improved and approached normal. Finally, in the fourth-month post-surgery, therapy of hyperthyroidism which consisted of propranolol and thiamazole, was stopped as the patient had reached the euthyroid condition.

## SUMMARY

A 26-year-old male patient with a history of cryptorchidism had been reported with complaints of palpitation, diarrhea,

weight loss, fatigue, and sleeping difficulty. Patients also complained of a palpable mass in the lower abdomen and slightly enlarged breasts. From the investigation of TSH and FT4, the patient's clinical symptoms were found in accordance with thyrotoxicosis. Anti-TPO examination and thyroid ultrasound were within normal limits. Patients were treated with beta-blocker and anti-thyroid drugs. Histopathology from a sample of intra-abdominal mass obtained from the open biopsy showed a testicular seminoma. Post-surgery and chemotherapy with the BEP regimen, the clinical symptoms of hyperthyroidism significantly improved. Beta-blocker and anti-thyroid drug therapy were stopped four months after surgery as the patient had reached the euthyroid condition.

## CONFLICT OF INTEREST

The authors declare there is no conflict of interest.

## REFERENCES

- Baagar K, Khan FY, Al-Kuwari E. 2013. Choriocarcinoma syndrome: a case report and a literature view. *Case Rep Oncol Med*:1-4.
- Bose S, Sengupta S, Mukherjee R. 2017. Case report: seminoma in an undescended testis. *SM J Surg*; 3(2):1018-19.
- Carlotto JRM, Colleoni-Neto R, Shigueoka DC, Artigiani-Neto R, Lopes-Filho GJ. 2015. Intra-abdominal seminoma testis in adult: Case Report. *Arq Bras Cir Dig* 28(4):296.
- Dimitriadis GK, Angelousi A, Weickert MO, Randeva HS, Kaltsas G, Grossman A. 2017. Paraneoplastic endocrine syndromes. *Society Endocrinol* 1-51.
- Gama R. 2001. Hyperthyroidism induced by beta-human chorionic gonadotropin. *Postgrad Med J* 77:423-424.
- Handayani W. 2015. Laki-laki 18 tahun dengan tumor testis. Lampung, Universitas Lampung.
- Hussain H, Eck LM. 2012. hCG induced hyperthyroidism due to a metastatic germ cell tumor. *Kansas J of Med*: 58-61.
- Kurdi MS. 2014. Trophoblastic hyperthyroidism and its perioperative oncems. *Thyroid Disorders*:243-269.
- Meister LHF, Hauck PR, Graf H, Carvalho GA. 2005. Hyperthyroidism due to secretion of human chorionic gonadotropin in a patient with metastatic choriocarcinoma. *Arq Bras Endocrinol Metab* 49(2):319-322.
- Mieritz MG, Sorensen K, Aksglaede L, Mouritsen A, Hagen CP, Hilsted L, Andersson AM, Juul A. 2014. Elevated serum levels of free triiodothyronine in adolescent boys with gynaecomastia compared with controls. *Eur J Endocrinol* 171:193-198.
- Mitra ES, Niederkohr RD, Rodriguez C, El-Maghraby T, McDougall. 2008. Uncommon causes of thyrotoxicosis. *J Nucl Med* 49:265-278.
- Oldenburg J, Fossa SD, Nuver J, Heidenreich A, Schmoll HJ, Bokemeyer C, Horwich A, Beyer J, Kataja V. 2013. Testicular seminoma and non-seminoma: ESMO clinical practice guidelines for diagnosis, treatment, and follow-up. *Annals of Oncol* 24(Suppl 6):vi125-vi132.
- Palace MR. 2017. Perioperative management of thyroid dysfunction. *Health Services Insight* 1-5.
- Peloso LC, Gerber DE. 2010. Paraneoplastic syndromes: an approach to diagnosis and treatment. *Mayo Clin Proc* 85(9):838-854.
- Ross DS, Burch HB, Cooper DS, Greenlee MC, Laurberg P, Maia AL, Rivkees SA, Samuels M, Sosa JA, Stan MN, Walter MA. 2016. American thyroid association guidelines for diagnosis and management of hyperthyroidism and other

- causes of thyrotoxicosis. *Thyroid* 26(10):1343-1421.
- Sotello D, Rivas AM, Test VJ, Lado-Abeal J. 2016. Choriocarcinoma Presenting with Thyrotoxicosis. *Bayl Univ Med Cent* 29(1):42-43.
- Sutjahjo A, Tjokroprawiro A. 2015. Tirotoksikosis. In: Tjokroprawiro A, Setiawan PB, Effendi C, Santoso D, Soegiarto G (eds.). *Buku Ajar Ilmu Penyakit Dalam Fakultas Kedokteran Universitas Airlangga, Rumah Sakit Pendidikan Dr. Soetomo Surabaya, Edisi 2*. Surabaya, Airlangga University Press, p136-139.
- Tan JG, Aw TC. 2018. Assessment of thyroid function. *J Endocr Disord* 5(1): 1030.
- Taslimi R. 2011. Forgotten abdominal pain. *Middle East J Digest Dis* 3(1):72-73.
- The Testicular Cancer Research Center. 2018. Testicular cancer tests: the pathology report. Accessed from [http://theterc.org/pathology\\_report.html](http://theterc.org/pathology_report.html)
- Walkington L, Webster J, Hancock BW, Everard J, Coleman RE. 2011. Hyperthyroidism and human chorionic gonadotrophin production in gestational trophoblastic disease. *British J Cancer* 104:1665-1669.

# Diagnostic and Management Problems of Hyperthyroidism in A Patient with Testicular Seminoma

## ORIGINALITY REPORT

**20%**  
SIMILARITY INDEX

%  
INTERNET SOURCES

**20%**  
PUBLICATIONS

%  
STUDENT PAPERS

## PRIMARY SOURCES

- 1** Mieritz, M. G., K. Sorensen, L. Aksglaede, A. Mouritsen, C. P. Hagen, L. Hilsted, A.-M. Andersson, and A. Juul. "Elevated serum levels of free triiodothyronine in adolescent boys with gynaecomastia compared with controls", *European Journal of Endocrinology*, 2014.  
Publication **2%**
- 2** Georgios K Dimitriadis, Anna Angelousi, Martin O Weickert, Harpal S Randeva, Gregory Kaltsas, Ashley Grossman. "Paraneoplastic endocrine syndromes", *Endocrine-Related Cancer*, 2017  
Publication **2%**
- 3** Khaled Baagar, Fahmi Yousef Khan, Einas AlKuwari. "Choriocarcinoma Syndrome: A Case Report and a Literature Review", *Case Reports in Oncological Medicine*, 2013  
Publication **2%**
- 4** Marcia Rashelle Palace. "Perioperative Management of Thyroid Dysfunction", *Health* **1%**



5

Alice Monzani. "A novel familial variation of the thyroid hormone receptor beta gene (I276N) associated with resistance to thyroid hormone", *Thyroid*, 01/08/2012

Publication

---

1 %

6

"Encyclopedia of Cancer", Springer Science and Business Media LLC, 2017

Publication

---

1 %

7

Tutik Kusmiati, Ni Made Mertaniasih, Johanes Nugroho Eko Putranto, Budi Suprapti et al. "The role of C-Reactive protein as an inflammatory marker to predict prolonged QTc interval in rifampicin-resistant tuberculosis patients: A case-control study", *Annals of Medicine and Surgery*, 2021

Publication

---

1 %

8

Abebayehu Zemedkun Mekonen, Miesso Negesso, Hailemariam Mulugeta Kasim, Zemedu Awoke Ferede. "

Perioperative Management of Thyroidectomy After a Failed Antithyroid Therapy in a Resource Limited Setting: A Clinical Case Report

", *Open Access Surgery*, 2020

Publication

---

1 %

9

Oldenburg, J., S. D. Fossa, J. Nuver, A. Heidenreich, H.-J. Schmoll, C. Bokemeyer, A. Horwich, J. Beyer, and V. Kataja. "Testicular seminoma and non-seminoma: ESMO Clinical Practice Guidelines for diagnosis, treatment and follow-up", *Annals of Oncology*, 2013.

Publication

---

1 %

10

Ludimyla H.F. Meister, Patrícia R. Hauck, Hans Graf, Gisah A. Carvalho. "Hyperthyroidism due to secretion of human chorionic gonadotropin in a patient with metastatic choriocarcinoma", *Arquivos Brasileiros de Endocrinologia & Metabologia*, 2005

Publication

---

1 %

11

Rosaria Maddalena Ruggeri, Alfredo Campennì, Desiree Deandreis, Massimiliano Siracusa et al. "SARS-COV-2-related immune-inflammatory thyroid disorders: facts and perspectives", *Expert Review of Clinical Immunology*, 2021

Publication

---

1 %

12

CARLOTTO, Jorge Roberto Marcante, Ramiro COLLEONI-NETO, David Carlos SHIGUEOKA, Ricardo ARTIGIANI-NETO, and Gaspar de Jesus LOPES-FILHO. "INTRA-ABDOMINAL SEMINOMA TESTIS IN ADULT: CASE REPORT", *ABCD Arquivos Brasileiros de Cirurgia Digestiva (São Paulo)*, 2015.

Publication

1 %

---

13 Karen Beer. "Low Thyroid-Stimulating Hormone: What Is Next?", Physician Assistant Clinics, 2017 1 %

Publication

---

14 Ronit Yerushalmi. "Are platinum-based chemotherapeutic drugs safe for patients with Charcot-Marie-Tooth disease?", Journal of the Peripheral Nervous System, 6/2007 1 %

Publication

---

15 "Pathology and Biology of Human Germ Cell Tumors", Springer Science and Business Media LLC, 2017 1 %

Publication

---

16 George J. Kahaly, Luigi Bartalena, Lazlo Hegedüs, Laurence Leenhardt, Kris Poppe, Simon H. Pearce. "2018 European Thyroid Association Guideline for the Management of Graves' Hyperthyroidism", European Thyroid Journal, 2018 1 %

Publication

---

17 Lucien Marchand, Paul Chabert, Elise Chaudesaygues, Mélanie Grasse et al. "An unusual cause of cardiothyreosis", Gynecological Endocrinology, 2015 1 %

Publication

---

18 A GERL, P WEIGL, WD GASSEL, W WILMANNNS. "MYOCARDIAL-INFARCTION AFTER ADJUVANT <1 %

CHEMOTHERAPY FOR RESECTED STAGE-II  
NONSEMINOMATOUS TESTICULAR CANCER",  
Oncology Reports, 1995

Publication

---

19

Wieland Voigt, Gita Maher, Hans-Heinrich Wolf, Hans-Joachim Schmoll. "Human Chorionic Gonadotropin-Induced Hyperthyroidism in Germ Cell Cancer – a Case Presentation and Review of the Literature", Oncology Research and Treatment, 2007

<1 %

Publication

---

20

Ken Takezawa, Isamu Okamoto, Junya Fukuoka, Kaoru Tanaka et al. "Large Cell Neuroendocrine Carcinoma of the Mediastinum with  $\alpha$ -Fetoprotein Production", Journal of Thoracic Oncology, 2008

<1 %

Publication

---

21

A. Maitra, M. Basal, A. Kapoor, R. Biswas. "Delayed tendon reflex (a video demonstration)", Case Reports, 2010

<1 %

Publication

---

22

"Discussion", American Journal of Obstetrics and Gynecology, 2006

<1 %

Publication

---

23

Cheng Hou, Xinbai Jiang, Na Li, Zhenhua Zhang, Qian Zhang, Jinyou Shen, Xiaodong Liu. "Enhanced 4-chlorophenol biodegradation by integrating Fe<sub>2</sub>O<sub>3</sub> nanoparticles into an

<1 %

anaerobic reactor: Long-term performance and underlying mechanism", Frontiers of Environmental Science & Engineering, 2021

Publication

---

24

Soedarsono Soedarsono, Anna Febriani, Helmia Hasan, Anita Widyoningroem. "Management of severe COVID-19 patient with negative RT-PCR for SARS-CoV-2: Role of clinical, radiological, and serological diagnosis", Radiology Case Reports, 2021

Publication

---

<1 %

25

A. Lorch, A. Neubauer, M. Hackenthal, A. Dieing, J.T. Hartmann, O. Rick, C. Bokemeyer, J. Beyer. "High-dose chemotherapy (HDCT) as second-salvage treatment in patients with multiple relapsed or refractory germ-cell tumors", Annals of Oncology, 2010

Publication

---

<1 %

26

Endocrinology and Diabetes, 2014.

Publication

---

<1 %

27

A. Fleischman, V. W. Chiang. "Carbamazepine Overdose Recognized by a Tricyclic Antidepressant Assay", PEDIATRICS, 2001

Publication

---

<1 %

Exclude bibliography  On